Second Edition

Emergency Imaging

Mandip K Heir
Ram Vaidhyanath

pocket tutor

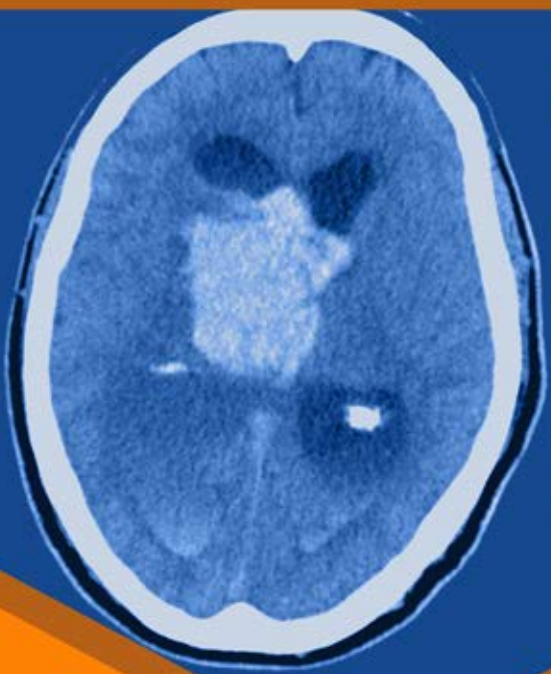

JP

Emergency Imaging

Second Edition

Mandip K Heir MBChB PG Dip MedEd FRCR
Consultant Radiologist
University Hospitals of Leicester NHS Trust
Leicester, UK

Ram Vaidhyanath DMRD DNB FRCR EBiHNR
Consultant Radiologist
The RCR – Dr PK Ganguli Visiting Professor
University Hospitals of Leicester NHS Trust
Leicester, UK

JAYPEE BROTHERS

pocket tutor

JP medical publishers

Contents

Preface *v*
Acknowledgements *xi*
Dedication *xiii*

Chapter 1 First principles of emergency imaging
1.1 Imaging modalities 1
1.2 Use of contrast media 6
1.3 Investigation requesting and image interpretation 8

Chapter 2 Understanding normal results
2.1 Plain radiographs 9
2.2 Ultrasound 9
2.3 Computed tomography 14
2.4 Magnetic resonance imaging 17

Chapter 3 Recognising abnormalities
3.1 Fractures 19
3.2 Inflammation and abscess 22
3.3 Effusion 24
3.4 Haemorrhage 26
3.5 Thrombosis 28
3.6 Tumours and mass lesions 30
3.7 Calcifications 31
3.8 Foreign bodies 34

Chapter 4 Gastrointestinal system
4.1 Key radiological anatomy 37
4.2 Trauma 41
4.3 Acute inflammation 46
4.4 Bowel obstruction 55
4.5 Acute mesenteric ischaemia 64
4.6 Acute gastrointestinal haemorrhage 68

JAYPEE BROTHERS

Chapter 5 Genitourinary system
5.1 Key radiological anatomy 73
5.2 Renal trauma 76
5.3 Bladder trauma 78
5.4 Urinary tract calculi 79
5.5 Testicular torsion 84
5.6 Ovarian torsion 85

Chapter 6 Chest and vascular disease
6.1 Key radiological anatomy 89
6.2 Thoracic trauma 92
6.3 Acute aortic syndrome 104
6.4 Abdominal aortic aneurysm 106
6.5 Deep vein thrombosis 110
6.6 Pulmonary embolism 111
6.7 Foreign bodies 113

Chapter 7 Head and neck
7.1 Key radiological anatomy 117
7.2 Facial trauma 124
7.3 Orbital trauma 128
7.4 Orbital infection 131
7.5 Retropharyngeal abscess 133
7.6 Foreign bodies 134

Chapter 8 Neurological imaging
8.1 Key radiological anatomy 137
8.2 Head injury 142
8.3 Extradural haemorrhage 146
8.4 Subdural haemorrhage 148
8.5 Subarachnoid haemorrhage 152
8.6 Carotid/vertebral artery dissection 154
8.7 Stroke 155
8.8 Cerebral venous thrombosis 160
8.9 Space-occupying lesions 162

Chapter 9 Musculoskeletal system
9.1 Key radiological anatomy 167
9.2 Cervical spine injuries 175

JAYPEE BROTHERS

9.3 Thoracic spine injuries 180
9.4 Lumbar spine injuries 181
9.5 Cauda equina compression 186
9.6 Spondylodiscitis 188

Chapter 10 Paediatric emergency imaging
10.1 Upper gastrointestinal tract disorders 191
10.2 Lower gastrointestinal tract disorders 196
10.3 Musculoskeletal disorders 200

Chapter 11 Emergency cases
11.1 Chest pain and breathlessness 207
11.2 Acute abdominal pain 210
11.3 Low back pain 211
11.4 Swollen right eye 213
11.5 Weight loss and jaundice 216
11.6 Neck pain after a fall 220
11.7 Collapse 222
11.8 Sudden onset headache 225

Index *229*

JAYPEE BROTHERS

chapter 7

Head and neck

7.1 Key radiological anatomy

Facial bones

Patients with facial trauma will be initially assessed and, if necessary, plain radiographs will be requested. Two views are usually obtained as part of a trauma series: (1) occipitomental (OM) 15 and (2) OM 30 views. On an OM 15 view (**Figure 7.1**), structures to review are the frontal bone Ⓐ, frontal sinuses Ⓑ, zygomatic bone Ⓒ, maxilla Ⓓ, maxillary sinuses Ⓔ, and mandible Ⓕ. Indirect signs of injury include overlying soft tissue swelling and fluid levels within the sinuses.

Common facial fractures disrupt the three 'lines of Dolan' (**Figure 7.2**), which when drawn can look like elephant trunks:

1. The **orbital line** ⓄⓁ is drawn through the zygomaticofrontal suture, along the superior orbital rim and through the frontal sinuses.
2. The **zygomatic line** ⓏⓁ is drawn along the superior border of the zygomatic arch, the inferior orbital rim and over the nasal bridge.
3. The **maxillary line** ⓂⓁ is along the inferior border of the zygomatic arch, inferior margins of maxillary antra and across the maxilla.

Mandible

Mandibular injuries can be assessed on an orthopantomogram (OPT). The mandible consists of a body Ⓖ, angle Ⓗ, ramus Ⓘ, condyle Ⓙ, and coronoid process (**Figure 7.3**). The temporomandibular (TM) joint Ⓛ comprises the mandibular condyle and the articular tubercle of the temporal bone.

Orbits

Computed tomography (CT) is the modality of choice to assess bony injury to the orbit (**Figure 7.4**). Bony structures to

JAYPEE BROTHERS

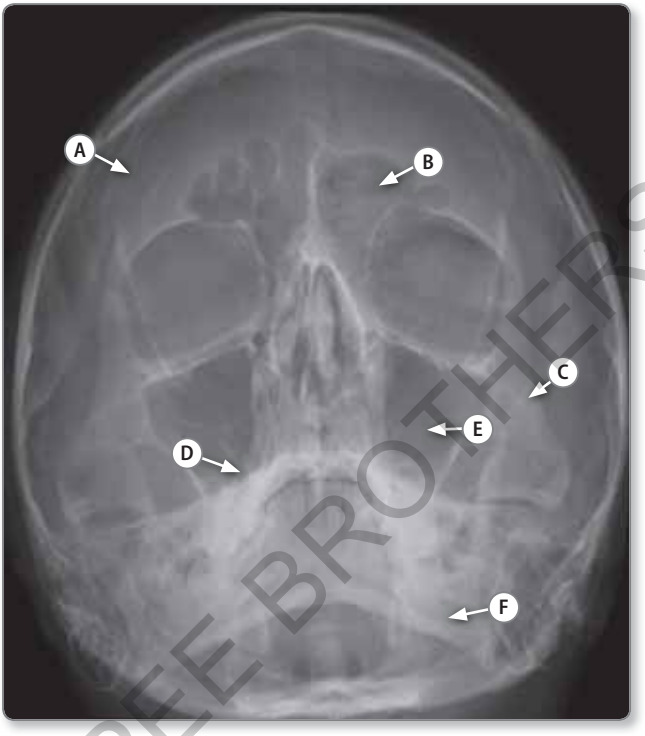

Figure 7.1 Occipitomental (OM) 15 view demonstrating the facial bones and sinuses. Frontal bone (A), frontal sinuses (B), zygomatic bone (C), maxilla (D), maxillary sinuses (E) and mandible (F).

JAYPEE BROTHERS

assess include the orbital roof (M), medial orbital wall (N), lateral orbital wall (O), and the orbital floor (P). Important soft tissue structures that are assessed better by magnetic resonance imaging (MRI) include the optic nerve (Q), inferior rectus muscle (R), lateral rectus muscle (S), medial rectus muscle (T), and superior rectus muscle (U) (**Figures 7.4–7.6**).

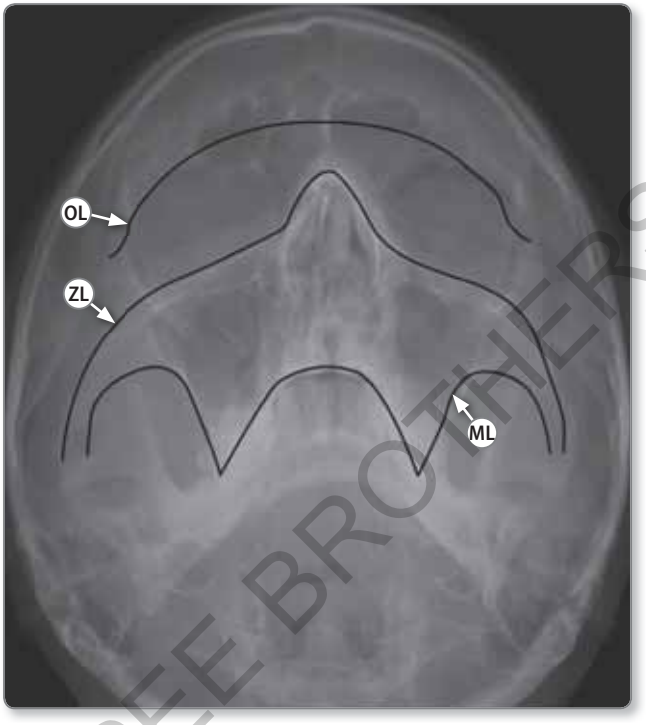

Figure 7.2 Occipitomental (OM) 30 view demonstrating the lines of Dolan. Orbital line (OL), zygomatic line (ZL) and maxillary line (ML).

JAYPEE BROTHERS

Soft tissues of the neck

The deep spaces of the suprahyoid head and neck contain fascial-bound compartments within which infection can track and spread beyond (**Figure 7.7**).

These spaces include the:

- **Masticator space** (V): This is lateral to the parapharyngeal space and contains the muscles of mastication, ramus

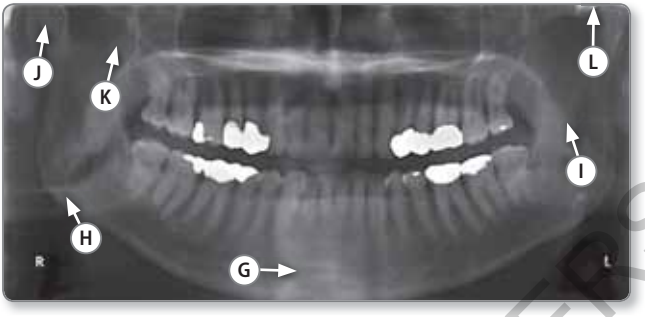

Figure 7.3 Orthopantomogram demonstrating the mandible anatomy: Body (G), angle (H), ramus (I), condyle (J), coronoid process (K) and the temporomandibular joint (L).

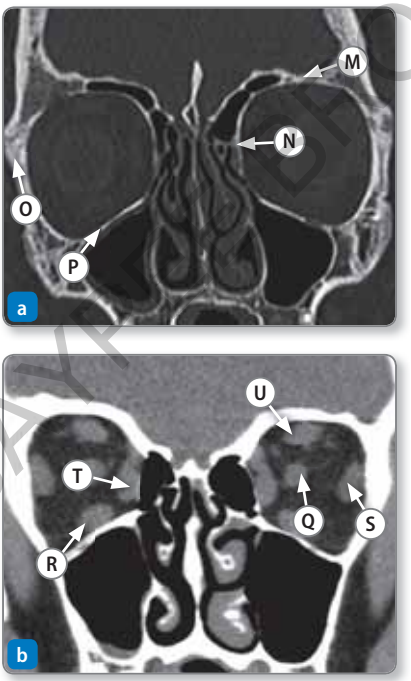

Figure 7.4 (a) Coronal CT scan showing the bony structure of the orbits. Orbital roof (M), medial orbital wall (N), lateral orbital wall (O) and the orbital floor (P). (b) Coronal CT scan showing the soft tissue structures of the orbits. Optic nerve (Q), inferior rectus muscle (R), lateral rectus muscle (S), medial rectus muscle (T) and superior rectus muscle (U).

JAYPEE BROTHERS

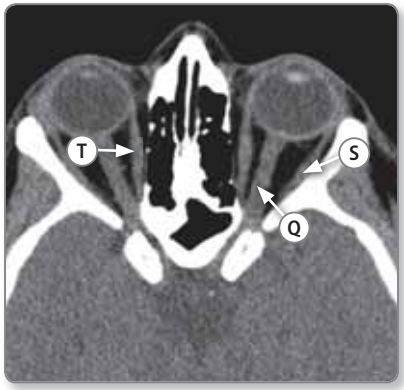

Figure 7.5 Axial CT scan showing the optic nerve (Q), lateral rectus (S) and medial rectus (T).

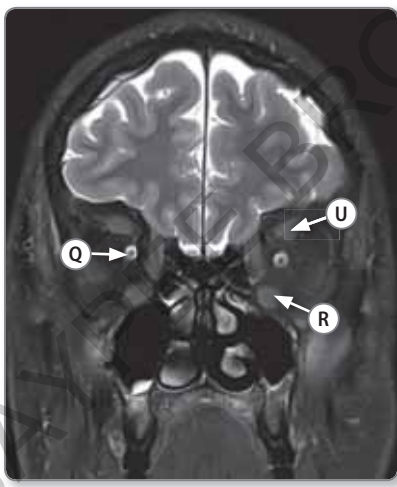

Figure 7.6 Coronal MR T2-weighted scan demonstrating the optic nerve (Q), superior rectus (U) and inferior rectus (R).

JAYPEE BROTHERS

and body of mandible, and the mandibular division of the trigeminal nerve.

- **Parapharyngeal space** (W): This is a centrally located space extending from the skull base to the hyoid. This space is effaced when there are lesions within the other spaces (**Table 7.1** and **Figure 7.8**)

- **Retropharyngeal space** (X): This is a potential space anterior to the prevertebral space, extending from the skull base to the third thoracic vertebra



Figure 7.7 (a) Axial MR at the level of the nasopharynx demonstrating the masticator space (V), retropharyngeal space (X), prevertebral space (Y) and carotid space (Z). (b) Axial MR at the level of the oropharynx demonstrating the masticator space (V), parapharyngeal space (W), retropharyngeal space (X), prevertebral space (Y) and parotid space (AA).

JAMES ROTHERS

Compartment in which pathology present	Direction in which parapharyngeal space is effaced
Masticator space	Posteromedial
Retropharyngeal space	Anterolateral
Carotid space	Anterior
Parotid space	Anteromedial

Table 7.1 Effacement of the parapharyngeal space by pathologies in related deep spaces of the suprahyoid head and neck.

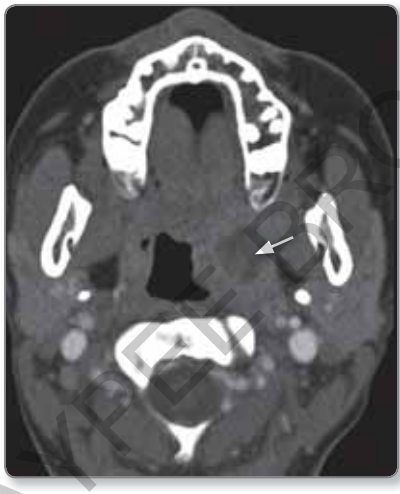

Figure 7.8 Axial CT post-contrast demonstrating a large left parapharyngeal abscess (arrow) with displacement of the oropharynx.

JAYPEE BROTHERS

- **Prevertebral space** (Y): This is a space posterior to the retropharyngeal space extending from the skull base to the fourth thoracic vertebra
- **Carotid space** (Z): This composes the carotid fascia which extends from the skull base to the aortic arch
- **Parotid space** (AA): This space contains the parotid gland, facial nerve, and the retromandibular vein

7.2 Facial trauma

Facial injury and fractures are common presentations in the emergency department as a result of road traffic collisions, assault, falls, and other trauma. The type of injury sustained depends upon the part of the face injured and the force applied.

Localised injuries (**Figures 7.9** – **7.11**) include nasoethmoid fractures, zygomatic complex fractures, mid facial fractures, and mandibular fractures.

Key facts

- A naso-orbitoethmoid (NOE) complex fracture results from trauma to the nasal bridge. The fracture extends into the nose through the ethmoids and is more serious than isolated nasal bone fracture
- **Zygomaticomaxillary complex (ZMC) fractures (quadripod or tripod fractures)**: This includes fractures through the zygomaticofrontal, zygomaticotemporal, and zygomaticomaxillary sutures. It is essential to assess involvement of the orbital floor as this affects the management of the patient
- Mid-facial fractures include Le Fort I, II, and III fractures (**Table 7.2**) – these result in separation of part or all of a portion of the maxilla from the skull base. In order to be classed as a Le Fort fracture, the junction of the posterior



Figure 7.9 Orthopantomogram demonstrating a right-sided mandibular fracture (arrow).

JAYPEE BROTHERS



Figure 7.10 Facial radiograph demonstrating a left zygomatic complex fracture and disruption in the lines of Dolan (arrows).

JAYPEE BROTHERS

maxillary sinus with the pterygoid plates of the sphenoid must be disrupted

- The mandible is considered a complete ring and hence fractures usually involve both sides of the mandible. Therefore, if one fracture is observed another should be sought. Mandibular fractures can be associated with TM joint dislocation
- Complex mid-facial and mandibular fractures can compromise the airway and hence it should be secured before imaging

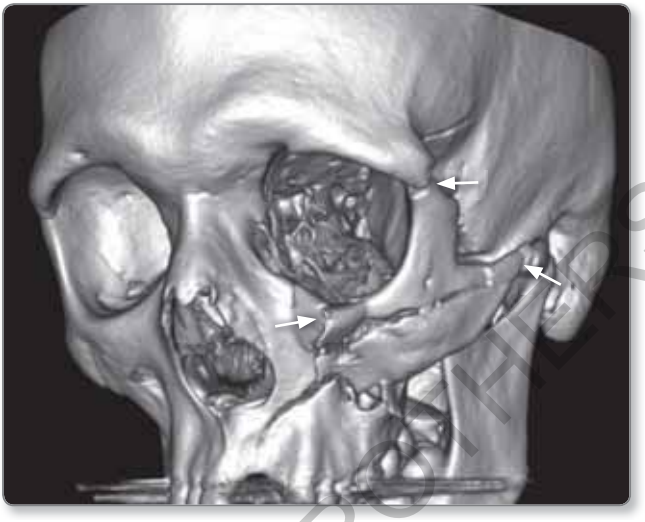

Figure 7.11 CT reconstruction demonstrating a left zygomatic complex fracture.

Radiographic findings

Plain radiograph Direct signs of facial fracture include disruptions of the Dolan lines. These may be seen as linear lucencies, cortical defects, bone fragments overlying each other and facial asymmetry. Indirect signs include soft tissue swelling and fluid levels in the paranasal sinuses.

CT CT is the modality of choice and the signs seen on plain radiographs are better appreciated. Another subtle sign that a fracture is present includes intracranial or intraorbital air.

Key signs

- Disruption of lines of Dolan
- Intraorbital air
- Mandibular instability

JAYPEE BROTHERS

Le Fort type	Fracture extension
Le Fort I	
Le Fort II	
Le Fort III	

Table 7.2: Mid-facial fractures – Le Fort I, II, and III fractures.

JAYPEE BROTHERS

Management

Further management of the patient will depend on the severity of the injury sustained and its location. Referral to ear, nose, and throat (ENT) or maxillofacial surgeons should be made.

7.3 Orbital trauma

Orbital fractures are usually the result of direct trauma to the orbit.

Key facts

- 'Blowout' fractures of the orbital wall are the result of blunt trauma. The term 'blowout' is used when there is a fracture of the inferior (floor) and/or medial wall of the orbit and the orbital rim is intact
- Inferior wall or floor fracture may occur in combination with other facial fractures. This includes posterior extension of the zygomaticomaxillary complex fracture into the zygomaticosphenoid suture (quadripod). Le Fort II fractures also involve the orbital floor. NOE complex fractures can involve the medial wall
- High impact fractures of the brain and cervical spine can involve the superior orbital rim, part of the frontal bone. Involvement of the posterior wall of the frontal sinus can result in cerebrospinal fluid (CSF) rhinorrhoea and possibly meningitis

Clinical insight

Make sure to examine eye movements in a patient who has sustained a blow to the orbit. Restriction of upward gaze indicates an associated injury to the inferior rectus muscle. Loss of vision or decreasing visual acuity warrants urgent ophthalmology referral.

Radiographic findings

Plain radiograph An orbital floor fracture may be very subtle on plain radiograph and may be interpreted as normal. However, there are indirect signs of orbital floor fracture (**Figure 7.12**), which include fluid level in the maxillary sinus and overlying soft tissue swelling. There may be additional soft tissue seen under the orbital floor 'teardrop sign'. This indicates herniation of

JAYPEE BROTHERS

pocket tutor

Second Edition

Emergency Imaging

pocket tutor Emergency Imaging is the perfect companion for medical students, junior doctors, allied health-care professionals and anyone seeking to improve their working knowledge of the radiological appearance of common emergency presentations.

- ✓ Guide to appearance of normal and abnormal signs across different imaging modalities, helping you to navigate imaging results quickly and recognise underlying pathology
- ✓ Clearly labelled, high quality images teach you to identify anatomical landmarks and clinical signs
- ✓ Concise disease descriptions give key facts and cardinal imaging features to look out for in emergency cases
- ✓ Additional chapter on common emergency case presentations and how they are imaged

pocket tutor is the best-selling series that reinforces knowledge fast: in practice, in tutorials, before exams. Reminders of key underlying principles, insightful clinical scenarios and an accessible format mean you can trust **pocket tutor** to provide you with the right answer, whenever you need it.

JP medical publishers

www.jpmedpub.com

ISBN 978-1-78779-120-6

9 781787 791206