Recent Advances in Orthopaedics



Edited by
Gregg R Klein
P Maxwell Courtney

Contents

Preface v
Acknowledgements ix

Chapter 1 What is new in spine surgery? 1
Zachary T Grace, John D Koerner

Chapter 2 Hip preservation: An evidence-based update 15
Robert L Parisien, Joshua S Hornstein

Chapter 3 What is new in total hip arthroplasty? Direct anterior approach 35
Harlan B Levine, Gregg R Klein

Chapter 4 What is new in total hip arthroplasty? A Latin-American Perspective in 2020 43
Claudio Diaz-Ledezma, Cristián Morales Huircaman

Chapter 5 What is new in total knee arthroplasty? In klein/ courtney recent advances in orthopaedics 51
Chad A Krueger, Jess H Lonner

Chapter 6 What is new in knee arthroplasty? European perspective 63
Tanvir Khan, Andrew Price, Abtin Alvand, William Jackson

Chapter 7 Revision total hip and knee replacement 75
Ari Seidenstein

Chapter 8 What is new in sports medicine? Orthobiologics: An evidence-based review of the literature 91
Rocco Bassora

Chapter 9 What is new in shoulder and elbow surgery? 103
Frank G Alberta, Christopher L Antonacci, Jeffrey D Tompson

Chapter 10 What is new in orthopaedic trauma? 117
Brianna R Fram, Taylor Paziuk, Gerard Chang, James C Krieg

Chapter 11 What is new in hand surgery? 133
Kevin Lutsky, Michael Nakashian, Samir Sodha, Jonas Matzon, Pedro Beredjiklian

Chapter 12 What is new in foot and ankle surgery? 147
Tara Gaston Moncman, Joseph Daniel, Rachel Shakked

Chapter 13 What is new in orthopaedic oncology? 177
Joseph Ippolito, Valdis Lelkes, Francis Patterson

Chapter 14 What is new in robotic knee arthroplasty? 191
Gregg R Klein, Harlan B Levine

Chapter 15 Coronavirus disease 2019: An orthopaedic perspective 203
Paul M Sousa, Chad A Krueger

Chapter 2

Hip preservation: An evidence-based update

Robert L Parisien, Joshua S Hornstein

JAYPEE BROTHERS

INTRODUCTION

Over the course of the last two decades, there has been a rapidly expanding understanding of the spectrum of hip pathomorphology and the surgical treatment thereof. In addition to open surgical options, advances in arthroscopic skill and techniques have expanded the surgeon population attempting to understand and manage these disorders. In this review, we provide an update on recent evidence and clinical implications of hip preservation surgery for the management of young adult hip pathomorphology including hip dysplasia, intra-articular and extra-articular hip impingement, as well as the sequelae of paediatric hip disease.

DYSPLASIA

Dysplasia of the hip joint typically manifests as decreased anterior and lateral coverage of the femoral head. Radiographic parameters consistent with dysplasia include a lateral centre edge angle (LCEA) <20°, anterior centre edge angle (ACEA) <20°, sharp angle >45°, and Tönnis angle >10° [1]. Since its introduction >20 years ago, the Bernese periacetabular osteotomy (PAO) has been adopted as the preferred contemporary surgical treatment in adults with symptomatic hip dysplasia and without signs of osteoarthritis (OA). The surgical goals of PAO include pain relief and improved function and quality of life while preventing or delaying secondary development of OA. As such, we have seen a nearly four-fold increase in the number of operations completed in the adult population since 2005. Advantages of this osteotomy include maintenance of the blood supply to the articular fragment and an intact posterior column providing construct stability, thus allowing early patient mobilisation. Furthermore, the PAO technique enables acetabular reorientation such that both anterior and lateral coverage can be achieved. By normalising acetabular coverage, the PAO technique may decrease femoroacetabular chondral and labral contact stress, which may delay the onset of hip OA [2]. In evaluation of return to play (RTP) in 46 patients with a mean age of 26 years

Robert L Parisien MD, Orthopaedic Surgery and Sports Medicine, Icahn School of Medicine at Mount Sinai, New York City, New York, USA
Email: Robert.Parisien@MountSinai.org

Joshua S Hornstein MD, Orthopaedic Surgery and Sports medicine, Rothman Institute, Bordentown Township, NJ, USA
Email: Joshua.Hornstein@RothmanOrtho.com

following PAO, Heyworth et al reported RTP in 80% of patients at a median of 9 months with 73% successfully returning to the same level of competition [3]. Abraham et al [4] and Knight et al [5] emphasise the need for longer follow-up using biomechanical analysis to better understand the role of PAO in preventing OA. Troelson et al [6] reported hip joint survival rates of 81.6% at 9.2 years. Negative predictive factors included age >45 years, preoperative LCEA < 0°, post-operative LCEA <30°, or >40°, pre- or post-operative joint space <3 mm, pre-operative Tönnis OA grade ≥II, and pre-operative os acetabuli. Steppacher et al [7] reported the long-term results of 68 hips followed for a minimum of 19 years. At 20 years, there was a one-grade difference in Tönnis OA grade with a 60.5% hip survival rate and consistently good patient-reported outcomes (PROs). Factors predictive of poor surgical outcomes include age >30 years, patients with preoperative Merle d'Aubgné and Postel scores of 14 or less and those with preoperative Tönnis OA grade of 2 or more. As a complement to radiographic Tönnis grading, Cunningham et al [8] found the delayed gadolinium-enhanced magnetic resonance image of cartilage (dGEMRIC) index to be the most important predictor of failure of PAO surgery. Their follow-up study identified anterior dome cartilage as the most important factor contributing to survivorship. In evaluation of 75 hips treated with PAO, Lerch et al [9] identified that 33% reported good clinical results, no progression of OA, and no conversion to total hip arthroplasty (THA) at 30-year follow-up. Negative prognostic indicators included age at surgery > 40 years, pre-operative impingement signs or limited range of motion (specifically IR < 20), Tönnis grade > I, postoperative acetabular retroversion, and low preoperative PROs.

Addressing intra-articular pathology at the time of PAO

Periacetabular osteotomy is performed to restore the normal acetabular coverage of the femoral head. The reorientation of the acetabulum, however, may create iatrogenic femoroacetabular impingement (FAI) [10]. Additionally, pre-existing chondrolabral lesions can cause symptoms that mitigate the clinical success of PAO. As such, arthrotomy and arthroscopy prior to performance of a PAO may be utilised to address intra-articular chondrolabral lesions. Redmond et al [11] performed a recent systematic review of eight articles (775 patients) and reported a substantial presence of chondrolabral injuries at the time of PAO with arthroscopy able to more accurately identify such lesions as compared to arthrotomy. Furthermore, Ginnetti et al [12] reported on a retrospective series of 151 patients who underwent PAO and hip arthrotomy and compared the outcome to 39 patients who underwent PAO alone. A decreased head–neck offset was identified and corrected with femoral osteochondroplasty in 85% of patients but the effect on survivorship and symptomatology was not well understood. Literature on this topic continues to present controversy with differing outcomes among studies. Kain et al [13] performed an interesting analysis in which they sought to determine the effectiveness of PAO follow failed hip arthroscopy for labral pathology in dysplastic patients. The authors identified no difference in PROs in those patients undergoing a PAO following prior failed hip arthroscopy as compared to those undergoing primary PAO without previous arthroscopy. Therefore, PAO may be a reasonable treatment option for hip joint preservation following failed arthroscopic labral debridement. Thus, in 2020, there remain differing approaches for the management of intra-articular pathology at the time of PAO.

JAYPEE BROTHERS

Periacetabular osteotomy for acetabular retroversion

Patients with significant acetabular retroversion often have anterior overcoverage and deficient posterior wall coverage evident via the radiographic cross-over sign. The PAO allows reorientation of the acetabular surface relative to the femoral head relieving abnormal anterior impingement and restoring normal posterior coverage. Siebenrock et al [14] reported on a series of 29 hips (22 patients) that underwent an anteversion-producing PAO. At a minimum follow-up of 2 years, 26 of 29 hips experienced good or excellent results. Peters et al [15] reported the results of reverse PAO for acetabular retroversion in 30 patients and found significantly improved clinical outcomes (based on Harris hip scores) and 28 of 30 hips experienced good or excellent outcomes.

Borderline dysplasia and the role of arthroscopy

In the setting of borderline hip dysplasia (BHD) (LCEA, 20–25°), the labrum may hypertrophy in response to increased load and subsequently assume a more important role as a weight-bearing surface in addition to providing a greater contribution to joint stability. Decreasing acetabular coverage leads to greater joint reaction forces imparted on the labrum, raising the risk for developing labral tears, degeneration, and detachment. Additionally, the reduced acetabular articular surface results in increased contact pressure, which may result in articular cartilage degeneration.

An early series by Byrd et al [16] of 48 hips having undergone hip arthroscopy for either symptomatic dysplasia or BHD identified an improvement in the modified Harris hip score (mHHS) with no difference noted in outcomes between dysplastic and borderline dysplastic hips. An additional evaluation by Hwang et al [17] analysed the utility of arthroscopy in patients with symptomatic BHD. A total of 162 patients having undergone arthroscopy for labral pathology were included. The authors found no difference in lateral labral thickness between the dysplastic group as compared to non-dysplastic controls. At a mean follow-up of 87 months, patients reported increased clinical outcome scores without demonstration of increased rates of OA, thus supporting hip arthroscopy for BHD. Similarly, a recent study by Beck et al [18] evaluated clinical outcomes of patients who underwent hip arthroscopy for BHD. Compared to matched-controls with adequate acetabular coverage, patients with BHD demonstrated no significant difference in clinical success at 5-year follow-up. With regards to revision arthroscopy, a recent analysis compared revision hip arthroscopy in patients with BHD with both primary arthroscopy in patients with BHD and revision hip arthroscopy in patients without BHD [19]. The authors reported that BHD patients having undergone revision arthroscopy demonstrated clinical improvement but were less likely to achieve PASS metrics for several PROs as compared to the BHD primary and non-BHD revision group. Furthermore, Cvetanovich et al [20] reported on arthroscopic treatment of FAI hips with BHD and compared them to a matched group of non-dysplastic hips with FAI. The authors reported no difference at minimum 2-year follow-up in hip outcome score activities of daily living (HOS-ADL), percentage of patients demonstrating clinical improvement, and those requiring subsequent surgery. While PAO remains the optimal treatment for acetabular dysplasia, debate remains in the literature regarding the appropriate intervention for BHD with concomitant intra-articular pathology. In a recent study comparing dysplastic hips managed via PAO alone or arthroscopy with subsequent PAO, a statistically significant difference in mHHS, HOS,

JAYPEE BROTHERS

and international hip outcome tool (iHOT) scores was realised at 1 year [21]. Fujii et al [22] further reported on 121 hips having undergone a combined PAO and arthroscopy at the index procedure. Arthroscopic findings of exposed subchondral bone and full-thickness labral tears and pre- and post-operative joint incongruity were strongly correlated to OA progression with unsatisfactory clinical scores at a mean follow-up of 9.9 years.

FEMOROACETABULAR IMPINGEMENT

Femoroacetabular impingement can be found in a number of patterns: Cam, Pincer, and mixed Cam–Pincer type FAI. Other unusual sources of intra-articular impingement may also be found (psoas tendon or ligamentum teres), and more recently emphasis has also been placed on identification and treatment of extra-articular sources of symptomatic impingement.

Intra-articular femoroacetabular impingement

Classic FAI is an osseous pathomorphologic variant predisposing the joint to potentially symptomatic intra-articular pathology, specifically labral tears and chondral lesions that lead to early hip arthritis and need for THA [23]. In Cam-type FAI, impingement most commonly occurs with hip flexion and internal rotation when an aspherical portion of the femoral head enters the acetabulum causing increased shear forces to the acetabular chondrolabral margin (**Figures 2.1** and **2.2**) [24] The impingement often occurs at the anterolateral acetabulum and frequently spares the capsular margin of labrum until late in the disease process. Cam-type FAI has been shown to produce a characteristic chondral injury, hyaline cartilage delamination, at the area of impingement, which can adversely affect surgical treatment outcome and complicate surgical decision making.

Pincer-type FAI is an acetabular-based pathomorphology where the acetabular rim and labrum impact the femoral neck or head-neck junction (**Figure 2.3**). This impingement mechanism may lead to labral attenuation, gradual ossification, and over time, the potential for posterior joint damage (contrecoup injury pattern) due to shear forces as the hip levers at the anterior neck–rim contact [24]. Pincer-type FAI can arise from acetabular retroversion, focal or global acetabular overcoverage. Pincer-type FAI is often radiographically characterised by findings consistent with acetabular retroversion (crossover sign, a posterior wall sign, and an ischial spine sign) and acetabular overcoverage (LCEA >40°, negative

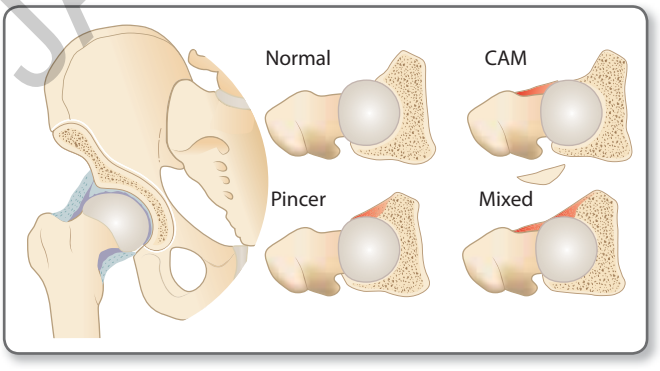

Figure 2.1 Bony morphology of femoroacetabular impingement.

JAYPEE BROTHERS

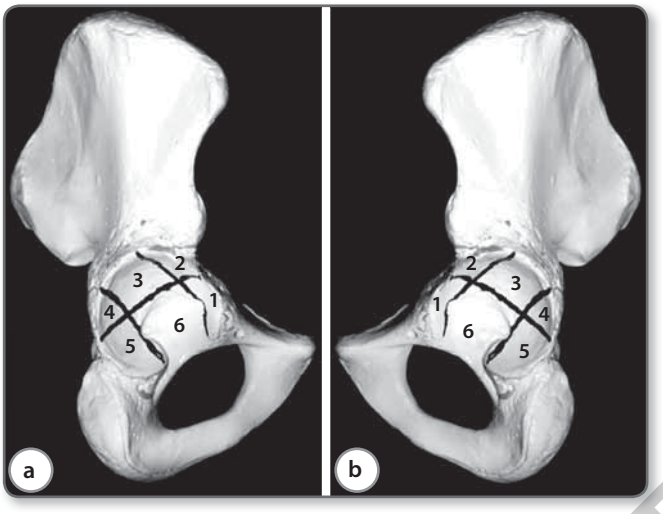

Figure 2.2 The right (a) and left (b) hemipelvis with an en face view of the acetabulum divided into 6 distinct zones.

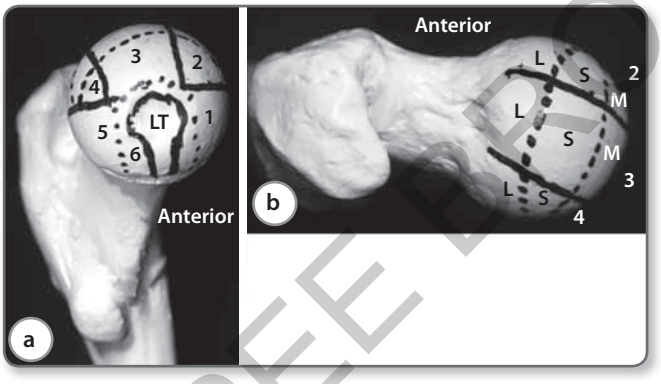

Figure 2.3 Proximal femur divided into 6 distinct zones around the projection of the acetabular fossa. LT, ligamentum teres; M, medial; S, superior; L, lateral.

JAYPEE BROTHERS

acetabular index, and acetabular protrusio). While coxa profunda (defined as medial acetabular fossa in contact or projecting medial to the ilioischial line) was often considered diagnostic of Pincer-type FAI, several recent studies show that it is both a common and non-specific finding [25,26].

Often hips have components of both Cam- and Pincer-type FAI, which has been termed Mixed-type FAI. The pincer component combined with the Cam lesion can lead to earlier impingement with intra-articular shear forces consistent with Cam FAI. This can lead to an array of chondrolabral injuries including labral tears, labral detachments, and acetabular delamination [23,24]. Typically, femoral articular cartilage is preserved until very late in the disease process.

Open treatment of FAI

The understanding of FAI evolved from treatment of dysplasia and a growing understanding of young hip pathology, including Perthes and slipped capital femoral epiphysis (SCFE) (retroversion, FAI). This understanding highlights the need for a surgical

intervention to address not only intra-articular lesions, but also correct the underlying deformity which was leading to pathologic impingement. Open surgical dislocation and osteochondroplasty (SDO) was initially proposed by Ganz et al [27], SDO revolutionised treatment and understanding of FAI, and has proved a workhorse for the treatment of FAI and its more dramatic causes including SCFE and Perthes. With the advent of minimally invasive techniques, SDO has fallen out of favour as the primary approach to FAI except in very select clinical scenarios.

Non-surgical treatment options for FAI

Not every patient diagnosed with FAI needs or desires surgical intervention. A number of authors have recommended and been successful with nonoperative treatment modalities such as rehabilitation and selective hip joint intra-articular injection. Tangtiphaiboontana and colleagues found 48% of adolescents with hip pain had prolonged symptom improvement after intra-articular corticosteroid injection of the hip. Interestingly, over 90% of patients without bony deformity had improvement and did not require surgery [28]. Kraeutler et al found in a group of patients with clinical and radiographic proof of intra-articular hip pathology underwent in-clinic hip injection with 98% of patients obtaining at least a 70% improvement in pain level [29]. This group showed that injections can be very valuable for both diagnosis and therapeutic reasons.

Physical therapy has been shown to be a valuable adjunct in the treatment of FAI. Hoit et al performed a systematic review of 124 patients from five studies on the efficacy of physical therapy in the treatment of FAI. They concluded that a supervised program focussing on active and core strengthening versus a passive program would be the best model for the non-operative treatment of FAI [30]. On a related note, Malloy found significant unilateral muscle atrophy on the CT scans of patients with unilateral symptomatic FAI. The authors concluded that the muscle atrophy could be addressed prior to or potentially in place of surgery to address the patients' muscular imbalances and deficiencies [31,32].

Labral refixation versus debridement

Larsen et al [33] noted good to excellent results in 68% of the focal debridement group and 92% of the refixation group at a mean 3.5-year follow-up. Despite reports to the contrary, the labrum does not appear to regenerate after excision and hips after excision have inferior results compared to hips that underwent labral repair or reconstruction.

Current trends in the treatment of FAI with labral tears has strongly favoured labral repair over debridement. In fact, some authors have begun to recommend labral reconstruction over repair as a primary treatment [34]. This recommendation has not been without controversy and debate [35].

Labral reconstruction

Labral reconstruction using allograft or autograft tissue, iliotibial band [36,37], allograft tendon/tissue, indirect head of rectus tendon [38,39], and even capsular advancement to the rim have all been described with varying degrees of clinical follow-up and success. From both a biomechanical and clinical perspective, best results at re-creating normal mechanics and preserving hip function and longevity are permitted by retaining as much labrum as possible and reconstructing the deficient labrum. Some authors have recommended either segmental [40] or circumferential reconstruction [41]. An attempt at

JAYPEE BROTHERS

gaining a general consensus on reconstruction technique, graft type, and outcomes have been attempted by a number of authors [42,43]. Circumferential intact labral tissue seems to give the best outcomes, however, this question needs to be clearly answered by future studies.

Chondral lesion patterns

Chondral lesions of the hip were historically graded using the Outerbridge Classification System borrowed from sports medicine for the grading of knee chondromalacia from 0-IV: 0 is normal cartilage, grade I is softening, grade II is superficial fraying, III is partial thickness loss, and grade IV is areas of full loss down to bone. Beck et al [24] proposed a now well-accepted grading scale for acetabular articular cartilage involvement: Beck score – 1, normal cartilage – 2, softening or malacia – 3, debonding or carpet lesions – 4, cleavage/flap lesions with free edge – 5, and full-thickness defect. The location of involvement is described using a clock face description with 3 O'clock always being anterior regardless of right or left hip. Lesions are described as from X to X O'clock and distance from the rim that the lesion extends. Additionally, Beck et al [24] classified labral involvement: Beck score – 1, normal labrum; – 2, degeneration, thinning or frayed labrum – 3, full-thickness tearing of labrum – 4 labral detachment – 5, labral ossification. These were used with the clock face to describe location and extent of labral lesions. An acetabular zone classification has been championed by Illizaliturri et al to improve the description and communication of these types of lesions. Based on location, the outcome of different treatment modalities can be evaluated as well [44].

With regards to predictive models of those patients at greatest risk of intra-articular chondral damage, Utsunomiya et al [45] evaluated patient-specific data of 2,396 hips having undergone arthroscopy. They found that chondral damage (Outerbridge III and IV) was more commonly present on the acetabulum as compared to the femoral head with older age identified as an independent risk factor. Male sex, increased body mass index (BMI), and increased alpha angle were found to be significantly associated with increased risk of chondral damage to the acetabulum. Decreased CEA and increased Tönnis angle were predictive of chondral damage to the femoral head. An additional multicentre cohort analysis of 802 patients attempted to determine the effect of hip morphology on acetabular chondral wear [46]. The authors reported significantly increased acetabular chondral debonding in patients with Cam (93%) and mixed (97%) impingement as compared to those with Pincer (75%) type pathology. Furthermore, superolateral chondral defects were more commonly identified in patients with Cam (90%) and mixed (91%) morphology as compared to Pincer (60%) impingement.

CHONDRAL TREATMENT OPTIONS

Debridement and microfracture

Unstable cartilage cannot heal autonomously and so careful cartilage probing and examination is required to locate these lesions. The goal of debridement of chondral lesions is to eliminate unstable cartilage that will progress to loose bodies or instability of adjacent cartilage while preserving stable cartilage. Using larger shavers and shavers of various angles avoids gouging the cartilage or clogging the shaver tip.

JAYPEEBROTHERS

The goal of microfracture in the treatment of cartilage lesions of the hip is to perforate the cortical bone at the base of the lesion to permit undifferentiated mesenchymal stem cells (MSCs) and growth factors to fill the defect with fibrocartilage, a reparative cartilage of inferior biomechanical quality to hyaline cartilage. Ideally, the lesion should be focal and contained so that the bleeding bone can form a chondrogenic clot and not larger than 4 cm^2 [47]. Additionally, there is some evidence that drilling causes less distortion and damage to the subchondral plate than microfracture with an awl. Specially developed arthroscopic drill bits and guides are now available to drill perpendicular to the bone.

One of the earliest studies on microfracture for acetabular high-grade cartilage lesions was published by Philippon et al [48], which demonstrated good filling of lesions by fibrocartilage but without clinical results. 11 out of 12 studies showed good results after microfracture of chondral lesions in 267 patients undergoing arthroscopy for FAI in a systematic review by MacDonald et al [49]. All publications used focal high-grade lesions as the indication for microfracture and limited weight-bearing after surgery for some period, usually 4–8 weeks. A study by Levinson and colleagues [50] showed the chondral flap associated with chondrolabral disruption had reasonable chondrocyte viability but the extracellular matrix was disorganised. The authors questioned the clinical efficacy of replacing these chondral flaps with fibrin glue sealant. Finally, O'Connor et al performed a systematic review on the outcomes of chondral joint preservation procedures about the hip. In their analysis, the authors found that microfracture was the most commonly used technique. Microfracture had an 89.6% success rate and PROs for all procedures demonstrated statistically significant increases post-operatively [51].

Resection and labral advancement

Some success has been achieved with resection and labral advancement of high-grade rim lesions and report favourable outcomes. The negative of this technique is the risk of iatrogenic acetabular dysplasia and need for resultant PAO. Peters et al could not determine difference in clinical and radiographic outcomes between microfracture, debridement, or resection/labral advancement for high grade rim lesions [52].

Biological treatments and technology

A number of treatments involve harnessing biological technology to encourage chondral healing in full-thickness chondral lesions. Most of these were first utilised in the knee before recently being borrowed for hip pathology and so most have limited data in the hip literature on outcomes.

Stem cells or MSCs augmentation can enhance the healing and quality of the reparative cartilage [53,54]. Bone marrow aspiration concentrate (BMAC) can be harvested and injected into the joint through a needle as an outpatient procedure 6 weeks after a microfracture treatment to augment the biologics of the microfracture healing process and quality of repair cartilage.

Autologous matrix-induced chondroplasty (AMIC) is a single surgery procedure that combines microfracture with application of a porous resorbable type I and III collagen matrix over the defect. This traps the microfracture-induced MSCs within the defect and provides a porous membrane to facilitate stable growth of a cartilage-like tissue. The membrane is held in place by creating a sharp border to the chondral defect and from

JAYPEE BROTHERS

the pressure of the femoral head; otherwise, the addition of fibrin glue can be helpful for membrane fixation.

Microfragmented adipose tissue transplantation (MATT) with or without microfracture has been suggested as an ideal treatment for delamination lesions [55]. The advantage of microfracture and MATT is that it requires only one surgical intervention and is readily available without pre-operative planning. Jannelli and Fontana [56] report that adipose tissue is chondrogenic, a source of large quantity MSCs comparable to bone marrow aspirate but less invasive and requires simpler preparation.

Matrix-induced autologous chondrocyte implantation (MACI) is a two-stage surgical procedure that first requires biopsy of chondrocytes from the hip or removal of unstable cartilage fragments at time of initial diagnostic scope and chondral debridement [56]. The chondrocytes are then cultured on a matrix that functions as a scaffold and then the matrix, or membrane, is implanted over the defect during a second surgery [55]. Protein and carbohydrate matrices and artificial polymers have all been proposed as the membrane of choice [56]. As confidence in imaging grows and biologic treatment becomes mainstream, one can imagine diagnosing a lesion on MRI and deciding to harvest cartilage from an unaffected joint such as the knee. 3-year follow-up data from Krueger has shown excellent improvement in outcome measures with two clinical failures in 32 study subjects when using traditional injectable autologous chondrocyte implantation (ACI) for full-thickness acetabular defects of >2 cm^2 [57].

Single-stage autologous matrix-enhanced chondrocyte transplantation (AMECT) is a novel technique that involves transplanting the excised cartilage from the femoroplasty into a femoral head or acetabular defect. The graft is mixed with whole blood, BioCartilage (Arthrex, Naples, Florida) and delivered to the chondral defect under dry arthroscopic conditions. The graft is held in place with fibrin glue [58].

Comparing chondral treatment results

There are limited studies in the literature comparing outcomes between treatments for chondral lesions in the hip. Domb et al [59] compared outcomes of FAI patients with chondral lesions treated with and without microfracture after a minimum follow-up period of 2 years. All patients significantly improved but no significant difference between groups was noted. Comparing 5-year results of microfracture versus AMIC treatments for full-thickness acetabular lesions, Fontana et al [60] reported that both did equally well at a year but while results deteriorated in the microfracture group, they were stable in the AMIC group over the following 4 years. Similarly, Fontana also noted improvement up to 3 years after AMIC for grade III and IV acetabular lesions in 201 hips with sustained 40-point improvement in HHS at a mean follow-up of 5 years [61]. When comparing AMIC to MACI, Fontana found similar results with medium-sized lesions but noted the benefit of one surgery with AMIC over the two-stage MACI.

Chondral treatment algorithm

Jannelli and Fontana [56] proposed a treatment algorithm based on their experience and current outcomes studies. They recommended debridement of partial thickness lesions, microfracture with near full chondral thickness lesions but small in diameter (<2 cm^2). MACI or autologous matrix-induced chondrogenesis (AMIC) was recommneded for

JAYPEE BROTHERS

full-thickness lesions >2 cm^2. MATT or microfracture with chondrolabral refixation and fibrin glue was suggested for delamination lesions. The advantage of microfracture, AMIC, and MATT is one surgical intervention while MACI requires harvesting chondrocytes and culturing them for a future reimplantation. Furthermore, Jannelli and Fontana [56] cautioned that addressing pathomorphology that caused the cartilage lesions, such as Cam lesions, was necessary for success. Finally, they discouraged chondral treatment in Tönnis grades II or greater due to high failure rates. Dallich and colleagues have also produced an excellent summary chart of the appropriate use of different articular cartilage modalities around the hip joint from multiple sources [62].

Future technology and advancements in chondral repair undoubtedly are on the horizon. Unfortunately, it will take years and large well-designed studies to know what patient and chondral lesion factors will lead to the optimal treatment and outcomes.

Capsular laxity, deficiency, repair, and reconstruction

While failure of early hip arthroscopy was often due to failure to treat the bony deformity of Cam lesions, over the last 15–20 years, knowledge of associated pathomorphology and arthroscopic techniques to address these pathologies has improved. A less common complication has become apparent with respect to hip arthroscopy; capsular instability. As larger bony deformities and labral reconstructions were undertaken, larger capsular portals were required. Interportal capsulotomy and later T-capsulotomy became the workhorses of hip arthroscopy, enabling the surgeon to debride larger Cam lesions and even reconstruct a labrum from gracilis graft. These larger portals were often re-approximated as an afterthought with several stitches that may or not heal completely. Reports of hip dislocations following hip arthroscopy when initially reported was dramatic but by many considered an anomaly in an otherwise minimally invasive surgical movement [63]. However, over time, it became clear that some patients did not improve with arthroscopy despite adequate treatment of labral and Cam pathology and a sense of instability was reported by patients.

Symptomatic instability as either primary or iatrogenic pathology subsequent to arthroscopic treatment of FAI has been described. Myers et al [64] examined the effects of sectioning capsule and labrum in cadavers. They demonstrated with biplane fluoroscopy that defects in the capsule alone and capsule and labrum together, but not labrum alone, lead to increased anteroposterior translation and external rotation in the native hip and are likely culprits in symptomatic hip instability. Attention to capsular closure as an important part of the procedure has been emphasised. In addition to symptoms of instability, it has been shown that there is a distinct pattern of labral and chondral pathology that is straight anterior or lateral with accompanying shallow width of acetabular articular cartilage injury. In addition to symptoms of instability, it has been shown that there is a distinct pattern of labral and chondral pathology that is straight anterior or lateral with accompanying shallow width of acetabular articular cartilage injury. Capsular plication has been suggested by numerous authors to combat iatrogenic or congenital hip joint laxity [65,66].

Prevention: Frank et al [67] noted improved outcomes in both final HOS and failure rate in a cohort of 32 patients treated with hip arthroscopy with complete repair of the T capsulotomy versus a similar cohort of 32 patients with closure of the T but not the interportal capsulotomy.

JAYPEE BROTHERS

Repair of capsule: A cadaveric study by Baha et al [68] indicated a near complete restoration of capsular kinematics when complete capsular closure is performed. Krautler et al [69] performed MRI follow-up on 49 hips undergoing arthroscopy for FAI, with 23 hips undergoing capsular repair. The authors found that by 24 weeks after surgery, 83% of the non-repaired capsules had closed and that repair of the capsule for small- to medium-sized interportal capsulotomies may not be necessary. Wylie et al [70] reported on 20 patients who were treated with arthroscopic capsular repair for iatrogenic instability after prior hip arthroscopy including two patients with a dislocation episode. 19 of the 20 patients had improved physical abilities and average HOS-sports improved from 36 to 88 at minimum 2-year follow-up. A more recent study from Philippon et al [71] indicated superior HOSs when the capsulotomy was closed when compared to a matched cohort of unrepaired capsules. Interestingly, there was no difference in the MCID mHHS between the two groups. Another study indicated that capsular closure made no difference in surgical outcomes at 3 years after surgery [72]. Finally, a randomised study by Economopoulos and colleagues [73] found superior PROs in the complete closure group when compared to isolated t-capsulotomy or interportal capsulotomy closure.

Clearly, capsular management with hip arthroscopy is an evolving topic. The current literature, however, has recently tilted in favour of capsular closure with the possible addition of plication in select patients. Whether capsulectomy is advantageous in inflammatory hip conditions, repair necessary in FAI surgery, and whether capsular plication results in improved clinical outcomes over repair in hips prone to instability have been discussed in recent reviews [74–76]. Further studies are needed with PROs at follow-up after these procedures to better understand the rates of complications and demonstrate the ability to optimise outcomes of hip arthroscopy while minimising stiffness and avoiding or resolving symptoms of instability.

EXTRA-ARTICULAR HIP IMPINGEMENT

While there has been much focus on identification and treatment of intra-articular FAI, there is a growing body of evidence describing extra-articular sources of impingement. Subspine impingement (SSI) involves the anterior–inferior iliac spine (AIIS) and proximal femoral neck while ischiofemoral impingement (IFI) involves the ischium and the lesser trochanter.

Anterior–inferior iliac spine impingement

The AIIS has been demonstrated to impinge against the distal femoral neck in certain hips leading to loss of hip flexion and internal rotation resulting in pain and subchondral cystic changes in the distal femoral neck. To further characterise and understand AIIS morphologic variants contributing to impingement, Hetsroni et al [77] evaluated 3D CT reconstructions of 53 hips with impingement. Based upon this study, they classified AIIS by whether there was a normal sulcus between the AIIS and the acetabular rim and whether the AIIS extended to or beyond the rim. Samim et al [78] additionally reported on MRI assessment of SSI with further evaluation of contributing morphologic features beyond the AIIS. Of the 62 patients included for analysis, 32% were identified as having SSI. Patients with SSI were more likely to possess a distal Cam defect, signs of impingement of the distal femoral neck, and superior capsular oedema.

JAYPEE BROTHERS

Resection of the AIIS prominence has been shown to improve hip flexion and decrease. A recent retrospective analysis of 10 patients treated with arthroscopic decompression of the AIIS with mean follow-up of 15 months demonstrated an 18° increase in hip flexion as well as a 34-point increase in the HHS [79]. An additional evaluation by Nwachukwu et al [80] reported on 33 females treated with arthroscopic decompression of the AIIS. The authors reported satisfactory clinical improvement in PROs at 1-year follow-up. Additionally, de Sa et al [81] performed a systematic review of extra-articular hip impingement with inclusion of 14 studies and 333 hips. With regards to arthroscopic management of SSI, the authors identified an 18.5° improvement in hip flexion ROM and visual analogue scale (VAS) pain scores as well as the mHHS.

Ischiofemoral impingement

Ischiofemoral impingement is a relatively uncommon diagnosis described as a symptomatic extra-articular impingement between the ischium and proximal femur (most commonly the lesser trochanter). The condition is associated with increased valgus and anteverted femoral morphology resulting in reduced femoral offset or ischiofemoral space (IFS). Impingement occurs with external rotation of the femur in extension resulting in compression of the soft tissue in the space between the lesser trochanter and ischium.

Hatem et al [82] reported on 2-year results in five hips having undergone endoscopic resection of the lesser trochanter. Return to sport averaged 4.4 months and significant improvement in HHS at final follow-up. Patients were treated with endoscopic resection of the lesser trochanter, which resulted in significant improvement HHS at 12 months follow-up. de Sa et al [81] further reported improvement of extra-articular IFI symptoms following open surgical management.

Iliopsoas pain and impingement

The iliopsoas is a powerful hip flexor that passes over the rim of the pelvis at the level of the anteromedial acetabulum with insertion to the lesser trochanter. Iliopsoas pathology including tendonitis, bursitis, labral impingement, and snapping is well described with several studies having evaluated outcomes following iliopsoas release in native hips.

In evaluation of 300 consecutive hip arthroscopies, Nelson and Keene [83] identified a 10% incidence of iliopsoas impingement (ISI) on the acetabular labrum. At 2-year follow-up, patients demonstrated significant improvement in the mHHS with 77% reporting good-to-excellent results. Furthermore, Adib et al performed a retrospective study review of 60 patients having developed post-arthroscopic iliopsoas tendinitis. 32 (53%) patients required iliopsoas tendon sheath injections while seven (12%) patients underwent revision arthroscopy [84]. In their systematic review of extra-articular hip pathology, de Sa et al [81] identified that 88% of patients reported good-to-excellent outcomes and significant improvements in clinical outcome scores following arthroscopic treatment of ISI.

However, the surgeon should understand that release of the iliopsoas tendon is not without consequence. Brandenburg et al [85] compared postoperative iliopsoas muscle volume and seated hip flexion strength in patients having undergone arthroscopic labral repair and iliopsoas tenotomy versus a controls group having undergone isolated arthroscopic labral repair. The authors reported that iliopsoas tenotomy was associated with a 25% volume loss and 19% decrease in seated hip flexion strength. Furthermore,

WYPEF BROTHERS

as an important hip stabiliser, Sansone et al [86] were concerned that arthroscopic release of the iliopsoas resulted in the occurrence of two iatrogenic hip dislocations in their series.

PAEDIATRIC HIP DISEASE

Legg–Calvé–Perthes disease

Legg–Calvé–Perthes (LCP) disease is caused by a vascular insult of the hip occurring in skeletally immature children aged 5–9 years old. It is not uncommon for young adults with sequelae of LCP to present with symptoms and radiographic findings consistent with both hip impingement and instability, making surgical decision-making challenging [87,88]. The efficacy of surgical treatment in the early stages of LCP remains a topic of debate. Historically, surgical management has focussed on containment of the femoral head within the acetabulum with the surgical hip dislocation technique expanding treatment options of the post-Perthes hip. This approach allows for femoral head reshaping and treatment of concomitant intra-articular hip pathology with several recent reports identifying improved hip biomechanics and patient outcomes. Modified approaches to surgical hip dislocation involving the development of an extended retinacular flap are being utilised to address complicated morphologic changes of the femoral head [89]. Collectively termed 'femoral head reduction,' these techniques offer the potential for substantial modification of post-Perthes femoral morphology. However, in evaluation of epiphysiodesis or isolated descent of the GT for the management of LCP, Haskel et al [90] demonstrated no difference in neck-shaft angle and abductor strength testing at 6 years post-operatively.

Hip arthroscopy has also been utilised to address chondrolabral pathology, loose bodies, and Cam lesions associated with LCP disease. However, much of LCP pathology is related to proximal femoral deformity associated with acetabular dysplasia. Therefore, further study is warranted to provide a more comprehensive understanding of the appropriate indications for arthroscopic management of LCP disease.

Although the literature consists of many case reports and series, there remains a need for long-term outcome studies with development of surgical algorithms to guide management of the complex deformities associated with LCP.

Slipped capital femoral epiphysis

The aetiology of SCFE is unknown but likely includes factors such as adolescent obesity, mechanical components, and endocrine disorders. SCFE usually occurs around 13 years of age for boys and 11 years of age for girls. A recent natural history review by Matthew and Larson [91] reported a 15–50% risk of avascular necrosis (AVN) following acute, unstable slips. They further identified a 5% risk of THA at 20 years with the history of AVN as the highest independent risk factor.

For the vast majority of acute SCFE in children, in situ pinning is regularly utilised but does not correct the deformity. Some evidence supports favourable outcomes with this approach but it remains difficult to predict which hips will become symptomatic. Although conventional wisdom has held that the majority of hips with mild-to-moderate deformity do well into young adulthood, more recent evidence suggests that even mild slips may lead to FAI, pain, loss of function, and early joint degeneration.

JAYPEE BROTHERS

Similar to LCP, surgical hip dislocation has proven valuable for addressing the morphologic abnormalities commonly encountered in more severe slips. For severe slip angles > 45° with an open proximal femoral physis, subcapital realignment via the modified Dunn procedure has proven safe and effective. However, there may be an increased risk of AVN following subcapital realignment in the setting of a closed physis. A recent report has further described improvement in head–neck offset in mostly mild to moderate slips managed arthroscopically [92]. All nine hips treated at a mean of 56 months following in situ pinning demonstrated acetabular cartilage or labral injury at the time of arthroscopy. All but one patient demonstrated improvement in HOS at a mean follow-up of 28.6 months.

In an effort to optimise hip mechanics and articular longevity, Schoenecker et al [93] formulated a surgical algorithm for the varied pathomorphology seen with stable slips. The algorithm considers the pattern of slip to aid in appropriate determination of surgical indications.

IMPLICATIONS FOR EVENTUAL TOTAL HIP ARTHROPLASTY

Not only do some hip conditions have abnormal anatomy to start with, hip preservation sometimes adds deformity or complexity to the soft-tissues and bony structures that further complicate eventual THA. The surgeon may consider the likelihood of hip preservation success weighed against the risk of complicating THA in the future particularly with proximal femoral osteotomies that change the anatomy of the intertrochanteric/subtrochanteric region required for femoral stem broaching and bony fixation. Several groups have found increased rates of blood loss and transfusions, overall rate of revision predominately for aseptic loosening, as well as greater use of modular revision type implants especially on the femoral side in young patients with prior hip preservation surgery undergoing THA. Salvo and colleagues, in a systematic review, found no differences in short- and mid-term outcomes between patients that had prior hip arthroscopy undergoing hip arthroplasty [94]. In another systematic review, this same conclusion was reached by Rosinsky [95]. They, however, could not conclude whether complications were increased in the post-hip arthroscopy cohort compared to the primary arthroplasty group. Finally, Dwyer looked at 20 years follow-up on hip arthroscopy patients treated for labrum tears and chondral flaps. There was a 41% conversion rate to hip arthroplasty in the cohort. Factors that predicted future arthroplasty were age >40 years old and the presence of both femoral and acetabular chondral lesions [96].

On the other hand, it appears that improving acetabular coverage through PAO does not negatively affect future THA; Amanatullah et al [97] demonstrated no difference in complications, revision rates and HHS for THAs in hips that undergone previous PAO compared to a matched cohort of THAs that had not undergone prior PAO.

CONCLUSION

It is now recognised that a variety of hip pathomorphological conditions such as acetabular dysplasia and alteration of normal femoral and acetabular anatomy leading to development of FAI can produce pain and premature OA in young adult and adolescent hips. It is also recognised that the heterogeneous nature of the anatomy and clinical

JAYPEE BROTHERS

presentation in these patients create substantial difficulty in selecting the correct diagnosis and appropriate treatment. Expansion of knowledge in the areas of disease pathogenesis, disease staging, and surgical treatment has improved surgical outcomes. The diverse nature of hip pathomorphology also complicates design of high-level clinical studies to investigate outcomes. Current literature on hip preservation treatment is most often a small series of variable treatment methods for a spectrum of pathology with intermediate-term outcomes at best. The rapidly expanding field of hip preservation surgery is benefiting from higher-level studies examining the clinical outcomes and basic science in the treatment of hip pathology. Longer term outcomes and the development of 'best practices' will help to standardise the treatment options in the field of hip preservation. Only with this, we will be able to predict outcomes and understand the long-term impact of various hip preservation surgeries on hip joint survivorship.

ACKNOWLEDGEMENTS

The authors would like to thank Lucas A Anderson MD, Frank R Avilucea MD, Christopher E Pelt MD, Jill A Erickson MD, and Christopher L Peters MD for their substantial past contributions to this chapter.

REFERENCES

1. Tannast M, Hanke MS, Zheng G, Steppacher SD, Siebenrock KA. What are the radiographic reference values for acetabular under- and overcoverage? Clin Orthop Relat Res 2015; 473:1234–1246.
2. Parry JA, Swann RP, Erickson JA, et al. Midterm Outcomes of Reverse (Anteverting) Periacetabular Osteotomy in Patients with Hip Impingement Secondary to Acetabular Retroversion. Am J Sports Med 2016; 44:672–676.
3. Heyworth BE, Novais EN, Murray K, et al. Return to play after periacetabular osteotomy for treatment of acetabular dysplasia in adolescent and young adult athletes. Am J Sports Med 2016; 44:1573–1581.
4. Abraham CL, Knight SJ, Peters CL, Weiss JA, Anderson AE. Patient-specific chondrolabral contact mechanics in patients with acetabular dysplasia following treatment with peri-acetabular osteotomy. Osteoarthritis Cartilage 2017; 25:676–684.
5. Knight SJ, Abraham CL, Peters CL, Weiss JA, Anderson AE. Changes in chondrolabral mechanics, coverage, and congruency following peri-acetabular osteotomy for treatment of acetabular retroversion: A patient-specific finite element study. J Orthop Res 2017; 35:2567–2576.
6. Troelsen A, Elmengaard B, Soballe K. Medium-term outcome of periacetabular osteotomy and predictors of conversion to total hip replacement. J Bone Joint Surg Am 2009; 91:2169–2179.
7. Steppacher SD, Tannast M, Ganz R, Siebenrock KA. Mean 20-year follow-up of Bernese periacetabular osteotomy. Clin Orthop Relat Res 2008; 466:1633–1644.
8. Cunningham T, Jessel R, Zurakowski D, Millis MB, Kim YJ. Delayed gadolinium-enhanced magnetic resonance imaging of cartilage to predict early failure of Bernese periacetabular osteotomy for hip dysplasia. J Bone Joint Surg Am 2006; 88:1540–1548.
9. Lerch TD, Steppacher SD, Liechti EF, Tannast M, Siebenrock KA. One-third of Hips After Periacetabular Osteotomy Survive 30 Years with Good Clinical Results, No Progression of Arthritis, or Conversion to THA. Clin Orthop Relat Res 2017; 475:1154–1168.
10. Wells J, Nepple JJ, Crook K, et al. Femoral Morphology in the Dysplastic Hip: Three-dimensional Characterizations with CT. Clin Orthop Relat Res 2017; 475:1045–1054.
11. Redmond JM, Gupta A, Stake CE, Domb BG. The Prevalence of Hip Labral and Chondral Lesions Identified by Method of Detection During Periacetabular Osteotomy: Arthroscopy Versus Arthrotomy. Arthroscopy 2014; 30:382–388.
12. Ginnetti JG, Pelt CE, Erickson JA, Van Dine C, Peters CL. Prevalence and treatment of intra-articular pathology recognized at the time of periacetabular osteotomy for the dysplastic hip. Clin Orthop Relat Res 2013; 471:498–503.

JAYPEE BROTHERS

Recent Advances in Orthopaedics

4

Recent Advances in Orthopaedics 4 is intended to keep the busy "orthopaedic surgeon" in training and in practice up-to-date with the recent trends and the best practices in the field. The theme is focussed on "What is new in…"

Each chapter reviews the recent literature on changes in practice and in emerging therapies and technologies for each specialty area within orthopaedics including:

- Coronavirus disease 2019 (COVID-19) and orthopaedic surgery
- Foot and ankle surgery
- Hand and wrist surgery
- Hip joint preservation surgery
- Orthopaedic oncology
- Total hip arthroplasty
- Total knee arthroplasty
- Revision total joint arthroplasty
- Sports medicine
- Shoulder and elbow surgery
- Spine surgery
- Trauma surgery
- Robotic knee surgery

JP medical publishers

www.jpmedpub.com

ISBN 978-1-78779-174-9

9 781787 791749