Key Clinical Topics in Paediatric Surgery

SECOND EDITION

Edited by
Max Pachl • Oliver Gee • Ruth Wragg



Contents

Preface v
Contributors xi
Acknowledgements xvii

Topics

1 Abdominal and thoracic trauma 1
2 Achalasia 7
3 Acute scrotum 10
4 Anorectal malformation in females 14
5 Anorectal malformation in males 18
6 Antenatal hydronephrosis 21
7 Appendicitis 25
8 Balanitis xerotica obliterans 28
9 Biliary atresia 31
10 Bladder dysfunction 35
11 Branchial remnants 39
12 Central venous access techniques 42
13 Chest wall deformities 45
14 Child protection 48
15 Choledochal malformation 53
16 Cholelithiasis 56
17 Chronic abdominal pain 60
18 Chylothorax 63
19 Cloaca 65
20 Colonic atresia 69
21 Congenital diaphragmatic hernia 72
22 Congenital lung malformations 76
23 Consent in paediatric surgery 80

24	Constipation and faecal incontinence	83
25	Crohn's disease	89
26	Cystic hygroma	93
27	Diabetes mellitus	96
28	Disorders/Differences in sex development 1	100
29	Disorders/Differences in sex development 2	104
30	Duodenal atresia	108
31	Duplications of the urological system	111
32	Empyema	114
33	Endocrine conditions presenting to paediatric surgery	117
34	Exomphalos	121
35	Exstrophy-epispadias complex	125
36	Femoral hernia	131
37	Gastric and oesophageal foreign bodies	134
38	Gastric volvulus	137
39	Gastrointestinal bleeding	140
40	Gastro-oesophageal reflux disease	144
41	Gastroschisis	148
42	Germ cell tumours	151
43	Growth disorders	156
44	Haematological malignant disease	159
45	Haematuria	164
46	Head trauma	167
47	Hepatoblastoma	170
48	Hirschsprung disease	174
49	Hydrocele	177
50	Hyperhidrosis	180
51	Hypospadias – distal	182
52	Hypospadias – proximal	186
53	Inguinal hernia	190

54	Inhaled foreign body	193
55	Intussusception	195
56	Long segment Hirschsprung disease	199
57	Lymphadenopathy	201
58	Malrotation	204
59	Management of the wetting child	208
60	Meatal stenosis	211
61	Meckel diverticulum	213
62	Meconium ileus	215
63	Mediastinal masses	218
64	Minimal access surgery in neonates	221
65	Necrotising enterocolitis	226
66	Neuroblastoma	231
67	Oesophageal atresia and tracheo-oesophageal fistula	236
68	Oesophageal atresia – long gap	241
69	Osteosarcoma	245
70	Paediatric anaesthesia	248
71	Paediatric bariatric surgery	251
72	Paediatric breast disease	255
73	Paediatric cardiac surgery	259
74	Paediatric gynaecology	262
75	Paediatric neurosurgery	265
76	Paediatric orthopaedic surgery	268
77	Paediatric otorhinolaryngology	273
78	Paediatric plastic surgery	278
79	Paediatric transplantation	282
80	Pancreatitis	287
81	Pelviureteric junction obstruction	290
82	Perianal disease and anal laceration	294
83	Posterior urethral valves	296

84	Pyloric atresia	300
85	Pyloric stenosis	303
86	Rectal prolapse	306
87	Renal failure	308
88	Sacrococcygeal teratoma	313
89	Salivary gland lesions	317
90	Short bowel syndrome and intestinal failure	320
91	Skin lesions	325
92	Small bowel atresia	328
93	Small bowel duplications	331
94	Soft tissue tumours	334
95	Spleen disorders	337
96	Thyroid and parathyroid glands	342
97	Thyroglossal cyst	346
98	Tracheal anomalies	349
99	Ulcerative colitis	353
100	Umbilical and supraumbilical disease	356
101	Undescended testis	360
102	Urethral anomalies	363
103	Urinary tract infection	367
104	Urolithiasis	370
105	Varicocele	373
106	Vascular anomalies in paediatrics	376
107	Vesicoureteric junction obstruction	380
108	Vesicoureteral reflux	383
109	Wilms' tumour	386

Index 389

Anorectal malformation in females

Jonathan Sutcliffe, Kelly Hoffmann

Learning outcomes

- To know how to assess a female neonate with an anorectal malformation (ARM)
- To be aware of when and how to form a colostomy
- To understand the principles of definitive surgery

Overview

Anorectal malformations in females should be recognised in the neonatal period and accurately characterised. Rectoperineal fistulae and rectovestibular fistulae are common in comparison to cloacae. Associated abnormalities, typically from the VACTERL association, are frequently seen.

Clinical assessment of the neonate will usually determine if a temporary stoma is required. If so, definitive surgery is performed during the first few months of life before closing the stoma. The approach is through a posterior midline approach, the posterior sagittal anorectoplasty (PSARP). Long-term outcome can be optimised with careful management of functional sequelae.

Epidemiology and aetiology

The overall incidence of ARM is approximately 1 in 4,000, with cloacae being seen in 1 in 35,000. Types of defect seen in a female are shown in **Figure 1**. The aetiology remains poorly understood but is the focus of ongoing work.

Clinical features

An absent or abnormal anus should be identified clinically during neonatal assessment. However, some patients have a fistula that allows meconium to be passed into the nappy, obscuring the view. This may lead an unsuspecting clinician to miss

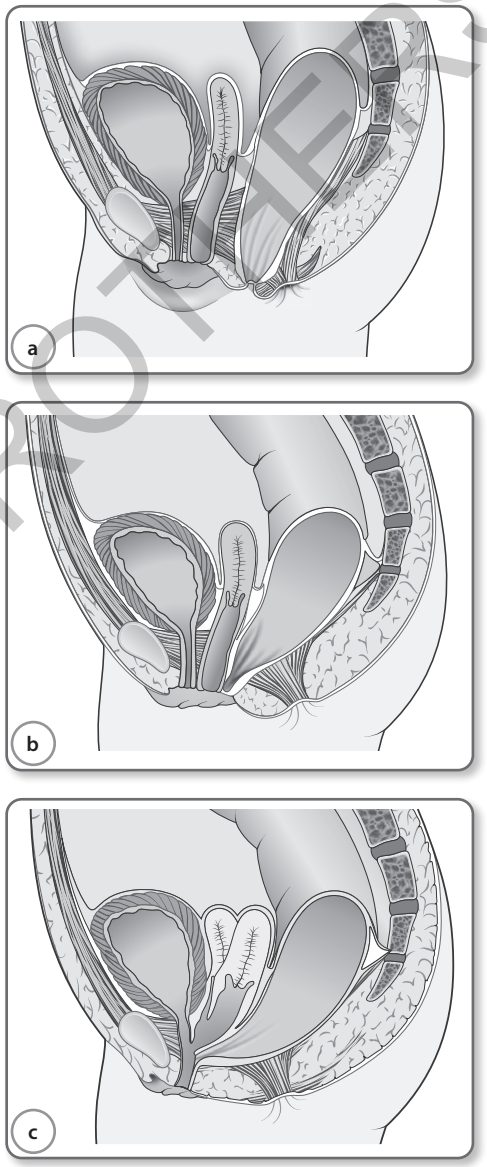

Figure 1 Female ARM Defects (a) Rectoperineal (b) Rectovestibular and (c) Cloacal
Reprinted from Chapter 4 – Female defects. In: Peña A. Atlas of surgical management of anorectal malformations, Springer Verlag: New York, 1989. With kind permission of Springer Science+Business Media.

JAYPEE BROTHERS

the diagnosis, a situation that remains surprisingly common.

There is a spectrum of abnormalities; a perineal fistula is usually easily differentiated from a vestibular fistula, which is hidden in the posterior wall of the vestibule. A small single orifice in the perineum suggests a cloaca.

Associated abnormalities usually fall within the VACTERL association and include *V*ertebral (often dysraphism or sacral abnormalities), *A*norectal, *C*ardiac (septal defects), *T*racheo-o*e*sophageal (OA-TOF), *R*enal (e.g. vesicoureteric reflux or bladder dysfunction) and *L*imb abnormalities (e.g. radial limb deformities). Gynaecological abnormalities may also be found in any female with ARM, most commonly those with cloacae.

Investigations

Careful clinical assessment of the perineum is usually sufficient to determine if a stoma will be required and begin to characterise the ARM (see below). In a newborn, placement of a nasogastric tube excludes oesophageal atresia, and spinal X-ray and ultrasound scanning (USS), echocardiography and renal tract USS are required to exclude associated abnormalities. These abnormalities are seen most frequently with more severe ARMs.

Parents will benefit from having a realistic expectation of outcome from early on. The 'height' of the ARM, the presence of spinal cord defects and quality of gluteal musculature all inform prognosis. A poorly developed sacrum may also infer poor innervation, poor sphincter function and therefore poor outcome. Anteroposterior and lateral sacral films allow the length of the sacrum in comparison to that of the pelvis to be calculated ('sacral ratio') (**Figure 2**), although the optimal age for assessment is undefined. If the ratio is <0.4, voluntary continence is unusual, but social continence can be achieved with a bowel management regimen, often with washouts. Conversely, in patients with a good ratio, a favourable outcome may be predicted. Information on the quality of the sacrum can also be obtained from a magnetic resonance imaging (MRI), if one has been done for any other reason.

Differential diagnosis

The most common mistake is to fail to recognise the abnormality at all, usually because meconium is not adequately cleaned from the perineum in the neonatal period. Rectoperineal fistulae are incompletely surrounded by sphincteric muscle and lie anteriorly on the perineum. These may result in incontinence or severe constipation if

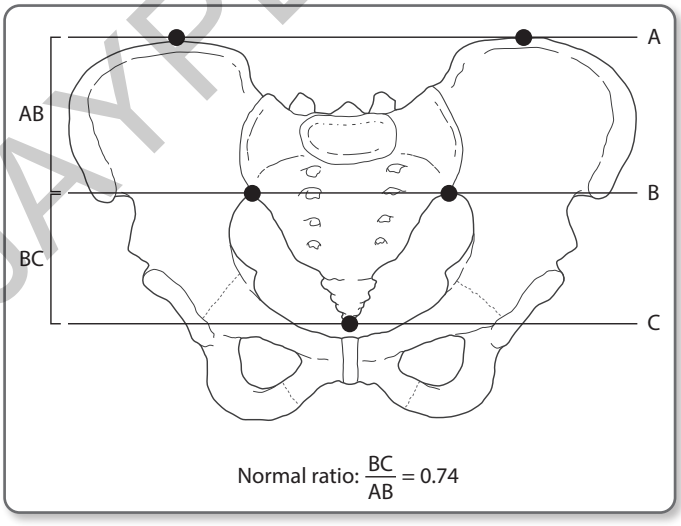

Figure 2 Landmarks used to determine the sacral ratio.

JAYPEE BROTHERS

uncorrected. It is important to differentiate this from an anterior anus, which is also positioned anteriorly but is completely within the sphincter complex and unlikely to lead to symptoms. Examination under anaesthesia, with stimulation of the sphincter complex, may be required. Rectovestibular fistulae open just inside the introitus, the vestibule. Cloacal abnormalities are defects in which the anorectum, genital and urinary tract all open into a single, common channel. The term 'rectovaginal fistula' implies the opening lies above the hymen. Many of these defects will have an unrecognised abnormal urethral opening and are therefore actually cloacae. This is more than semantics as potentially significant urogenital abnormalities may require correction.

Anal or rectal stenosis can exist with a normally placed anus, and hence be 'missed'. As well as leading to significant clinical symptoms, delay in diagnosis must be avoided given the association with the presence of a presacral mass (potentially a teratoma) and an abnormal sacrum as part of the Currarino triad. When symptoms of 'ribbon-like stool' are elicited in a baby presenting with constipation, calibration with Hagar dilators must be considered.

Treatment

In the neonatal period, a decision must be made about the need for a colostomy; the purpose of a colostomy is to divert the faecal stream if further investigations are required, the patient has other anomalies that take immediate precedence, or there is some technical advantage to delay surgical correction. Cloacal defects require cover with a stoma, whilst the practice varies for other fistulae; in some centres, a primary pull through is performed either as a neonate, or after a few weeks of being dilated to allow decompression and growth. In other centres, it may be felt that a staged approach with placement of a stoma in the neonatal phase is associated with better long-term outcomes. Both approaches are acceptable in experienced hands.

Formation of a colostomy for an ARM involves a left lower quadrant incision and identification of the most proximal loop of sigmoid colon. The bowel is frequently distended, limiting vision, so particular care is needed to make sure that the proximal end is identified, and the distal limb thoroughly washed out. The colostomy is brought out at the lateral end of the wound and a mucous fistula at the medial end of the incision, just far enough away to allow placement of a stoma bag over the colostomy alone. This prevents spill-over of effluent into the distal limb. The 'divided descending colostomy' allows the neonate to decompress, has a low chance of stomal prolapse (the proximal limb is fixed to the retroperitoneum), gives access to the distal limb for washouts and leaves sufficient downstream bowel for a future pull through.

The principle of definitive repair in girls is to mobilise the anorectum or fistula into the sphincteric muscle through a posterior sagittal (PSARP) incision, as first described by Peña. Since perineal innervation and musculature are paired, a midline approach minimises iatrogenic injury whilst providing excellent exposure. Parasagittal fibres can be seen running just under the perineal skin (probably representing external sphincter) and 'muscle complex' running in a perpendicular direction up to the levator. Accurate placement of the hindgut within these structures, likely including the deeper structures, will give the best chance of a good functional outcome. Additional considerations in a rectovestibular fistula or cloaca are the need for meticulous dissection of the anorectum or fistula from the back of the vagina (the plane is often so thin that it is considered as a common wall) and creation of an adequate perineal body. The operative repair of cloaca may be complex and management requires attention to a number of different systems in the neonatal period, during definitive repair and during long-term follow-up. Treatment of this rare condition is best undertaken by teams of experienced clinicians.

Following repair in most centres, daily anal dilatation is performed to prevent cicatrisation of the neoanus, something many parents struggle with and therefore require support. Once an adequate size is reached, the colostomy is closed, and dilatations

JAYPEE BROTHERS

reduced before being stopped. Central to good long-term outcome is close follow-up and early management of sequelae, which may include constipation, incontinence and urogenital symptoms. Work to further define patient- and parent-important priorities will drive metric setting and research, such as the role of post-operative dilatation and the application of new technologies in evaluation and definitive repair.

Further readings

Haider N, Fisher R. Mortality and morbidity associated with late diagnosis of anorectal malformations in children. Surgeon 2007; 5:327–330.

Levitt MA, Bischoff A, Breech L, Peña A. Rectovestibular fistula—rarely recognized associated gynecologic anomalies. J Pediatr Surg 2009; 44:1261–1267.

Pena A, Devries PA. Posterior sagittal anorectoplasty: important technical considerations and new applications. J Pediatr Surg 1982; 17:796–811.

Versteegh HP, Gardner DS, Scriven L, et al. Reconsidering diagnosis, treatment, and postoperative care in children with cloacal malformations. J Pediatr Adolesc Gynecol 2021; 34:773–779.

Related topics of interest

- Anorectal malformation in males (p. 18)
- Cloaca (p. 65)

JAYPEE BROTHERS

Key Clinical Topics in Paediatric Surgery

SECOND EDITION

Key Clinical Topics in Paediatric Surgery is an indispensable and practical guide for clinical practice and examination revision. Edited by experienced surgeons and with contributions from specialists who have recognised expertise in their field, this book provides an authoritative and up-to-date guide to common paediatric surgical conditions.

Presented in a concise format that enables rapid access to core information, **Key Clinical Topics in Paediatric Surgery** delivers the essential clinical knowledge and practical skills for paediatric surgeons in training.

- Over 100 topics presented in alphabetical order, from abdominal trauma to Wilms' tumour
- Succinct coverage of diagnosis, surgical techniques and management
- Ideal quick reference for day-to-day practice and effective tool for examination revision

JP medical publishers

www.jpmedpub.com

ISBN 978-1-78779-176-3