Recent Advances in Histopathology



Edited by
Fred T Bosman
Ivan Damjanov

Contents

Preface v
Editorial board vii
List of abbreviations ix

Chapter 1 Pathobiology, morphology and clinical significance of minimally invasive thyroid neoplasms 1
Paula Soares, José Manuel Cameselle-Teijeiro, Elisabete Teixeira, Antónia Póvoa, João Magalhães, Isabel Amendoeira, Manuel Sobrinho-Simões

Chapter 2 Drug-related changes in gastrointestinal biopsies 21
Hanna Henzinger, Iva Brcic

Chapter 3 Eosinophilic diseases of the gastrointestinal tract 67
Robert M Genta, Shelby D Melton, Kevin O Turner

Chapter 4 Mesonephric-like adenocarcinoma of the gynaecologic tract 93
Ridin Balakrishnan, Ricardo R Lastra

Chapter 5 Soft-tissue tumours with an epithelioid morphology – diagnostic challenges 107
Kyle D Perry, Anamarija M Perry

Chapter 6 Molecular biology of gliomas 123
Peter P Molnar

Chapter 7 Chromatin regulatory complexes-associated cancers: The emerging landscapes of switch/sucrose non-fermenting (complex)-deficient and NUTM1-rearranged malignancies 143
Abbas Agaimy

Chapter 8 Papillary renal cell carcinoma: A review of the past, present and future 161
Oluwayomi Oyedeji, Sean R Williamson, Khaleel I Al-Obaidy

Chapter 9 Breast implant related lymphomas 173
Mario L Marques-Piubelli, Sofia A Garces, Roberto N Miranda

Chapter 10 T- and NK-cell lymphomas of gastrointestinal tract: A practical approach 189
Anamarija M Perry

Index 205

Chapter 4

Mesonephric-like adenocarcinoma of the gynaecologic tract

Ridin Balakrishnan, Ricardo R Lastra

INTRODUCTION

Mesonephric remnants are relics of the embryonic mesonephric (Wolffian) ducts and can occur anywhere along the path where mesonephric duct regress in biologic females. They are generally found in the mesosalpinx or the lateral aspect of the cervix but can rarely be present in the lateral wall of the vagina and uterine corpus. Mesonephric carcinomas are rare tumours that arise from these mesonephric remnants in the uterine cervix [1]. Within the last few years, tumours with mesonephric-like morphology and immunohistochemical profile have been described in sites in which mesonephric remnants are not usually expected, particularly the uterine corpus and the ovaries. In the seminal paper by McFarland et al in 2015, the authors reported a series of uterine and ovarian adenocarcinomas with distinct morphological and immunophenotypic profile, resembling mesonephric carcinomas [2]. The ovarian cases demonstrated foci of endometriosis in the same ovary. In all uterine cases, none involved the myometrium without predominant involvement of the endometrium. Notably, the authors did not identify any benign mesonephric remnants in association with the uterine tumours or in the cervix [2]. Given the uncertainty of the origin of these tumours at that time (i.e. did these represent mesonephric carcinomas arising in unusual location or variations of Müllerian-derived carcinomas), the authors recommended that they are termed "mesonephric-like" adenocarcinomas until their histogenesis was firmly established.

Although recent molecular data supports the notion that these tumours are, indeed, of Müllerian origin, mesonephric-like adenocarcinoma (MLA) retained their initial descriptive name because of the morphological, immunophenotypic, and molecular overlap with classic mesonephric carcinomas [1,3,4]. The morphologic spectrum and scarcity of mesonephric carcinomas and MLA tend to cause substantial problems in their recognition and diagnosis. However, the aggressive nature of these deceptively low-grade appearing lesions has since been well established, with the majority presenting at advanced stage and with distant metastases [4]. Hence, the importance of their recognition

Ridin Balakrishnan MD, Department of Pathology, LSU Health Center, New Orleans, Louisiana
E-mail: ridin.balakrishnan@gmail.com

Ricardo R Lastra MD, Department of Pathology, University of Chicago Medicine, Chicago, Illinois
E-mail: ricardo.lastra@bsd.uchicago.edu

JAYPEE BROTHERS

and proper diagnosis has become evident, resulting in its inclusion as a new entity in the latest 2020 WHO Classification of Female Genital Tumors [5].

EPIDEMIOLOGY

Mesonephric-like adenocarcinomas are rare tumours with an incidence of approximately 1% amongst all endometrial carcinomas [6,7]. In one comprehensive study, the mean age of diagnosis of endometrial MLA was 60 years (median: 61 years, range from 28 to 91 years) with the most common presenting symptom being vaginal bleeding, followed by post-menopausal bleeding and abnormal uterine bleeding [4]. Patients with MLA of the ovary most commonly present with pelvic pain, post-menopausal/abnormal uterine bleeding and/or abdominal distension and bloating [4].

PATHOGENESIS

The cell of origin in MLA has been a subject of debate for several years. In all uterine cases, including those in the seminal description by McFarland et al, tumours arose from the endometrium rather than the myometrium; in addition, a majority of the ovarian MLA were associated with endometriosis [2]. Direct transition between ovarian MLA and concomitant endometriosis has been reported [8]. An extensive literature review of MLA by Deolet et al in 2021 showed that some of the tumours were associated with underlying Müllerian-derived processes, including adenomyosis, endometriosis, atypical hyperplasia of the endometrium, serous borderline tumours, serous cystadenoma, borderline endometrioid adenofibroma, low-grade endometrioid endometrial carcinoma, and low-grade serous ovarian carcinoma [9]. These point favourably to the notion that MLAs do not arise from mesonephric remnants, but perhaps rather from Müllerian structures differentiating along a mesonephric pathway [2]. Attempts to differentiate mesonephric carcinomas and MLA based on proteomic analysis have shown no difference, and various studies have shown clonality between the background Müllerian-derived lesions and concomitant MLA present within the same case (see Molecular Findings) [10–13].

GROSS FINDINGS

In the original series, when gross findings were available, the ovarian MLA ranged from 4 to 32 cm, with a predominantly solid and cystic, yellow-tan or gray-white cut surface [2]. In other studies, ovarian MLA ranged from 7 to 15 cm with solid and cystic gross appearance. Papillary excrescences, fleshy and gelatinous cut-surfaces have also been described **(Figure 4.1)** [9,11]. Gross findings of uterine MLA are not specifically mentioned in the literature.

HISTOLOGIC FEATURES

There is significant overlap in morphology between MLA and conventional mesonephric carcinomas. A variety of growth patterns are typically present, including glandular, tubular, solid, slit-like, sex-cord like, trabecular, retiform, sieve-like, glomeruloid, spindle-cell, and papillary [2,14]. The classic architecture is usually a tubular growth pattern containing

JAYPEE BROTHERS

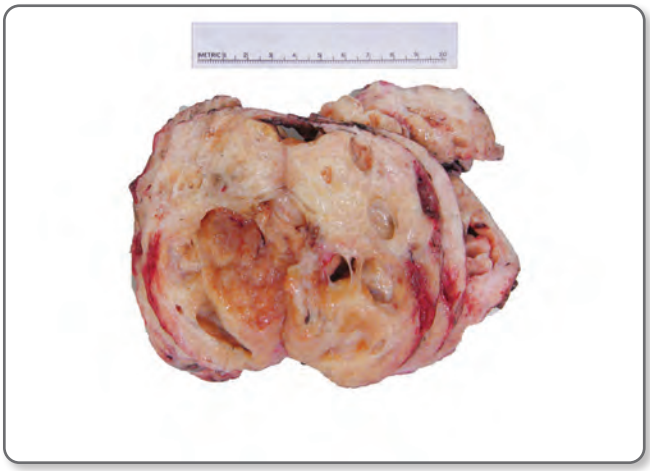

Figure 4.1 Ovarian MLA demonstrating a yellow-tan, solid and cystic mass with focal papillary excrescences involving the lining of the cystic spaces.

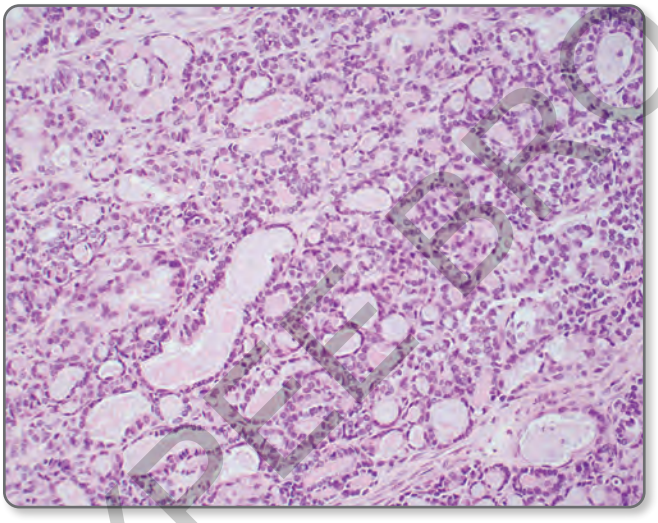

Figure 4.2 Tubular growth pattern with intraluminal eosinophilic colloid-like material (H&E, 200×).

eosinophilic colloid-like material in the lumen **(Figure 4.2)**, although this can be focal or absent. The neoplastic cells typically show moderate nuclear atypia **(Figure 4.3)** with nuclear overlapping, nuclear clearing, nuclear membrane angulations, nuclear grooves, and small nucleoli, often reminiscent of the classic nuclear features seen in papillary thyroid carcinoma **(Figure 4.4)** [2]. The cytoplasm is generally scant and in some solid areas, a spindled morphology can be seen [2]. No mucinous, ciliated, or squamous differentiation or metaplasia should be present, and no identifiable mesonephric remnants should be identified; if either of these features is present, the possibility of an unusual endometrioid carcinoma or a true mesonephric carcinoma, respectively, should be strongly considered **(Figure 4.5)** [15]. The morphologic spectrum of MLA is further highlighted in **Figure 4.6**. There are no reported differences in morphologies between ovarian and endometrial MLA [3].

JAYPEE BROTHERS

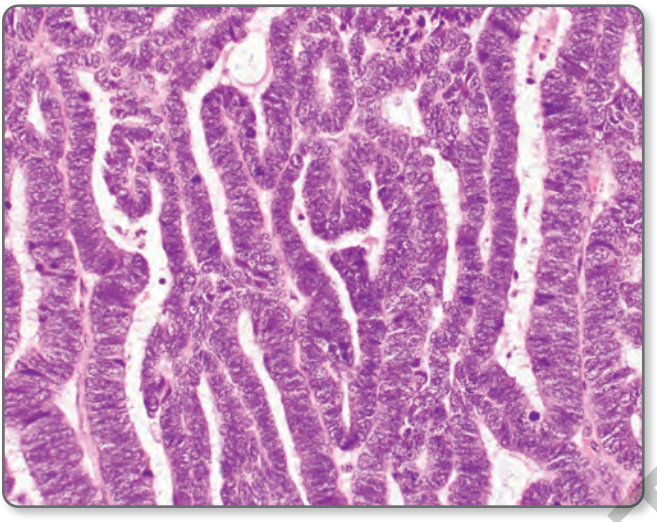

Figure 4.3 Moderate nuclear atypia with nuclear overlapping and conspicuous mitotic activity (H&E, 400×).

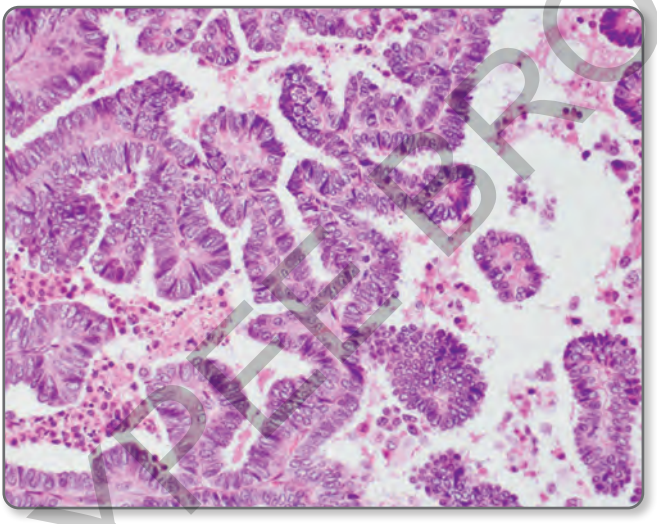

Figure 4.4 MLA demonstrating nuclear clearing, nuclear overlapping, nuclear grooves, and small nucleoli, reminiscent of the nuclear features of papillary thyroid carcinoma (H&E, 400×).

JAYPEE BROTHERS

IMMUNOHISTOCHEMISTRY

The typical immunohistochemical profile for MLA is as follows **(Figure 4.7)** [15].

- *PAX-8*: Positive; nuclear
- *GATA-3 and TTF-1*: Variably positive; nuclear
- *CD10*: Luminal staining
- *Calretinin*: Focal staining; nuclear and cytoplasmic
- *Oestrogen receptors (OR/ER) and progesterone receptors (PR)*: Negative

It must be noted that focal/weak positivity for ER can be seen, as shown in multiple studies, which does not preclude a diagnosis of MLA, with PR being a more reliably

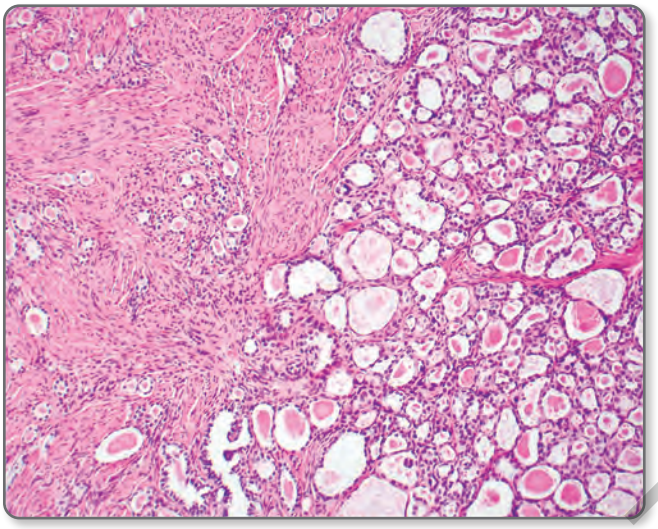

Figure 4.5 The presence of mesonephric hyperplasia (top left) adjacent to a carcinoma with mesonephric features (right) provides strong evidence for a diagnosis of cervical mesonephric carcinoma over MLA (H&E, 200×).

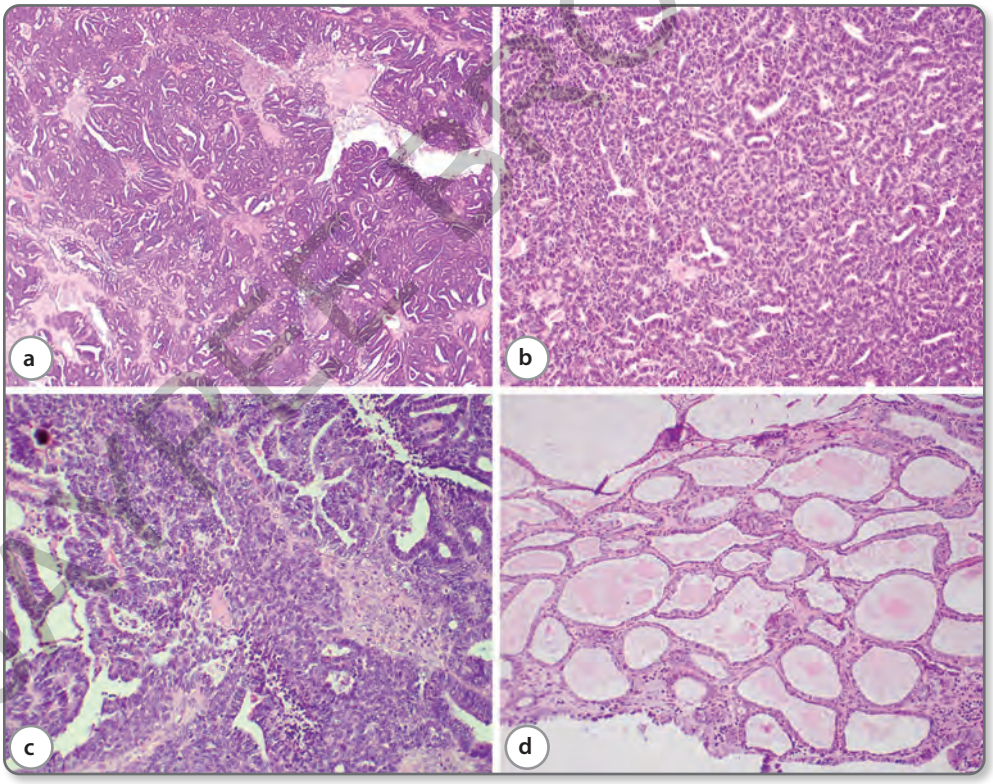

Figure 4.6 Histologic spectrum of MLA: (a) Glandular morphology with slit-like spaces and papillary architecture (H&E, 100×); (b) closely packed tubules (H&E, 200×); (c) focal solid growth (H&E, 200×); (d) cystic and dilated glands with attenuated lining (H&E, 200×).

WILEY BLACKWELL OTHERS

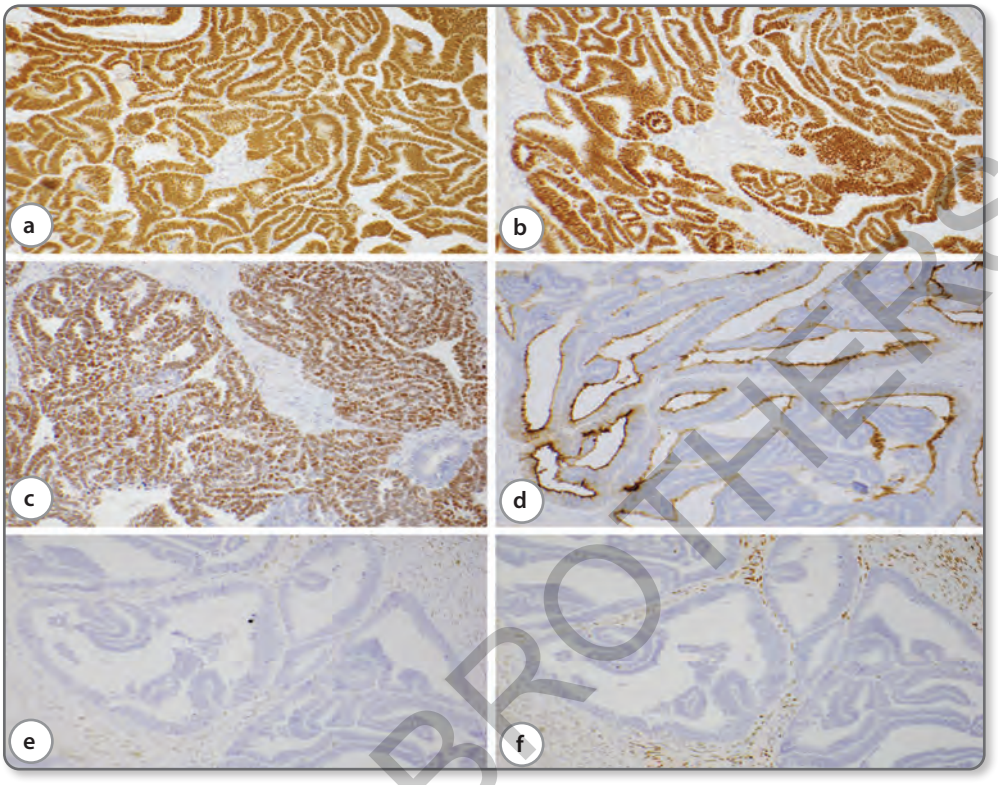

Figure 4.7 Typical immunohistochemical profile of MLA: (a) PAX-8 nuclear positivity (200×); (b) GATA-3 nuclear positivity (200×); (c) TTF-1 nuclear positivity (200×); (d) luminal positivity with CD10 (200×); (e) negative staining for ER (200×); (f) negative staining for PR (200×).

negative marker [4,6,16–19]. In fact, the absence of diffuse ER and PR expression in tumours that are initially considered to be low-grade endometrioid carcinomas is extremely unusual; this discrepancy should hint to the possibility of the tumour representing MLA, and additional immunohistochemical staining would be warranted. Interestingly, GATA-3 and TTF-1 often show an inverse staining pattern which can be useful in small biopsies where GATA-3 is negative **(Figure 4.8)** [19]. Because CD10 invariably stains surrounding endometrial stroma and calretinin can be non-specific, these stains are often difficult to interpret. MLAs show wild-type *p53* expression and patchy *p16* positivity, as well as negative staining for WT-1. Recent studies have demonstrated that they are typically mismatch-repair protein proficient, with retained expression of *MLH1, PMS2, MSH2* and *MSH6*, and the loss of expression of any of these markers should put in doubt a diagnosis of MLA [15].

Although TTF-1 is considered the most specific marker for MLA, GATA-3 is the best overall stain when combining both sensitivity and specificity, followed by TTF-1, CD10, and calretinin. Greater TTF-1 positivity in MLA when compared to mesonephric carcinoma may be secondary to the fact that the two are biologically distinct. Focal GATA-3 positivity may be seen in a subset of mesonephric carcinomas, limiting its utility in distinguishing MLA from true mesonephric carcinomas [10].

JAYPEE BROTHERS

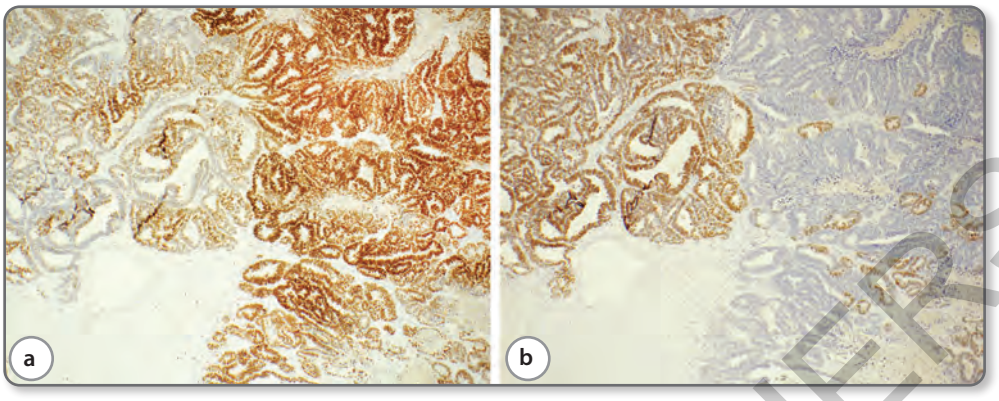

Figure 4.8 Characteristic inverse staining pattern of MLA with GATA-3 and TTF-1: (a) GATA-3 demonstrating strong expression in the right half of the image with weak expression on the left; (b) TTF-1 demonstrates strong expression in the left half with decreased to absent expression in the right half.

MOLECULAR FINDINGS

Mesonephric-like adenocarcinomas are characterised by molecular findings which overlap between endometrioid carcinomas and mesonephric carcinomas. As such, they often demonstrate recurrent *KRAS* mutations (often seen in mesonephric carcinomas), as well as *PIK3CA* and *ARID1A* mutations (commonly seen in endometrioid carcinomas) but lack the characteristic *PTEN* mutations seen in endometrioid carcinomas [3,20]. Gains of chromosomes 1q, 10, and 12 have also been described as a recurrent feature [3].

There are a few caveats to keep in mind when using molecular findings to aid in the diagnosis. Copy number changes are not specific to MLA and can be seen in a subset of endometrioid carcinomas [21]. *KRAS* and *ARID1A* mutations are common in both mesonephric and endometrioid carcinomas and are not useful in determining the Müllerian origin of MLA [3,21]. *PIK3CA* mutations are also commonly seen in endometrioid carcinomas and MLA, but not in mesonephric carcinomas [21], raising the possibility that MLA could possess dual endometrioid and mesonephric differentiation or, more likely, derive from Müllerian epithelium but exhibit predominantly mesonephric differentiation [3].

Interestingly, one study demonstrated the presence of 1q gain in all ovarian tumours but only in one uterine tumour, while gains of chromosomes 10 and 12 were only observed in uterine MLAs [3]. In the same study, all ovarian MLA had G12D *KRAS* mutations and all uterine MLA harboured G12V *KRAS* mutations [3]. While the biologic significance of this distinction is not known, the G12D mutation has been linked to adverse clinical behaviour in some gastrointestinal carcinomas [22,23].

Lastly, MLAs have not been shown to have mutations in *TP53*, are microsatellite stable (MSS), and have not been shown to harbour *POLE* mutations. As such, when endometrial based, they belong to the "No specific molecular profile (NSMP)" group of endometrial tumours [21]. It is speculated that a proportion of patients with poor survivals seen in this TCGA (The Cancer Genome Atlas) group may be explained by their tumours being unrecognised MLA [15].

JAYPEE BROTHERS

DIFFERENTIAL DIAGNOSIS

The diagnosis of MLA is challenging, particularly because these are newly described and unusual tumours with diverse histology. As a result, they are often misdiagnosed, generally as low-grade endometrioid carcinomas. Even though MLAs commonly have tubular and glandular growth patterns, they are characterised by extensive architectural heterogeneity. Cytological findings such as nuclear grooves and vesicular chromatin are usually not observed in endometrioid carcinomas, which are characterised by columnar cells with pseudostratified nuclei. On the other hand, the presence of metaplastic changes, including mucinous and squamous metaplasia, is not expected in MLA and would favour a diagnosis of endometrioid carcinoma. Similarly, the presence of atypical hyperplasia/endometrial intraepithelial neoplasia (AH/EIN) favours an endometrioid carcinoma, but there are described instances in which these precursor lesions are found co-existing with *bona fide* MLA [4]. MLAs are characterised by the expression of GATA-3 and/or TTF-1, not normally seen in endometrioid carcinomas. Additionally, low-grade endometrioid carcinomas are classically ER and PR positive; when dealing with an architecturally low-grade appearing tumour reminiscent of an endometrioid carcinoma demonstrating absence of ER and PR expression, MLA must be strongly considered as an alternative diagnosis. Conversely, while MLA may occasionally demonstrate focal staining for ER, the presence of strong and diffuse ER and PR expression generally argues against a diagnosis of MLA. Lastly, as mentioned above, MLAs are generally mismatch-repair protein proficient; loss of expression of any of the four mismatch-repair proteins would be unusual for this diagnosis, and endometrioid carcinoma should be considered instead.

When confronted with a tumour demonstrating mesonephric-like features, the possibility of cervical mesonephric carcinomas with uterine corpus involvement must always be considered and excluded. Radiologic correlation and determination of the location of the bulk of the tumour can help to determine site of origin, and aid in this distinction; the identification of background mesonephric hyperplasia of the cervix in association to the cervical component of the tumour should be taken as a strong indication of a true primary cervical mesonephric carcinoma with secondary uterine corpus involvement. MLAs of the uterine corpus typically arise in the endometrium, while mesonephric carcinomas, on the other hand, potentially arise in the lateral walls of the myometrium where mesonephric remnants are expected to exist [15]. Immunohistochemical overlap exists between these two entities, with both usually staining negative for ER and PR. GATA-3, calretinin, and CD10 can be positive in both. However, MLAs tend to have more TTF-1 staining in comparison to mesonephric carcinomas [19]. Additional molecular testing can be performed if needed to aid in this distinction, and although MLA and mesonephric carcinomas share *KRAS* mutations, the presence of concurrent *PIK3CA* mutations favours the diagnosis of the former within this differential.

While less likely to be included in the differential diagnosis, the diagnostic differences between MLA and the other Müllerian-derived carcinomas (namely high-grade serous carcinoma and clear-cell carcinoma) are worth mentioning. High-grade nuclear atypia, particularly in the context of a papillary growth pattern, should raise the possibility of serous carcinoma. While MLAs act in an aggressive manner, the cytologic atypia characteristic of serous carcinomas is not seen in MLAs, which in fact usually demonstrate only mild-to-moderate nuclear atypia. Evidently, serous carcinomas demonstrate aberrant *p53* staining patterns and often show block positivity with *p16*, features rarely ever seen in MLA. Since ER and PR may be negative in serous carcinomas, these are less helpful in this differential.

JAYPEE BROTHERS

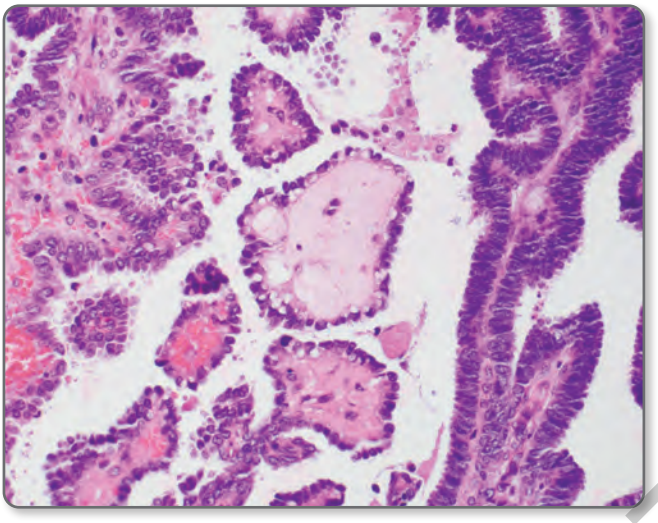

Figure 4.9 Stromal hyalinisation, hobnailing, and focal cytoplasmic clearing in MLA, mimicking the morphology of clear cell carcinoma (H&E, 400×).

Clear-cell carcinomas, which may also demonstrate a multitude of architectural growth patterns, are also generally negative for ER and PR, as are MLAs. However, the cytoplasmic clearing, hobnailing, and prominent nucleoli, classically seen in clear-cell carcinomas, are not characteristics of MLA. In addition, the classic stromal hyalinisation often seen in clear-cell carcinomas is also lacking in MLA. However, there can be areas that mimic these features in MLA **(Figure 4.9)**. Immunohistochemical stains used to help diagnose clear-cell carcinoma, such as Napsin-A and hepatocyte nuclear factor-1-beta (HNF-1β) can be focally positive in MLA and are thus of limited utility [24]. GATA-3 and TTF-1 are typically negative in clear-cell carcinomas, which as is the case with endometrioid carcinomas, can also be DNA mismatch-repair protein deficient.

Owing to the frequent positivity with TTF-1 and characteristic nuclear features, an additional diagnosis to keep in the differential, mainly when dealing with an ovarian lesion, is metastatic papillary thyroid carcinoma (PTC) or malignant struma ovarii with a papillary thyroid carcinoma component [25]. This is even more challenging when the MLA is associated with a teratoma [9]. The use of additional thyroid-specific markers, such as thyroglobulin, is usually sufficient to establish the correct diagnosis.

Female adnexal tumour of probable Wolffian origin (FATWO) may also enter in the differential diagnosis. While FATWO and MLA both have varied architectural patterns, the former does not show the papillary thyroid carcinoma-like nuclear features, and more frequently demonstrate a sieve-like architecture [25]. Unlike MLA, and in addition to being positive for inhibin, FATWOs are more likely to also be positive for ER and are usually negative for PAX-8, TTF-1 and GATA-3 [26].

A scenario where immunohistochemical staining can cause a dilemma is when MLA metastasises to the lungs. Positive TTF-1 with negative hormone receptors can make it hard to delineate metastatic MLA from a lung adenocarcinoma [15]. In these cases, the clinical history is crucial in avoiding a misdiagnosis. As such, if there is a known history of a gynaecologic malignancy, or if there are clinico-radiologic features concerning for a potential endometrial or ovarian lesion (including abnormal vaginal bleeding and/or the presence of a pelvic mass), doing a PAX-8 is invaluable [15]. Morphological clues such as

JAYPEE BROTHERS

pseudo-endometrioid glands and small tubules with eosinophilic secretions provide clues for MLA. GATA-3, CD10, and calretinin can be used for confirmation, if deemed necessary.

PROGNOSIS

Even though MLAs generally have low-grade histologic features, they have been shown to act in an aggressive manner. In comparison to other endometrial adenocarcinomas, uterine MLA have a worse overall survival compared to International Federation of Gynaecology and Obstetrics (FIGO) grade 1 and 2 endometrial endometrioid carcinomas, similar overall survival to FIGO grade 3 endometrial endometrioid carcinomas, and slightly better overall survival than serous carcinomas and carcinosarcomas [4]. Metastasis to the lungs and recurrences are common [4,6,7,14,20]. Even low-stage tumours tend to metastasise frequently and characteristics such as large tumour size (>4 cm), advanced FIGO stages (III to IV), ill-defined tumour borders, tumour necrosis, increased mitotic activity (>10 mitotic figures per 10 high-power fields) and lymphovascular invasion are significantly associated with an increased risk of dissemination [20].

Based on the data available in the literature, ovarian MLAs tend to have a worse prognosis than clear cell and endometrioid ovarian carcinomas [27].

TREATMENT

Unfortunately, as of now, there is not an established optimal regimen of treatment with respect to chemotherapy or radiation for MLA. Historically, cases have undergone hysterectomy with bilateral salpingo-oophorectomy. Pelvic and para-aortic lymph node dissections are occasionally performed. Various combinations of adjuvant therapy (carboplatin with paclitaxel), radiation, and radiation with chemotherapy have been attempted. However, there are currently no tumour-specific treatments for MLA.

A recent study by Arslanian et al has demonstrated a case with a potentially actionable *PIK3CA H1047Q* mutation [28]. Although mutations in the *PIK3CA* gene have been reported in *KRAS* mutated MLAs, this variant is a new finding. Variants in this hotspot have shown response to a combination of ER antagonist and alpha-specific PI3K inhibitors in ER-positive breast carcinoma, demonstrating improved progression free and overall survival [29,30]. While the therapeutic prospective has not been elucidated specifically in MLA, future studies in ER-expressing MLA may shed light on the potential of this treatment option.

CONCLUSION

Given the significant prognostic implication of this diagnosis, proper recognition of MLA is crucial for adequate patient management. As mentioned in this review, the most common misdiagnosis when dealing with MLA is that of a low-grade endometrioid carcinoma. Since low-grade and low-stage endometrioid carcinomas are generally followed with observation only, this misdiagnosis could result in withholding of necessary adjuvant therapy in misdiagnosed MLAs, with negative impact on patient's outcomes. Features such as heterogeneous architectural patterns, with a predominant tubular and glandular architecture, intratubular eosinophilic secretions, papillary thyroid carcinoma-like nuclear features, and the absence of squamous or mucinous differentiation, are all

JAYPEE BROTHERS

important clues in avoiding this diagnostic pitfall. A low index of suspicion is necessary to request confirmatory immunohistochemical stains in order to adequately diagnose these uncommon but clinically relevant carcinomas, including PAX-8, GATA-3, TTF-1, ER and PR as first-line markers [19]. In challenging cases, CD10, calretinin, and mismatch-repair protein immunohistochemistry might be helpful. Molecular alterations in *KRAS*, *PIK3CA*, and/or *ARID1A*, in the absence of *PTEN* aberrations, would also support this diagnosis, but are seldom required.

Finally, MLAs are tumours with deceptively low-grade morphology that should be considered high-grade carcinomas. The tendency to metastasise and recur makes it imperative to recognise and differentiate it from its close mimics. While treatment options and therapeutic modalities are inadequate as of today, further research must be undertaken to understand the biology and pathogenesis of this tumour.

Key points for clinical practice

- Mesonephric-like adenocarcinoma (MLA) of the female genital tract is a recently recognised carcinoma of the gynaecologic tract, occurring in the uterine corpus and ovaries.
- It is considered to be a Müllerian-derived adenocarcinoma differentiating along mesonephric lines.
- These tumours show overlapping morphological, immunohistochemical, and molecular features with mesonephric carcinomas of the cervix and endometrial endometrioid carcinomas, leading to complexities in identification and diagnosis.
- MLAs have a significantly more aggressive clinical behaviour, particularly when endometrial based, compared to low-grade endometrioid carcinomas. Metastasis to the lungs and recurrences are common.
- Morphological features such as heterogeneous architectural patterns, with a predominant tubular and glandular architecture, intratubular eosinophilic secretions, and papillary thyroid carcinoma-like nuclear features, and the absence of squamous or mucinous differentiation, are all important clues for diagnosis.
- Confirmatory immunohistochemical stains include PAX-8, GATA-3, TTF-1, ER, and PR.
- Although not necessary, molecular alterations in *KRAS*, *PIK3CA*, and/or *ARID1A*, in the absence of *PTEN* aberrations, can support diagnosis.

REFERENCES

1. McCluggage WG. Progress in the pathological arena of gynecological cancers. Int J Gynecol Obstet 2021; 155:107–114.
2. McFarland M, Quick CM, McCluggage WG. Hormone receptor-negative, thyroid transcription factor 1-positive uterine and ovarian adenocarcinomas: report of a series of mesonephric-like adenocarcinomas. Histopathology 2016; 68:1013–1020.
3. Mirkovic J, McFarland M, Garcia E, et al. Targeted Genomic Profiling Reveals Recurrent KRAS Mutations in Mesonephric-like Adenocarcinomas of the Female Genital Tract. Am J Surg Pathol 2018; 42:227–233.
4. Pors J, Segura S, Chiu DS, et al. Clinicopathologic Characteristics of Mesonephric Adenocarcinomas and Mesonephric-like Adenocarcinomas in the Gynecologic Tract: A Multi-institutional Study. Am J Surg Pathol 2021; 45:498–506.

JAYPEE BROTHERS

5. Quick CM, Malpica A, Hoang LN. Mesonephric-like adenocarcinoma. In: WHO Classification of Tumours Editorial Board (Ed). WHO classification of tumours: Female Genital Tumours, 5th Edition. WHO, France: the International Agency for Research on Cancer Publications, 2020.
6. Kolin DL, Costigan DC, Dong F, Nucci MR, Howitt BE. A Combined Morphologic and Molecular Approach to Retrospectively Identify KRAS-Mutated Mesonephric-like Adenocarcinomas of the Endometrium. Am J Surg Pathol 2019; 43:389–398.
7. Horn LC, Höhn AK, Krücken I, et al. Mesonephric-like adenocarcinomas of the uterine corpus: report of a case series and review of the literature indicating poor prognosis for this subtype of endometrial adenocarcinoma. J Cancer Res Clin Oncol 2020; 146:971–983.
8. Chang CS, Carney ME, Killeen JL. Two Cases of Mesonephric-like Carcinoma Arising From Endometriosis: Case Report and Review of the Literature. Int J Gynecol Pathol 2023; 42:101–107.
9. Deolet E, Arora I, Van Dorpe J, et al. Extrauterine Mesonephric-like Neoplasms: Expanding the Morphologic Spectrum. Am J Surg Pathol 2022; 46:124–133.
10. Gibbard E, Cochrane DR, Pors J, et al. Whole-proteome analysis of mesonephric-derived cancers describes new potential biomarkers. Hum Pathol 2021; 108:1–11.
11. Chapel DB, Joseph NM, Krausz T, Lastra RR. An Ovarian Adenocarcinoma With Combined Low-grade Serous and Mesonephric Morphologies Suggests a Müllerian Origin for Some Mesonephric Carcinomas: Int J Gynecol Pathol 2018; 37:448–459.
12. McCluggage WG, Vosmikova H, Laco J. Ovarian Combined Low-grade Serous and Mesonephric-like Adenocarcinoma: Further Evidence for A Müllerian Origin of Mesonephric-like Adenocarcinoma. Int J Gynecol Pathol 2020; 39:84–92.
13. Yano M, Shintani D, Katoh T, et al. Coexistence of endometrial mesonephric-like adenocarcinoma and endometrioid carcinoma suggests a Müllerian duct lineage: a case report. Diagn Pathol 2019; 14:54.
14. Euscher ED, Bassett R, Duose DY, et al. Mesonephric-like Carcinoma of the Endometrium: A Subset of Endometrial Carcinoma With an Aggressive Behavior. Am J Surg Pathol 2020; 44:429–443.
15. Deolet E, Van Dorpe J, Van de Vijver K. Mesonephric-Like Adenocarcinoma of the Endometrium: Diagnostic Advances to Spot This Wolf in Sheep's Clothing. A Review of the Literature. J Clin Med 2021; 10:698.
16. Ando H, Watanabe Y, Ogawa M, et al. Mesonephric adenocarcinoma of the uterine corpus with intracystic growth completely confined to the myometrium: a case report and literature review. Diagn Pathol 2017; 12:63.
17. Kenny SL, McBride HA, Jamison J, McCluggage WG. Mesonephric Adenocarcinomas of the Uterine Cervix and Corpus: HPV-negative Neoplasms That Are Commonly PAX8, CA125, and HMGA2 Positive and That May Be Immunoreactive with TTF1 and Hepatocyte Nuclear Factor 1-β. Am J Surg Pathol 2012; 36:799–807.
18. Patel V, Kipp B, Schoolmeester JK. Corded and hyalinized mesonephric-like adenocarcinoma of the uterine corpus: report of a case mimicking endometrioid carcinoma. Hum Pathol 2019; 86:243–248.
19. Pors J, Cheng A, Leo JM, et al. A Comparison of GATA3, TTF1, CD10, and Calretinin in Identifying Mesonephric and Mesonephric-like Carcinomas of the Gynecologic Tract. Am J Surg Pathol 2018; 42:1596–1606.
20. Na K, Kim HS. Clinicopathologic and Molecular Characteristics of Mesonephric Adenocarcinoma Arising From the Uterine Body. Am J Surg Pathol 2019; 43:14.
21. The Cancer Genome Atlas Research Network, Levine DA. Integrated genomic characterization of endometrial carcinoma. Nature 2013; 497:67–73.
22. Modest DP, Ricard I, Heinemann V, et al. Outcome according to KRAS-, NRAS- and BRAF-mutation as well as KRAS mutation variants: pooled analysis of five randomized trials in metastatic colorectal cancer by the AIO colorectal cancer study group. Ann Oncol 2016; 27:1746–1753.
23. Bournet B, Muscari F, Buscail C, et al. KRAS G12D Mutation Subtype Is A Prognostic Factor for Advanced Pancreatic Adenocarcinoma. Clin Transl Gastroenterol 2016; 7:e157.
24. Kajiwara H, Hirasara T, Kawashima M, et al. Three cases of mesonephric-like adenocarcinoma in the female genital organs. Obstet Gynecol Rep 2020; 4:1–7.

JAYPEE BROTHERS

25. McCluggage WG. Mesonephric-like Adenocarcinoma of the Female Genital Tract: From Morphologic Observations to a Well-characterized Carcinoma With Aggressive Clinical Behavior. Adv Anat Pathol 2022; 29:208–216.
26. Goyal A, Masand RP, Roma AA. Value of PAX-8 and SF-1 Immunohistochemistry in the Distinction Between Female Adnexal Tumor of Probable Wolffian Origin and its Mimics: Int J Gynecol Pathol 2016; 35:167–175.
27. Davis M, Rauh-Hain JA, Andrade C, et al. Comparison of clinical outcomes of patients with clear cell and endometrioid ovarian cancer associated with endometriosis to papillary serous carcinoma of the ovary. Gynecol Oncol 2014; 132:760–766.
28. Arslanian E, Singh K, James Sung C, Quddus MR. Somatic mutation analysis of Mesonephric-Like adenocarcinoma and associated putative precursor Lesions: Insight into pathogenesis and potential molecular treatment targets. Gynecol Oncol Rep 2022; 42:101049.
29. André F, Ciruelos EM, Juric D, et al. Alpelisib plus fulvestrant for PIK3CA-mutated, hormone receptor-positive, human epidermal growth factor receptor-2–negative advanced breast cancer: final overall survival results from SOLAR-1. Ann Oncol 2021; 32:208–217.
30. Juric D, Janku F, Rodón J, et al. Alpelisib Plus Fulvestrant in *PIK3CA*-Altered and *PIK3CA*-Wild-Type Estrogen Receptor–Positive Advanced Breast Cancer: A Phase 1b Clinical Trial. JAMA Oncol 2019; 5:e184475.

JAYPEE BROTHERS

Recent Advances in Histopathology

26

This volume presents a collection of in-depth reviews dealing with recent developments in histopathology. The chapters are written by recognised experts in an accessible and easy-to-read format supplemented with judiciously chosen colour microphotographs. For quick review and additional emphasis, each article is further enhanced by a set of bulleted "Key points for clinical practice", summarising the message and pin-pointing the clinical relevance of the presented material for the daily practice of histopathology.

In this volume ample attention is paid to developments in the histopathology of digestive tract conditions. Drug-related changes are frequently encountered and these are extensively covered. Furthermore, an integrating review of the enigmatic eosinophilic diseases is presented as well as the diagnostic approach to T- and NK-cell lymphomas. Further topics addressed include (among others):

- Pathobiology, morphology and clinical significance of minimally invasive thyroid neoplasms
- Mesonephric and mesonephric-like carcinoma of the female genital tract
- Soft-tissue tumours with an epithelioid morphology
- Papillary renal cell carcinoma
- Breast implant related lymphomas

Each chapter provides a comprehensive overview and emphasises the salient points of interest. An index will guide readers in search of a specific issue to the desired information. The volume will prove particularly useful for practicing histopathologists wanting to update their knowledge and for histopathology trainees preparing for proficiency testing.

JP medical publishers

www.jpmedpub.com

ISBN 978-1-78779-178-7