First FRCR Anatomy: Practice Cases

SECOND EDITION

Edited by
Eunjong Yoo • Claire Exley • David Minks
Constantinos Tingerides • Ashley Uttley



Contents

Preface to the second edition		**v**
Preface to the first edition		**vii**
Contributors		**xi**
Acknowledgement		**xii**
Examination revision hints and tips		**xiii**
Chapter 1	**Head and neck**	**1**
	Brain	Cases 1.1–1.19
	Face and neck	Cases 1.20–1.53
	Skull	Cases 1.54–1.62
	Answers	64
Chapter 2	**Chest**	**109**
	Cardiac and vascular	Cases 2.1–2.19
	Bronchopulmonary	Cases 2.20–2.25
	Chest wall and diaphragm	Cases 2.26–2.34
	Breast	Case 2.35
	Answers	145
Chapter 3	**Abdomen and pelvis**	**169**
	Bowel	Cases 3.1–3.14
	Upper abdominal viscera	Cases 3.15–3.21
	Abdominal wall	Cases 3.22–3.27
	Spaces and planes	Cases 3.28–3.32
	Genitourinary	Cases 3.33–3.40
	Gynaecology	Cases 3.41–3.47
	Vascular supply and lymph node groups	Cases 3.48–3.58
	Answers	228

Chapter 4	**Musculoskeletal system**	**269**
	Lower limb	Cases 4.1–4.18
	Spine	Cases 4.19–4.31
	Upper limb	Cases 4.32–4.45
	Answers	315
Chapter 5	**Practice Paper 1**	**345**
	Cases	346
	Answers	366
Chapter 6	**Practice Paper 2**	**373**
	Cases	374
	Answers	394
Chapter 7	**Practice Paper 3**	**401**
	Cases	402
	Answers	427
Index		431

Chapter 2

Chest

Cardiac and vascular	Cases 2.1–2.19	110
Bronchopulmonary	Cases 2.20–2.25	129
Chest wall and diaphragm	Cases 2.26–2.34	135
Breast	Case 2.35	144
Answers		145

JAYPEE BROTHERS

Cardiac and vascular

Case 2.1

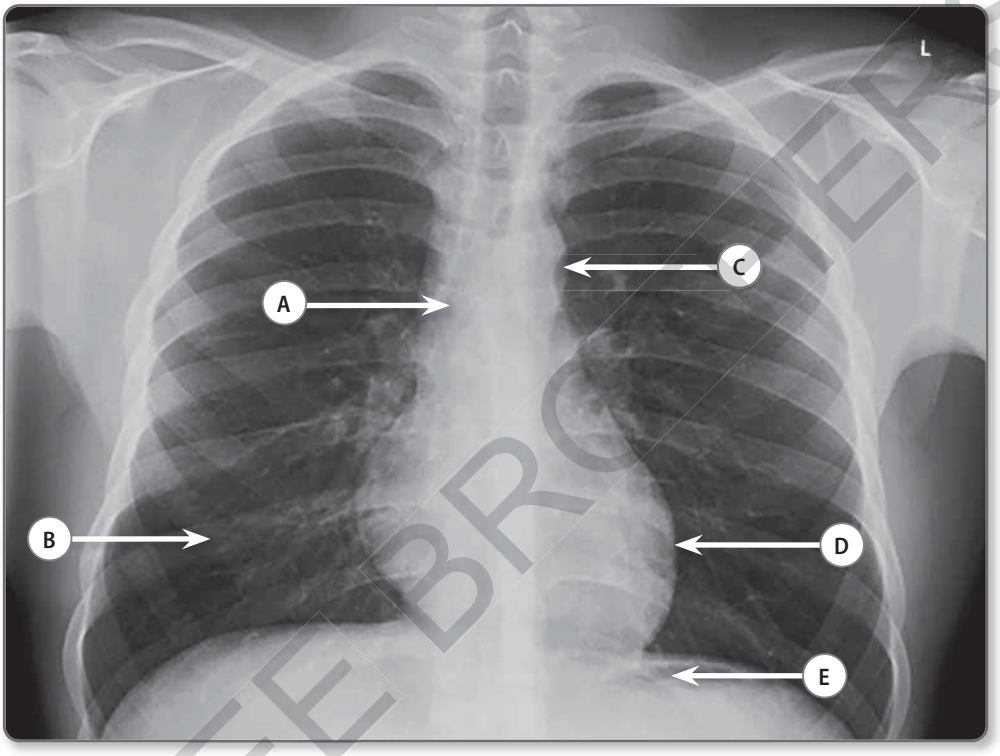

Case 2.1

	QUESTION	WRITE YOUR ANSWER HERE
A	Name the structure labelled A.	
B	Name the structure labelled B.	
C	Name the structure labelled C.	
D	Name the structure labelled D.	
E	Name the structure labelled E.	

JAYPEE BROTHERS

Case 2.2

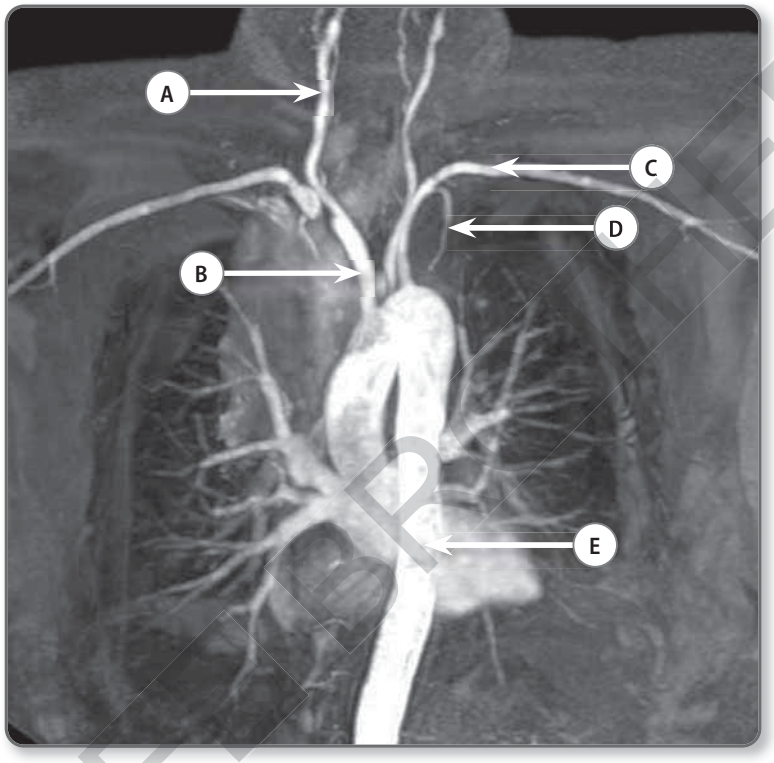

Case 2.2

QUESTION		WRITE YOUR ANSWER HERE
A	Name the structure labelled A.	
B	Name the structure labelled B.	
C	Name the structure labelled C.	
D	Name the structure labelled D.	
E	Name the structure labelled E.	

JAYPEE BROTHERS

Case 2.3

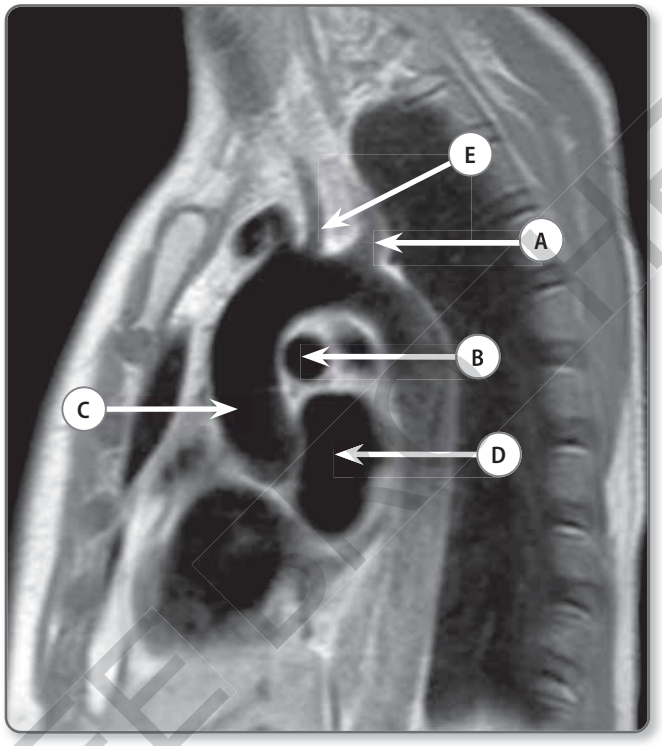

Case 2.3

QUESTION		WRITE YOUR ANSWER HERE
A	Name the structure labelled A.	
B	Name the structure labelled B.	
C	Name the structure labelled C.	
D	Name the structure labelled D.	
E	Name the structure labelled E.	

JAYPEE BROTHERS

Case 2.4

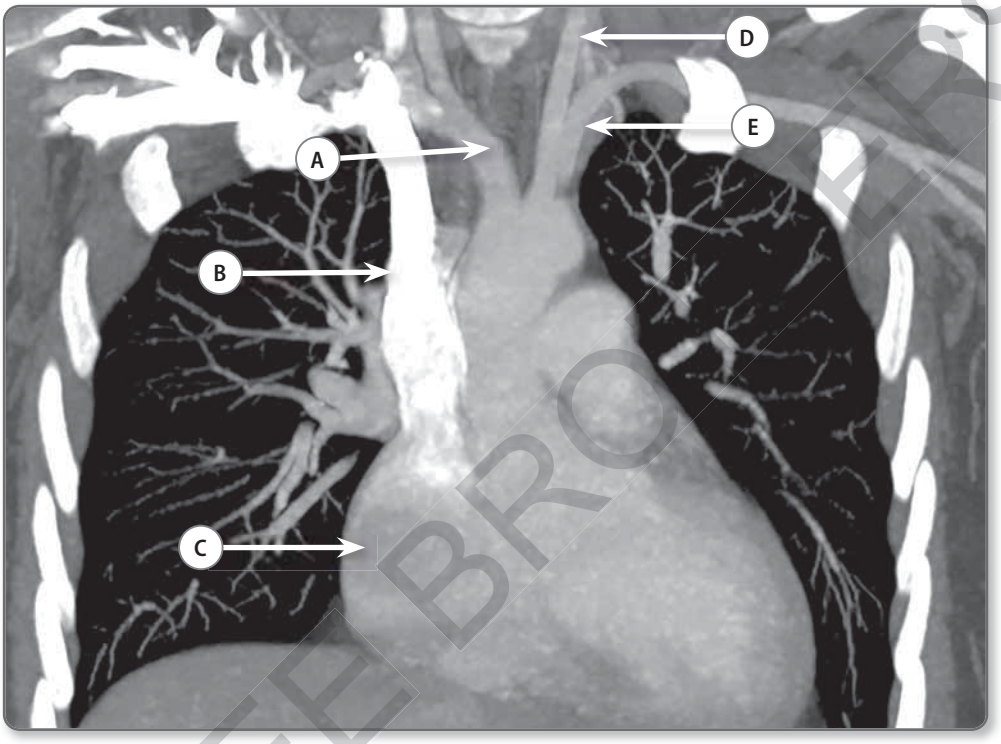

Case 2.4

QUESTION		WRITE YOUR ANSWER HERE
A	Name the structure labelled A.	
B	Name the structure labelled B.	
C	Name the structure labelled C.	
D	Name the structure labelled D.	
E	Name the structure labelled E.	

JAYPEE BROTHERS

Case 2.5

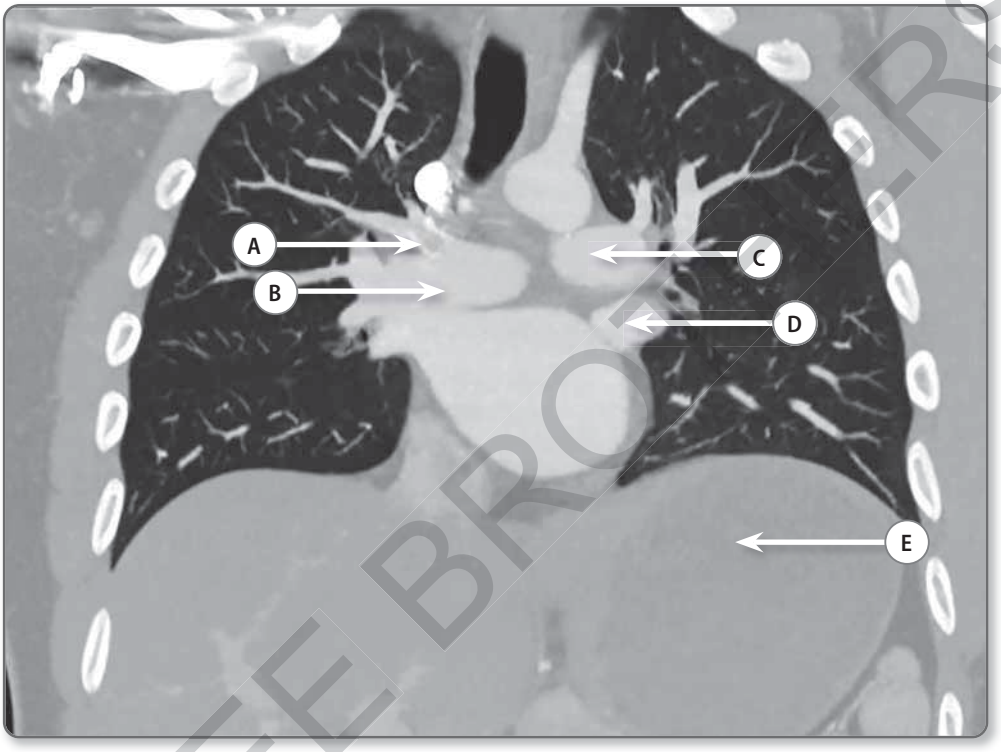

JAYPEE BROTHERS

Case 2.5

	QUESTION	WRITE YOUR ANSWER HERE
A	Name the structure labelled A.	
B	Name the structure labelled B.	
C	Name the structure labelled C.	
D	Name the structure labelled D.	
E	Name the structure labelled E.	

Answers

Case 2.1

A Right main bronchus

B Right 9th rib

C Aortic arch

D Left ventricle border

E Gastric fundus

Plain frontal chest radiograph.

The trachea bifurcates into the left and right main bronchi at the level of the sternal angle (T5 level; T4 on inspiration, T6 on expiration). The trachea is made of 15–20 incomplete rings of cartilage which are completed posteriorly by the trachealis muscle.

The aortic arch passes posteriorly from right to left to lie just left of T4. It is anterior to the trachea and arches over the left main bronchus and pulmonary artery. Lying to the right are the trachea, oesophagus, thoracic duct and body of T4 from front to back. The ligamentum arteriosum is the fibrous remnant of the ductus arteriosus which is connected to its inferior aspect. The aortic isthmus is the junction of the descending aorta with the arch. This is liable to injury in blunt trauma as it is fixed.

The aortic arch, or aortic knuckle, is seen forming the left upper mediastinal contour and continues as the descending thoracic aorta which can be seen behind the cardiac shadow. The descending aorta is found in the posterior mediastinum. A right-sided aortic arch, or double aortic arch, is sometimes seen as a normal variant. These particular anomalies can create complete vascular rings, and may cause compressive symptoms affecting the trachea and oesophagus.

The right atrium forms the right heart border and the superior and inferior vena cava drain into its superior and inferior parts respectively. The left ventricle forms the left heart border.

In a situs solitus patient, the stomach lies predominantly to the left of the midline, with gastric gas rising to a dependent position in the fundus giving rise to a contained bubble of air below the left hemidiaphragm.

Weir J, Abrahams P. Imaging Atlas of Human Anatomy, 4th edition. Edinburgh: Mosby, 2010:90.

Ryan S, McNicholas M, Eustace SJ. Anatomy for Diagnostic Imaging, 3rd edition. Edinburgh: Saunders, 2010:120.

Weber E, Netter FH, Vilensky JA, Carmichael SW. Netter's Concise Radiologic Anatomy. Philadelphia: Saunders/Elsevier, 2009:183.

JAYPEE BROTHERS

Case 2.2

A Right common carotid artery

B Brachiocephalic trunk

C Left subclavian artery

D Left internal thoracic artery/left internal mammary artery

E Descending thoracic aorta

MRI aortic angiogram.

The aortic arch begins at the origin of the brachiocephalic trunk. The branch vessels that arise from the aortic arch are, in order:

- Brachiocephalic trunk
- Left common carotid artery
- Left subclavian artery

The brachiocephalic trunk bifurcates into the right subclavian and right common carotid arteries. From the subclavian arteries arise the internal thoracic or internal mammary arteries.

The most common variation in the anatomy of the aortic arch vessels is a common origin of the brachiocephalic trunk and the left common carotid, or so-called bovine arch (20%). In 6%, the left vertebral artery arises directly from the arch, instead of the left subclavian. An anomalous right subclavian artery is another variant, whereby the right subclavian originates as the last of the arch vessels, and takes a retro-oesophageal course as it traverses from left to right. This can cause symptoms of dysphagia, and can be seen on a barium swallow as a persistent indentation posteriorly.

The aortic arch ends, and the descending thoracic aorta begins immediately distal to the left subclavian artery. At this point, the ligamentum venosum (remnant of the ductus arteriosus) joins the lower border of the arch to the main pulmonary artery. The aorta is fixed at this point.

Weir J, Abrahams P. Imaging Atlas of Human Anatomy, 4th edition. Edinburgh: Mosby, 2010:101–103.

Ryan S, McNicholas M, Eustace SJ. Anatomy for Diagnostic Imaging, 3rd edition. Edinburgh: Saunders, 2010:142.

Layton KF. Bovine aortic arch variant in humans: clarification of a common misnomer. Am J Neuroradiol 2006; 27:1541–1542.

Case 2.3

A Left subclavian artery

B Left pulmonary artery

C Ascending thoracic aorta

D Left atrium

E Left common carotid artery

JAYPEE BROTHERS

Sagittal thoracic MRI.

Blood can appear 'black' or 'bright' on MRI, depending on which sequence is used. Standard gradient echo sequences will give a 'bright blood' picture. This is a parasagittal section, on a spin echo MRI sequence, on which blood appears 'black'. Spin echo sequences show 'black blood' because of high velocity signal loss. This occurs due to the 180° pulse. Blood which receives the 90° pulse moves out of the slice before the 180° pulse is applied. This means that the blood produces no signal.

The three main branch vessels can be seen arising from the aortic arch as it passes from anterior to posterior. The brachiocephalic trunk arises first, anteriorly, and the left subclavian last, the most posterior. The descending aorta is located in the posterior mediastinum, to the left of midline.

Posterior to the left main pulmonary artery on this section, is the left main bronchus (which also appears dark, as it is filled with air). As the left main pulmonary artery courses laterally, it comes to lie on top of the left main bronchus, which is why the left hilum is higher than the right on a frontal chest radiograph.

The left atrium is the most posterior of the cardiac chambers, as seen on this parasagittal section.

Kagetsu NJ. Flow. http://www.revisemri.com/questions/pulse_sequences/black_blood_bright_blood. (Last accessed 8 April 2024).

Case 2.4

A Brachiocephalic trunk

B Superior vena cava

C Right atrium

D Left common carotid artery

E Left subclavian artery

Coronal maximum intensity projection of a CT pulmonary angiogram.

Variations in the pattern of branching of the aortic arch are common, such that only 65% of people have a 'normal' branching pattern. 2.7% of people have a common origin of the left subclavian and common carotid arteries, to form a left-sided brachiocephalic trunk. This gives a symmetrical appearance to the aortic branches. The right common carotid is seen to arise in its normal position from a standard right-sided brachiocephalic trunk.

Weir J, Abrahams P. Imaging Atlas of Human Anatomy, 4th edition. Edinburgh: Mosby, 2010:140–144.

Ryan S, McNicholas M, Eustace SJ. Anatomy for Diagnostic Imaging, 3rd edition. Edinburgh: Saunders, 2010:117.

Case 2.5

A Right upper lobe pulmonary artery

B Right main pulmonary artery

C Left main pulmonary artery

JAYPEE BROTHERS

D Left superior pulmonary vein

E Gastric fundus

Coronal maximum intensity projection from a thorax CT.

The main pulmonary artery arises from the right ventricle, and travels superiorly and posteriorly. It starts off anterior to the aorta, before coming to lie to its left. At the level of T5, it bifurcates into the left and right main pulmonary arteries.

The left main pulmonary artery runs superoposteriorly, and arches over the left main bronchus before entering the hilum. At this point, it branches into its lobar branches.

The right pulmonary artery branches from the main pulmonary trunk at 90°, and passes behind the superior vena cava and ascending aorta, anterior to the right main bronchus. The right main pulmonary artery divides into upper lobe and interlobar branches.

There are four main pulmonary veins which drain into the left atrium; the right and left, superior and inferior pulmonary veins. In the upper zones, the veins lie inferolateral to the arteries, and in the lower zones the veins have quite a horizontal course, compared to the arteries which are much more vertical.

The pulmonary vasculature makes up the hilar point, which can be seen on a frontal chest radiograph. Remember, the hilar point is where the superior pulmonary vein crosses the interlobar pulmonary artery.

Weir J, Abrahams P. Imaging Atlas of Human Anatomy, 4th edition. Edinburgh: Mosby, 2010:110–111.

Ryan S, McNicholas M, Eustace SJ. Anatomy for Diagnostic Imaging, 3rd edition. Edinburgh: Saunders, 2010:128–130.

Case 2.6

A Right upper lobe pulmonary artery

B Left atrium

C Aorta

D Left superior pulmonary vein

E Left atrial appendage

Coronal CT angiogram aorta MIP through the left atrium.

The right pulmonary artery can be easily identified as it arises from the pulmonary trunk. It passes in front of the right main bronchus and behind the ascending aorta (not seen here). After the origin of the right upper lobe pulmonary artery, it becomes the interlobar artery from which the middle and lower lobe branches arise. The arterial branching follows the segmental branching pattern of the airways.

The left atrial appendage serves to increase the capacity of the left atrium, and may be the source of emboli in atrial fibrillation.

Weir J, Abrahams P. Imaging Atlas of Human Anatomy, 4th edition. Edinburgh: Mosby, 2010:100–103.

Ryan S, McNicholas M, Eustace SJ. Anatomy for Diagnostic Imaging, 3rd edition. Edinburgh: Saunders, 2010:122–125.

Weber E, Netter FH, Vilensky JA, Carmichael SW. Netter's Concise Radiologic Anatomy. Philadelphia: Saunders/Elsevier, 2009:177.

JAYPEE BROTHERS

Case 2.7

A Left spine of scapula

B Left upper lobe

C Left oblique fissure

D Right ventricle

E Interventricular septum

A left parasagittal CT of the thorax through the right and left ventricles of the heart.

The left oblique fissure extends from about T4/T5 posteriorly to the diaphragm anteriorly. This is similar in both left and right lungs.

The right ventricle is the most anterior chamber of the heart. It is crescent-shaped, and has a thinner wall than the larger, more muscular left ventricle. The left ventricle is large and under higher pressure, therefore producing a bulge into the right ventricle, giving it this crescent shape. Inflow is from the right atrium via the tricuspid valve (three leaflets). Outflow is into the pulmonary artery via the pulmonary valve.

The muscular interventricular septum lies between the two ventricles and bulges into the right ventricle, giving the right ventricle its crescent shape and the left ventricle its circular shape.

Weir J, Abrahams P. Imaging Atlas of Human Anatomy, 4th edition. Edinburgh: Mosby, 2010:104–107.

Ryan S, McNicholas M, Eustace SJ. Anatomy for Diagnostic Imaging, 3rd edition. Edinburgh: Saunders, 2010:134.

Case 2.8

A Left lobe of the thyroid

B Trachea

C Brachiocephalic trunk

D Right axillary artery

E Left subclavian artery

Coronal CT of the thorax through the arch of the aorta.

The ascending aorta begins at the aortic valve which lies at the level of the 2nd costal cartilage. The arch of the aorta passes posteriorly and from right to left.

The subclavian artery becomes the axillary artery at the lateral margin of the first rib. It becomes the brachial artery at the lower aspect of teres major. It provides branches to the lateral thorax and upper limb.

This configuration is only seen in 65% of people as variation is common:

- In 5%, the vertebral artery arises directly from the arch of the aorta, between the left common carotid and left subclavian artery. This leads to four vessels arising from the aorta instead of three

JAYPEE BROTHERS

- In 2.7%, there is a common origin of the left common carotid and subclavian arteries (left brachiocephalic artery)
- In 2.5%, the left common carotid artery arises from the brachiocephalic artery
- In 0.5%, there is an aberrant right subclavian artery which arises distal to the left subclavian. It passes to the right passing behind the oesophagus

You should make sure that you have seen images of these variants prior to the examination.

Weir J, Abrahams P. Imaging Atlas of Human Anatomy, 4th edition. Edinburgh: Mosby, 2010:117.

Ryan S, McNicholas M, Eustace SJ. Anatomy for Diagnostic Imaging, 3rd edition. Edinburgh: Saunders, 2010:140–144.

Weber E, Netter FH, Vilensky JA, Carmichael SW. Netter's Concise Radiologic Anatomy. Philadelphia: Saunders/Elsevier, 2008:183.

Case 2.9

A Sternum

B Right ventricle

C Right atrium

D Interventricular septum

E Non-coronary (or right posterior) sinus of the aorta

Axial CT through the heart and aortic valve.

It is important to be able to identify the chambers of the heart both on coronal and axial images.

The right ventricle forms most of the sternocostal surface of the heart. The cavities of the right and left ventricles are separated by the interventricular septum. The cavity of the right ventricle is crescentic in cross-section because the interventricular septum bulges into it.

The aortic valve has three cusps. Above each cusp is a localised dilatation or sinus (sinuses of Valsalva). The right coronary artery arises from the anterior sinus (also known as the right coronary sinus). The left coronary artery arises from the left posterior sinus (also known as the left coronary sinus). No artery arises from the right posterior sinus (also known as the non-coronary sinus).

A tip to help orientate yourself to the sinuses in the axial place, the non-coronary sinus is the one that lies adjacent to the inter-atrial septum in individuals with normal anatomy.

The interventricular septum is a thick muscular septum separating the left and right ventricles. It bulges into the right ventricle due to the increased pressure in the left ventricle.

Weir J, Abrahams P. Imaging Atlas of Human Anatomy, 4th edition. Edinburgh: Mosby, 2010:99.

Ryan S, McNicholas M, Eustace SJ. Anatomy for Diagnostic Imaging, 3rd edition. Edinburgh: Saunders, 2010:139.

JAYPEE BROTHERS

Case 2.10

A Thoracic vertebral body

B Apex of heart/left ventricular apex

C Papillary muscle

D Anterior cusp of mitral/bicuspid valve

E Right inferior pulmonary vein

Axial CT of the heart.

The papillary muscles of the heart can be appreciated on CT, particularly on a cardiac gated image. These muscles are located in the ventricles, and act to tether the atrioventricular valves by the chordae tendinae. The chordae are attached to the valve cusps, and prevent them prolapsing during systole, and preventing regurgitation of blood into the atrium. In the left ventricle, there are two papillary muscles, an anterior and a posterior one. The right ventricle contains three papillary muscles: the anterior, posterior and septal.

The bicuspid mitral valve separates the left atrium and left ventricle. The right pulmonary vein drains oxygenated blood from the lungs into the left atrium.

Weir J, Abrahams P. Imaging Atlas of Human Anatomy, 4th edition. Edinburgh: Mosby, 2010:99.

Ryan S, McNicholas M, Eustace SJ. Anatomy for Diagnostic Imaging, 3rd edition. Edinburgh: Saunders, 2010:139.

Weber E, Netter FH, Vilensky JA, Carmichael SW. Netter's Concise Radiologic Anatomy. Philadelphia: Saunders/Elsevier, 2009:191.

Case 2.11

A Right atrium

B Oesophagus

C Azygous vein

D Left atrium

E Left superior pulmonary vein

Axial CT pulmonary angiogram.

The right atrium receives deoxygenated blood from the superior vena cava (SVC), inferior vena cava (IVC) and coronary sinus through its smooth posterior wall. The SVC drains superiorly at the level of the right third costal cartilage. The IVC drains at the level of the right fifth costal cartilage. The coronary sinus opens in between the right atrioventricular orifice and the IVC opening.

The anterior wall is rough and composed of pectinate muscular ridges. These ridges are continuous with the right atrial appendage/auricle which overlies the aorta and serves to increase the capacity of the right atrium. The interatrial septum has a depression, the fossa ovalis, the remnant of the foramen ovale which allows a right to left shunt during fetal circulation.

JAYPEE BROTHERS

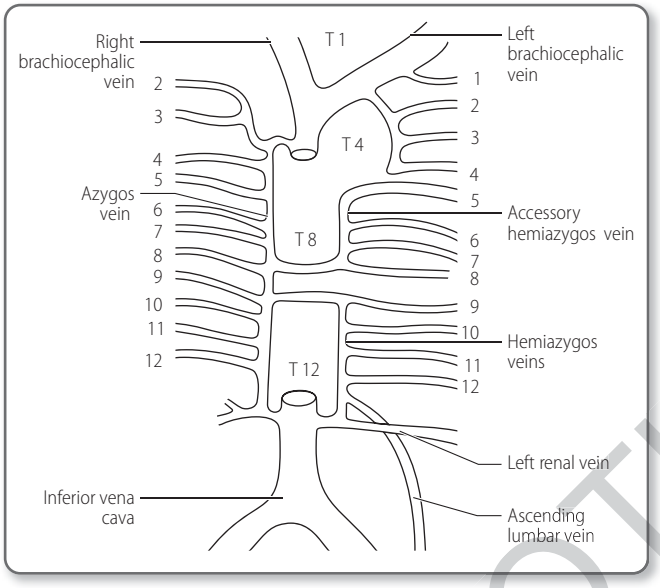

Figure 2.1 The azygos system.

The azygos system of veins lies on either side of the vertebral column in the posterior mediastinum and drains the mediastinal organs, thoracic and abdominal walls, and the back. Its course and anatomy are variable.

The azygos begins at the level of L2 as a branch of the IVC, or as a confluence of lumbar and subcostal veins. It enters the thorax behind the right crus of the diaphragm, and lies to the right of the aorta and thoracic duct. The azygos enters the SVC by arching over the right hilum from the posterior mediastinum.

The azygos receives blood from most of the intercostal veins on the right, as displayed in the diagram above. The hemiazygos and accessory hemiazygos receive blood from most of the intercostal veins on the left, and drain into the azygos at the midthoracic level.

The hemiazygos often begins at the left renal vein, and ascends into the thorax on the left side of the aorta. These structures are shown in **Figure 2.1**.

Moore KL, Dalley AF, Agur AMR. Clinically Oriented Anatomy, 6th edition. Philadelphia: Lippincott Williams & Wilkins, 2009:135–165.

Weir J, Abrahams P. Imaging Atlas of Human Anatomy, 4th edition. Edinburgh: Mosby, 2010:99.

Ryan S, McNicholas M, Eustace SJ. Anatomy for Diagnostic Imaging, 3rd edition. Edinburgh: Saunders, 2010:132–135.

Case 2.12

A Left main stem coronary artery

B Circumflex

C First obtuse marginal branch

D Septal branch

E Left anterior descending

JAYPEE BROTHERS

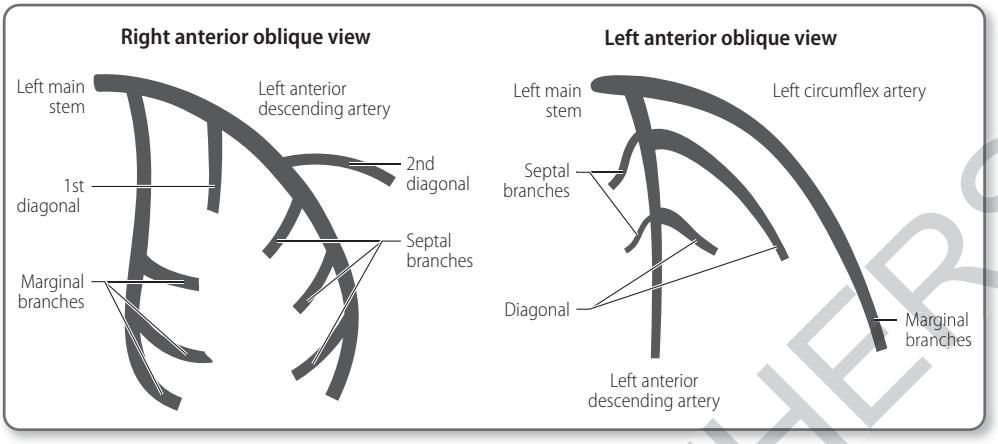

Figure 2.2 The left coronary artery.

Conventional coronary angiogram, right anterior oblique. Selective catheterisation of left main stem.

The left coronary artery (LCA) arises as the left main stem from the posterior sinus of Valsalva/left coronary sinus, and travels between the left atrial appendage and the pulmonary trunk in the left atrioventricular groove. It bifurcates early into the left anterior descending artery (LAD), which continues in the interventricular groove, and the left circumflex which continues laterally in the atrioventricular groove.

The LAD travels over the anterior aspect of the heart in the interventricular groove, it turns around the inferior border to anastomose with the posterior descending branch of the right coronary artery. The LAD gives off septal and diagonal branches.

The left circumflex travels down the posterior aspect of the heart and gives off obtuse marginal and atrial branches **(Figure 2.2)**.

The LCA supplies:

- The left atrium
- Most of the left ventricle
- Part of the right ventricle
- Most of the interventricular septum, including the bundle of His
- The sinoatrial node (in 40% of people)

Moore KL, Dalley AF, Agur AMR. Clinically Oriented Anatomy, 6th edition. Philadelphia: Lippincott Williams & Wilkins, 2009:135–165.

Weir J, Abrahams P. Imaging Atlas of Human Anatomy, 4th edition. Edinburgh: Mosby, 2010:113.

Ryan S, McNicholas M, Eustace SJ. Anatomy for Diagnostic Imaging, 3rd edition. Edinburgh: Saunders, 2010:135.

Case 2.13

A Right coronary artery

B Posterolateral branch

C Right ventricular branch

JAYPEE BROTHERS

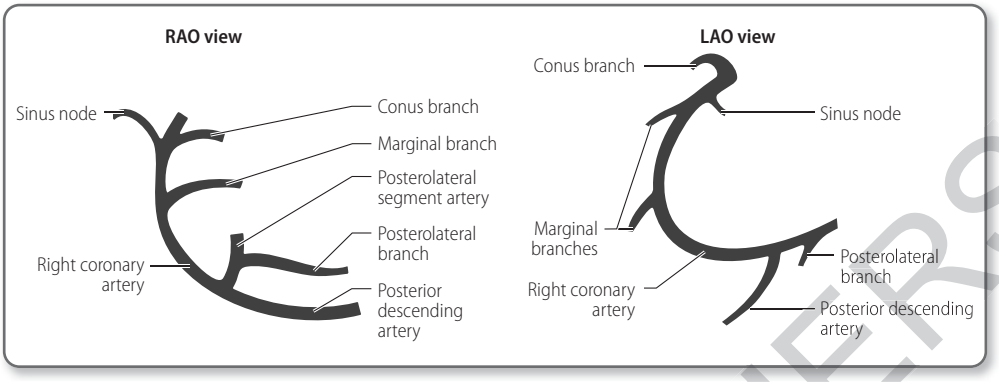

Figure 2.3 The right coronary artery.

D Atrioventricular nodal artery

E Posterior descending artery

Conventional coronary angiogram, left anterior oblique. Selective catheterisation of right coronary artery.

The right coronary artery (RCA) arises from the anterior sinus of Valsalva/right coronary sinus and travels between the right atrium and pulmonary trunk in the right atrioventricular groove. The sinoatrial nodal branch, given off near the origin of the RCA, supplies the sinoatrial node. The marginal branch supplies the right border of the heart. The RCA continues to the posterior aspect of the heart where it gives off the posterior descending artery (PDA). The dominance of the coronary system is defined by which coronary supplies the PDA **(Figure 2.3)**.

The RCA supplies:

- The right atrium
- Most of the right ventricle
- The diaphragmatic surface of the left ventricle
- Part of the atrioventricular septum
- The sinoatrial node (in 60% of people)
- The atrioventricular node (in 80% of people)

Moore KL, Dalley AF, Agur AMR. Clinically Oriented Anatomy, 6th edition. Philadelphia: Lippincott Williams & Wilkins, 2009:135–165.

Weir J, Abrahams P. Imaging Atlas of Human Anatomy, 4th edition. Edinburgh: Mosby, 2010:113.

Ryan S, McNicholas M, Eustace SJ. Anatomy for Diagnostic Imaging, 3rd edition. Edinburgh: Saunders, 2010:135.

Case 2.14

A Right subclavian artery

B Brachiocephalic artery

C Right vertebral artery

JAYPEE BROTHERS

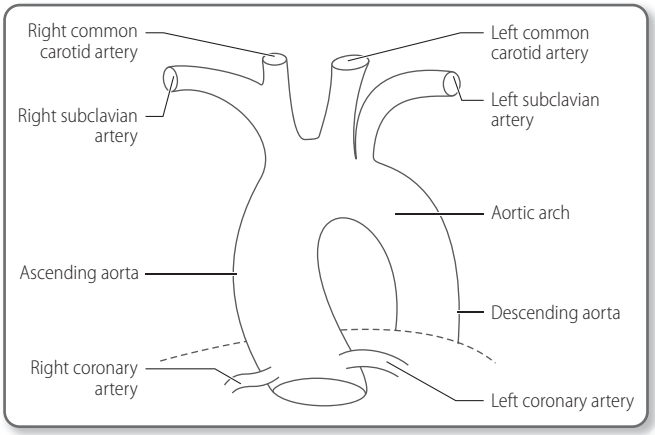

Figure 2.4 Branches of the arch of the aorta.

D Left common carotid artery

E Left subclavian artery

Digital subtraction arch aortogram.

The common pattern for the branches of the arch of the aorta **(Figure 2.4)** is:

- Brachiocephalic trunk, which gives off the right subclavian and right common carotid arteries
- Left common carotid artery
- Left subclavian artery

Moore KL, Dalley AF, Agur AMR. Clinically Oriented Anatomy, 6th edition. Philadelphia: Lippincott Williams & Wilkins, 2009:94.

Weir J, Abrahams P. Imaging Atlas of Human Anatomy, 4th edition. Edinburgh: Mosby, 2010:117.

Case 2.15

A Right internal mammary/thoracic artery

B Thymus

C Ascending aorta

D Main pulmonary artery

E Left main bronchus

Axial arterial phase CT chest in a paediatric patient.

The internal mammary/thoracic arteries originate from the subclavian arteries, and enter the thorax behind the clavicle and first costal cartilage. They run along the inside of the thoracic wall just lateral to the sternum, to the sixth intercostal space where they divide into the superior epigastric and musculophrenic arteries.

The thymus is a soft structure of the lymphatic system which sits in the anterior mediastinum. It has left and right lobes, and on CT it is a homogenous soft-tissue density.

JAYPEE BROTHERS

The thymus normally involutes by around age 8, but may be seen as a small remnant of anterior mediastinal soft tissue on CT in adults.

Moore KL, Dalley AF, Agur AMR. Clinically Oriented Anatomy, 6th edition. Philadelphia: Lippincott Williams & Wilkins, 2009:135–165.

Weir J, Abrahams P. Imaging Atlas of Human Anatomy, 4th edition. Edinburgh: Mosby, 2010:99.

Case 2.16

A Left atrium

B Posterior leaflet of the mitral vale

C Fundus of the stomach

D Aortic valve

E Left ventricle

Three-chamber view gated cardiac CT.

This view includes the left atrium, left ventricle and the proximal aorta as its 'three chambers'. It is also known as the left ventricular outflow tract view, as is reformatted into a plane which includes the left ventricle apex and both the mitral and aortic valves.

The mitral valve is also known at the bicuspid valve, as it has two leaflets–anterior and posterior. In this image, although off axis for the usual axial plane, the vertebral body and sternum can still be seen, helping to orientate which is the anterior leaflet and which is posterior.

Case 2.17

A Thyrocervical trunk

B Catheter in left subclavian artery

C Ascending cervical artery

D Left vertebral artery

E Left internal thoracic artery

Selective catheterisation and angiogram of the left subclavian artery.

The branches of the subclavian artery (shown in **Figure 2.5**) can be recalled with the mnemonic VITamin C and D.

The first part (from origin to medial border of scalenus anterior):

- *Vertebral artery:* Runs in the foramen transversarium of the vertebra to supply the posterior circulation of the brain
- *Internal thoracic artery:* Runs along the inside of the thoracic cage
- *Thyrocervical trunk:* It is short in length and quickly divides into inferior thyroid, suprascapular and transverse cervical arteries

The second part (posterior to scalenus anterior):

- *Costocervical trunk:* Divides into superior intercostal and deep cervical arteries

JAYPEE BROTHERS

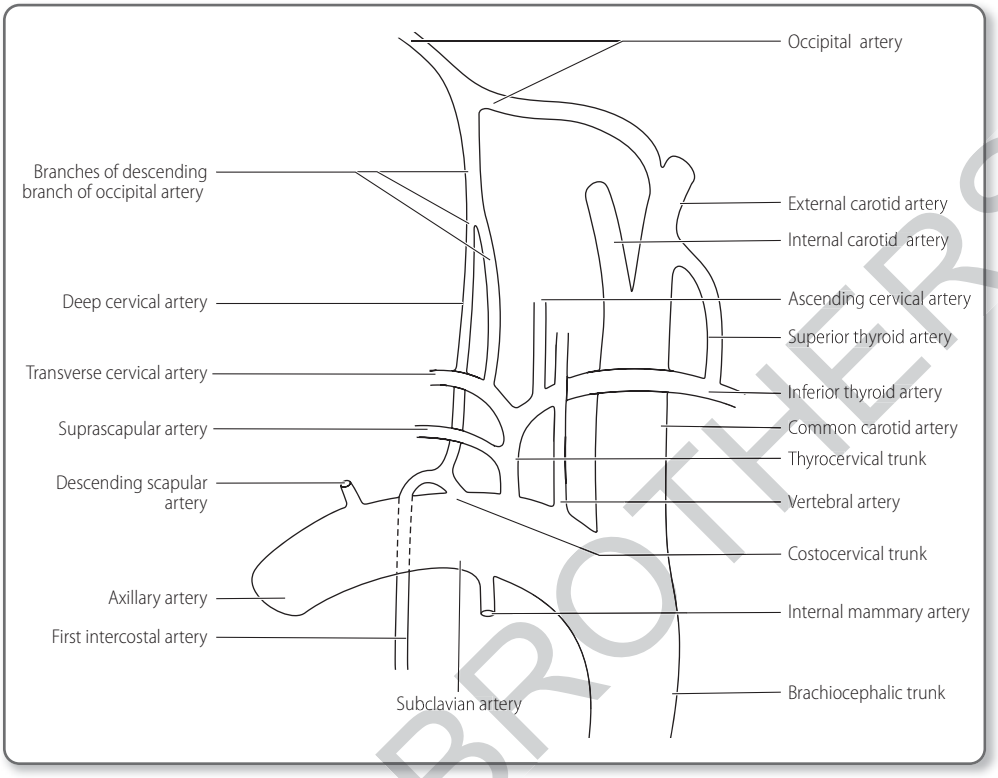

Figure 2.5 Branches of the subclavian artery.

The third part (between scalenus anterior and first rib):

- Dorsal scapular artery, which may also originate from the second part of subclavian. This supplies the levator scapulae and rhomboid muscles

Moore KL, Dalley AF, Agur AMR. Clinically Oriented Anatomy, 6th edition. Philadelphia: Lippincott Williams & Wilkins, 2009:1003.

Weir J, Abrahams P. Imaging Atlas of Human Anatomy, 4th edition. Edinburgh: Mosby, 2010:33.

Case 2.18

A Brachiocephalic artery

B Left common carotid artery

C Left subclavian artery

D Coeliac axis

E Superior mesenteric artery

MR angiogram.

An MR angiogram showing the great vessels of the aorta. The first two unpaired abdominal aortic branches are the coeliac axis and the superior mesenteric artery.

Ryan S, McNicholas M, Eustace SJ. Anatomy for Diagnostic Imaging, 3rd edition. Edinburgh: Saunders, 2010:142.

JAYPEE BROTHERS

Case 2.19

A Sternum

B Right coronary artery

C Anterior sinus of Valsalva/right aortic sinus

D Left atrium

E Left inferior pulmonary artery

Axial CT of the chest.

The sternum consists of three fused bones: manubrium, body of sternum and xiphoid process. Superiorly, the junction of the manubrium with the body of sternum is called the 'Angle of Louis'. This is at the level of T4/T5, where the second rib articulates. This is the same level as the aortic arch and the carina.

The right coronary artery (RCA) arises from the anterior sinus of Valsalva/right aortic sinus and travels between the right atrium and pulmonary trunk in the right atrioventricular groove. The RCA supplies:

- The right atrium
- Most of the right ventricle
- The diaphragmatic surface of the left ventricle
- Part of the atrioventricular septum
- The sinoatrial node (in 60% of people)
- The atrioventricular node (in 80% of people)

The left main pulmonary artery runs superoposteriorly, and arches over the left main bronchus before entering the hilum. At this point, it branches into its lobar branches.

Moore KL, Dalley AF, Agur AMR. Clinically Oriented Anatomy, 6th edition. Philadelphia: Lippincott Williams & Wilkins, 2009:135–165.

Weir J, Abrahams P. Imaging Atlas of Human Anatomy, 4th edition. Edinburgh: Mosby, 2010:99.

Ryan S, McNicholas M, Eustace SJ. Anatomy for Diagnostic Imaging, 3rd edition. Edinburgh: Saunders, 2010:139.

Case 2.20

A Trachea

B Right upper lobe bronchus

C Bronchus intermedius

D Left clavicle

E Carina

Coronal reformatted CT of the thorax.

The trachea begins at C6 level at the lower border of the cricoid cartilage. The trachea is approximately 15 cm long, 2 cm in diameter, and made of 15–20 incomplete rings of cartilage which are completed posteriorly by the trachealis

JAYPEE BROTHERS

muscle. The lower trachea is supplied by branches of the bronchial artery. The upper trachea is supplied by the inferior thyroid artery. The arch of the aorta may indent the left side of the trachea just above the carina.

Weir J, Abrahams P. Imaging Atlas of Human Anatomy, 4th edition. Edinburgh: Mosby, 2010:102.

Ryan S, McNicholas M, Eustace SJ. Anatomy for Diagnostic Imaging, 3rd edition. Edinburgh: Saunders, 2010:122–125.

Case 2.21

A Horizontal fissure

B Middle lobe bronchus

C Oblique fissure

D Right lower lobe bronchus

E Left lower lobe bronchus

High-resolution CT (HRCT).

The fissures are well demonstrated on HRCT. The oblique fissures appear as:

- Thin curvilinear lines which are concaved anteriorly in the upper thorax
- Flat lines in the midthorax
- Convex anterior lines in the lower chest

The horizontal fissure is seen as an avascular zone in the midthorax **(Figure 2.6)**.

Ryan S, McNicholas M, Eustace SJ. Anatomy for Diagnostic Imaging, 3rd edition. Edinburgh: Saunders, 2010:122.

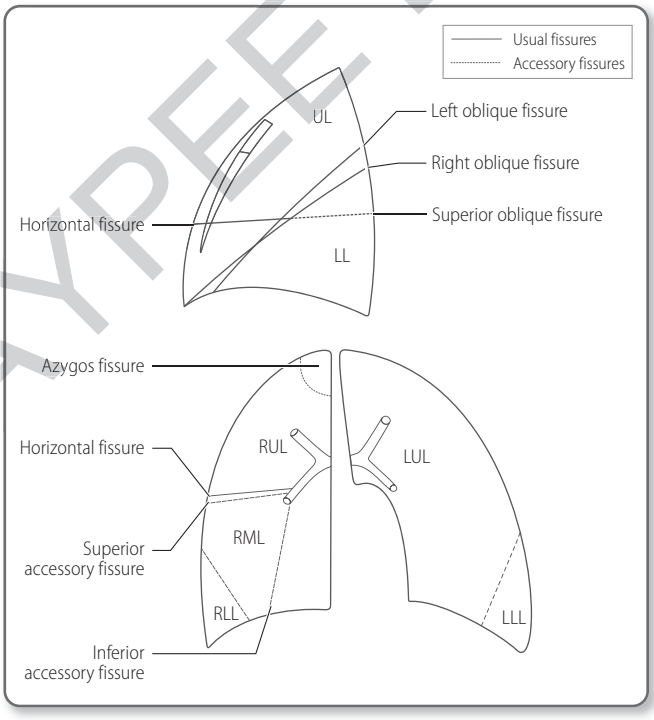

Figure 2.6 The pulmonary lobes and fissures. UL, upper lobe; ML, middle lobe; LL, lower lobe; RUL, right upper lobe; RML, right middle lobe; RLL, right lower lobe; LUL, left upper lobe; LLL, left lower lobe.

JAYPEE BROTHERS

Case 2.22

A Paratracheal stripe

B Right hilar point

C Right costophrenic angle

D Left coracoid process

E Descending thoracic aorta

Chest radiograph.

The paratracheal stripe is normally <3–4 mm wide and formed by the pleura in contact with the right lateral wall of the trachea. The pleura is in contact with the trachea from the clavicles down to the azygous vein at the right tracheobronchial angle. The left lateral wall of the trachea is not normally distinguishable from the mediastinum.

The left coracoid process projects anteriorly from the upper border of the neck of the scapula.

Most lung markings are due to vessels. The hilar point is where the superior pulmonary vein crosses the descending pulmonary artery. The right is 1 cm lower than the left, and is projected over the sixth posterior interspace. The angle between the vessels at the hilar point (hilar angle) is normally 120°.

Weir J, Abrahams P. Imaging Atlas of Human Anatomy, 4th edition. Edinburgh: Mosby, 2010:90.

Ryan S, McNicholas M, Eustace SJ. Anatomy for Diagnostic Imaging, 3rd edition. Edinburgh: Saunders, 2010:120.

Weber E, Netter FH, Vilensky JA, Carmichael SW. Netter's Concise Radiologic Anatomy. Philadelphia: Saunders/Elsevier, 2009:183.

Case 2.23

A Left upper lobe

B Left lower lobe

C Left oblique fissure

D Left anterior hemidiaphragm

E Stomach with gastric contents

Sagittal reformatted high-resolution CT.

The left upper lobe is anterior and superior to the left lower lobe. The left oblique fissure separates the two lobes, and travels from T4/T5 posteriorly to the diaphragm anteroinferiorly.

The stomach is situated just inferior to the left hemidiaphragm, which is demonstrated well here.

Ryan S, McNicholas M, Eustace SJ. Anatomy for Diagnostic Imaging, 3rd edition. Edinburgh: Saunders, 2010:125–126.

JAYPEE BROTHERS

Case 2.24

A Right upper lobe

B Horizontal fissure

C Middle lobe

D Right oblique fissure

E Right lower lobe

Sagittal reformatted high-resolution CT.

The right upper lobe is superior and anterior. The middle lobe sits anterior and inferior, and the right lower lobe sites posterior and inferior. The right oblique fissure follows a similar course to the left oblique fissure.

The horizontal fissure travels from the hilum laterally at the level of the 4th costal cartilage. It meets the oblique fissure posteriorly in the midaxillary line at the level of the sixth rib. It is absent in 10% of people and complete in only 30%.

Ryan S, McNicholas M, Eustace SJ. Anatomy for Diagnostic Imaging, 3rd edition. Edinburgh: Saunders, 2010:125–126.

Case 2.25

A Medial segment of middle lobe bronchus

B Middle lobe bronchus

C Right lower lobe bronchus

D Sternum

E Left scapula

Axial contrast enhanced CT chest.

Bronchus intermedius bifurcates to give rise to the middle and lower lobar bronchi (middle lobe = medial and lateral segments). The middle lobe bronchus has two branches the medial and lateral segmental bronchi. The right lower lobe branches into five segmental bronchi, the superior, medial basal, anterior, lateral basal and posterior basal.

Case 2.26

A Right atrial border

B Azygos fissure

C Anatomical neck of right humerus

D Superior vena cava

E Acromion of right scapula

JAYPEE BROTHERS

Shoulder radiograph.

The azygos fissure is a normal variant. The azygos vein travels through the right apical lobe, where it has four pleural layers: two parietal and two visceral.

The anatomical neck of the humerus separates the greater and lesser tuberosities. The surgical neck is the narrow area of shaft just inferior to the tuberosities and anatomical neck. The surgical neck is fractured more frequently than the anatomical neck, and the axillary nerve is at risk here.

The acromion articulates with the clavicle at the acromioclavicular joint to help to provide stability to the shoulder joint.

Ryan S, McNicholas M, Eustace SJ. Anatomy for Diagnostic Imaging, 3rd edition. Edinburgh: Saunders, 2010:125–126.

Moore KL, Dalley AF, Agur AMR. Clinically Oriented Anatomy, 6th edition. Philadelphia: Lippincott Williams & Wilkins, 2009:114.

Case 2.27

A Right fourth rib

B T9 vertebral body

C Sternum (ossification centre)

D Left humerus diaphysis

E Left hemidiaphragm

Left lateral oblique paediatric chest radiograph.

These views are most commonly performed as part of skeletal surveys and sometimes for suspected rib abnormalities. Prior to complete fusion between 6 and 12 years of age, the sternum exists as multiple rounded ossification centres. This is important to recognise, because sometimes these rounded ossification centres can each line up and project over ribs on oblique projections and mimic a row of healing rib fractures.

Weir J, Abrahams P. Imaging Atlas of Human Anatomy, 4th edition. Edinburgh: Mosby, 2010:90.

Ryan S, McNicholas M, Eustace SJ. Anatomy for Diagnostic Imaging, 3rd edition. Edinburgh: Saunders, 2010:120.

Case 2.28

A Right main pulmonary artery

B Right hemidiaphragm

C Stomach bubble

D Left hemidiaphragm

E Right ventricle

Plain lateral chest radiograph.

JAYPEE BROTHERS

The right diaphragm is usually higher than the left, and you can see the heart through it, i.e. the heart therefore cannot be in contact with it. The inferior vena cava may be seen to pass through the right diaphragm.

Aerated lung is adjacent to the right hemidiaphragm and therefore its contour is visible from its posterior to anterior aspects.

The left diaphragm is usually lower than the right and the heart is in contact with it, i.e. the heart is sitting on the left diaphragm and the gastric bubble can be seen to lie below it.

The right ventricle is the most anterior chamber of the heart. It is crescent shaped, and has a thinner wall than the larger, more muscular left ventricle. The left ventricle is so large that it bulges into the right ventricle, giving it its crescent shape. Inflow is from the right atrium via the tricuspid valve (three leaflets). Outflow is into the pulmonary artery via the pulmonary valve.

Weir J, Abrahams P. Imaging Atlas of Human Anatomy, 4th edition. Edinburgh: Mosby, 2010:91.

Ryan S, McNicholas M, Eustace SJ. Anatomy for Diagnostic Imaging, 3rd edition. Edinburgh: Saunders, 2010:121.

Weber E, Netter FH, Vilensky JA, Carmichael SW. Netter's Concise Radiologic Anatomy. Philadelphia: Saunders/Elsevier, 2009:203.

Case 2.29

A Left atrial border

B Left scapula

C Trachea

D Right eighth rib

E Body of sternum

Plain lateral chest radiograph.

The left atrium forms the left posterior heart border. The left ventricle can be identified as the most posterior and inferior of the cardiac chambers.

The lower trachea is supplied by branches of the bronchial artery. The upper trachea is supplied by the inferior thyroid artery. The arch of the aorta may be seen to indent the left side of the trachea just above the carina.

The sternum consists of three fused bones: manubrium, body of sternum and xiphoid process. Superiorly, the junction of the manubrium with the body of sternum is called the 'Angle of Louis'. This is at the level of T4/T5, where the 2nd rib articulates. This is the same level as the aortic arch and the carina.

In order to ascertain which rib is labelled, one can use the 'big rib sign'. On a well-positioned left lateral chest radiograph, the left ribs are in contact with the film. The right ribs are farther from the film than the left, and are therefore magnified and look bigger.

JAYPEE BROTHERS

Weir J, Abrahams P. Imaging Atlas of Human Anatomy, 4th edition. Edinburgh: Mosby, 2010:91.

Ryan S, McNicholas M, Eustace SJ. Anatomy for Diagnostic Imaging, 3rd edition. Edinburgh: Saunders, 2010:121.

Kurihara Y, Yakushiji YK, Matsumoto J, et al. The ribs: anatomic and radiologic considerations. Radiographics 1999; 19:105–119.

Case 2.30

A T4 vertebral body

B Right 5th rib

C Left lower lobe pulmonary artery

D Left lower lobe pulmonary vein

E Left crus of the diaphragm

Coronal CT pulmonary angiogram of the thorax.

This is a posterior section as the vertebral bodies and the aorta can be seen. There is contrast in the pulmonary arteries and thus they are of higher attenuation than the aorta.

Bony structures A and B are easily recognised as a vertebral body and a rib. It is of paramount importance not to rush into writing these answers down; the number and laterality of the ribs must be given. Forgetting to include these details will cost precious points. In this case, the first rib can be seen and the numbers of the labelled structures can be determined by counting down. If you cannot find anything that helps to determine the number of a labelled vertebral body, simply indicate whether it is cervical, thoracic or lumbar.

The branching of the pulmonary arteries closely follows the branching of the airways; this is not the case with the branching of the pulmonary veins. Remembering this fact will prevent mistaking pulmonary arteries for veins.

The main divisions of the pulmonary trunk are the right and left pulmonary arteries. At the left hilum, the left pulmonary artery divides into the upper and lower lobe branches.

Weir J, Abrahams P. Imaging Atlas of Human Anatomy, 4th edition. Edinburgh: Mosby, 2010:110–111.

Ryan S, McNicholas M, Eustace SJ. Anatomy for Diagnostic Imaging, 3rd edition. Edinburgh: Saunders, 2010:126–127.

Weber E, Netter FH, Vilensky JA, Carmichael SW. Netter's Concise Radiologic Anatomy. Philadelphia: Saunders/Elsevier, 2009:205.

Case 2.31

A Right internal thoracic artery/mammary artery

B Right main bronchus

C Pulmonary trunk/main pulmonary artery

JAYPEE BROTHERS

D Costotransverse joint on the right

E Left erector spinae

Axial CT of the chest.

This is an axial section through the thorax at the level of the pulmonary trunk division. The pulmonary trunk begins at the pulmonary valve inferior to the level seen here. At first, it lies anterior to the aorta and then passes to its left to lie in the concavity of the arch where it divides.

The internal thoracic/internal mammary artery arises from the subclavian artery near its origin. It is a paired artery that supplies the anterior chest wall and the breast. It divides into the superior epigastric and musculophrenic arteries.

The facet of the tubercle of the rib forms an articulation with the transverse process of the vertebra. This is called the costotransverse joint. It is not possible to assign a number to the costotransverse joint in this image as there are no solid landmarks to count from. Therefore, only laterality can be indicated.

The erector spinae is a large muscular and tendinous mass which acts as an extensor of the spine. Its superior part attaches to the transverse processes of the lumbar vertebra and the 11th and 12th rib.

Weir J, Abrahams P. Imaging Atlas of Human Anatomy, 4th edition. Edinburgh: Mosby, 2010:93.

Ryan S, McNicholas M, Eustace SJ. Anatomy for Diagnostic Imaging, 3rd edition. Edinburgh: Saunders, 2010:133.

Case 2.32

A Right pectoralis minor

B Oesophagus

C Left brachiocephalic vein/innominate vein

D Right brachiocephalic trunk/artery

E Left subclavian artery

Axial CT of the thorax.

The pectoralis minor lies beneath the larger pectoralis major. Its attachments are the anterior third to fifth ribs and the coracoid process of the scapula. It lies in the anterior wall of the axilla, and nerves and vessels travel under it to enter the arm. Its functions are to draw the scapula anteriorly and inferiorly to stabilise it against the chest wall, and to elevate the ribs in deep inspiration. It is innervated by the medial pectoral nerve.

The left brachiocephalic trunk, or innominate vein is the common drainage vessel of the left arm and the left of the neck, formed by the left internal jugular vein and left subclavian vein. It courses anterior to the arch vessels to join the right brachiocephalic vein to become the superior vena cava. This is why the IV contrast

JAYPEE BROTHERS

injection should be in the right arm for a CT angiogram aorta, as high-density contrast draining centrally via the left brachiocephalic vein may cause streak artefact that obscures the arch and its branch vessels.

Moore KL, Dalley AF, Agur AMR. Clinically Oriented Anatomy, 6th edition. Philadelphia: Lippincott Williams & Wilkins, 2009:709.

Weir J, Abrahams P. Imaging Atlas of Human Anatomy, 4th edition. Edinburgh: Mosby, 2010:96.

Ryan S, McNicholas M, Eustace SJ. Anatomy for Diagnostic Imaging, 3rd edition. Edinburgh: Saunders, 2010:153.

Case 2.33

A Pericardium

B Right lobe of liver

C Inferior vena cava

D Left ventricle

E Left latissimus dorsi

Axial CT of the thorax.

The pericardium is a double-walled sac which is draped over the heart and great vessels and has a visceral and parietal layer. The visceral layer is attached to the myocardium. The parietal layer is loose except superiorly where it is attached to the great vessels, and inferiorly where it is attached to the central tendon of the diaphragm by the pericardiophrenic ligament.

Ryan S, McNicholas M, Eustace SJ. Anatomy for Diagnostic Imaging, 3rd edition. Edinburgh: Saunders, 2010:132.

Moore KL, Dalley AF, Agur AMR. Clinically Oriented Anatomy, 6th edition. Philadelphia: Lippincott Williams & Wilkins, 2009:107.

Case 2.34

A Thymus

B Left cardiophrenic angle

C Ossification centre of left humeral proximal femoral epiphysis.

D Right clavicle

E Left posterior 5th rib

Frontal chest radiograph.

The thymus is hugely variable in size and shape, and because of its soft density, the lateral edges may appear 'wavy' as they conform to the overlying ribs and intercostal spaces. Lung markings may be seen through it, and a normal thymus should never deviate other structures.

Ryan S, McNicholas M, Eustace SJ. Anatomy for Diagnostic Imaging, 3rd edition. Edinburgh: Saunders, 2010:147–148.

JAYPEE BROTHERS

Case 2.35

A Pectoral muscle

B Skin line

C Glandular tissue

D Nipple

E Inframammary fold

Mammogram.

The breast lies on the second to sixth ribs. It consists of fatty and glandular tissue, which is held in place by Cooper's ligaments that attach to skin and underlying pectoralis muscle fascia. It is supplied by the internal mammary artery and the lateral thoracic branch of the axillary artery. Venous drainage follows the arterial supply.

Most of the lymph drainage is to the axillary chain, with 5% draining to the internal mammary chain.

Weir J, Abrahams P. Imaging Atlas of Human Anatomy, 4th edition. Edinburgh: Mosby, 2010:120–122.

Ryan S, McNicholas M, Eustace SJ. Anatomy for Diagnostic Imaging. Edinburgh: Saunders, 2004:313–325.

JAYPEE BROTHERS

First FRCR Anatomy:
Practice Cases

SECOND EDITION

The Second Edition of this popular 'FRCR Part 1 Anatomy Revision Book' is finally here! Written by highly experienced radiology consultants, this book offers comprehensive coverage of key anatomical areas tested on the examination. The 265 high-quality images have been meticulously curated and are accompanied by over 1,200 questions. Cases are arranged in a structured manner by subspecialty area for easy revision, and detailed answers are provided to aid in retaining knowledge. "**First FRCR Anatomy: Practice Cases, 2nd Edition**" is a must-have revision tool for all candidates, crucial for achieving success in the examination.

JP medical publishers

www.jpmedpub.com

ISBN 978-1-78779-179-4