Practical Handbook of OCT

Retina, Choroid & Inflammatory Disorders

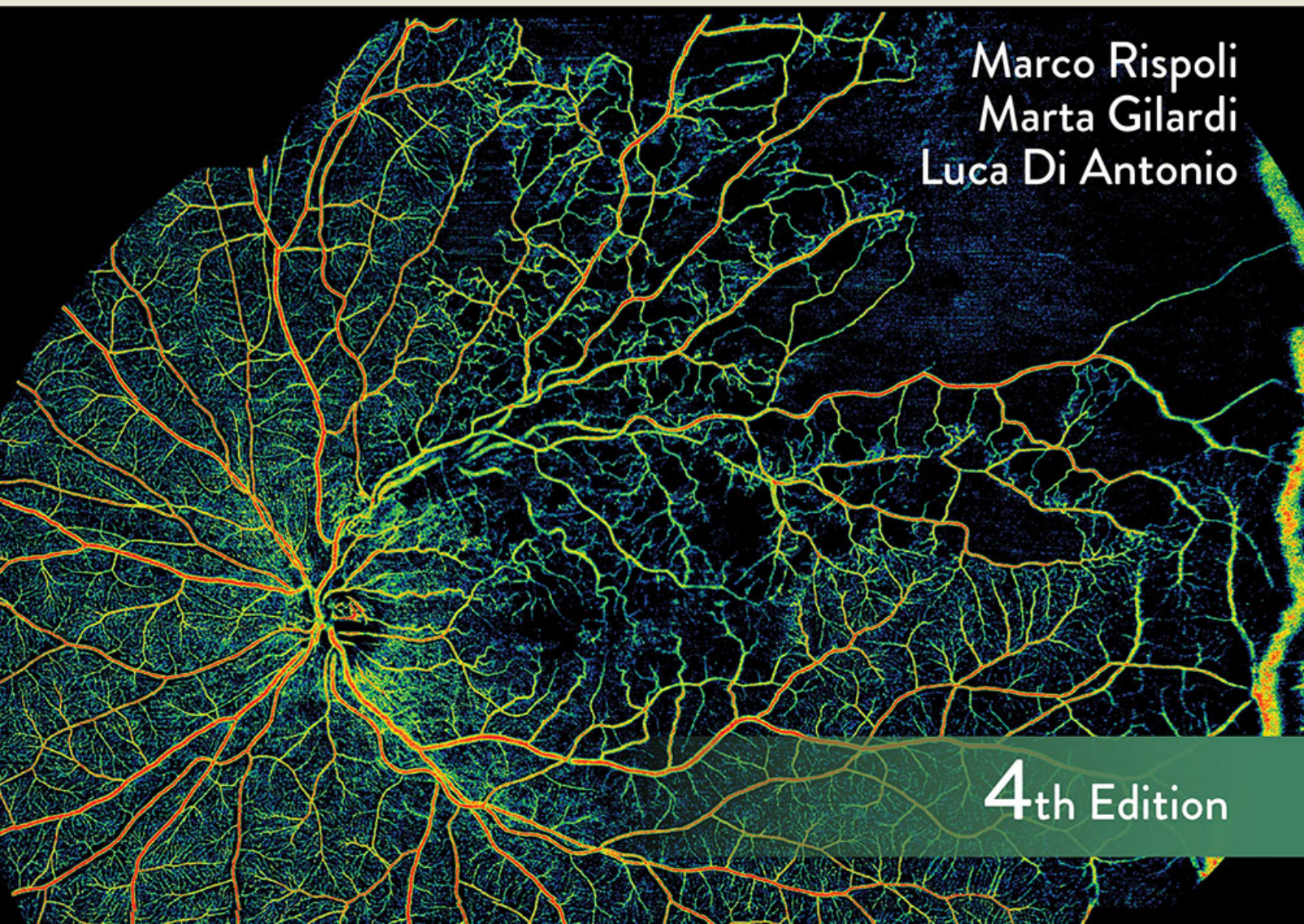

Marco Rispoli
Marta Gilardi
Luca Di Antonio

4th Edition

Contents

Preface to the fourth edition v

Practical handbook presentation ix

Contributors xi

Chapter 1
Practical suggestions for obtaining clear and clinically useful optical coherence tomography images 1
Marco Rispoli

Chapter 2
Basic normal anatomy and optical coherence tomography 5
Marco Rispoli

Chapter 3
Logical method of optical coherence tomography interpretation: Analysis and synthesis 11
Marco Rispoli

Chapter 4
Tridimensional and 'en face' scan analysis 23
Marco Rispoli

Chapter 5
Optical coherence tomography angiography: Interpretation, synthesis, and deduction 31
Marco Rispoli

Chapter 6
Widefield and ultra-widefield optical coherence tomography angiography imaging of retinal vascular disease 37
Luca Di Antonio, Rodolfo Mastropasqua

Chapter 7
Vitreoretinal diseases: Optical coherence tomography/optical coherence tomography angiography 43
Maria Cristina Savastano, Claudia Fossataro, Clara Rizzo, Stanislao Rizzo

Chapter 8
Myopia 57
Barbara Parolini

Chapter 9
Macular disorders 73
Marco Rispoli, Luca Di Antonio

Chapter 10
Pachychoroid spectrum diseases 87
Alessia Di Stefano, Claudia Fossataro, Marta Gilardi

Chapter 11
Inflammatory diseases 97
Marta Gilardi, Marco Rispoli, Massimo Accorinti

Chapter 12
Vascular occlusions 109
Giulia Piccotti, Marco Rispoli

Chapter 13
Diabetic retinopathy 119
Eliana Costanzo, Mariacristina Parravano

Chapter 14
Optical coherence tomography in glaucoma 129
Sara Giammaria, Francesco Oddone

Index 145

Chapter 1 Practical suggestions for obtaining clear and clinically useful optical coherence tomography images

Marco Rispoli

MAYPEE BROTHERS

STANDARD OPTICAL COHERENCE TOMOGRAPHY ANALYSIS

Standard analysis should include both qualitative and quantitative analysis of one- or two-line scans: cross-scan or radial scan centered on the fovea, line scans centered on the area of interest (if not located on the fovea), full retinal map analysis, three-dimensional (3D) analysis, enface analysis and progression analysis.

Gray scale

We recommend studying optical coherence tomography (OCT) images in grayscale (black and white) rather than conventional pseudocolors. This allows for better assessment of subtle variations in gray intensities and reveals details that might otherwise be missed. Negative black and white images can sometimes highlight certain pathological patterns that are difficult to distinguish.

When using color images, the software arbitrarily assigns a color to each degree of reflectivity, leading to exaggerated differences in color and abnormally high contrast where a gradual change in reflectivity is actually present. While this higher contrast can be useful in some cases, it may also obscure details.

Averaging

Multiple cross-section scans averaging is a simple and effective method for improving the quality of OCT retinal images. Approximately 30 or more OCT images of the same area are taken and then automatically overlaid and averaged by the software. All OCT devices employ this technique, which enhances image sharpness and clarity, aiding in the diagnosis and management of retinal diseases. Some devices can average 100 or more images (**Figure 1.1**).

Averaged images provide a clearer view of many pathological conditions, including diffuse retinal edema, cystoid macular edema, retinal hemorrhages, pigment epithelial detachment, choroidal structures, and lesions beneath the pigment epithelium.

Enface scans

Enface technology enables the acquisition and analysis of frontal retinal scans adapted to the natural concavity of the posterior pole of the eye. These frontal or transverse scans are part of the 3D study of the retina. They serve as a valuable complement to conventional cross-sectional B-scan OCT imaging, offering a more intuitive and easier-to-understand perspective. Clinical studies have confirmed the utility of enface OCT scans.

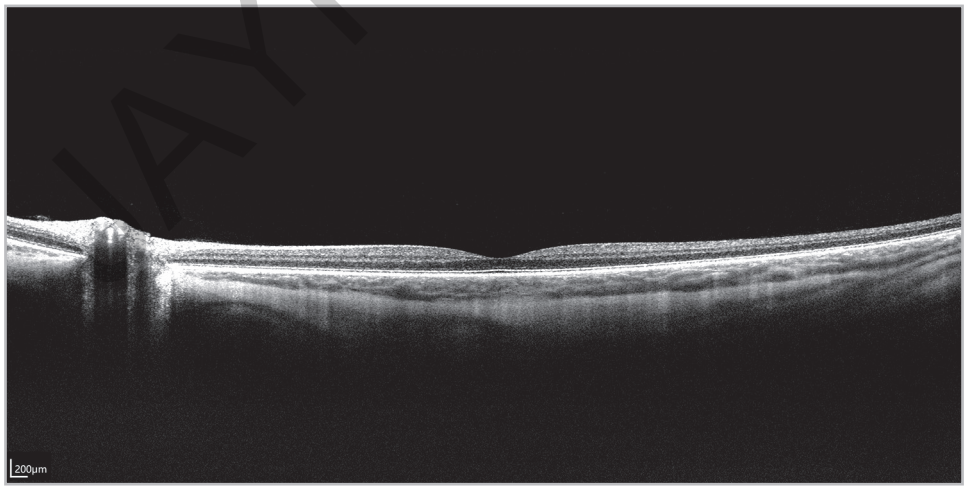

Figure 1.1 *Averaged image:* 100 optical coherence tomography (OCT) images of the same area have been overlaid and averaged by software. This technique significantly enhances image sharpness and clarity, making images more intelligible.

In age-related macular degeneration and central serous chorioretinopathy, frontal scans allow for the study of the dimensions and shape of pigment epithelium detachments and a detailed examination of photoreceptors. They help to assess the shape, thickness and smoothness of retinal layer boundaries.

Enface scans are also useful in white dot syndromes and acute zonal occult outer retinopathy, revealing the shape and ramification of outer retinal and ellipsoid zone (EZ) lesions.

In cases of vitreoretinal interface lesions, epiretinal membranes, and macular holes, frontal enface imaging enables in-vivo identification of the extent and dynamics of epiretinal traction providing images that facilitate understanding of abnormalities in the vitreomacular interface.

OPTICAL COHERENCE TOMOGRAPHY ANGIOGRAPHY SCANS

Since 2014, a new technology, OCT angiography (OCTA), has rapidly gained popularity and replaced invasive fluorescein and indocyanine green angiography (ICGA) in many cases. This method is easy, fast, and noninvasive, has no side effects, and can be repeated multiple times without causing discomfort to patients.

In age-related macular degeneration and central serous chorioretinopathy, OCTA scans allow for the study of the dimensions and shape of new vessels. They have led to new classifications and enable easy follow-up.

In diabetic retinopathy and vascular occlusions, OCTA helps in understanding the type and extent of capillary occlusions, cystoid retinal edema, and nonperfused areas. Widefield OCTA devices allow for comprehensive assessment of the choroid and retinal inflammation.

Enface one-click mode

To simplify and expedite the acquisition and use of enface images, the 'en face one-click mode' (**Figures 1.2a** and **b**) allows for the simultaneous acquisition of several scans: four enface images corresponding to the most clinically important frontal sections and a cross-line scan. The same procedure can be performed for vascular layers in OCTA.

The first enface scan is taken at the retinal surface level and shows retina-vitreous interface alterations. The second is placed

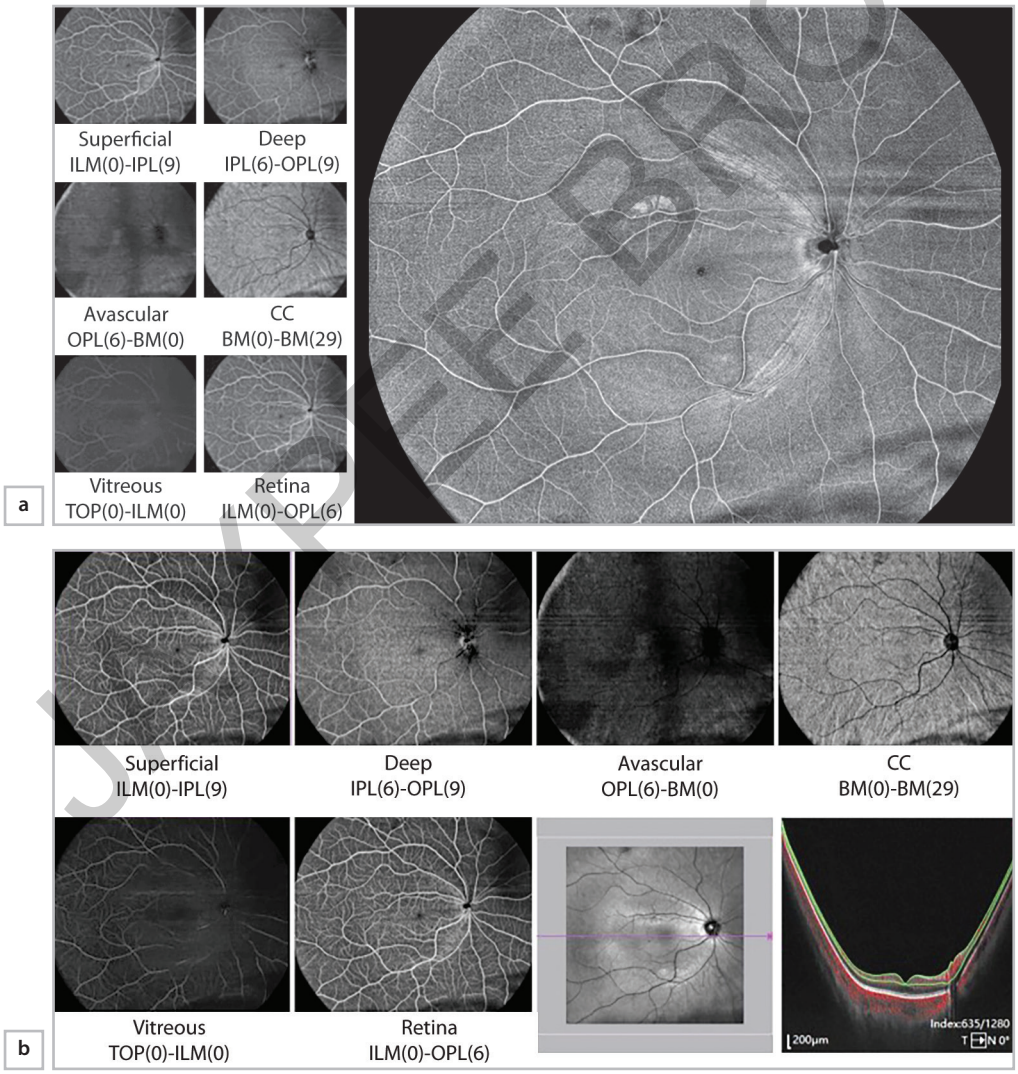

Figure 1.2 (a and b) The OCTA software allows you to acquire eight scans with a single click: six enface angio images, a line scan with boundaries, and a scanning laser ophthalmoscopy (SLO) image of the retina. The enface scans show the superficial capillary plexus (SCP), deep capillary plexus (DCP), outer retina (OR) slab, choriocapillary (CC), pre-retinal vitreous, and whole retina (ILM to OPL or customized scan like choroid). In order to have more details, select a larger image of the structural superficial retina with six miniature angio scans. (BM, Bruch's membrane; ILM, internal limiting membrane; IPL, inner plexiform layer, OPL, outer plexiform layer).

JAYPEE BROTHERS

deeper in the retina and shows diffuse edema, cystoid edema, and exudates. The third enface scan is parallel to the retinal pigment epithelium (RPE) and cuts through drusen and RPE detachments. Ultimately, the fourth scan is placed in the choroid (Ch), parallel to the RPE at the level of Haller's vascular layer, to show choroidal conditions.

The OCT cross-line scan indicates the exact level in the retina of the four frontal scans. This feature allows OCT users to instantly obtain multiple and standardized enface images that are most clinically useful for fine-tuning diagnosis and to determine their exact location in relation to the retinal and choroidal layers.

Segmentation

Optical coherence tomography devices can accurately detect retinal and vascular boundaries in normal retinal layers. Structural and OCTA software is capable of automatically detecting and delineating retinal boundaries, resulting in more accurate retinal thickness maps and aiding in the diagnosis and management of retinal diseases (**Figure 1.3**).

Optical coherence tomography systems can accurately detect retinal boundaries in eyes with some degree of macular edema but may have limitations in eyes with advanced diseases like diabetic retinopathy and age-related macular degeneration. In these cases, boundaries may be incorrectly identified by the software. When there is significant structural loss, manual segmentation can be difficult or impossible, and automated segmentation may be unreliable. It is crucial to understand when segmentation is clinically useful and when it may lead to misdiagnosis. In many cases, manual segmentation by an experienced OCT operator may be necessary. Recently, artificial intelligence (AI) has been introduced to propagate user boundary modifications.

Progression analysis

Progression analysis software is a valuable tool for monitoring disease evolution with or without treatment. Thickness maps can be compared from visit to visit, and it is important to correlate these maps with microperimetry maps. significance map detailing thickness changes provide valuable evaluation data. In OCTA, progression analysis can help to assess treatment efficacy.

ARTIFACTS IN OPTICAL COHERENCE TOMOGRAPHY IMAGING

Optical coherence tomography technology has significantly reduced artifacts in OCT imaging. The rapid acquisition speed (over 40 images per second) and the ability to average images produce clear and well-defined OCT scans. Eye movements and blinking can affect only one or two images within the stack of 30 or more images.

Modern OCT devices exhibit minimal artifacts. Artifacts can still occur in procedures that require longer acquisition times, such as macular maps and 3D scans. These protocols involve acquiring >500 images to create a virtual cube.

Macular cube acquisition typically takes 3–4 seconds. Eye movements or blinking during this time can affect the alignment of scans, leading to artifacts that appear as horizontal notches on the macular cube and may interfere with the accuracy of segmentation and thickness measurements.

If only a few scans are imperfect, manual correction may be possible. However, if multiple scans are affected, it may be necessary to repeat the acquisition. If the patient cannot maintain fixation for 3 seconds, a lower resolution cube can be acquired in 1–2 seconds. This cube is composed of fewer scans (~40–60).

STANDARD OPTICAL COHERENCE TOMOGRAPHY PRINTS

Standard OCT prints should be provided to the referring ophthalmologist along with the OCT report and given to the patient. Prints should include at least one cross-scan centered on the fovea, one or more-line scans centered on the area of interest (if not located on the fovea), a full retinal map analysis, and enface angio and structural analyses. When possible, progression analysis maps can aid in follow-up. Standard OCT prints should always be accompanied by a detailed OCT report.

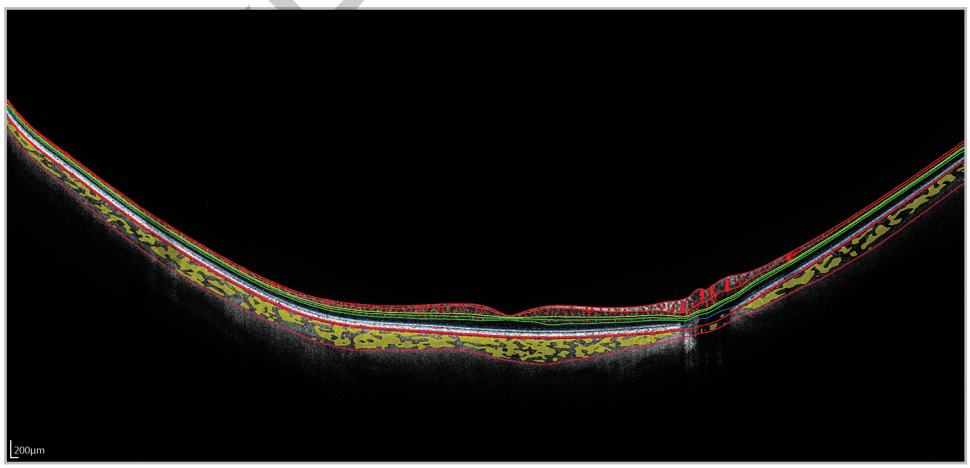

Figure 1.3 *Segmentation:* The Swept Source 400 KHz optical coherence tomography angiography (OCTA) device automatically detects retinal and choroidal boundaries, leading to easier diagnosis and management of retinal diseases at their onset. In this scan, eight boundary lines have been selected.

PEP BROTHERS

SUGGESTED READINGS

1. Bayer A, Akman A. Artifacts and Anatomic Variations in Optical Coherence Tomography. Turk J Ophthalmol 2020; 50:99–106.
2. Brar M, Bartsch DU, Nigam N, et al. Colour versus grey-scale display of images on high-resolution spectral OCT. Br J Ophthalmol 2009; 93:597–602.
3. Dabir S, Bhatt V, Bhatt D, et al. Need for manual segmentation in optical coherence tomography angiography of neovascular age-related macular degeneration. PLoS One 2020; 15:e0244828.
4. De Bats F, Wolff B, Vasseur V, et al. "En-face" spectral-domain optical coherence tomography findings in multiple evanescent white dot syndrome. J Ophthalmol 2014; 2014:928028.
5. Gupta V, Gupta A, Dogra HR. Optical Coherence Tomography of Macular Diseases. New Delhi: Jaypee Brothers Medical Publishers (P) Ltd., 2004.
6. Lumbroso B, Rispoli M, Savastano MC. Practical Handbook of OCT (Retina, Choroid, Glaucoma), 3rd Edition. New Delhi: Jaypee Brothers Medical Publishers (P) Ltd, 2021.
7. Schuman JS, Puliafito CA, Fujimoto JG. Everyday OCT: A Handbook for Clinicians and Technicians. Thorofare NJ: Slack Inc., 2006.
8. Schuman JS, Puliafito CA, Fujimoto JG. Optical Coherence Tomography of Ocular Diseases Thorofare NJ: Slack Inc., 2004.
9. Spaide RF, Fujimoto JG, Waheed NK, Sadda SR, Staurenghi G. Optical coherence tomography angiography. Prog Retin Eye Res 2018; 64:1–55.

JAYPEE BROTHERS

Practical Handbook of OCT

Retina, Choroid & Inflammatory Disorders

This practical handbook offers a concise yet comprehensive guide to Optical Coherence Tomography (OCT) and Optical Coherence Tomography Angiography (OCTA), emphasising their combined role in diagnosing retinal pathologies. With OCTA increasingly replacing dye-based angiography, its clinical relevance is thoroughly addressed through a user-friendly, application-focussed approach. Designed for ophthalmologists, residents, and allied eye care professionals, the book serves as an essential reference for mastering modern retinal imaging.

Marco Rispoli MD is a Medical Retina Specialist and works in the Emergency and Surgical Ophthalmology Department at Rome Eye Hospital. He is the Chief of the Centro Italiano Macula in Rome, Italy and is actively involved in the diagnosis and management of complex retinal disorders.

Marta Gilardi MD is a Uveitis and Medical Retina Specialist working in the Medical Retina Unit of the Emergency and Surgical Ophthalmology Department at Rome Eye Hospital. She is also associated with the Centro Italiano Macula, Rome, Italy, and has a keen interest in inflammatory and degenerative retinal diseases.

Luca Di Antonio MD PhD is a Medical Retinal Specialist working in the Medical Retinal Unit of the Ophthalmology and Surgical Department at ASL-1 Avezzano-Sulmona-L'Aquila, Italy. He is a co-investigator in several clinical trials adherent to the principles of good clinical practices (GCPs). With clinical, research, and academic expertise, he contributes significantly to the retinal field.

JP medical publishers

www.jpmedpub.com

ISBN 978-1-78779-186-2