4TH EDITION

Moorfields Manual of Ophthalmology

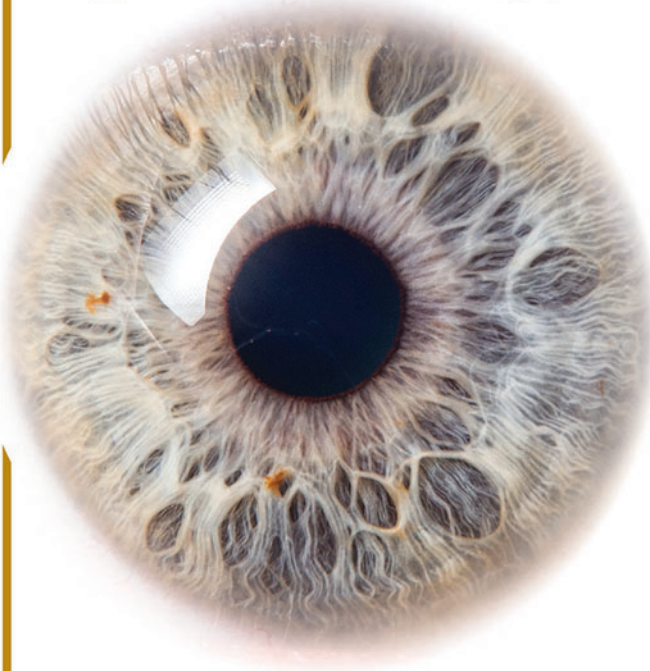

Edited by Timothy L Jackson

CONTENTS

Preface v
Contributing authors xv
Contributors to First, Second and Third Edition xviii
Acknowledgements xxi
Dedication xxii

CHAPTER 1: TRIAGE
Ronald Kam

Acute, painful loss of vision 1
Gradual loss of vision 3
Red eye 4
Eye discomfort or foreign body sensation 5
White painful eye 6
Double vision (diplopia) 7
Dangerous diplopia 8
Extra things in the visual field 9

CHAPTER 2: OCULOPLASTICS
David H Verity & Michelle Khan

Eyelid anatomy revision 11
History 15
Examination 18
Ectropion 21
Floppy eyelid syndrome 26
Lower lid entropion 28
Upper lid entropion 31
Trichiasis 32
Distichiasis 34
Facial nerve palsy 35
Ptosis 39
Chalazion 42
Necrotising fasciitis 44
Benign lid lesions 45
Neoplastic lid lesions 53
Facial dystonias 60
Congenital eyelid disease 63
Eyelid trauma 66
Optometry and general practice guidelines 69

CHAPTER 3: LACRIMAL
Thomas G Hardy & Geoffrey E Rose

The watery eye 71
Dacryocystorhinostomy 79
Lester Jones' canalicular bypass tube 83
Congenital nasolacrimal duct obstruction 84
Canaliculitis 86
Acute dacryocystitis/lacrimal sac abscess 87
Lacrimal drainage system tumours 88
Optometry and general practice guidelines 89

CHAPTER 4: ORBIT
Thomas G Hardy & Geoffrey E Rose

Anatomy 91
History and examination 93
Investigations 96
Congenital disorders 98
Thyroid eye disease 102
Cellulitis 107
Idiopathic orbital inflammatory disease 111
Dacryoadenitis 113
Orbital myositis 115
Superior orbital fissure syndrome (Tolosa-Hunt syndrome) 117
Orbital vascular lesions 118
Orbital lymphoproliferative disorders 122
Lacrimal gland tumours 124
Rhabdomyosarcoma 126
Solitary fibrous tumour 126
Orbital trauma 127
Eye socket disorders 131
Procedures (enucleation and evisceration) 133
Optometry and general practice guidelines 135

CHAPTER 5: EXTERNAL EYE DISEASE
Guy T Smith & Su-yin Koay

Conjunctival anatomy 137
History and examination 137
Anterior blepharitis 141
Posterior blepharitis 143
Ocular rosacea 148
Bacterial conjunctivitis 150
Adenoviral keratoconjunctivitis 153

Chlamydial conjunctivitis 156
Acute, seasonal and perennial allergic conjunctivitis 159
Vernal keratoconjunctivitis 161
Atopic keratoconjunctivitis 165
Giant papillary conjunctivitis
(including contact lens-associated papillary conjunctivitis) 167
Drop toxicity/ocular surface medicamentosa
(contact hypersensitivity and toxic conjunctivitis) 169
Stevens–Johnson syndrome – toxic epidermal necrolysis spectrum 171
Mucous membrane pemphigoid 174
Subconjunctival haemorrhage 178
Superior limbic keratoconjunctivitis 179
Miscellaneous conditions of the conjunctiva 181
Chemical injury 183
Optometry and general practice guidelines 186

CHAPTER 6: CORNEA
Guy T Smith, Su-yin Koay & Jennifer McMahon

Anatomy 189
History and examination 190
Investigations 192
Corneal abrasions and foreign bodies 197
Recurrent corneal erosion 200
Persistent epithelial defect 202
Neurotrophic keratitis 205
Dry eye disease 207
Keratoconus 213
Peripheral corneal ulceration and thinning 218
Interstitial keratitis 223
Phlyctenulosis 225
Marginal keratitis 226
Bacterial keratitis 227
Fungal keratitis 231
Acanthamoeba keratitis 234
Herpes simplex keratitis 237
Herpes zoster ophthalmicus (ophthalmic shingles) 241
Thygeson's keratitis 244
Corneal dystrophies 245
Pterygium 255
Band keratopathy 257
Corneal degenerations and deposits 259
Corneal graft rejection 264

Anterior segment trauma 267
Contact lenses 269
Laser refractive surgery 277
Optometry and general practice guidelines 281

CHAPTER 7: CATARACT SURGERY
Yashin Ramkissoon, Alex Ionides, Carol Cunningham & Alexander Day

Background 283
Biometry 287
Management of astigmatism 291
Presbyopia correction 296
Local anaesthesia 298
Basic surgical techniques 302
Difficult cases 315
Intraoperative complications 322
Postoperative complications 330
Femtosecond laser-assisted phacoemulsification surgery 334
Optometry and general practice guidelines 336

CHAPTER 8: GLAUCOMA
David L Lunt, Anthony Khawaja & Peng T Khaw

Background 339
History 340
Intraocular pressure 341
Gonioscopy 343
Optic disc examination 346
Interpreting humphrey visual field tests 348
Primary open-angle glaucoma 350
Primary angle-closure 353
Pseudoexfoliation syndrome 357
Pigment dispersion syndrome 359
Neovascular glaucoma 361
Uveitic glaucoma 363
Steroid pressure response and associated glaucoma 364
Phacolytic and phacomorphic glaucoma 365
Traumatic glaucoma 367
Glaucoma following vitreoretinal surgery 369
Aqueous misdirection (malignant glaucoma) 371
Congenital glaucoma 374
Selective laser trabeculoplasty 377
Pharmacology of intraocular pressure-lowering drugs 378
Minimally invasive glaucoma surgery 381

Trabeculectomy I: Surgical technique 385
Trabeculectomy II: Postoperative care 390
Bleb-related infection 392
Glaucoma drainage implants 394
Trans-scleral cyclodiode laser treatment 396
Optometry and general practice guidelines 397

CHAPTER 9: UVEITIS
Sue L Lightman & Avi Gurbaxani

History and examination 399
Acute anterior uveitis 401
Chronic anterior uveitis 405
Intermediate uveitis 407
Posterior uveitis 410
Sarcoidosis 416
Tuberculosis 418
Syphilis 420
Behcet disease 422
Vogt–Koyanagi–Harada syndrome 424
Sympathetic ophthalmia 426
White dot syndromes 428
AZOOR 436
Serpiginous choroidopathy 437
Toxoplasmosis 438
Acute retinal necrosis 441
Cytomegalovirus retinitis 443
Masquerade syndromes 445
Uveitis in children 447
Uveitis in pregnancy 448
Human immunodeficiency virus 448
Episcleritis 452
Scleritis 453
Endophthalmitis 456
Optometry and general practice guidelines 461

CHAPTER 10: OCULAR ONCOLOGY
Prithvi Mruthyunjaya, Mandeep S Sagoo & M Ashwin Reddy

Conjunctival tumours 463
Iris melanoma 472
Differential diagnosis of fundus tumours 475
Choroidal melanoma 482

Retinoblastoma 486
Optometry and general practice guidelines 490

CHAPTER 11: MEDICAL RETINA
Timothy L Jackson, Catherine Egan, Andrew Webster & Adnan Tufail

Taking a family history for inherited disease 493
Fluorescein angiography 496
Indocyanine green angiography 505
Optical coherence tomography 508
Blue light autofluorescence imaging 513
Electrophysiology 516
Retinal laser guidelines 521
Differential diagnosis 528
Age-related macular degeneration 541
Polypoidal choroidal vasculopathy 554
Diabetic retinopathy and maculopathy 557
Central retinal vein occlusion 569
Branch retinal vein occlusion 574
Central retinal artery occlusion 576
Branch retinal artery occlusion 578
Hypertensive retinopathy 579
Retinal arterial macroaneurysm 581
Ocular ischaemic syndrome 583
Juxtafoveal telangiectasia 585
Sickle cell retinopathy 588
Eales' disease 591
Pseudophakic macular oedema (Irvine–Gass syndrome) 593
Central serous chorioretinopathy 594
Retinitis pigmentosa 598
Cone dystrophy 602
Choroideremia 604
Best's disease 606
Pattern dystrophy 609
Stargardt's disease 610
Other macular dystrophies 611
Albinism 612
Syphilis 614
Solar retinopathy 616
Poppers maculopathy 618
Fingolimod-associated macular oedema 619
Toxic retinopathies 620
Optometry and general practice guidelines 624

CHAPTER 12: SURGICAL RETINA
Timothy L Jackson & Lyndon da Cruz

Indirect ophthalmoscopy 627
Posterior vitreous detachment 628
Retinal degenerations and tears 630
Rhegmatogenous retinal detachment 636
Diabetic vitreoretinal surgery 641
Epiretinal membrane 643
Vitreomacular traction syndrome 646
Macular hole 648
Vitreous haemorrhage 651
Optic disc pit 653
Uveal effusion syndrome 654
Hereditary vitreoretinal degenerations 656
Marfan's syndrome 659
Posterior segment trauma 661
Optometry and general practice guidelines 666

CHAPTER 13: PAEDIATRICS
Gillian GW Adams, Lucy Barker & Adam Bates

History and examination 669
Prescribing glasses 671
Myopia control 672
Leucocoria 673
Infantile cataract 674
Coats' disease 679
Persistent fetal vasculature (persistent hyperplastic primary vitreous) 680
Toxocariasis 681
Retinopathy of prematurity 682
Conjunctivitis of the newborn (ophthalmia neonatorum) 689
Anterior segment dysgenesis 691
Non-accidental injury 698
Reduced vision with an otherwise normal examination 700
Optometry and general practice guidelines 703

CHAPTER 14: STRABISMUS
Gillian GW Adams & Naz Raoof

Anatomy and physiology 705
History and examination 707
Amblyopia 711

Esotropia 714
Exotropia 719
Microtropia 722
Accommodation and convergence disorders 723
Incomitant strabismus 725
Alphabet patterns 727
Duane's syndrome 729
Brown's syndrome 732
Thyroid eye disease 735
Third nerve palsy 736
Fourth nerve palsy 739
Sixth nerve palsy 742
Optometry and general practice guidelines 745

CHAPTER 15: NEURO-OPHTHALMOLOGY
Fion Bremner, Neringa Jurkute & Emanuel De Carvalho

History and examination 747
Investigations 752
Anisocoria 763
Transient visual loss 765
Nystagmus 768
Visual field defects 770
Optic disc swelling 776
Idiopathic intracranial hypertension 779
Headache and facial pain 782
Migraine 785
Non-arteritic anterior ischaemic optic neuropathy 787
Giant cell arteritis (temporal arteritis) 789
Demyelinating (multiple sclerosis-associated) optic neuritis 792
Traumatic optic neuropathy 796
Compressive, infiltrative and inflammatory optic neuropathy 797
Nutritional and toxic optic neuropathy 799
Hereditary optic neuropathy 801
Radiation optic neuropathy 804
Optic nerve tumours 805
Cerebrovascular disease 808
Carotid cavernous fistula 811
Medically unexplained visual loss 813
Systemic disease associations 816
Optometry and general practice guidelines 819

APPENDICES

James E Neffendorf & Timothy L Jackson

1	Cardiorespiratory arrest	821
2	Anaphylaxis	824
3	Visual standards for driving	825
4	Visual criteria for registration as sight impaired	829
5	Sutures and needles	830
6	Ophthalmic surgical instruments	834
7	Use of the operating microscope	838
8	Drug use in pregnancy	840
9	Reading test types	847
10	Amsler chart	849
11	Visual acuity conversion	850

INDEX **851**

LACRIMAL

Thomas G Hardy & Geoffrey E Rose

3

THE WATERY EYE

Anatomy and physiology The tear film provides corneal lubrication, nourishment and protection, has anti-infective properties, aids removal of bacteria, cells and debris, and optimises the optical interface between air and cornea. It is triphasic, comprising a mucous layer (from goblet cells), aqueous layer (basal production from the accessory glands of Krause and Wolfring; reflex production from the main lacrimal glands), and lipid layer (meibomian glands).

Symptomatic watering results from reduced tear removal (normally by evaporation and drainage) and/or overproduction. Obstructive epiphora refers to reduced tear drainage. Tear distribution is also important, as is eyelid movement (lacrimal pump) and position. Patient tolerance of watering varies widely.

The lacrimal drainage system comprises three compartments:

1. Tear lake
2. Lacrimal sac
3. Nasal cavity

Relatively high-resistance conduits connect these compartments; the canaliculi (connecting compartments 1 and 2), and nasolacrimal duct (NLD, connecting compartments 2 and 3) **(Fig. 3.1)**:

- *Canalicular obstruction produces 'flow' symptoms*: 'Eyes well up with water', blur on downgaze, e.g. reading. 'Volume' symptoms are minimal or absent.
- *Nasolacrimal duct obstruction (NLDO) produces 'volume' symptoms* due to backwash from the lacrimal sac, e.g. recurrent conjunctivitis; morning stickiness; mucous debris in the tear film; dacryocystitis; lacrimal sac mucocoele or abscess. If tears cannot reflux from the sac via the canaliculi or valve of Rosenmüller, then the sac may become distended, painful and/or infected.

History Assess severity – symptoms indoors are more significant than those outdoors in cold, windy weather; frequency of dabbing with tissues; ± Munk score (0 = no watering; 1 = occasional watering with dabbing less than twice daily; 2 = dabbing 2–4 times daily; 3 = 5–10 times daily; 4 = >10 times daily or constant). Ask about onset, time relationships,

JAYPEE BROTHERS

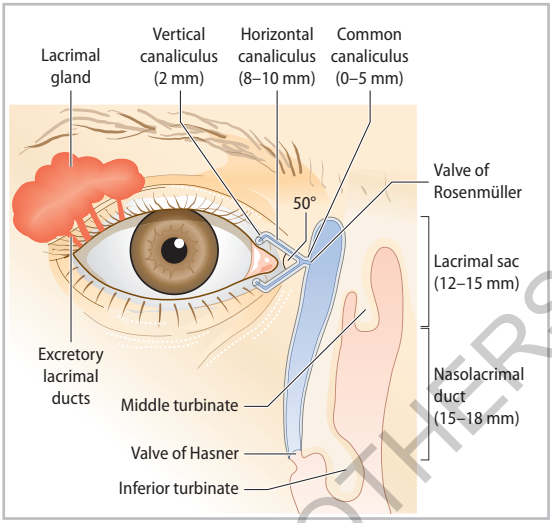

Fig. 3.1: Lacrimal drainage anatomy. The angle between the horizontal and common canaliculi in the axial plane is ~135°. Therefore, one must pull the lid laterally when probing the common canaliculus (during intubation, e.g. at dacryocystorhinostomy) to straighten out this angle and avoid a 'false passage' from canalicular perforation.

duration, and site of tear spillover. Medial spillage suggests impaired drainage; lateral spillage may relate to lower lid laxity, or upper lid dermatochalasis contacting the tear film with chronic skin wetting by capillary action. Reflex watering from tear-film deficiency is often worse in dry, warm or evaporative environments, bright light, or when blinking is reduced, e.g. concentrating on reading, computer use, and Parkinson's disease. Simultaneous rhinorrhoea suggests overproduction. Bloody tears suggest a sac tumour (rare), canaliculitis, or trauma to the canaliculi/sac (including iatrogenic injury and factitious disorder). Ask about surface irritation or itch (atopy), a history of facial/nasal trauma, and previous sinonasal or lacrimal surgery. 'Crocodile tears' are associated with facial palsy and involve neurogenic reflex watering, often sudden, from the thought of food, eating, or chewing. Lacrimal sac swelling may be secondary to a dacryocoele (a congenital cyst), mucocoele (see below), pyocoele, dacryocystitis or acute tear retention (both painful), tumour (usually painless ± bloody tears), or occasionally air (± pain).

JAYPEE BROTHERS

Examination Examine for causes of overproduction or impaired drainage.

- *Overproduction*: Look for–
  1. Lid or lash malposition – trichiasis, distichiasis, entropion, exposure keratopathy due to ectropion or lagophthalmos.
  2. Lid margin disease.
  3. Tear film deficiency – perform Schirmer's test (p. 209) and tear film break-up time (p. 209).
  4. Corneal foreign body/erosions or subtarsal foreign body.
  5. Conjunctivitis – look for allergic papillae, follicles.
  6. Corneal disease, especially superficial punctate keratopathy from tear film anomalies or exposure keratopathy, and early dendritic keratitis.
  7. Uveitis and scleritis.
- *Impaired drainage*: Look for–
  1. Eyelid laxity or malposition of the lower lid or punctum, particularly ectropion.
  2. Punctal or canalicular stenosis, cicatrising conjunctival disease (e.g. pemphigoid and lichen planus), eye drops (e.g. glaucoma therapy), systemic chemotherapy (especially 5-FU and docetaxel), and trauma (including iatrogenic, e.g. lid tumour resection).
  3. Canaliculitis.
  4. Fistula – congenital or acquired (following dacryocystitis) – and accessory (duplicated) punctum/canaliculus.
  5. Lacrimal pump failure – especially facial palsy, scarring (trauma and surgery).
  6. Lacrimal sac mucocoele – this is a chronic collection of mucopurulent material due to low grade colonisation/infection of stagnant tears. Pressing on the sac causes reflux of mucus or pus (**Fig. 3.2**).
  7. Lacrimal sac mass – consider tumour or tense mucocoele. In general, a mass below medial canthal tendon (MCT) originates from the sac; lesions above the MCT may indicate non-sac origin (e.g. encephalocele) or lacrimal sac tumour.
  8. Dacryocystitis – active or resolved.
  9. Nasal obstruction, e.g. mass, inflammation and scarring. Perform nasal endoscopy if suspect obstruction/stenosis distal to lacrimal sac.
  10. Altered facial/lid relationship – including proptosis/prominent eyes, lower lid retraction and hypoplastic midface.
  11. Prior surgery or trauma – look for scars.

JAYPEE BROTHERS

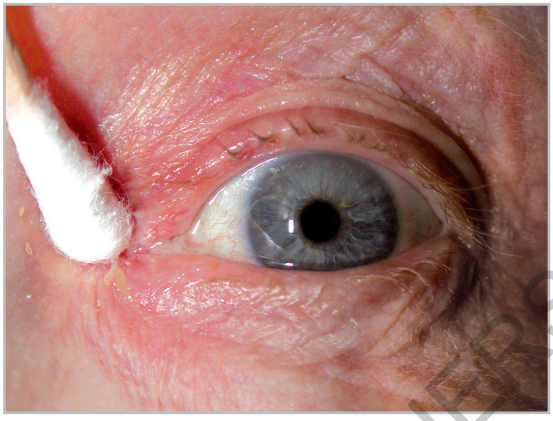

Fig. 3.2: Mucocoele with mucous reflux.

Clinical tests

- *Fluorescein disappearance test (FDT)*: Instil a tiny drop of fluorescein 2% in both eyes at the start of history taking. After ~5 minutes, look at tear film height ± asymmetry. High + diluted = overproduction; high + undiluted = impaired drainage.
- *Syringing*: Perform diagnostic lacrimal syringing in all patients with epiphora (including ectropion), except those with acute dacryocystitis in whom the procedure is usually painful. Consider patient's comfort and use a reclining chair with head support. Be very gentle to avoid canalicular trauma. Instil topical anaesthetic. If necessary, dilate the punctum, but avoid tearing the fibrous annulus and avoid sharp dilators. Keep the lower lid under firm lateral tension to eliminate the angle between the horizontal and common canaliculus to avoid canalicular perforation (false passage). Gently inject saline using a 2.5 mL syringe with a lacrimal cannula, inserted no more than ~5 mm into the horizontal canaliculus. It is seldom necessary to check for a 'hard' or 'soft stop' by pushing the cannula up against the medial sac wall, which is often uncomfortable. Lower canalicular reflux suggests obstruction proximal to the common canaliculus. Upper canalicular reflux with fluorescein or mucus reflux suggests a mucocoele due to NLDO. Early reflux via the upper canaliculus without fluorescein suggests common canalicular obstruction. Syringe the upper canaliculus if the lower punctum is occluded. The site of canalicular obstruction may be measured (hold cannula

JAYPEE BROTHERS

with forceps at punctum and withdraw cannula; measure forceps-cannula tip distance).

- *Jones I dye test*: Assesses physiological drainage. Instil fluorescein 2% and then insert a cotton bud under the inferior turbinate – if there is dye on the cotton bud, the test is positive. Nasal endoscopic visualisation is more accurate. A negative result indicates non-patency, partial patency, or functional NLDO. The test is most useful following dacryocystorhinostomy (DCR) with nasal endoscopy or cotton bud placement at the surgical ostium; otherwise, it is less reliable.
- *Jones II assisted dye test (non-physiological)*: As per Jones I, but after syringing. Not needed if Jones I is positive.

Investigations

- *Dacryocystogram (DCG)*: Indications include non-compressible lacrimal sac mass, failed DCR or trauma without mucocoele (surgery for post-traumatic or recurrent mucocoele is relatively straightforward in experienced hands, so DCG is not needed), suspected functional NLDO (shows narrow NLD ± dilated sac, with delayed clearance from sac on late erect films), and bloody epiphora (mass/filling defect). Assess for anatomy, filling defects, NLD calibre and delayed lacrimal drainage system emptying on late erect films.
- *CT-DCG (bone ± soft-tissue window CT facial bones performed immediately after DCG)*: Indications include sinonasal disease, lacrimal tumours (widened NLD canal, soft-tissue mass and bony destruction), and in some cases following trauma, especially if metallic implants are suspected.
- *Dacryoscintigraphy*: Semi-functional test; may distinguish between delayed drainage between compartments 1 and 2 ('pre-sac delay' or lacrimal pump failure), and 2 and 3 ('post-sac delay', NLD stenosis or obstruction).

Management (Fig. 3.3)

- *Overproduction*: Treat the underlying cause, e.g. lid hygiene, lash removal, topical lubricant, steroid, or antibiotic.
- *Impaired drainage*:
  - Lid malposition: Surgical correction.
  - Punctal stenosis: Punctoplasty **(Box 3.1)**.
  - *Canalicular stenosis*:
    - *Proximal*: DCR + retrograde canaliculostomy (canaliculi are intubated from within the opened lacrimal sac and a 'cut-down' performed lateral to the site of obstruction).
    - *Distal*: canaliculo-dacryocystorhinostomy (C-DCR; canaliculi are joined to the sac flaps after excision or

JAYPEE BROTHERS

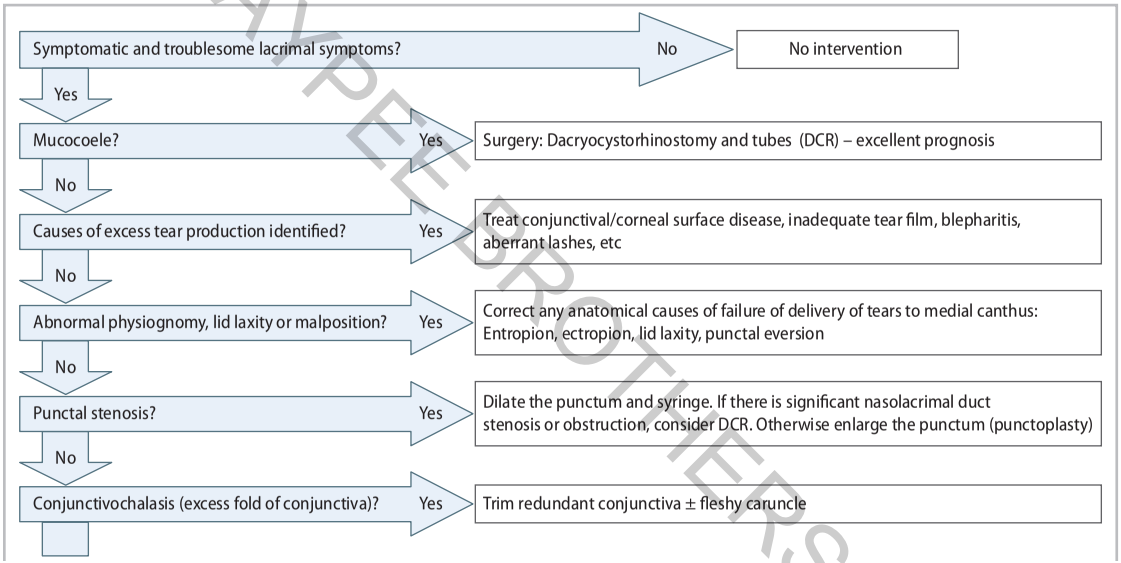

JAYPEE BROTHERS

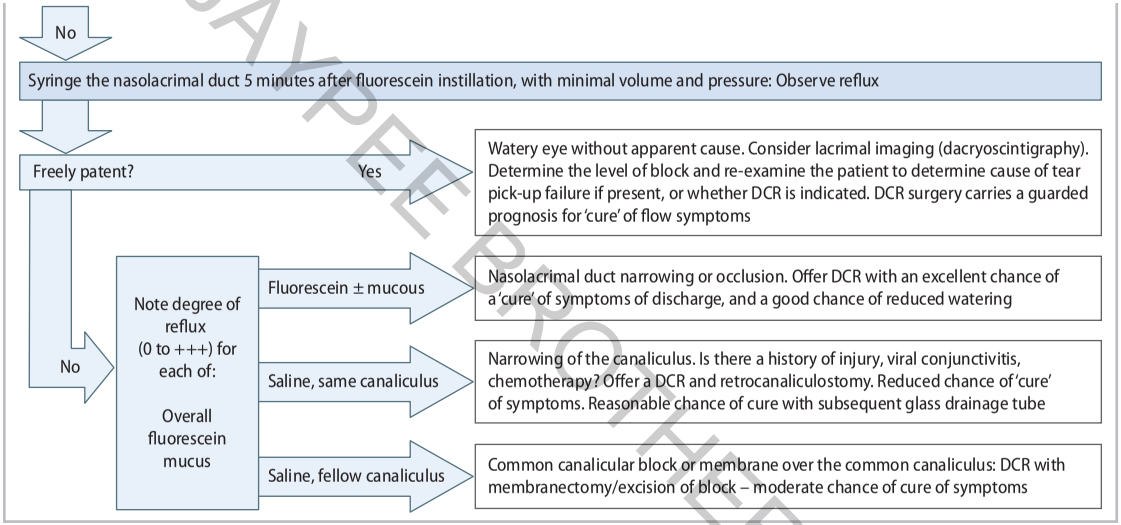

Fig. 3.3: Management of epiphora in adults.

JAYPEE BROTHERS

Box 3.1: Punctoplasty ('3-snip' or posterior ampullectomy)

1. Instil topical anaesthetic.
2. Dilate lower punctum with a punctum dilator, e.g. Nettleship.
3. Make two parallel cuts (medial and lateral) in the posterior wall of the vertical canaliculus (ampulla) and join at the bottom with fine, straight scissors (e.g. Vannas).
4. Gently cauterise conjunctiva at wound edges.
5. Prescribe G. chloramphenicol q.d.s. and mild topical steroid q.d.s. for 2 weeks.
6. Review in 2–3 weeks.

trephination of intervening scar tissue, or the scar is excised from within the sac until the probes are seen (stents passed directly into the sac) ± lacrimal canalicular bypass, e.g. Lester Jones tube (LJT).

- *Canaliculitis*: see page 86.
- *Acute dacryocystitis (lacrimal sac abscess)*: see page 87.
- *Mucocoele or functional NLDO*: DCR (see below).
- *Lacrimal sac tumour (biopsy sac)*: If discovered intraoperatively perform incisional (±frozen section) biopsy, abandon DCR and plan later definitive excision of lacrimal drainage system (e.g. dacryocystectomy).
- *Lacrimal pump failure (atonic canaliculi)*: Difficult to treat. Tighten/shorten lid ± punctoplasty ± DCR ± lacrimal canalicular bypass (e.g. LJT).
- *Nasal congestion*: Prescribe a nasal decongestant, e.g. xylometazoline hydrochloride nasal spray 0.1%, one spray per nostril, 2–3 times daily for up to 7 days. Beware interactions with monoamine oxidase inhibitors, etc. Restrict use to 5–7 consecutive days to avoid rebound rhinorrhoea. Also, prescribe steroid, e.g. beclomethasone dipropionate (Beconase) nasal spray 50 µg/metered spray, two sprays per nostril daily for 2–3 weeks. Consider an ENT opinion.
- *Nasal mass*: Refer to ENT for biopsy.
- *Congenital NLDO*: See page 84.
- *Botox to lacrimal gland*: 5-10 U, transconjunctival (palpebral lobe) or transcutaneous (orbital lobe). Consider for functional obstruction or if surgery inappropriate.

JAYPEE BROTHERS

DACRYOCYSTORHINOSTOMY

Background Aims to create a mucosal-lined anastomosis between the lacrimal sac and nose using an external (open) or endoscopic approach. An external approach is absolutely indicated if sac tumour is suspected [if confirmed, biopsy the sac but do not complete dacryocystorhinostomy (DCR)], and for proximal canalicular disease. For external and endonasal techniques see **Boxes 3.2 and 3.3**.

Box 3.2: External dacryocystorhinostomy

1. Select general anaesthetic (GA) or local anaesthetic (LA) with sedation (bupivacaine 0.5% with 1:200,000 epinephrine on side of nose, medial peribulbar, infraorbital nerve block, plus cocaine 5% 3 mL intranasal packing around middle turbinate; avoid cocaine in children).
2. Haemostasis under GA is assisted by head-up position, BP control, intranasal 0.1% epinephrine moistened cotton buds or cocaine 5% nasal pack. Consider tranexamic acid 1g i.v.
3. Consider prophylactic antibiotics in cases of dacryocystitis.
4. Make a straight incision 1 cm anterior to the medial canthus, ~1.5 cm long, raise skin flap and expose the medial canthal tendon (MCT) using blunt dissection (Rollet's rougine).
5. Dissect MCT and periosteum from anterior lacrimal crest, release sac, especially superiorly, and mobilise laterally.
6. Start rhinostomy by opening suture between nasal and lacrimal bones with Traquair periosteal elevator. Use bone punch, e.g. Kerrison's rongeurs, to extend as far superiorly and anteriorly as possible, inferiorly (level with inferior orbital rim) and posteriorly (to just behind the posterior lacrimal crest). Rhinostomy should measure about 2–3 cm in diameter **(Fig. 3.4)**. Protect nasal mucosa from inadvertent perforation.
7. Perform anterior ethmoidectomy (with, e.g. curved haemostat) as required to allow posterior nasal mucosal flap to mobilise laterally.
8. Fully open sac from fundus to duct and fashion sac and nasal mucosal flaps, using all available rhinostomy space. Incise nasal mucosa >3 mm anterior to root of middle turbinate – the anterior nasal mucosal flap should be larger than posterior **(Fig. 3.5)**. Suture flaps with 6/0 Vicryl. 'Suspend' anterior flaps to overlying orbicularis.
9. Consider O'Donoghue tubing or similar stent if canalicular obstruction. Tie tubing in the nose and place a marker stitch, e.g. 5/0 silk, to aid later stent removal.
10. Carefully close skin with 6/0 non-absorbable suture. Keep closure flat and avoid 'bow-stringing'.

JAYPEE BROTHERS

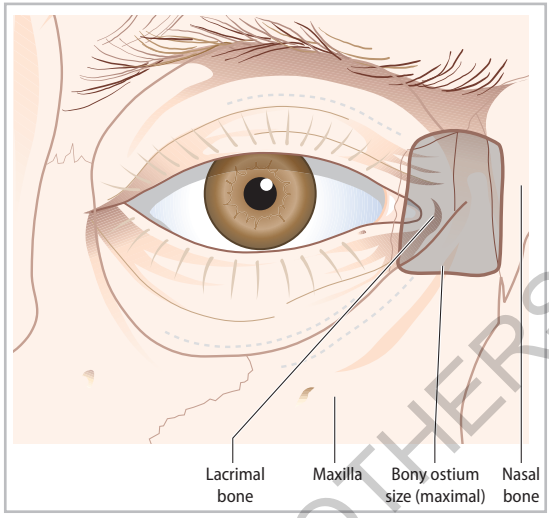

Fig. 3.4: Dacryocystorhinostomy: rhinostomy.

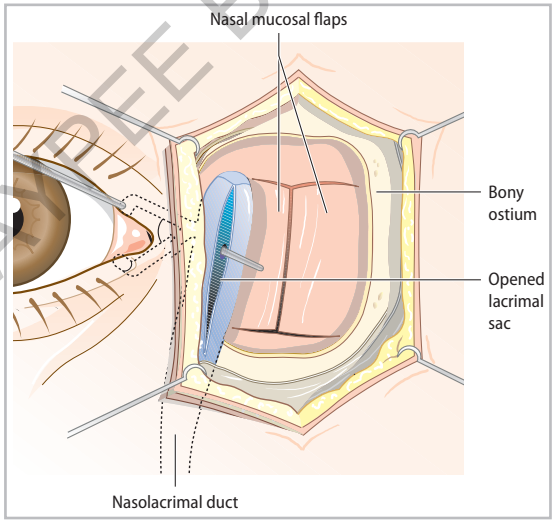

Fig. 3.5: Dacryocystorhinostomy: mucosal flaps.

JAYPEE BROTHERS

Box 3.3: Endonasal dacryocystorhinostomy

1. Steps 1–3 as for external DCR, but endonasal anaesthesia and haemostasis require additional local infiltration of the lateral nasal wall under direct vision, and placement of cocaine-soaked neurosurgical patties at the operative site.
2. Perform septoplasty as required for access.
3. Using a crescent blade or similar, place a vertical incision along the maxillary line, with posteriorly-directed horizontal relieving incisions at the upper (just above middle turbinate origin) and lower (middle of middle turbinate) ends of this primary incision. Use a periosteal elevator (e.g. suction Freer) to raise the flap posteriorly and reflect medially over the turbinate.
4. Identify the very thin lacrimal bone and pass an anteriorly – directed angled 3 mm rongeur to engage and remove the frontal process of the maxilla. Repeat to remove the majority of the process, revealing the lacrimal sac and upper nasolacrimal duct.
5. Remove bone alongside the upper part of the lacrimal sac with a guarded high-speed diamond burr (avoiding perforation of the skull base).
6. Remove any lacrimal bone or ethmoid encroaching medially to the lacrimal sac. Consider opening the agger nasi air cell.
7. Vertically open the lacrimal sac (angled keratome or crescent blade) after passage of a suitable lacrimal probe, with the flaps relieved at their upper and lower ends to encourage them to lay flat on the lateral nasal wall. Inspect the sac for stones or masses (biopsy if in doubt) and common canalicular opening.
8. When the sac is opened widely, consider silicone stent and secure within the nose, e.g. ligature clip.
9. Trim nasal mucosal flap leaving mucosa to cover any areas of raw bone, particularly at the maxillary frontal process. Place a dissolving intranasal dressing to keep the flaps widely open.

JAYPEE BROTHERS

Consent

- *Benefit*: External DCR success rate is similar to powered mechanical endoscopic DCR (85–95%); endoscopic laser DCR has lower success rates (~60%). Success with primary surgery varies with definition of success (anatomic vs. symptomatic), symptoms (near 100% cure from mucocoele stickiness with correctly performed DCR), and underlying disease (mucocoele > functional nasolacrimal duct obstruction (NLDO) ~70% > canalicular block ~30–50%).
- *Risk*: Visible scar (1–2% at 1 year); significant post-operative epistaxis (2–3%, occasionally requiring nasal packing,

admission and monitoring for hypovolaemia), sinusitis (~1%), infection (~1%); cerebrospinal fluid leak (exceedingly rare).

Post-operative care No hot drinks for 12 hours; no nose blowing for 5–7 days. Prescribe a steroid-antibiotic combination eye drop q.d.s. 2 weeks, then b.d. 2 weeks, and nasal saline ± steroid spray (e.g. mometasone furoate one puff daily) for 1 month.

Follow-up Remove sutures at 7 days and stent at 4 weeks, unless canaliculo-dacryocystorhinostomy (2–3 months) or retrograde canaliculostomy (2–3 weeks).

JAYPEE BROTHERS

LESTER JONES' CANALICULAR BYPASS TUBE

Provides a permanent fistula connecting the conjunctival sac to the nose. Requires prior or simultaneous dacryocystorhinostomy (DCR) and carunculectomy. Use a 'bull-horn' dilator or specific Lester Jones' tube (LJT) insertion set followed by passage of the LJT down the dilated tract; place the LJT just behind the medial canthus, angled about 30° inferiorly **(Fig. 3.6)**. Avoid abutting the nasal septum. Secure LJT with silk suture and bolster over medial lower lid in primary placement. Avoid nose blowing for 1 week postoperatively (risk of tube coming out), and review at 6 weeks. Advise the patient to place finger over the tube if sneezing or blowing nose, and perform daily 'sniff' test to confirm patency (inhale through nose with ipsilateral nostril blocked; sniffing water into nose may aid cleaning). Attend within 1–2 days if tube dislodges, when replacement without LA/GA is sometimes successful. Review annually for internal cleaning and saline irrigation.

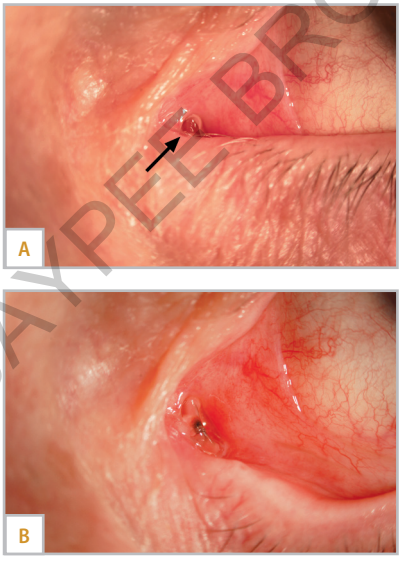

Fig. 3.6: Lester Jones tube (arrow). (A) Tip of well-positioned Jones tube just visible above medial lower eyelid; (B) Tube seen more easily on eversion of lower lid.

JAYPEE BROTHERS

CONGENITAL NASOLACRIMAL DUCT OBSTRUCTION

Background The lacrimal system usually canalises by 7 months of fetal life. In the first year postpartum, 96% of cases of nasolacrimal duct obstruction resolve; a further 60% resolve in the second year with some slow resolution thereafter.

Examination Perform the fluorescein disappearance test (p. 74). Check for an expressible mucocoele and dacryocoele (a tense, bluish sac swelling usually in the first month of life). Look for 'accessory' fistulae (duplicated punctum-canaliculus), typically in the medial lower lid (skin or lid margin); these may drain fluorescein **(Fig. 3.7)**.

Differential diagnosis

- *Watery eye*: Atopy, punctal ageneis or incomplete canalisation (rare), conjunctivitis and blepharitis.
- *Lacrimal sac mass*: Dermoid; tumour, e.g. haemangioma, rhabdomyosarcoma; meningo-encephalocoele.

Management Explain the natural history. Massage the sac six times daily by firm pressure on the medial upper lid, behind the anterior lacrimal crest; demonstrate to parents. Use topical antibiotics for episodes of conjunctivitis. Defer probing until 12 months, unless dacryo(cysto)coele, acute/recurrent dacryocystitis and/or abscess occur, but only probe after the acute episode resolves **(Box 3.4)**.

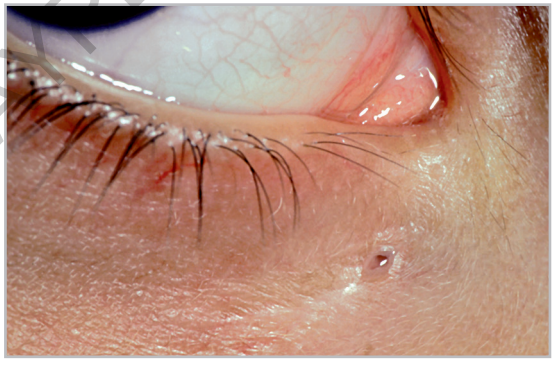

Fig. 3.7: Typical location for congenital lacrimal fistula, joining the common canaliculus by passing below the anterior limb of the medial canthal tendon.

JAYPEE BROTHERS

Box 3.4: Syringe and probe (probing)

1. Explain the procedure:

   Benefit: Complete symptom resolution rates (approximate): >90% if done at the age of 1 year, 90% at 2 years, 80% at 3 years, 70% at 4 years and 40% at 5 years.

   Risk: False passage, bleeding, failure and bronchospasm.

2. Examine (under GA) lids, conjunctiva and puncta. Look for fistulae and expressible mucocoele. Perform nasal endoscopy.

3. Perform dacryocystogram (DCG) if redo, to clarify anatomy.

4. Inject saline and fluorescein mixture using a lacrimal cannula. Feel for resistance. If not able to easily introduce cannula, dilate puncta gently. Place a fine suction catheter or endoscope up nose to look for fluorescein.

5. Consider probing even if patent to syringing, e.g. if significant symptoms or prior failed probing. Try to start with a '0' Bowman for lower punctum, '00' for upper. Try to avoid smaller probes or sizes larger than '1'.

6. Insert probe vertically (2 mm) then horizontally with lid on lateral traction. Feel for 'hard stop' as probe contacts medial sac wall against nasal bones. Otherwise, compressed tissue results in a 'soft stop'.

7. Direct probe vertically down into the nasolacrimal duct (NLD), angled slightly posteriorly and medially. Feel for a 'pop' as the probe perforates the membrane of a non-patent NLD. Feel for tight 'gritty' sensation (stenosed bony canal). Inability to pass probe may indicate absent NLD; look for 'buried probe' (anomalous submucosal NLD).

8. Check probe is below inferior turbinate – feel using large probe along floor of nose or look with an endoscope.

9. Repeat syringing. This also assists sac washout.

10. Prescribe a steroid-antibiotic combination drop t.d.s. and continue effective lacrimal sac massage for 1 week.

Follow-up Review as required if first probing, or 6–8 weeks if a redo. Consider balloon dacryoplasty and/or intubation (silicone stent) if multiple endoscopically monitored probings fail.

JAYPEE BROTHERS

CANALICULITIS

Background Canaliculi become grossly dilated with intraluminal deposits of granules caused by low-grade infection, classically *Actinomyces*, but also fungi.

Symptoms Chronic discharge with lids stuck together especially in mornings. Epiphora is often mild but worse in mornings.

Signs Swollen inflamed lid medial to prominent 'pouting' punctum **(Fig. 3.8)**. Features may be subtle.

Management Usually responds to canaliculotomy – dilate and open 5 mm of horizontal canaliculus. Use a pair of cotton buds (rolled medial to lateral) to compress the canaliculus and express deposits; consider small curette to remove granules. Consider microbiology and prescribe G. chloramphenicol q.d.s. for 10 days.

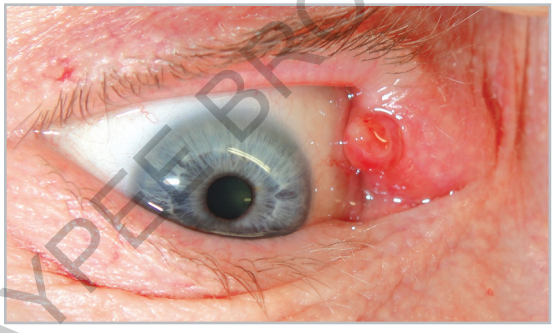

Fig. 3.8: Canaliculitis (*Actinomyces*) with punctal granuloma and stringy discharge from dilated upper canaliculus (Courtesy D Verity).

JAYPEE BROTHERS

ACUTE DACRYOCYSTITIS/ LACRIMAL SAC ABSCESS

Background A purulent lacrimal sac infection/abscess with surrounding cellulitis, often associated with nasolacrimal duct obstruction. Caused by superinfection of a mucocoele. May form a discharging cutaneous fistula below the medial canthal tendon (MCT).

Clinical features Tense, painful erythematous swelling below the MCT, often with a history of stickiness and epiphora **(Fig. 3.9)**.

Management Hot compresses 4–6 times daily, G. chloramphenicol q.d.s until resolved, and oral cefalexin 250–500 mg q.d.s. 1–2 weeks or until cellulitis resolves. If febrile or acutely unwell treat as preseptal cellulitis (p. 107). Incise and drain if fails to respond after 5–7 days, or if worsens. Apply topical skin anaesthetic e.g. eutectic mixture of local anaesthetics (EMLA), for 30 minutes, then inject LA slowly around the abscess and then into the abscess cavity; this may be very painful if not performed slowly. Incise with a blade, drain, and send pus to microbiology; packing with ribbon gauze is rarely required except for very large abscesses. Arrange definitive treatment with dacryocystorhinostomy (DCR) when cellulitis is resolved (or occasionally, in acute setting).

Children with non-resolving acute dacryocystitis or infected dacryocoele require systemic antibiotics, examination under anaesthesia, and drainage via the nasal cavity (probing or endoscopic DCR).

JAYPEE BROTHERS



Fig. 3.9: Acute dacryocystitis with purulent discharge from acquired lacrimal sac fistula.

LACRIMAL DRAINAGE SYSTEM TUMOURS

Background and clinical features Inflammatory (e.g. granuloma and lymphoid hyperplasia) and neoplastic (transitional cell carcinoma, papilloma, squamous cell carcinoma, lymphoma and melanoma) lesions of the lacrimal sac/duct are rare, but must be considered in cases of lacrimal sac mass, non-compressible mucocoele, bloody tears and/or mass or filling defect on dacryocystogram (DCG)/CT-DCG.

Management Biopsy via external approach. Further treatment depends on underlying disease and may involve radical *en bloc* excision of the entire lacrimal drainage system ± radiotherapy ± chemotherapy.

JAYPEE BROTHERS

OPTOMETRY AND GENERAL PRACTICE GUIDELINES

Most lacrimal problems are non-urgent. Reassure patients who have very mild watering, e.g. only outdoors in cold, windy weather. In those with troublesome epiphora, treat or refer any sinonasal disease to an ENT surgeon (e.g. rhinitis, polyps and mass) before referral to an ophthalmologist, the latter preferably one experienced in lacrimal disorders. Also consider epiphora secondary to eye disease and ask if the eye becomes red and painful or if vision is blurred. Treat or refer any readily identifiable ocular surface problem (e.g. tear film deficiency, blepharitis, allergic conjunctivitis and trichiasis). Look specifically for eyelid/lash malpositions, e.g. lower lid ectropion/entropion.

A firm and non-reducible mass in the lacrimal sac fossa or blood-stained tears suggest a lacrimal sac neoplasm, so refer urgently; sac mucocoeles are generally compressible. Any swelling presenting in the region above the medial canthal tendon is neoplasia until proven otherwise.

Instruct parents of children with congenital nasolacrimal duct obstruction to massage firmly over the nasolacrimal sac (not just on the side of the nose) six times daily. Refer if symptoms fail to resolve after a year, or sooner if frequent conjunctivitis or dacryocystitis occurs.

The following guide to referral urgency is not prescriptive, as clinical situations vary.

Same day

- Canalicular injuries p. 66
- Acute dacryocystitis/lacrimal sac abscess (commence G. chloramphenicol q.d.s. and systemic antibiotics, e.g. cefalexin 250–500 mg p.o. q.d.s.) p. 87

Urgent (within 1 week)

- Epiphora with blood-stained tears p. 87
- Non-compressible lacrimal sac mass p. 88

Routine (non-urgent)

- Isolated epiphora p. 38
- Epiphora with recurrent conjunctivitis (treat episodes with G. chloramphenicol q.d.s. 1 week) p. 38
- A child with epiphora since birth unless suspected dacryocoele, recurrent problematic conjunctivitis, or any dacryocystitis p. 38
- Suspected canaliculitis (prescribe G. chloramphenicol q.d.s. 2 weeks) p. 86
- Lacrimal sac mucocoele p. 73

JAYPEE BROTHERS

JAYPEE BROTHERS

4TH EDITION

Moorfields Manual of Ophthalmology

The *Moorfields Manual of Ophthalmology* has undergone front-to-back revision, incorporating the latest clinical evidence and practice.

- The culmination of more than 70 authors' contribution across the four editions
- Written by leading experts in their field
- Chapter 1 provides diagnostic decision trees, to guide readers to the most likely diagnosis
- More images aid pattern recognition
- Details how to manage the most common and serious eye diseases
- Step-by-step guides to performing outpatient procedures, with a chapter dedicated to cataract surgery
- Wide range of appendices covering topics such as anaphylaxis, use of the operating microscope, surgical instrument names, ophthalmic drug use in pregnancy, and many others
- Triage guidelines for general practitioners and optometrists

JP medical publishers

www.jpmedpub.com

ISBN 978-1-78779-191-6