Snippets in Surgery

Volume 2



Srinivasan Ravi

Contents

	Preface	v
	Contributors	vii
	Dedication	ix
Chapter 1	The scientific method *Srinivasan Ravi*	1
Chapter 2	Oncology *Srinivasan Ravi*	19
Chapter 3	Breast disease *Srinivasan Ravi*	39
Chapter 4	Upper gastrointestinal malignancies *Ilias Marios Oikonomou, Marena Gray, Vlasios Gourgiotis, Stavros Gourgiotis, Srinivasan Ravi*	60
Chapter 5	Small bowel malignancies *Srinivasan Ravi, Ilias Marios Oikonomou, Marena Gray, Vlasios Gourgiotis, Stavros Gourgiotis*	83
Chapter 6	Hepatobiliary malignancies *Srinivasan Ravi*	87
Chapter 7	Colo-rectal disease *Srinivasan Ravi*	98
Chapter 8	Thyroid disease *Srinivasan Ravi*	126
Chapter 9	Parathyroid disease and calcium metabolism *Srinivasan Ravi*	137
Chapter 10	Nutrition of the surgical patient *Srinivasan Ravi*	142
Chapter 11	Metabolic response to trauma *Srinivasan Ravi*	152
Chapter 12	General plastic surgery *Srinivasan Ravi*	158

Chapter 13 General paediatric surgery 167
Srinivasan Ravi

Chapter 14 Perioperative care 171
Srinivasan Ravi

Chapter 15 Experiential case-based learning 180
Srinivasan Ravi

Chapter 16 Multiple choice questions: Test yourself 187
Srinivasan Ravi

Chapter 17 Multiple choice question: Answers 197
Srinivasan Ravi

Chapter 18 Reflections on progress in surgery – surgery then and now 204
Srinivasan Ravi

Bibliography 209

Index 213

Chapter 6

Hepatobiliary malignancies

Srinivasan Ravi

JAYPEE BROTHERS

Anatomy of the liver

Morphological anatomy (**Figure 1**) based on the external appearance divides the liver into four lobes, the left and right separated by the falciform ligament and the quadrate and caudate lobes. The blood supply is 20% from the hepatic artery and 80% from the portal vein that drains the gut and spleen; the liver acts as the first filter. The portal vein is only about 8 cm long and 13 mm wide. It is formed behind the pancreas by the confluence of the superior and inferior mesenteric veins that drain the small and large intestine. The other tributaries are the splenic and gastric veins. The venous drainage of the liver is to the hepatic vein and then the inferior vena cava (IVC). The portal and venous systems are in intimate contact in the substance of the liver.

Functional anatomy (**Figure 2**) is more utilitarian with the increasing progress in technology that enables various types of resections of the liver for multiple indications such as primary tumours and metastases. It was described by the French anatomist and surgeon *Claude Couinaud*. In this system the liver is divided into *eight segments* as shown below. The caudate lobe remains as segment one. The other segments are divided by the hepatic and portal veins into different independent functional segments that permit segmental resections. Each of these segments has its own inflow and outflow systems. If the resections are done in the correct planes, good haemostasis can be achieved.

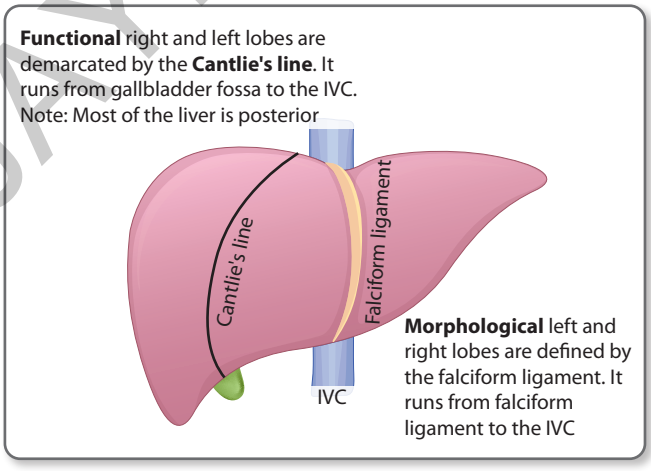

Figure 1 Morphological anatomy. IVC, inferior vena cava.

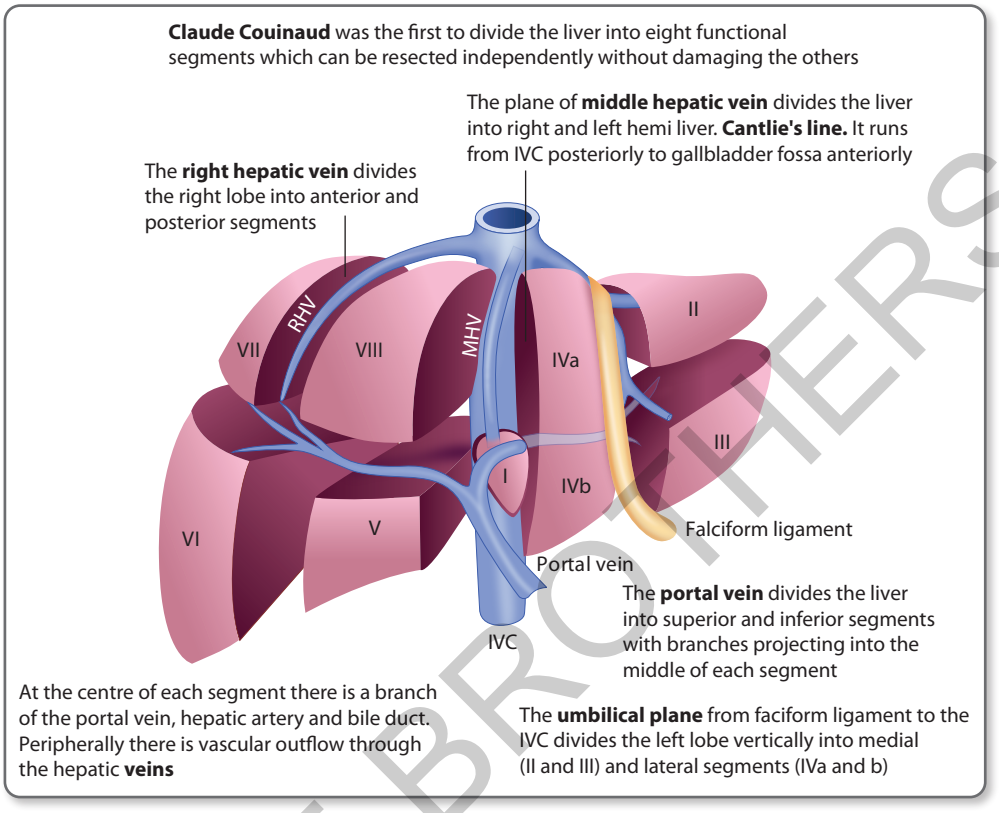

Figure 2 Schematic functional anatomy of the liver.

There are normally three large hepatic veins situated superiorly in the liver draining into the IVC whilst the caudate lobe drains directly into the IVC via several small veins.

- The *right hepatic vein* divides the right lobe into anterior and posterior segments.
- The *middle hepatic vein* lies in the same plane as the IVC and divides the liver into two equal functional segments of left and right hemi liver.
- The *left hepatic vein* (the umbilical plane) according to some divides the left lobe into two vertical segments whilst some anatomists believe that it is the only plane that is not defined by the hepatic or portal veins.
- *The portal vein* (left and right branches) divides the liver into a superior and inferior plane.

Cantlie, a Scottish surgeon, noted, in 1887, that the true division of right and left lobes of the liver was in a plane from the gallbladder to the IVC based on autopsy findings. This plane is useful in hepatectomy and lies lateral to the falciform ligament than the schematic diagram shows (**Figure 1**).

Malignant tumour of the liver can be primary or secondary. Secondary tumours from colorectal cancers are the most common cause of liver tumours. At the time of initial diagnosis 15–20% of colorectal cancer patients may have a liver metastasis with a further 15% going on to develop metachronous disease. Primary liver tumours are more common in Asia and Africa due to increased prevalence of chronic liver disease. Primary liver tumours are:

JAYPEE BROTHERS

- Hepatocellular carcinoma
- Cholangiocarcinoma
- Gallbladder carcinoma

Hepatocellular carcinoma

Risk factors:

- *Hepatitis B (HBV) and C (HCV) infections*: Chronic liver disease associated with HBV and HCV is the strongest risk factor globally. A high proportion of cases show evidence of infection with HBV and HCV (Benson et al.).
- *Excessive alcohol intake:* In the UK, alcohol-related cirrhosis is the cause of a third of the liver cancers. Nearly 80% of patients with hepatocellular carcinoma (HCC) have evidence of cirrhosis (Bartlett *DL)*.
- *Non-alchoholic fatty liver* [non-alcoholic steatohepatitis (*NASH*)] is now referred to as metabolic dysfunction associated steatotic liver disease (MASLD) related to obesity increasingly thought of as being a risk factor. 20% of cases occur in non-cirrhotic livers.
- *Schistosoma mansoni* is currently thought to be of doubtful significance. It is quite possible that is a co-factor or a promoter in the presence of HBV and HBC infections.
- *Aflatoxin* – long-term exposure increases risk. Aflatoxin is found in grains and peanuts exposed to *Aspergillus* contamination.
- *Rare in born errors of metabolism, haemochromatosis* (build-up of iron), *Wilson's disease* (build-up of copper)

Presentation

This can be very non-specific unless made obvious with jaundice.

- Unexplained weight loss
- Jaundice
- Palpable mass
- Fatigue
- Pyrexia

Pathology

Three gross morphologic types of HCC have been identified:

1. *Nodular* – associated with cirrhosis. Well-circumscribed
2. *Massive* – more common in non-cirrhotic liver. This occupies a large area of the liver
3. *Diffuse* – less common and involves the whole liver

Role of screening

Enrolment in screening in high-risk individuals in China with chronic hepatitis or HBV has shown a benefit. Monitoring of serum alpha fetoprotein (AFP) and ultrasound every 6 months showed a 37% reduction in risk of mortality even when only 60% of the cohort completed the screening programme (Zang). In a separate study in Singapore, screening in high-risk individuals was noted to be of benefit not only in older patients but also in the 40-year-old patients.

JAYPEE BROTHERS

Diagnosis

The diagnosis can be challenging as it is mostly insidious. When suspected the primary screening modality is an ultrasound examination of the liver along with routine blood counts, renal and liver function tests including lactate dehydrogenase (LDH), alkaline phosphatase (ALP), albumin, international normalised ratio (INR) and AFP levels.

Alpha fetoprotein: In the presence of an ultrasound detected mass in the liver that is >2 cm an elevated AFP > 200 ng/mL is diagnostic of the HCC. AFP > 200 ng/mL has a specificity of nearly 100% in the presence of chronic liver disease. It must also be noted that AFP may not be elevated in up to 40% of patients with hepatocellular carcinoma, a group referred to as N-HCC. In A-HCC the AFP is raised.

Role of fine-needle biopsy

Fine-needle biopsy (FNB) is associated with problems, such as tumour seeding, which are probably underestimated (Torzilli). The actual risks of FNB and its impact on patient prognosis due to tumour seeding are still unclear.

When the AFP is non-diagnostic preoperative FNB may play a diagnostic role in selected patients with:

- Focal lesions in cirrhotic livers that are indeterminate on imaging
- Focal lesions in non-cirrhotic livers to differentiate from metastatic disease

Any attempt to do a biopsy should be discussed with a specialist liver unit first.

Modalities of radiological imaging are:

- Triphasic helical CT
- Triphasic dynamic contrast-enhanced MRI
- Contrast-enhanced ultrasonography

Triphasic CT involves three phases:

1. *Arterial phase:* This occurs in the first 15–30 seconds after contrast injection.
2. *Portal venous phase* is when the portal vein (80% of oxygenated blood supply) perfuses the lesion a little later than the arterial phase.
3. *Delayed phase: Wash out phase.* This is the phase, 2–5 minutes following contrast.

Typically, in HCC, there is prominence of the tumour with the arterial flush (enhancement) followed by a wash out in the delayed venous phase. In *liver cysts,* there is no enhancement in any of the phases while in *haemangioma,* there is prominence in the arterial and portal venous phases.

Management

This is determined by the:

- Hepatic function
- TNM staging
- Degree of portal hypertension
- Patient's performance status

Surgical resection is the treatment of choice in selected patients.

Surgery depends on:

- The extent of the disease such as limited to the liver
- Resectability of the lesion

JAYPEE BROTHERS

- *Adequacy of functional liver remnant (FLR)*
- *Feasibility of a clear resection margin*
- Adequate hepatic function (Child–Pugh score A)
- Absence of signs of portal hypertension. A platelet count of <1,00,000/μL is a very good surrogate for clinically significant portal hypertension
- Absence of metastasis (lungs, abdominal nodes, and bones)

Surgical interventions:
Surgical resection can achieve 5-year survival rates of 60% with a operative mortality of 2–3% in selected patients. Adjuvant systemic immunotherapy may reduce tumour recurrence

- *Downstaging strategies:*
  - *Transarterial chemoembolisation (TACE)*: This treatment utilises the fact that the major blood supply to an HCC is via the hepatic artery whilst the normal liver is mainly supplied by the portal vein. The procedure is performed through a femoral artery access with a catheter that is guided to the tumour via the hepatic artery. It is the most common treatment for unresectable disease and can be used as a bridging therapy for patients awaiting liver transplant.
- *Partial hepatectomy:* Where the disease is localised to a resectable area without invasion of major vascular structures.
- Percutaneous and laparoscopic ablation
- Minimally invasive operations, laparoscopic and robotic surgery
- Parenchyma sparing resection with ultrasound guidance
- Staged hepatectomy
- *Liver transplantation:* The major limitation to this is organ shortage and prolonged waiting times

Radiofrequency ablation (RFA): In situations where resection is not possible or when the tumour is so small that resection can be avoided, percutaneous radiofrequency or microwave ablation can be carried out (CRUK). This works of the principle of using heat to destroy cancer cells akin to diathermy. The area destroyed is limited to the immediate surroundings and the procedure is done by passing a needle through the skin and locating it within the lesion under ultrasound control. Microwave can also be used instead of radiofrequency.

Stereotactic ablative radiotherapy (SABR): This is an alternative modality of treatment using focussed high-dose radiotherapy to destroy liver lesions where surgery is not an option.

Histotripsy: It is a noninvasive ultrasound based therapy that uses high intensity pulsed and focused ultrasound to mechanically destroy tumour tissue in the liver. Focussed ultrasound creates microbubbles (cavitation) which expand and collapse creating 'liquefaction'. Most patients are treated on a day case basis with a single sitting of 1 to 3 hours. Once the tumour is liquified, the immune system does the clearance. This treatment has been approved by the NHS. Further studies are needed assess the complete clearance and side effects such as further spread. Bleeding is a complication. Early results are promising with regard to local control. Long term studies are awaited.

JAYPEE BROTHERS

Systemic therapy with tyrosine kinase inhibitors (TKI) such as sorafenib and lenvatinib that disrupt the intracellular pathways leading to cell destruction can be used in situations where surgical treatment cannot be offered (CRUK).

Liver transplant in hepatocellular carcinoma

Liver transplant can be used in selected patients where the tumour burden is small. It improves outcome in otherwise non-resectable lesions with cirrhosis.

Milan criteria for liver transplant was introduced in 1996 by Mazzaferro et al. The criteria are considered restrictive by some.

- A single tumour with a diameter of <5 cm
- Up to three tumours, each with a diameter of <3 cm
- No evidence of extrahepatic spread
- No evidence of macrovascular invasion

Child–Pugh score (ABCDE)

This scoring system gives an indication of the liver function and it classifies the severity of cirrhosis of the liver. It is, therefore, used to predict mortality in cirrhotic patients.

- A = Albumin level
- B = Bilirubin
- C = Coagulation – INR
- D = Deluge – ascites
- E = Hepatic encephalopathy

The Child–Pugh scoring system is from A to C, with C indicating the worst hepatic function.

Each factor is given points (1, 2, or 3) based on its severity.

- *Class A*: 5–6 points (well-compensated)
- *Class B*: 7–9 points (moderately decompensated)
- *Class C*: 10–15 points (significantly decompensated)

Cholangiocarcinoma

These are uncommon cancers. There are two types.

1. Intrahepatic cholangiocarcinoma
2. Extrahepatic cholangiocarcinoma

These can be:

- Perihilar *(Klatskin tumour)*
- Distal bile duct carcinoma

The presentation is normally with jaundice and unexplained weight loss.

Diagnosis is made with routine blood tests and liver function tests that show jaundice. *CEA and CA19-9* may be elevated.

Primary sclerosing cholangitis must be excluded.

Investigations may include:

- Endoscopic retrograde cholangiopancreatography (ERCP)
- *Endoscopic ultrasound examination (EUS):* This can also be used to get cytology.

JAYPEE BROTHERS

Radiological investigations include CT scan, MRCP, and MRI.

- *Percutaneous transhepatic cholangiogram (PTC)* may be needed in select cases where access is not possible via ERCP.

Treatment

Treatment is in specialised liver units.

It depends on the:

- Location
- Invasion
- Extent and spread

Very often these cancers are detected late and only *palliative treatment* may be feasible.

Gallbladder carcinoma

These, like the cholangiocarcinoma, are rare cancers that are seldom detected early. The presentation and work-up is similar to that of the cholangio carcinoma or chronic cholecystitis. Early-stage cancers that are limited to the gallbladder can be removed laparoscopically. Curative surgery is seldom possible when the cancer has spread beyond the confines of the gallbladder. Newer modalities of immunotherapy and targeted chemotherapy are currently being developed and studied.

Pancreatic malignancies

Gross anatomy of pancreas (Figure 3)

Pancreatic cancer (**Figure 4**) is the 10th most common cancer in the UK.

Presentation may be subtle and often missed in the early stages.

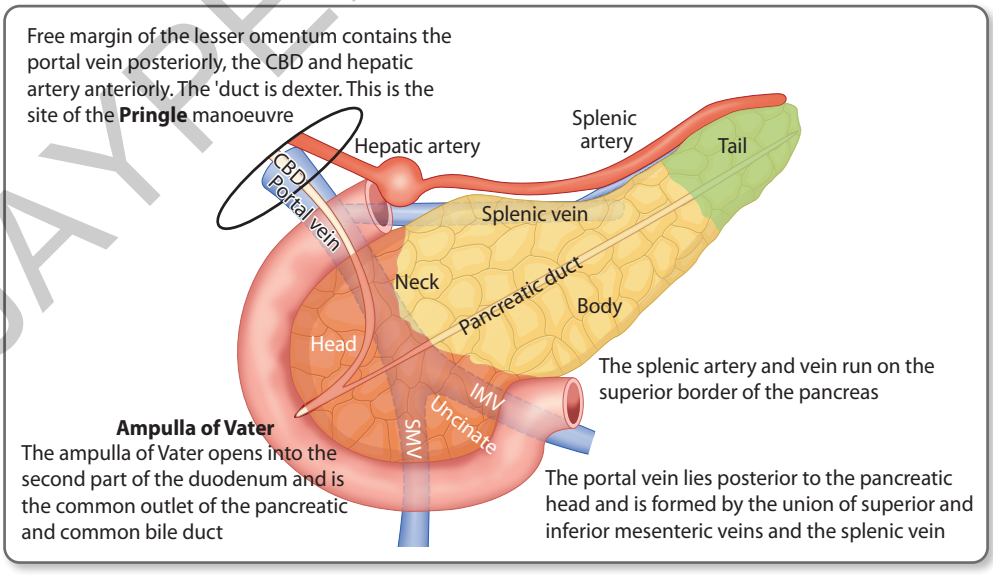

Figure 3 Anatomy of the pancreas.

JAYPEE BROTHERS

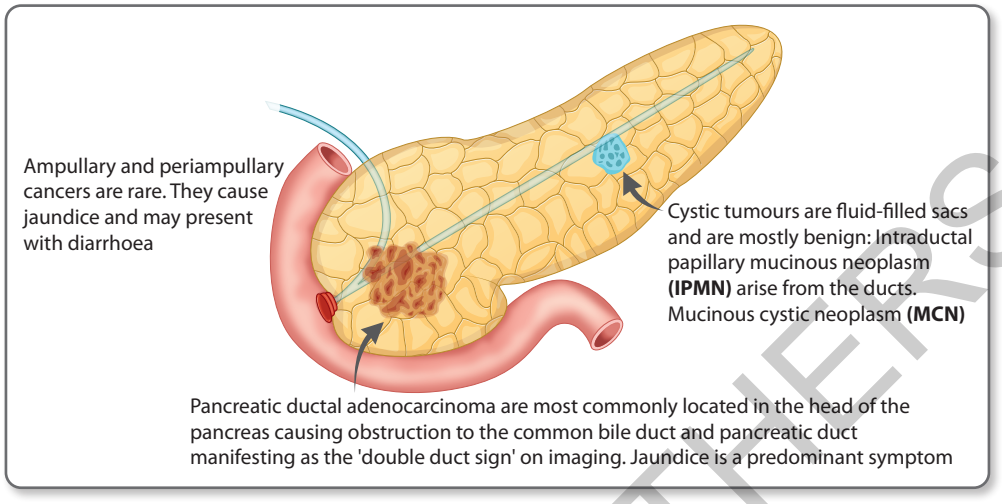

Figure 4 Exocrine pancreatic tumours.

Commonly it presents as:

- Painless progressive jaundice (obstructive)
- Pruritus
- Unexplained weight loss
- Diarrhoea
- Back pain
- Evidence of deep vein thrombosis (DVT) – migratory thrombophlebitis. Trousseau's sign of malignancy. This is a para neoplastic syndome, presenting mostly with migratory superficial and tender thrombosis, presenting as phlebitis.

In patients with obstructive jaundice, the liver function test will be grossly abnormal with an elevated ALP.

Tumour markers CA-19-9 (commonly found in the biliary system and is elevated in acute and chronic biliary disease and pancreatic cancers) and CEA may be raised.

Investigations are done to assess suitability for curative or palliative treatment and to aid in confirming the diagnosis with cytology or biopsy.

- *Endoscopy* may often be the initial investigation if the cause of the weight loss is unclear. In some situations, if the scope can be passed to D2 and a lesion noted, a biopsy for tissue diagnosis is invaluable
- *Endoscopic retrograde cholangiopancreatography* – may help to establish the diagnosis with a biopsy. Classically, the *double-duct sign* – a dilated common bile duct and a pancreatic duct may be seen on diagnostic ERCP. Biopsy or cytology can be carried out.
- *CT scan* – will define the extent of the disease within and around the pancreas. A triple phase of CT scan is used as this will not only pick up the tumour but also define its relationship to the main arteries and veins. It also picks up *pancreatic cysts.* Not all pancreatic cysts are malignant.
- *MRI or MRCP* of the pancreas will assist in clarifying the nature of the pathology. This is not normally needed but can be used to clarify the lesion.

JAYPEE BROTHERS

- *PET-CT* – This is done to quantify the total disease load and the presence of metastasis.
- *Endoscopic ultrasound (EUS):* This is of increasing value as it allows for ultrasound examination in close proximity to the pancreas. It helps to define cysts, aspirate tissue for cytology.

Pancreatic cysts

- *Intraductal papillary mucinous neoplasms (IPMN):* These arise in the ducts and secrete mucous thus forming a cyst. Depending upon the number of high-risk features such as duct size and the presence of nodules the risk of developing malignancy in main duct IPMN is 70% and for side-branch ducts is 20%.
- *Mucinous cyst neoplasms (MCN):* These arise in the body and tail of the pancreas and can turn malignant.
- *Serous cystadenoma (SCA):* These are non-cancerous and can be found anywhere in the pancreas.

Differentiating between mucinous and serous cystadenomas is important as the former has a malignant potential. The mucinous cystadenomas are larger cysts with calcification in the circumference, 'egg shell calcification'. The serous adenomas have a central stellate calcification and are microcystic. Density differences, measured in Hounsfield units, on CT scan can differentiate between these two but are thought to be unreliable.

Treatment

As always it depends on:

- The extent of the disease as quantified by TNM (**Table 1**)
- Nutritional status of the patient
- Suitability for surgery

Table 1 TNM category.

Category	Description
T1	Tumour 2 cm or less
T2	Tumour 2–4 cm
T3	Tumour larger than 4 cm but within pancreas
T4	Tumour involves adjacent structures/blood vessels
N0	No affected nodes
N1	1–3 nodes involved
N2	Four or more nodes involved
M0	No metastasis
M1	Presence of metastases

Surgery

Resection of part or whole of the pancreas may be carried out when a curative resection, that is possible in only about 20% of the patients can be carried out. The most common surgical operation for a resection of a tumour in the pancreatic head is a *pylorus preserving technique*.

JAYPEE BROTHERS

The classical operation should probably be called *the Kausch–Whipple pancreatoduodenectomy* as Walther Kausch, a German surgeon, first described a significant resection of the duodenum and pancreas in 1909 and *Allen Whipple,* an American surgeon, subsequently reported three resectional cases in 1935.

The Whipple's operation can be a massive undertaking and fraught with complications including a prolonged recovery. The principle of the operation involves resection of the malignant tumour in the pancreatic head with satisfactory clearance and reconstruction either through open, laparoscopic or robotic-assisted surgery.

The resection, apart from the lesion includes:

- Distal stomach
- Duodenum
- Common bile duct and gallbladder
- Adjacent lymph glands

Reconstruction is done with:

- Gastrojejunostomy – this may be done using a Roux-en-Y loop of jejunum
- Choledochojejunostomy
- Pancreaticojejunostomy

A modified operation with preservation of the pylorus is increasingly more commonly performed.

If the tumour is located distally, a distal pancreatectomy may be carried out.

Extended resections (Fortner operation types 1 and 2)

Where a cancer in the head of the pancreas is encroaching upon adjacent major vessels a superior mesenteric artery (SMA)-first approach can be used. To obtain clear margins a segment of portal vein can be resected with the tumour followed by an end-to-end anastomosis. Rarely part of the SMA can be taken and the artery re-anastomosed with or without a vein graft.

- *Type 1:* Includes resection of the pancreatic segment of the portal vein followed by end-to-end anastomosis *without a graft.*
- *Type 2:* Along with a type 1 resection, this includes resection of the involved artery most often either the hepatic or superior mesenteric artery. A primary arterial anastomosis can be carried out; where that is not feasible, a vein graft can be used.

These are major operations and carry a high risk of mortality and morbidity. Careful assessment and discussions of the risks and benefits with the patient and surrogates are needed.

Multimodality treatment: Chemotherapy alone and with radiotherapy can be given to patients prior to surgery in the form of neoadjuvant therapy if the primary tumour is considered borderline resectable due to involvement of major vessels. This may help achieve negative resection margins.

Adjuvant chemotherapy given after surgery is now the standard of care and has been shown to improve overall survival at 5 years from under 10% to nearly 30% (ESPAC-4 trial, Lancet, 389, 1011, 2017).

JAYPEE BROTHERS

Surveillance

The National Institute for Health and Care Excellence (NICE) recommends monitoring for pancreatic cancer in patients with:

- *Hereditary pancreatitis* with a fault in *PRSS1* gene
- *Peutz–Jegers syndrome:* There is a greater risk of bowel and breast cancer but also a risk for pancreatic cancer.
- *Two or more first-degree relatives* with pancreatic cancer, across two or more generations
- *Lynch syndrome and any first-degree* relatives with pancreatic cancer

Palliation

Unfortunately, many patients present late in the disease and palliative operations or treatment alone may be possible. The advent of ERCP has enabled stenting of the common bile duct to relieve the jaundice and pruritus and improve the quality of residual life which in many cases may only be a few months.

In patients with predominantly gastric outlet obstruction syndrome a gastro-jejunostomy anterior to the transverse colon may help to relieve the symptoms.

Chemoradiotherapy prior to surgery can be used to downstage the disease. More often than not, these are used for palliation to prolong life which must be balanced with the quality of residual life.

Survival rates in pancreatic cancer (Table 2)

Unfortunately most patients with pancreatic cancer present with late stage disease and efforts are required for earlier diagnosis. This is based on statistics from a study which included over 35,000 people diagnosed with pancreatic cancer in seven countries. These included Australia, Canada, Denmark, Ireland, New Zealand, Norway, and the UK. British Journal of Cancer, March 2022, Volume 126, pages 1774–82.

Table 2 Survival rates in pancreatic cancer at different stages.

Stages	Survival rate
Localised	55% survive 1 year 25% survive 3 years
Regional	50% survive 1 year 15% survive 3 years
Distant	10% survive 1 year 1% survive 3 years

Conclusion

Surgical resection remains the only potentially curative treatment for carcinoma of the pancreas, but it is feasible in only a small proportion of patients. Even in carefully selected cases, major pancreatic resections are technically demanding and associated with significant morbidity. Owing to the aggressive nature of the disease and its tendency for late presentation, the majority of patients are unsuitable for curative surgery at diagnosis. As a result, treatment in most cases is palliative, aimed at relieving symptoms and improving quality of life rather than achieving cure.

JAYPEE BROTHERS

Snippets in Surgery

This volume continues from Snippets in Surgery (volume 1) maintaining its concise and practical style while addressing the evolving needs of surgical trainees. It emphasises evidence-based practice, beginning with the fundamentals of scientific methods and progressing through key topics in oncology, trauma, nutrition, and general, plastic, paediatric, and endocrine surgery – areas essential to a well-rounded surgeon.

The book also includes illustrative cases from the author's personal experience, multiple-choice questions for self-assessment, and reflections on the progress of surgery over the past five decades. All figures and sketches have been hand-drawn by the author to highlight clarity of concept and understanding.

Designed as a companion to standard surgical texts, this is predominantly a single-author work with invited reviews from specialists in fields such as oncology, breast and upper gastrointestinal (GI) malignancies, nutrition and thyroid disease. It blends experience, insight, and precision – making it a valuable guide for trainees and practitioners alike.

Salient Features

- Continuation of the highly acclaimed Snippets in Surgery (volume 1) with updated and expanded content.
- Focussed on the practical needs of surgical trainees and practicing surgeons.
- Strong emphasis on evidence-based medicine and understanding of the scientific method.
- Covers essential topics including oncology, trauma, nutrition, general, plastic, paediatric, and endocrine surgery.
- Includes illustrative real-life cases with key learning points.
- Contains multiple choice questions with answers for self-assessment and quick revision.
- Features hand-drawn diagrams and sketches by the author to simplify complex surgical concepts.
- Offers concise and clear explanations designed for rapid review and concept reinforcement.
- Written as a single-author work, ensuring consistency, coherence, and clarity throughout.

Srinivasan Ravi served as a Consultant General Surgeon at Blackpool Teaching Hospitals and is currently a visiting Professor of Surgery at KS Hegde Medical Academy, NITTE (Deemed to be University) in Karnataka, India. He has over 40 years of surgical experience in the NHS UK and is dedicated to medical education. He was the Head of the Department of General Surgery and established Paediatric Surgery alongside Alder Hey Paediatric Hospital in Liverpool. In 2008, he introduced minimally invasive colorectal surgery and local anaesthetic hernia repairs at the Blackpool Teaching Hospital. He is a Member of the Court of Examiners at the Royal College of Surgeons of England. A gold medalist graduate from Mysore University, he completed his undergraduate studies at KMC Manipal/Mangalore and earned an MS in General Surgery from Madras University at JIPMER Puducherry (Pondicherry). Additionally, Professor Ravi served as a Surgical Tutor for the Royal College of Surgeons of England, where he was instrumental in establishing the first Basic Surgical Skills course in the Northwest of England. His role expanded as he became a STEP tutor and moderator for the Royal College and Postgraduate Tutor (Hospital Dean) at his institution. In this capacity, he managed the transition to the broad-based Foundation programme with his hospital being one of the select few chosen to pilot this initiative.

Professor Ravi, in conjunction with David Chang, a consultant and hepato-biliary surgeon, Blackburn Royal Infirmary, established intermediate and laparoscopic skills courses in the region. In 1999, he became a faculty member of the then newly established CCRISP course which he directs from time to time. As the Chairman of the Lancashire and South Cumbria Colorectal Cancer Network Site Specific Group, he contributed to the establishment of a hepato-biliary unit within the region to manage metastatic hepato-biliary cancers. He has an interest in gardening, quantum mechanics and ancient Indian Philosophy.

JP medical publishers

www.jpmedpub.com

ISBN 978-1-78779-199-2

9 781787 791992