3rd Edition

HAEMATOPATHOLOGY PEARLS

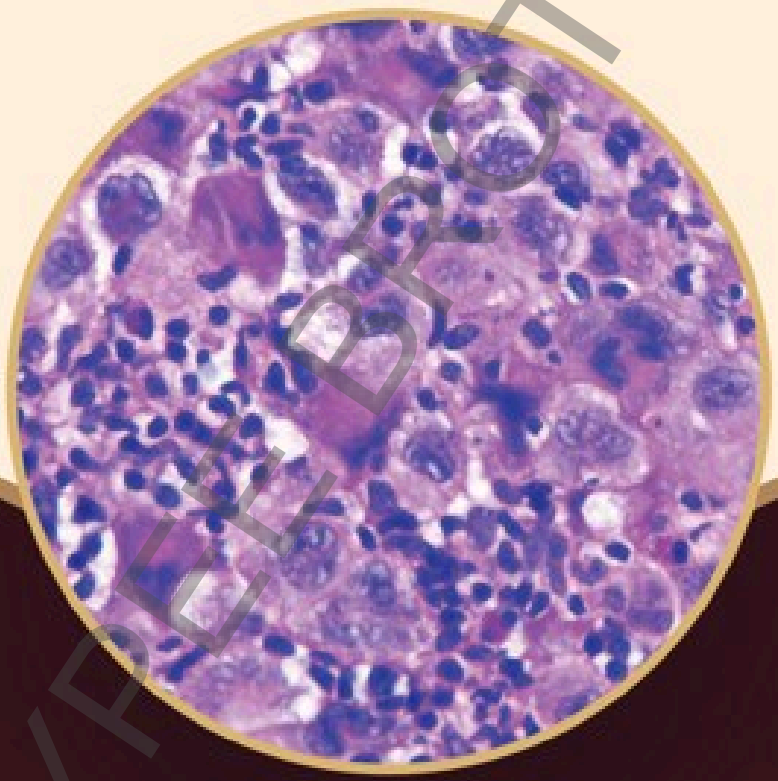

Da Zhang



JAYPEE BROTHERS

Contents

Preface		v
Acknowledgements		xiii
Chapter 1	Haematopoiesis and haematology testing	1
Chapter 2	Disorders of red blood cells	13
Chapter 3	Disorders of platelets and coagulation factors	49
Chapter 4	Disorders of non-neoplastic white blood cells	71
Chapter 5	Normal lymph node, thymus, lymphoid hyperplasia and tumour like lesions	85
Chapter 6	Spleen	107
Chapter 7	Myelodysplastic and myeloproliferative neoplasms	123
Chapter 8	Acute myeloid leukaemia and acute leukaemias of ambiguous lineage	191
Chapter 9	Acute lymphoblastic leukaemia/lymphoma, mature T- and B-cell leukaemias	233
Chapter 10	Non-Hodgkin lymphomas, plasma cell neoplasms, histiocytic/dendritic cell neoplasm and stroma-derived neoplasms of lymphoid tissues	271
Chapter 11	Hodgkin lymphoma	437
Chapter 12	Lymphoid proliferations and lymphomas associated with immune deficiency and dysregulation	451
Chapter 13	Flow cytometry	459
Chapter 14	Questions and answers	499
	Further readings	643
	Index	645

JAYPEE BROTHERS

12 Lymphoid proliferations and lymphomas associated with immune deficiency and dysregulation

Lymphoid proliferations and lymphomas associated with immune deficiency and dysregulation

- Hyperplasias arising in immunodeficiency and immune dysregulation (IDD)
- Polymorphic lymphoproliferative disorders (LPDs) arising in IDD
- Epstein–Barr virus (EBV)-positive mucocutaneous ulcer
- Lymphomas arising in IDD
- Inborn error of immunity-associated lymphoid proliferations and lymphomas

Hyperplasias arising in immune deficiency/dysregulation

- Reactive lymphoid hyperplasia due to underlying immune dysfunction
- Presents with lymphadenopathy, splenomegaly, and/or extranodal involvement
- Polyclonal proliferation with preserved architecture, lacking clonal rearrangements
- Generally benign but may progress to LPDs

Essential and desirable diagnostic criteria

Essential:

- Setting confirmed or highly suspicious for IDD
- Lack of architectural effacement; heterogeneous lymphoid and/or plasmacytic proliferations without atypia
- *One of the following three features*:
  1. Detection of EBV/EBER in tissue in the majority of hyperplasias
  2. Detection of Kaposi sarcoma-associated herpesvirus (KSHV)/human herpesvirus type-8 (HHV8) in multicentric Castleman disease
  3. Other specific features related to IDD [e.g. DNT cell proliferations in autoimmune lymphoproliferative syndrome (ALPS)]

JAYPEE BROTHERS

Polymorphic lymphoproliferative disorders arising in immune deficiency/dysregulation

- Heterogeneous lymphoid infiltrates with a mix of small and large lymphocytes, histiocytes, and plasma cells.
- Associated with chronic immunosuppression (e.g. post-transplant, congenital immunodeficiency)
- Often EBV-positive, showing variable expression of B and T-cell markers
- May exhibit partial architectural effacement but lacks defining features of lymphoma
- Risk of progression to overt lymphoma, necessitating close monitoring

Essential and desirable diagnostic criteria

Essential:

- Setting confirmed or highly suspicious for IDD
- Architectural effacement; polymorphous infiltrate with a spectrum of B-cell differentiation stages
- Atypical large cells positive for CD20 (variable), CD30 (variable), and PAX5
- EBV positivity demonstrated in tissue (EBV viral load measurements in the blood are not sufficient for diagnosis).

Desirable: IG gene rearrangement studies to support exclusion of hyperplasias.

Epstein–Barr virus-positive mucocutaneous ulcer

- Solitary, well-demarcated ulcer in mucosal or cutaneous sites, often in elderly or immunosuppressed patients.
- Histology shows a polymorphous infiltrate with prominent EBV-positive large B-cells.
- Typically self-limited but can mimic aggressive lymphomas histologically.
- Responsive to reduction in immunosuppression or conservative management.

Essential and desirable diagnostic criteria

Essential:

- Setting confirmed or highly suspicious for IDD
- Well-circumscribed shallow ulcer in mucosal or cutaneous sites with a polymorphous lymphoid infiltrate
- Atypical large cells positive for CD20 (variable), CD30 (variable), and PAX5

JAYPEE BROTHERS

- EBV positivity in tissue (EBV viral load measurements in blood are not sufficient for diagnosis).

Desirable: Band of CD3+ T cells at the periphery and at the base of the lesion.

Lymphomas arising in immune deficiency/dysregulation

- Encompasses a spectrum of B and T-cell lymphomas associated with immune dysfunction.
- Often EBV-driven, including post-transplant lymphoproliferative disorders (PTLD) and HIV-associated lymphomas.
- May exhibit aggressive behaviour with frequent extranodal involvement.
- Requires tailored therapeutic strategies, including immune reconstitution, antiviral therapy, or chemotherapy.

The current WHO classification no longer recommends the terms 'polymorphic PTLD' and 'monomorphic PTLD.' Instead, PTLDs are classified using the type of hyperplasia, EBV status (+/–), type of immunodeficiency, and the name of the lymphoma according to the type seen in immunocompetent patients, EBV status (+/–), KSHV status (+/–), and the type of immunodeficiency (e.g. DLBCL, EBV-, post-transplant setting/HIV setting/autoimmune setting/presumed immunosenescence setting) (**Figures 1a and b**).

Essential and desirable diagnostic criteria

Essential:

- Setting confirmed or highly suspicious for IDD
- Meets diagnostic criteria for corresponding lymphomas in immunocompetent patients.

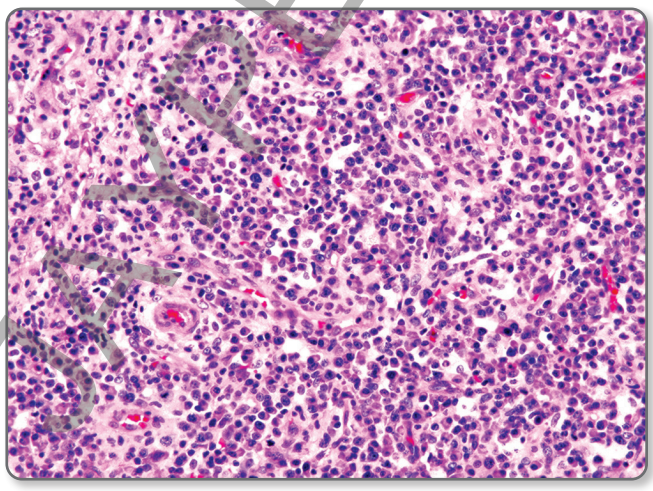

Figure 1a Polymorphic lymphoproliferative disorder, EBV+, post-transplant. Lymph node biopsy shows replacement of the normal architecture by a polymorphic infiltrate composed of small lymphocytes, larger activated lymphocytes, and plasma cells. Flow cytometry is negative for a monoclonal B-cell population. In situ hybridisation demonstrates a polyclonal plasma cell population and EBV positivity. EBV, Epstein–Barr virus.

TAYLOR & FRANCIS BROTHERS

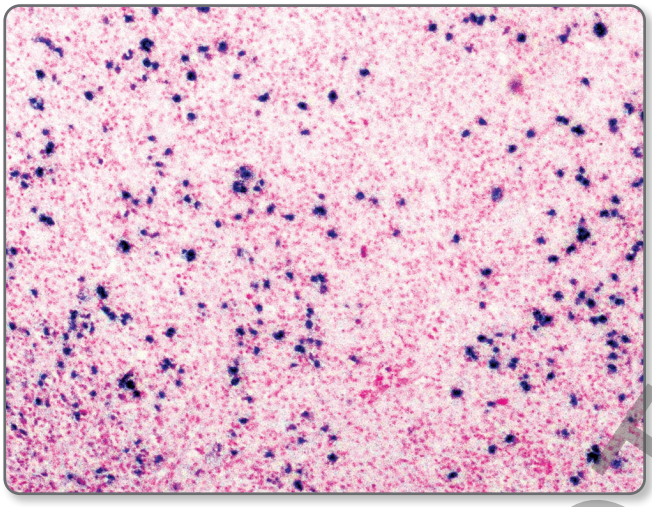

Figure 1b Diffuse large B-cell lymphoma, EBV+, post-transplant. In situ hybridisation for EBER demonstrates EBV-positive cells. Flow cytometry reveals a monoclonal B-cell population (lymph node biopsy). EBV, Epstein–Barr virus.

Desirable:

- Detection of EBV (EBER) and/or KSHV/HHV8 latency-associated nuclear antigen (LANA) in tissue (EBV viral load measurements in the blood are not sufficient for diagnosis)
- Demonstration of clonal B- or T-cell populations by molecular techniques in challenging cases.

Inborn error of immunity-associated with lymphoid proliferations and lymphomas

Inborn error of immunity (IEI)-associated with lymphoid proliferations and lymphomas (LPDs) include both reactive lymphoid proliferations and malignant lymphomas. They show a strong association with EBV and other viral infections, and molecular studies often reveal somatic mutations in immune regulatory pathways (see **Table 1**)

- Common variable immunodeficiency (CVID)
- Activated PI3Kδ syndrome (APDS)
- Hyper-immunoglobulin M (IgM) syndrome
- Agammaglobulinaemia
- Syndromic combined immunodeficiencies with malignancy predisposition [e.g. ataxia-telangiectasia (AT), Nijmegen Breakage syndrome (NBS)]
- Severe combined immunodeficiency (SCID), leaky SCID and Omenn syndrome
- Combined immunodeficiencies
- Thymic defects with additional congenital abnormalities
- Immuno-osseous dysplasias
- Hyper-immunoglobulin E (IgE) syndromes

JAYPEE BROTHERS

Table 1 Primary immune disorders associated with lymphoproliferative disorders.

Disorder	Clinical features	Epidemiology	Pathogenesis	Associated lymphoproliferative disorders (LPDs)
Common variable immunodeficiency (CVID)	Recurrent respiratory infections, autoimmunity, GI disease, and lymphoproliferation	Most common symptomatic primary immunodeficiency; onset often in late childhood or adulthood	Impaired B-cell differentiation and defective antibody production	DLBCL, MALT lymphoma, CHL and T-LGL
Activated PI3Kδ syndrome (APDS)	Recurrent sinopulmonary infections, lymphadenopathy and autoimmunity	Rare; autosomal dominant	GOF mutations in *PIK3CD* or *PIK3R1*, leading to dysregulated *PI3K* signaling	DLBCL, EBV+ B-cell lymphomas
Hyper-IgM syndrome	Recurrent bacterial infections, opportunistic infections and autoimmunity	Rare; X-linked (most common) or autosomal recessive	Defective class-switch recombination (CD40L, CD40 and AID defects)	DLBCL, CHL and plasmablastic lymphoma
Agammaglobulinaemia	Recurrent bacterial infections and chronic viral infections	Rare; X-linked (Bruton) or autosomal recessive	Defective B-cell development (BTK mutation in XLA)	Rare; some cases of B-cell lymphoma
Syndromic combined immunodeficiencies (e.g. AT and NBS)	Infections, progressive neurodegeneration (AT) and microcephaly (NBS)	Rare; autosomal recessive	DNA repair defects impair lymphocyte development	CHL, T-cell lymphoma and B-cell lymphoma
Severe combined immunodeficiency (SCID), leaky SCID, Omenn syndrome	Severe infections, failure to thrive, graft-versus-host-like rash (Omenn)	Rare; neonatal screening detects some cases	Defects in T-cell development and signalling pathways or DNA recombination repair	EBV+ B-cell lymphoma and T-cell lymphoma
Combined immunodeficiencies	Variable infections, autoimmunity and lymphoproliferation	Heterogeneous	Defects in T-cell signalling pathways or cytoskeletal proteins	B-cell lymphomas and CHL
Thymic defects with additional congenital abnormalities	Immunodeficiency with cardiac, craniofacial, or endocrine anomalies	Rare; 22q11.2 deletion (DiGeorge) most common	Developmental defect in thymus	Rare; occasional T-cell lymphomas

Continues overleaf

TAYPEE BROTHERS

Table 1 *Continued*.

Immuno-osseous dysplasias	Recurrent infections, bone abnormalities and growth failure	Rare	Genetic defects affecting immune and skeletal development	B-cell lymphoma, T-cell lymphoma
Hyper-IgE syndromes	Recurrent skin/lung infections, eczema, eosinophilia and connective tissue findings	Rare; AD (STAT3) or AR	Impaired Th-17 differentiation and immune signalling	B-cell lymphoma and CHL
Familial haemophagocytic lymphohistiocytosis (HLH)	Severe inflammatory episodes (fever, cytopenia and organomegaly)	Rare; often presents in infancy	T-cell hyperactivation	Lymphoma rare
Autosomal dominant immune dysregulation syndrome	Autoimmunity, lymphoproliferation and infections	Rare	*CTLA4* gene abnormality	CHL and B-cell lymphoma
Regulatory T-cell defects	Autoimmunity, immune dysregulation and organ infiltration	Rare	*FOXP3* defects (IPEX)	Lymphoma rare
Autoimmune lymphoproliferative syndrome (ALPS)	Splenomegaly, lymphadenopathy, lymphoproliferation and autoimmunity	Rare; often childhood onset	Defective FAS-mediated apoptosis	CHL, NLPHL, DLBCL and T-cell lymphoma
EBV susceptibility and B-cell lymphoproliferation	Severe EBV infections and chronic active EBV	Rare; childhood onset	Defective EBV-specific immunity (e.g. *SH2D1A* in XLP)	EBV+ DLBCL, CHL, Burkitt lymphoma and other PTLDs
Subcutaneous panniculitis-like T-cell lymphoma (SPTCL) with germline *HAVCR2* variants	Inflammatory panniculitis, cytopenias and HLH	Very rare; paediatric/young adult onset	*HAVCR2* mutations impair immune homeostasis	SPTCL (primary) and risk of HLH

CHL, classical Hodgkin lymphoma; DLBCL, diffuse large B-cell lymphoma; T-LGL, T-cell large granular lymphocytic leukaemia.

- Familial haemophagocytic lymphohistiocytosis (HLH) syndromes
- Autosomal dominant immune dysregulation syndrome
- Regulatory T-cell defects
- Autoimmune lymphoproliferative syndrome
- EBV susceptibility and B-cell lymphoproliferation
- Subcutaneous panniculitis-like T-cell lymphoma (SPTCL) with germline *HAVCR2* variants.

JAYPEE BROTHERS

Essential and desirable diagnostic criteria

Essential:

- The diagnostic criteria for EBV+ B-cell LPD are the same as those listed in the section LPDs.
- The diagnostic criteria for lymphoma are the same as those for sporadic lymphomas.
- EBV status must be assessed, and the immunodeficiency background (IEI) should be mentioned.
- A diagnosis of a granulomatous and/or CD8+ T-cell–rich lesion requires exclusion of an infectious aetiology or occult malignancy, such as T-cell/histocyte–rich B-cell lymphoma or overt T-cell lymphoma.

Desirable: Molecular classification, including germline genetic testing for the underlying IEI.

JAYPEE BROTHERS

HAEMATOPATHOLOGY PEARLS

This concise haematopathology review is designed as a practical study guide for medical students, residents, and fellows preparing for training and board examinations. Organised into 13 chapters with accompanying question-and-answer sections, the book covers key concepts in haematopoiesis, haematologic disorders, lymphoid neoplasms, flow cytometry, and molecular pathology, with an emphasis on essential diagnostic principles and morphology. Originally developed from focused teaching notes, this third edition has been extensively revised and updated to incorporate recent advances in the field, including the WHO 5th Edition Classification and the International Consensus Classification (ICC) of haematolymphoid neoplasms. It provides clinically relevant, up-to-date content aligned with current educational and diagnostic standards.

JAYPEE BROTHERS

JP medical publishers

www.jpmedpub.com

ISBN 978-1-78779-204-3