

COMPLEX INJURIES OF THE HAND



Tahseen Cheema
Foreword by Moheb S. Moneim

JP

21/03/2014 18:01

Contents

Foreword v

Preface vii

Contributors xi

BASIC PRINCIPLES

Chapter 1
Introduction 1
Tahseen A. Cheema

Chapter 2
Elements of complexity in hand injuries: what makes a hand injury complex? 3
Tahseen A. Cheema

Chapter 3
Complex hand injuries: evaluation and diagnosis 13
Tahseen A. Cheema

Chapter 4
Imaging in hand injuries 25
Gary W. Mlady

Chapter 5
Anesthesia for hand injuries 39
Firoz S. Vagh, Christopher Arndt, Randy L. Rosett

Chapter 6
Principles of treating complex hand injuries 51
Tahseen A. Cheema

Chapter 7
Hand therapy 75
Kate A. Steinberg, Patricia Siegel, Lynn Hatfield

TREATMENT OF DIFFERENT TISSUE SYSTEMS

Chapter 8
Fractures and dislocations 89
Barbara Jemec

Chapter 9
Wrist injuries 101
Jorge L. Orbay, Michael R. Mijares

Chapter 10
Complex injuries to the flexor mechanism in the hand and the forearm 115
S. Raja Sabapathy, David Elliot

Chapter 11
Extensor tendon injuries 129
Deana Mercer, Tahseen A. Cheema

Chapter 12
Nerve injuries 143
James Jung, Ranjan Gupta

Chapter 13
Skin coverage in complex hand injuries 153
Tahseen A. Cheema

INJURIES RESULTING FROM SPECIAL MECHANISMS

Chapter 14
Hand burns and frostbite 171
Mamoon Rashid

Chapter 15
Blast injuries of the hand 183
Mamoon Rashid

USE OF SPECIAL TECHNIQUES

Chapter 16
Secondary reconstruction in complex hand injuries 197
Tahseen A. Cheema

Chapter 17
Development of microsurgery and its impact on the management of complex hand injuries 219
Robert R. Schenck

Chapter 18
Microsurgery and complex hand injuries 233
S. Raja Sabapathy, Praveen Bhardwaj

Chapter 19
External fixation in complex hand injuries 255
Haroon ur Rashid, Tahseen A. Cheema

Index 267

Chapter 2 Elements of complexity in hand injuries: what makes a hand injury complex?

Tahseen A. Cheema

INTRODUCTION

There is such a wide range of the possible causes and nature of hand injuries that it is hard to provide an exact definition of a complex hand injury. A hand injury may be considered complex on account of many factors that include the mechanism of injury, the nature of the local anatomy in a particular injury, the number of tissue systems involved, and any associated injuries and comorbidities. Any factor that increases the chance of infection or affects the vascularity in a hand injury may also add to the complexity of the injury. The time elapsed between the injury and the treatment can affect both factors and make a relatively simple injury into a more complex one.

MECHANISM OF INJURY AND NATURE OF CAUSATIVE AGENT

The mechanism and force of injury is one of the most important factors determining the nature and extent of the damage done to the tissues in a hand injury and to a large extent affects the eventual recovery and outcome. The causative agent determines directly the kind of lesion encountered. Sharp instruments such as knives, tin sheets, and glass produce clean-cut or 'tidy' wounds. Such wounds usually have minimal contamination; tendons and nerves are commonly injured but fractures are rare. If crushing or avulsion is the main result of a causative agent, the resultant wound is 'untidy,' grossly contaminated, and the tissues may have variable viability. These injuries can result from industrial and farm machinery, road traffic accidents, and a plethora of other mechanisms.

Crushing and avulsion injuries

The most common cause of major hand injuries is the use of mechanical equipment (industrial, farm, or household) (Trybus et al. 2006). These injuries invariably show some element of crushing and avulsion. Motor vehicle accidents also result in significant crushing of tissues, characteristically associated with deep abrading wounds of the dorsum of the hand, which can remove a large part of the skin, underlying tendons and dorsal surface of metacarpals and phalanges (**Figure 2.1**). These injuries are open and are associated with variable amounts of local maceration and devitalization of tissues, multiple fractures, and ragged skin flaps. Multiple tissue involvement, compromised viability either locally or of the whole hand, and a risk of infection due to contamination and tissue necrosis are the factors contributing to the complexity of the injury. All structural systems including skin, muscle, vasculature, and bone/joints may be affected. In a crushing injury, fractures can be multiple and are usually open. Diaphyseal fractures are commonly comminuted, displaced, and grossly unstable, with partly devascularized or even extruded fragments. In the metaphyseal and articular areas, fractures may be displaced, impacted, or associated with a loss of articular fragments. Restoration of skeletal stability and preservation of mobility becomes a challenge. Associated injuries to soft tissues may include damage to arterial and venous vascularity from rupture, subadventitial tear, or intimal damage resulting in ischemia or devascularization locally or distally. Crushing injury to muscles results in tearing of the fascia, rupture of muscle substance, avulsion from the origin or insertion, devascularization, denervation, or a variable combination thereof, making the wound prone to compartment syndrome and infection. Tendons, even when they are not ruptured, usually have surface abrasions, interfascicular tears and destruction of nutrient pathways, with enormous tendency to adhesion formation. Even when there is no actual loss of skin, it can be ischemic, separated from deep structures along the deep or superficial planes with rupture of septal or fasciomuscular nutrient vessels. This makes it difficult to assess the degree and extent of the skin injury, its viability and ability to provide coverage and potential nutrient support for the healing of traumatized deeper structures. Difficulties in the precise initial assessment of injury and viability, the potential for infection, and the destabilization of the skeletal framework, as well as the need for immobilization make functional restoration particularly problematic in these injuries.

Roller injuries may be open or closed. Closed injuries consist of compression of the soft tissues, which may result in skin necrosis, or tearing and separation of the skin and soft tissues from the deep fascia and bones and might need decompression. Open injuries commonly produce distally based avulsion flaps with doubtful viability (**Figure 2.2**). Such flaps usually die and predispose to deep infection. The tissue damage depends on the space between the rollers, the speed of the rollers, the hardness of the rollers, the temperature of the rollers, and how violently the patient attempts to withdraw the entrapped part



Figure 2.1 Crush injury resulting from motor vehicle accident. Dorsal skin and extensor tendons are lost with tangential loss of multiple carpal bones.

JAYPEE BROTHERS



Figure 2.2 Roller injury of the hand. There are multiple fractures, skin flaps of undetermined viability, and avulsion injury to the fingers.



Figure 2.3 Saw injury. Incomplete amputation with multiple fracture and loss of tissue.

(Sanguinetti 1977). Tendons and nerves may be contused or avulsed. If vessels are disrupted or thrombosed, interpositional vein grafts may be needed to establish blood flow.

Punch press injury may be very severe, consisting of comminuted multiple fractures, carpal disruption, and soft tissue crush. Tendon and nerve injuries are often at two levels, corresponding with either side of the recess in the punch. Saw injuries are common and may be associated with significant local tissue loss corresponding to the width and set (deflection in the saw teeth from a straight line) of the blade. Wide set blades cause avulsion of tissues in addition to cutting (**Figure 2.3**). This makes anatomical reduction of fractures, revascularization, or replantation difficult.

Agricultural machinery and lawnmower injuries cause not only substantial physical damage to multiple tissues but also are particular hazardous due to the increased likelihood of infection (Angoules et al. 2007). Old, dirty machinery is often involved in these accidents. Tractors, corn pickers, conveyor belts, mowers, and common shop equipment are the common causes. Wounds are usually grossly soiled and bacteria, aerobic and anaerobic, actinomycoses, and fungi form the largest part of soil's microbial population. This necessitates early and aggressive debridement and irrigation and broad antimicrobial coverage including aminoglycosides. Immunization status should be documented and if there is a history of tetanus toxoid in previous 5 years, tetanus immunoglobulins are indicated.

High-pressure injection injuries

High-pressure injection injuries to the hand are potentially devastating and can lead to permanent functional loss or amputation. The most commonly injected materials include diesel, grease, hydraulic fluid, oil, paint, paint thinner, and automotive undercoating. The location of injury, the pressure of the injection gun, and the material injected contribute significantly to the need for amputation. Injections occurring at pressures > 70.3 kilogram-force/square centimeter (1000 psi) carry a higher risk of amputation than injuries sustained at lower pressures. The final location of the injected material depends on the angle of entry, depth of penetration, and resistance of the tissue it contacts. If the stream strikes perpendicular to the bone or a rigid pulley, the material usually deflects laterally, compressing the adjacent neurovascular bundle. Injections over the joints of a digit can penetrate through the thin pulleys in these regions and enter the tendon sheaths. The material advances along the tendons proximally into the forearm. The amputation rate after these injuries can be as high as 30% and is highest after injection of organic solvents into the fingers (Hogan & Ruland 2006). The initial benign appearance of the injury may fool patients into seeking medical treatment, lull primary care providers into inadequate treatment, and delay appropriate surgical intervention (**Figure 2.4**). Most high-pressure injection injuries present as innocuous wounds with minimal symptoms. But very soon, pressure from the injected material and inflammatory response provoked by the material causes the part to swell, compromising blood flow to the part and resulting in vasospasm and thrombosis. Evaluation and proper treatment hinge upon early recognition of the severity of the injury and prompt surgical intervention. X-rays may show the proximal spread of the injected material, either by the presence of a radio-opaque signal or by the evidence of lucent areas that represent either injected radiolucent material or injected air. Water and air seem to be less toxic to the tissues than other injected materials, as these injuries have been treated both surgically and non-operatively with routine recovery of motion and no reports of amputation. For injections other than water and air, early surgical debridement, removal of injected material to decompress the vascular system, copious irrigation with normal saline or lactated Ringer's solution to dilute the concentration of the injected material, and use of antibiotics to prevent infection are the essential elements of treatment. Administration of steroids should be considered when treating patients with injections of organic solvents (Schoo et al. 1980).

Gunshot injuries

Complexity in gunshot injuries to the hand is manifold. Gunshot wounds are typically classified as low velocity (<2000 feet/s) or high velocity (>2000 feet/s) (Bartlett 2003). However, injury severity is determined by the efficiency of energy transfer, which is dependent in turn on the projectile's physical characteristics, kinetic energy, and entrance profile, as well as the path traveled in the body, the multiplicity of tissue systems involved, and the actual anatomical location in the hand and upper extremity. Low-energy injuries are

JAYPEE BROTHERS

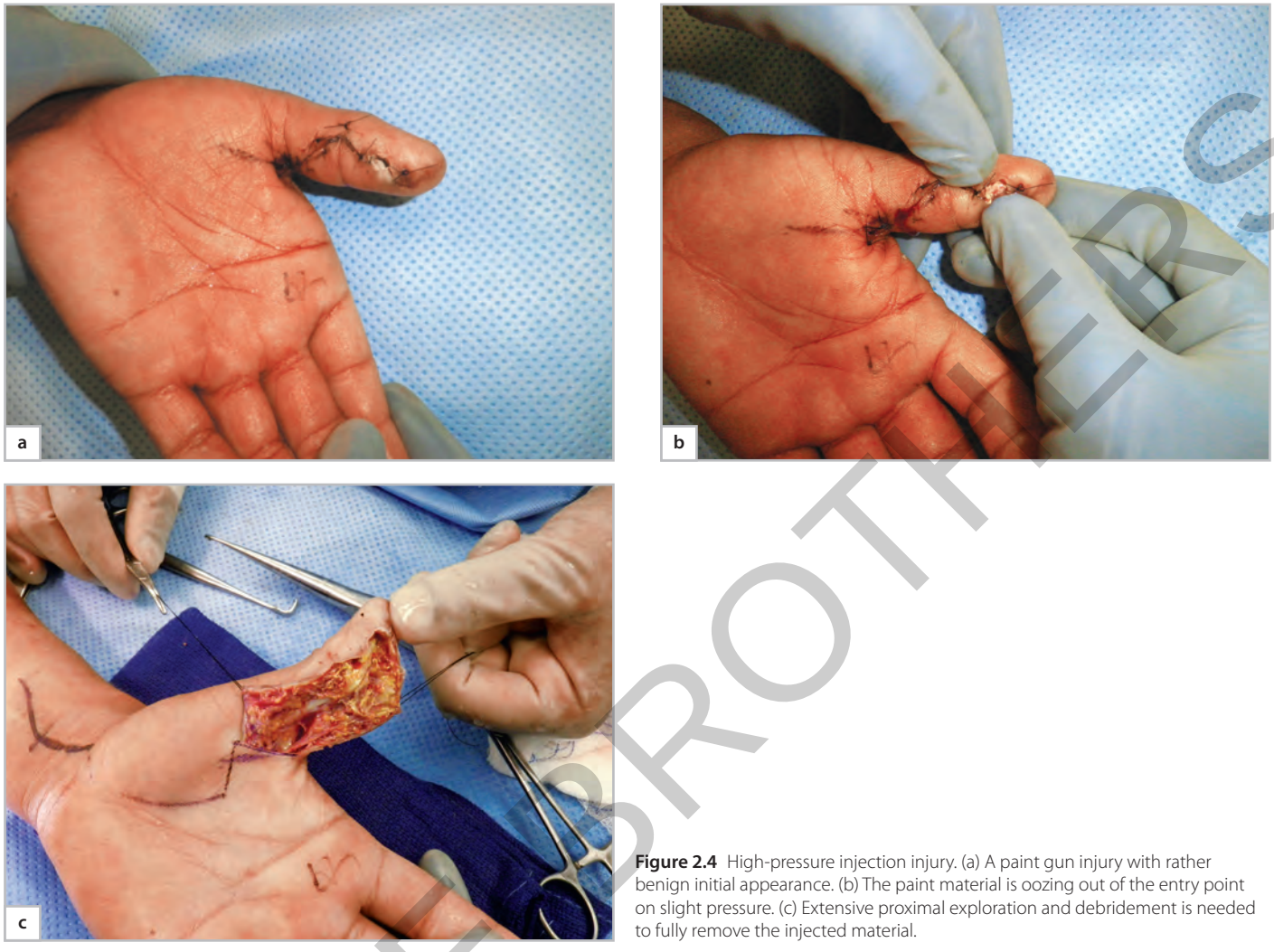

Figure 2.4 High-pressure injection injury. (a) A paint gun injury with rather benign initial appearance. (b) The paint material is oozing out of the entry point on slight pressure. (c) Extensive proximal exploration and debridement is needed to fully remove the injected material.

caused by small-caliber handguns, ball-bearing (BB) guns, and zip guns. There is less tissue damage, the infection rate is low and treatment is relatively simple. High-energy injuries result from high-caliber handguns or assault rifles (Wilson 2003). The greater energy transfer leads to more severe tissue damage. These injuries involve multiple tissue types such as skin, muscles, tendons, bones, joints, and nerves. Fracture comminution and bone loss may indicate the energy delivered by the projectile. Soft tissue damage is usually more widespread than is initially apparent. Infection may result from contaminated or devitalized tissues. Treatment and functional rehabilitation is difficult, requiring multistaged surgeries, and amputation is a serious possibility. Shotgun injuries lead to severe tissue damage because of the dispersal of pellets and material (**Figure 2.5**). Depending on the distance of the injured hand from the barrel, the pellets can be concentrated or spread over a wide area, resulting in devastating tissue damage and endangering the survival of parts. Treatment, as a rule, is difficult and prolonged.

In severe gunshot wounds, complexity arises from the difficulty in assessing damage initially and the fact that the multiple tissue systems injured have conflicting requirements for repair and rehabilitation.

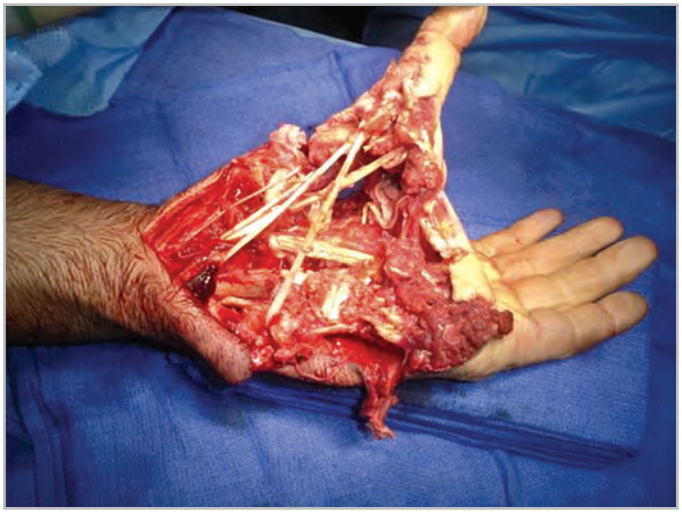

Figure 2.5 Shotgun injury. This close range shotgun injury resulted in massive tissue disruption and eventual loss of the thumb.

TAYLOR & FRANCIS

Treatment concepts include identification of injured structures and aggressive wound debridement and irrigation. Once vascularity is assured or reestablished, skeletal stabilization is the next priority. Rigid fixation will eliminate the need for prolonged immobilization, facilitate repair of other structures, and allow early rehabilitation. However, one should avoid extensive tissue stripping to achieve the best fixation. In case of bone loss, it is important to maintain bone length by Bayonet K-wires or external fixation and manage the gap with bone grafts at a more appropriate time in the future. In situations where articular surfaces have been damaged beyond reasonable restoration, external fixation can maintain length for later arthrodesis, arthroplasty, or articular grafting. Skin coverage is the next priority. If there is significant skin loss and important structures are exposed, a flap consisting of vascularized dermis and preferably a fascial layer will be needed. The hand surgeon dealing with these injuries should have knowledge of a wide variety of flaps, ranging from local flaps, reverse flow island flaps such as the radial forearm flap, or posterior interosseous flaps to free vascularized tissue transfer to best match the individual situation and need. Multiple tissue injury may provide innovative opportunities for composite tissue reconstruction by microsurgical techniques. Repair of tendons and nerves in more complex injuries depends on the extent of damage to the individual structure, the vascularity of the surrounding tissues, and the availability of adequate skin coverage. Overzealous primary repair of these structures under suboptimal conditions generally results in stiffness and functional failure. Early surgical reconstruction within a week or so and the initiation of quick rehabilitation remain good principles (Rodrigues et al. 2006).

The location of injury is critical. For injury to a solitary finger, options include surgical repair or amputation. Loss of one finger is not a cause of great functional deficit and amputation should be a consideration before any heroic attempts at salvage. However, if the thumb is involved, a serious attempt to salvage is always justified. Injuries to the palm are problematic, especially when they involve more than one ray. Gunshot injuries at the wrist level can result in extensive osseous and articular damage. A stable—although stiff—wrist is well tolerated. Wrist fusion can be performed when intra-articular damage is significant. Wrist level injuries are commonly associated with radial and ulnar arterial injury and median and ulnar nerve injury. In the case of arterial damage, vascular restoration becomes the priority. Nerve repair or reconstruction with a nerve graft can wait, but it is necessary for functional recovery. Proximal injuries lead to a more distal deficit. A vascular injury, even when incomplete, may result in distal symptoms and nerve injuries that require regeneration over long distance result in poor functional recovery. A gunshot blast may be complicated by causalgia and reflex sympathetic dystrophy, making rehabilitation extremely difficult.

Explosion injuries (firework, blast, and warfare injuries)

Common to these injuries is the tremendous amount of energy being spent at close range to the tissues. This results in mutilation of tissues and loss of parts of the hand and the upper extremity. Blast injuries to the hand are rare during peacetime and are mainly caused by fireworks and firecrackers (**Figure 2.6**). The majority of these injuries occur during the New Year celebration in the West and marriage celebrations in South East Asia (Giessler et al. 2006). The injury patterns show a combination of different types of tissue destruction including laceration, avulsion, crushing, and burning. Multiple fractures and bone loss are common (Frank et al. 2008). Larger shells cause traumatic subtotal amputations of the fifth finger ray and thenar ray, and small explosives generally result in multiple lacerations in the palm, subcutaneous flexor tendon ruptures and closed finger tip fractures. Giesssler et al. (2006) reviewed 50 cases of firework injuries and graded them according to Hand Injury Severity Score (HISS). There were 18 'minor' (HISS < 20), 16 'moderate' (HISS 21–50), 7 'severe' (HISS 51–100), and 9 'major' (HISS > 100) explosion injuries.

Wartime injuries pose additional challenges due to the lethal firepower of modern warfare and other life-threatening injuries in the body compounded by the situational difficulties of the war. Progress in the development of better safety equipment for troops and the availability of skilled surgical facilities close to the injured and with rapid evacuation times have dramatically reduced the rate of mortality and the morbidity in recent American wars (Hofmeister et al. 2007). Along with these improvements, the percentage of the injured extremities has increased, and injuries to the extremities now account for 70% of all injuries. The weapons causing these injuries include improvised explosive devices, mortars, rockets, rocket-propelled grenades, and guns of various types, resulting in high-energy wounds (**Figure 2.7**). Military personnel who are protected by body armor and helmets show an increased preponderance of extremity injuries as opposed to civilian casualties who sustain more penetrating trauma to the chest, abdomen, and pelvis due to the absence of body armor. Gunshot wounds tend to affect a single body area with a single entry and exit wound, whereas blast injuries tend to involve multiple areas, such as the head, neck, torso, and extremities. These injuries are commonly associated with varying degrees of burns.

Blast injuries of the hand need a fast and strategically planned surgical approach. Restoring tissue perfusion, early debridement and irrigation, skeletal stabilization and staged reconstruction is essential. Serial debridement may be necessary and delayed closure helps to avoid serious infections. The negative-pressure wound dressing has improved wound care in these situations. For skin coverage, a stepwise systemic approach is applied to ensure use of the simplest method, which will result in optimal functional outcome. Local rotational, pedicled flaps, and fillet flaps are preferred over free flaps. Major skeletal injuries are stabilized with external fixators and strategically placed K-wires can restore the stability and maintain length in the



Figure 2.6 Explosion injury. A low explosion injury from a firecracker resulted in volar tissue disruption and multiple fractures.

JAYPEE BROTHERS

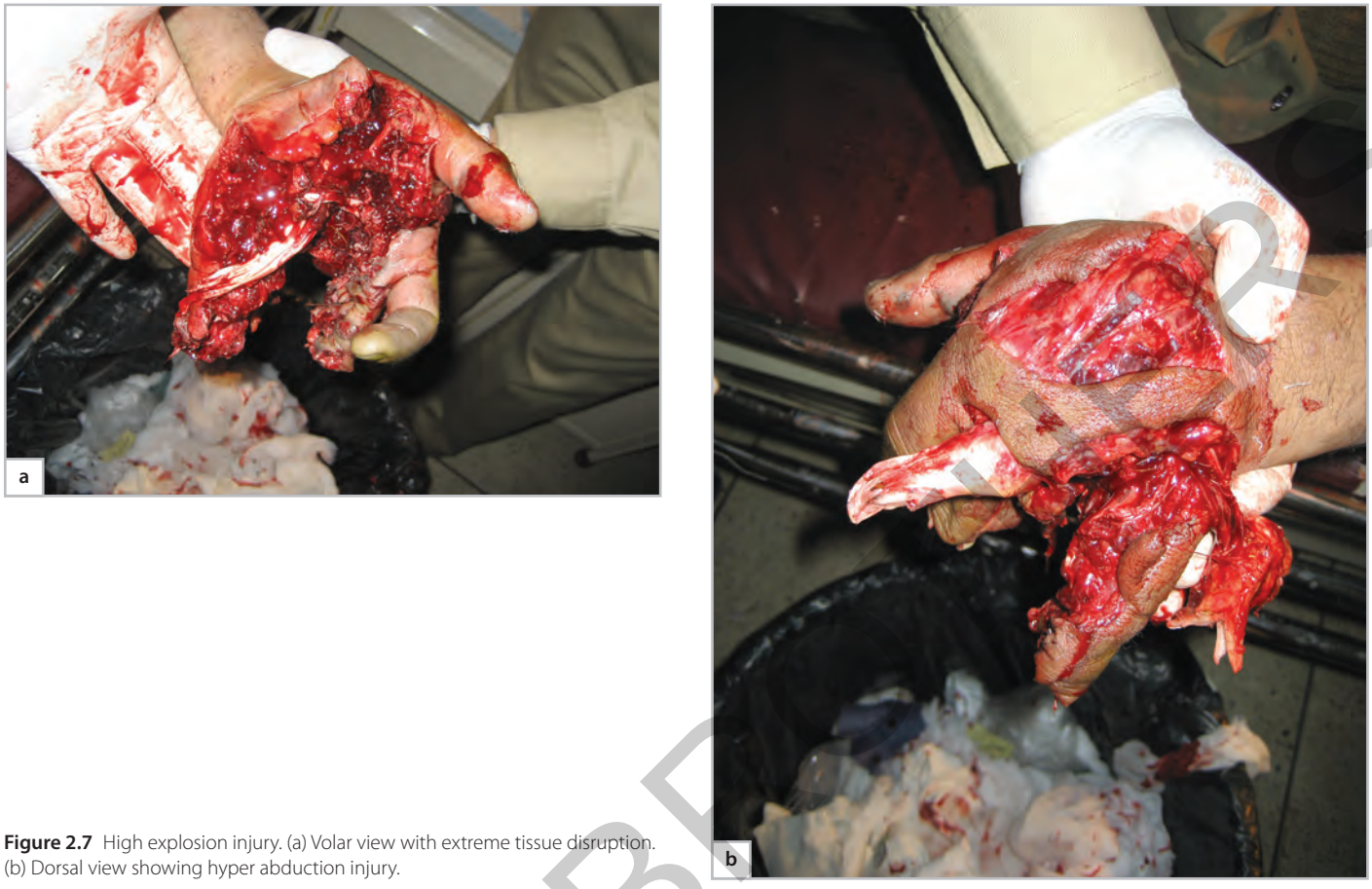

Figure 2.7 High explosion injury. (a) Volar view with extreme tissue disruption. (b) Dorsal view showing hyper abduction injury.

hand. Prevention of infection remains a major concern due to severe contamination in the battlefield wounds, the large size of devitalizing wounds, and the possible delays in the definitive treatment. Profound skills in reconstructive and microvascular hand surgery are needed to achieve optimal functional outcome in these severe injuries.

Thermal and electric burn injuries

Although the hands comprise <3% of the body surface, burn injuries of the hand are classified as severe injuries and require treatment in specialized burn centers. The complexity in hand burns is threefold:

1. Burns of the hand may be associated with extensive burns of other areas in the body, requiring the focus of early treatment to be on the resuscitation and survival of the patient. In these circumstances, there is always a possibility that hand burns are neglected and may not receive appropriate early treatment. Optimal hand burn management requires some important decisions, such as the necessity for escharotomy or fasciotomy, to be made in the early post-traumatic period
2. Determination of the depth and dimension of the burn is difficult and is shown to be accurate in only 60--75% of cases, even when carried out by an experienced hand surgeon (Kamolz et al. 2009). Clinical assessment remains the most frequently applied technique to determine the depth of the burn (**Figure 2.8**). There are other modalities available that may be useful to provide an objective assessment of the burn depth. These include various perfusion techniques, thermography, and laser Doppler techniques. The special anatomical characteristics and functional demands of the hand can pose daunting challenges to the treating surgeon in his efforts to preserve and restore hand function
3. Most deep and full thickness burns of the hand affect the dorsal surface as the hands are used to protect the face. The dorsal skin is thin, loose, and flexible, allowing maximum excursion of extensor tendons and joint mobility. The tendinous and neurovascular structures and joints lie very close to the skin surface. These structures are very vulnerable when exposed to high-thermal trauma. The skin is especially thin over the proximal interphalangeal joints and involvement of extensor tendons is common. Intricate hand function depends on the coordinated interplay of extrinsic and intrinsic muscles, tendons, joints, and sensory feedback. This delicate balance is easily disturbed in burn injuries and is difficult to restore. Although adequate treatment in the acute phase determines the final outcome to a large extent, sometimes deformities like clawing of the fingers, joint contractures, web space deformities, hypertrophic scars, and nail bed deformities cannot be avoided, even under optimum surgical and physical therapy treatment

High voltage electrical injuries are often life-threatening and are a primary cause of bilateral high upper extremity amputations. The extent of tissue damage is determined by current voltage, duration of contact, tissue resistance, and the pathway of the electrical flow through the body (**Figure 2.9**). The heat generated by the electrical current causes coagulation necrosis of structures including muscles, tendons, blood vessels, and nerves. Intravascular thrombosis can be

JAYPEE BROTHERS



Figure 2.8 Contact thermal burn. Evaluation of depth of the burn remains mostly a clinical judgment.



Figure 2.9 High-voltage electrical burn. After repeated debridements the patient developed late necrosis of the fingers and eventually lost his hand.

quite extensive, leading to ischemia and loss of the limb. Severe muscle destruction results in compartment syndrome and a clinical picture such as 'crush-syndrome' can ensue. Tissue decompression is central to the successful treatment of electrical injuries in the acute phase. One of the major difficulties in the management of electrical injury lies in assessment of the extent of necrosis. This may become obvious only with time and require repeated debridements (Danielson et al. 2000). A particular challenge is posed by either compound or very large defects as a result of multiple debridements. These defects may require composite tissue free flaps or several free flaps to avoid the amputation (Sauerbier et al. 2007).

COMBINED INJURIES AS A CAUSE OF COMPLEXITY

Combined injuries involve two or more separate but functionally relevant structural systems, at a specific location. In combined injuries, the ultimate functional outcome is not only affected by the individual tissue systems involved but also by the multiple interactions and restraints among different tissue systems at a particular location. While an isolated extensor tendon injury or a fracture of proximal phalanx will heal with little or no functional deficit, the combination of both in the same area can make it a significantly difficult problem to deal with. All of the elements involved in a system of motion, such as bones, joints, muscles, and tendons are highly interactive and mutually potentiate the adverse effects of injury, especially when associated with immobilization (Buchler 1990).

Volar combined injuries include damage to volar skin, neurovascular structures, flexor tendons, and skeletal elements, each structural system affecting the functional recovery of other structures adversely (**Figure 2.10**). Unless early skeletal stability can be achieved to allow early mobility, joints will become stiff and tendon repairs will be engulfed in unyielding scar tissue. Although dorsal structures may be uninjured, their functional preservation cannot be taken for granted. Edema, fibrosis, and immobilization can make joints and extensor mechanisms stiff and adherent. This will in turn act as a negative restraint on the functional healing capacity of the volar structures that needed repair. Therefore, preservation of intact structures becomes as important as the need to repair and restore the injured structures.

Dorsal combined injuries involve skin, extensor apparatus, and bone and/or joint (**Figure 2.11**). There are at least two interactive restraints that can affect functional recovery. Associated fractures can cause adhesions of the flexor and extensor apparatus and contracture of dependant joints, especially if immobilization is required. The quality of skin coverage also determines the ultimate result to a large extent. Combined volar and dorsal injuries show variable injury to both sides and are more complex as all components of the system of motion are at risk (**Figure 2.12**). Extrinsic flexor and extensor mechanisms, as well as the intrinsic mechanism and skeletal structures, are involved in different combinations. Each system can exert a negative influence on the functional recovery of the other. Local



Figure 2.10 Volar combined injury. There is loss of skin, neurovascular structures, and tendons.

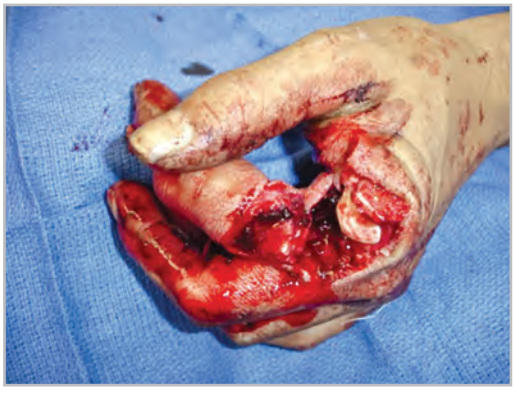

Figure 2.11 Dorsal combined injury. There is loss of skin, extensor tendon, and fracture of proximal phalanx of the index finger.

JAYPEE BROTHERS

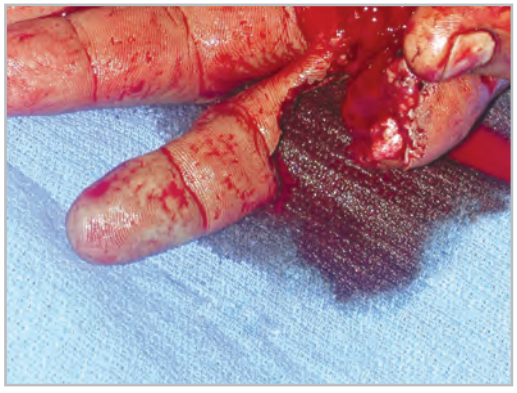

Figure 2.12 Volar and dorsal combined injury.

devascularization is usually present to a lesser or greater extent, with compromise of the distal vascularity. Extensive injuries result from industrial accidents or from blast injuries. The extent of volar and dorsal injury depends on the depth and width of the cutting implement and the amount of force spent in the injury. Gross contamination, loss of skin, and the indeterminate viability of different structures usually make primary repair of injured structures difficult and unreliable. Due to compromise of the venous and lymphatic systems, edema and fibrosis is common, making functional rehabilitation difficult. If the conditions allow, primary repair or reconstruction of at least one tendon system greatly facilitates the secondary reconstruction of other system at a later date after completion of wound healing and tissue homeostasis. In combined injuries, it is important to recognize the negative interactive restraints imposed by different combinations of lesions and consider that treatment strategies that work well for isolated injuries may fail when transferred to combined injuries.

ANATOMY AS A SOURCE OF COMPLEXITY

Hand function depends on an intricate anatomical arrangement with a necessary balance between stabilizing structures and gliding mechanisms that allows movement of the different parts of the hand. Certain areas of the hand are well known by surgeons as being the main cause of complexity, making functional restoration a major challenge. Some examples of anatomical tribulations include:

- Zone 2 tendon injury is the foremost example where essential anatomy makes restoration of tendon gliding difficult. Here, flexor digitorum superficialis and flexor digitorum profundus are in intimate relationship with each other and are enclosed in a fibro-osseous sheath. Achieving healing of the tendons without restrictive adhesions is much more demanding in zone 2 than in other areas of flexor tendon system
- The peculiar blood supply of the scaphoid increases the likelihood of avascular necrosis and non-union of fractures, especially in its proximal portion. The major blood supply to the scaphoid is via the radial artery. Seventy to eighty per cent of the interosseous vascularity and entire proximal pole is from branches of the radial artery entering the bone through small foramina located adjacent to the dorsal crest (Gelberman & Menon 1980). Because of the dependence on a singular dominant interosseous vessel, the proximal scaphoid pole is uniquely susceptible to avascular necrosis after a fracture
- The complex anatomy makes dislocation of the metacarpophalangeal joint of the fingers, especially in index finger, irreducible. Kaplan described a noose that formed around the joint (by the natatory ligament, superficial transverse metacarpal ligament, flexor tendons, and lumbricals) and contributed to the irreducibility of the dislocation, although volar plate and deep transverse intermetacarpal ligament seem to be a more likely cause of obstruction to reduction of the joint (Afifi et al. 2009).
- Multiple ligaments—extrinsic and intrinsic—connect the carpal bones to each other. Among the intrinsic ligaments, the scapholunate interosseous ligament and lunotriquetral interosseous ligaments are the most important and their injury causes intercalary dorsal or volar instability. Their anatomy is complex and restoration of their stabilizing function after the injury remains problematic

FACTORS RELATED TO INJURY ENVIRONMENT

Circumstances and the surrounding environment can significantly affect the nature of hand injury. The bacteriology of farm-related injuries differs from that of home- or industry-related injuries. Fitzgerald et al. (2007) reviewed the bacteriology of 86 patients with mutilating injuries, 48 prospectively, and 38 retrospectively. In farm-implement injuries 40% of the isolates were gram-positive and 60% were gram-negative. In injuries occurring at home or in industrial environment, roughly 70% of the isolates were gram-positive and 30% were gram-negative. This will dictate different antibiotic coverage in farm-related injuries. In addition, injuries from farm machinery are more likely to be grossly contaminated, to have more crushing and avulsion elements and vascular restoration at a digital level is therefore less likely to succeed. Infections associated with combat-related injuries in the recent operations in Iraq and Afghanistan have predominantly been secondary to multidrug-resistant pathogens including *Clostridium perfringens* (the cause of gangrene) from the soil, and aerobic gram-positive cocci of the skin, including *Streptococcus pyogenes* and *Staphylococcus aureus*. If the wound results in breaching of the gastrointestinal (GI) tract, the bacteria that constitute the GI flora can also contaminate (Hospenthal et al. 2011). Injury in a marine environment can be a key element in suspecting infection with *Mycobacterium marinum*, which can be a diagnostic challenge.

PSYCHOLOGICAL FACTORS

Both comorbid psychiatric conditions and psychosocial factors have been shown to affect treatment outcome in patients with traumatic hand injuries. Pre-existing psychological conditions may have a causative relationship with the injury as in some self-inflicted lacerations (**Figure 2.13**). Initial interaction with the patient, behavioral observation, circumstances of the injury, and the response to treatment may provide an insight into the patient's premorbid history, psychological stressors, and current emotional status (Koestler 2010). The patient's emotional status, coping responses, reaction to injury and pain, as well as the level of social support, self-sufficiency and outcome expectations can have a significant impact on the treatment course and the final functional outcome. Decreased participation in physical therapy, non-compliance, resistance to assuming self-care responsibilities, exaggerated pain behavior or guarding, and expression of blame, anger, helplessness, and hopelessness may make the treatment of an otherwise simple injury much more complex. Depending on the extent of these observations and their effect on the treatment, a more in-depth assessment by a psychiatrist may be indicated, especially if there is any indication of

JAYPEE BROTHERS



Figure 2.13 A self-inflicted injury with multiple (hesitation marks) lacerations.

suicidal tendencies, disabling depression, or abuse of prescription medications or other substances. The patient's perception of the circumstances surrounding an injury plays an important role in their ability to cope with the consequences of the injury. Negative emotional reaction may heighten if the patient perceives that the injury was result of someone's uncaring negligent behavior and was avoidable. Litigation issues, especially work-related compensations claims, may also complicate the rehabilitation of traumatic hand injuries (Meyer 2003). A delay in the payment of financial compensation is a frequent impediment to recovery, aggravated by the stalling tactics of some legal advisors. Early resolution of compensation issues may motivate the patient toward a quicker functional recovery. Even when these issues are not a factor, severe traumatic hand injuries can precipitate post-traumatic stress disorder (PTSD) or acute stress disorder (a disorder similar to PTSD but diagnosed in less than a month from the injury) with symptoms such as nightmares, flashbacks, affective lability, preoccupation with phantom limb sensations, concentration/attention problems, cosmetic concerns, fear of death, and denial of amputation (Grunert et al. 1988). Unless these conditions are managed effectively by mental health professionals, treatment of hand injuries may not achieve optimum results.

COMORBIDITIES

In addition to coexisting associated injuries, uncontrolled diabetes, peripheral vascular disease, smoking, certain skin conditions, and steroid intake can all have an adverse additive influence on hand injuries by affecting the healing process or increasing the risk of sepsis. Diabetes mellitus is known to be associated with an increased incidence of morbidity from local and systemic infections. A combination of chronic neuropathy, vascular disease, and poor wound healing may contribute to increased susceptibility to infection. In upper extremity infections in diabetic patients, an increased rate of amputation was associated with deep infections below the subcutaneous tissue, renal failure, and infections with gram-negative or polymicrobial cultures (Gonzalez et al. 1999). Patients with diabetes have impaired wound healing and the mechanisms involved at cellular level include an increase in acute inflammatory cells, absence of cellular growth, narrowing or occlusion of blood vessels within the wound edges, and impaired leukocytic function together with reduced chemotaxis of leukocytes (Blakytny & Jude 2006). These cellular changes predispose individuals to an increased risk of wound breakdown and infection.

Smokers have a higher incidence of infectious and non-infectious healing complications after surgery, thus adding to the adversity and vicissitudes of complex hand injury (Sørensen 2012). Smoking adds to the incidence of necrosis of wounds and tissue flaps, healing delay, and dehiscence of wounds. Fractures heal slowly in smokers compared with non-smokers. Tissue ischemia and wound healing impairment secondary to the influence of tobacco is particularly problematic in replantation procedures and free tissue transfers. Surgical outcomes can also be adversely affected by intraoperative and postoperative pulmonary, cardiovascular and cerebrovascular complications. There is some evidence that perioperative smoking cessation may reduce these complications.

Long-term exogenous steroid use leads to chronic suppression of the HPA axis, which consists of the hypothalamus, pituitary gland, and adrenal glands, via a negative feedback loop. This eventually results in adrenal cortical atrophy and manifests as an inability to secrete cortisol when stressed (Fleager & Yao 2010). Chronic steroid intake, in addition to a blunted stress response, is known to impair wound healing, increase fracture risk, and increase infection rate. A patient with hand injury who has a history of prolonged steroid use may need supplemental steroid dosing if a prolonged anesthesia and a stressful surgery is anticipated.

Patients who are infected with blood-borne viruses (BBV) pose special problems for the medical personnel responsible for the treatment. BBV are serious infections and include hepatitis B virus (HBV), hepatitis C virus (HCV), and human immunodeficiency virus (HIV). The risk of transmission to a health-care worker from an infected patient following percutaneous exposure secondary to needle stick injury has been shown to be around one in three when a source patient is infected with HBV and is 'e' antigen positive, around 1 in 30 when the patient is infected with HCV and around 1 in 300 when the patient is infected with HIV (Al-Ani et al. 2006). HIV-infected patients are more prone to the spontaneous onset of infection in the absence of penetrating injury. Infections in these patients are generally more serious and difficult to treat. When operating on these patients, the surgical team should employ adequate precautionary measures, including the use of double-gloving, fluid resistant masks, face shields, water proof gowns and boots, and take particular care with regard to the use of sharp instruments, suturing using a 'no touch' technique and instrument ties, and closure using staples or glue. In dealing with fractures, one should particularly be aware of sharp bone edges and splash exposure during irrigation. In case of exposure of the surgical team, the postexposure prophylaxis recommendations of the hospital or health authorities must be followed.

A patient with a known history of bleeding disorder, anticoagulation therapy or hepatitis should have their prothrombin time and activated partial thromboplastin time measured. Uncontrolled hemorrhage in the hand and forearm and an increased risk of compartment syndrome can be serious problems in hemophilic patients. The recommended factor VIII level for a major surgical procedure is 80–100% and for minor surgery is 50–60%.

CONCLUSIONS

There are many factors that affect the severity and complexity of a hand injury. When combined, they can have additive deleterious effect on the outcome in complex hand injury. A thorough understanding and analysis of these factors allows the surgeon to understand the injury in its entirety and helps them to plan the best therapeutic strategies.

JAYPEE BROTHERS

REFERENCES

Afifi AM, Medoro A, Salas C, et al. A cadaver model that investigates irreducible metacarpophalangeal joint dislocation. *J Hand Surg Am* 2009; **34**:1506–1511.

Al-Ani SA, Mohan D, Platt AJ. Hand surgery on patients who are 'high risk' for blood-borne viruses. *J Hand Surg Br* 2006; **31**:426–431.

Angoules AG, Lindner T, Vrentzos G, et al. Prevalence and current concepts of management of farmyard injuries. *Injury* 2007; **38**:S27–S34.

Bartlett CS. Clinical update: gunshot wound ballistics. *Clin Orthop Relat Res* 2003; :28–57.

Blakytny R, Jude E. The molecular biology of chronic wounds and delayed healing in diabetes. *Diabet Med* 2006; **23**:594–608.

Buchler U. Traumatic soft-tissue defects of the extremities. Implications and treatment guidelines. *Arch Orthop Trauma Surg* 1990; **109**:321–329.

Danielson JR, Capelli-Schellpfeffer M, Lee RC. Upper extremity electrical injury. *Hand Clin* 2000; **16**:225–234, viii.

Fitzgerald RH Jr., Cooney WP, 3rd, Washington JA 2nd, et al. Bacterial colonization of mutilating hand injuries and its treatment. *J Hand Surg Am* 1977, **2**: 85-89.

Fleager K, Yao J. Perioperative steroid dosing in patients receiving chronic oral steroids, undergoing outpatient hand surgery. *J Hand Surg Am* 2010; **35**:316–318; quiz 319.

Frank M, Schmucker U, Hinz P, et al. Not another 4th of July report: uncommon blast injuries to the hand. *Emerg Med J* 2008; **25**:93–97.

Gelberman RH, Menon J. The vascularity of the scaphoid bone. *J Hand Surg Am* 1980; **5**:508–513.

Giessler GA, Leopold A, Germann G, Heitmann C. [Blast injuries of the hands. Patterns of trauma and plastic surgical treatment]. *Unfallchirurg* 2006; **109**:956–963.

Gonzalez MH, Bochar S, Novotny J, et al. Upper extremity infections in patients with diabetes mellitus. *J Hand Surg Am* 1999; **24**:682–686.

Grunert BK, Smith CJ, Devine CA, et al. Early psychological aspects of severe hand injury. *J Hand Surg Br* 1988; **13**:177–180.

Hofmeister EP, Mazurek M, Ingari J. Injuries sustained to the upper extremity due to modern warfare and the evolution of care. *J Hand Surg Am* 2007; **32**:1141–1147.

Hogan CJ, Ruland RT. High-pressure injection injuries to the upper extremity: a review of the literature. *J Orthop Trauma* 2006; **20**:503–511.

Hospenthal DR, Green AD, Crouch HK, et al. Infection prevention and control in deployed military medical treatment facilities. *J Trauma* 2011; **71**:S290–S298.

Kamolz LP, Kitzinger HB, Karle B, Frey M. The treatment of hand burns. *Burns* 2009; **35**:327–337.

Koestler AJ. Psychological perspective on hand injury and pain. *J Hand Ther* 2010; **23**:199–210; quiz 211.

Meyer TM. Psychological aspects of mutilating hand injuries. *Hand Clin* 2003; **19**:41–49.

Rodrigues RL, Sammer DM, Chung KC. Treatment of complex below-the-elbow gunshot wounds. *Ann Plast Surg* 2006; **56**:122–127.

Sanguinetti MV. Reconstructive surgery of roller injuries of the hand. *J Hand Surg Am* 1977; **2**:134–140.

Sauerbier M, Ofer N, Germann G, Baumeister S. Microvascular reconstruction in burn and electrical burn injuries of the severely traumatized upper extremity. *Plast Reconstr Surg* 2007; **119**:605–615.

Schoo MJ, Scott FA, Boswick JA Jr. High-pressure injection injuries of the hand. *J Trauma* 1980; **20**:229–238.

Sørensen LT. Wound healing and infection in surgery: the clinical impact of smoking and smoking cessation: a systematic review and meta-analysis. *Arch Surg* 2012; **147**:373–383.

Trybus M, Lorkowski J, Brongel L, Hladki W. Causes and consequences of hand injuries. *Am J Surg* 2006; **192**:52–57.

Wilson RH. Gunshots to the hand and upper extremity. *Clin Orthop Relat Res* 2003; **(408)**:133–144.

JAYPEE BROTHERS

COMPLEX INJURIES OF THE HAND

The number of complex hand injuries is on the rise and these generally involve multiple tissue systems. *Complex Injuries of the Hand* defines the principles of their diagnosis and provides the anatomic and physiologic basis for optimal treatment leading to the restoration of maximal function. The book also discusses the staging and sequencing of repair and reconstruction based on the nature of the injury.

The book is divided into four sections: the first reviews the general principles and philosophy of treatment of complex injuries, including anesthesia and post-operative rehabilitation. The second part deals with complex injuries in each tissue system, the third with thermal and blast injuries, while the fourth covers the application of special techniques such as microsurgery and external fixation.

- Provides a definitive 'go to' reference for hand surgeons, orthopaedic surgeons and plastic surgeons
- Emphasis on the synthesis and integration of different treatment principles
- Lavishly illustrated with over 500 color photographs and diagrams showing repair and reconstruction techniques



JP medical publishers

www.jpmedpub.com

ISBN 978-1-907816-25-3

9 781907 816253

CheemaFINAL.indd 1