

MULTIMODAL RETINAL IMAGING

Amresh Chopdar
Tin Aung
Foreword by Yit Yang

Contents

Foreword v

Preface vii

Contributors xiii

Chapter 1
Fundus fluorescein angiography 1
Amresh Chopdar

Chapter 2
Indocyanine green angiography 11
Heinrich Heimann

Chapter 3
Optical coherence tomography for retinal diseases 23
Geeta Menon, Vishali Gupta

Chapter 4
Ocular echography 27
Hatem Riad Atta

Chapter 5
Autofluorescence imaging 51
Victor Chong

Chapter 6
Optic nerve head imaging 61
Carol Y Cheung, Yih-Chung Tham, Tin Aung

Chapter 7
The modern multimodal stand-alone ophthalmic imaging center: setup, skills, and operation 71
Ethan R Priel

Chapter 8
Retinal vascular disorders 75
Amresh Chopdar

Chapter 9
Macular degeneration 85
Raeba Mathew, Sobha Sivaprasad

Chapter 10
Macular dystrophies 101
Amresh Chopdar

Chapter 11
Choroidal disorders 109
Amresh Chopdar

Chapter 12
Diseases of the optic nerve head 119
Amresh Chopdar

Chapter 13
Intraocular neoplasms 127
Amresh Chopdar

Chapter 14
Diabetic retinopathy and maculopathy 137
Sushma Dhar-Munshi

Chapter 15
Imaging of the optic disc and retinal nerve fiber layer in glaucoma 151
John Mark S de Leon, Shamira Perera, Tin Aung

Index 171

Chapter 2 Indocyanine angiography

Heinrich Heimann

INTRODUCTION

Indocyanine green (ICG, $C_{43}H_{47}N_2NaO_6S_2$) is an artificial tricarbocyanine dye that is a component of color film. It was introduced into medicine in the 1950s when biocompatible dyes that could be injected into the bloodstream were first investigated. The primary medicodiagnostic applications of ICG were the quantification of cardiac output and liver function. The use of ICG for fundus angiography is based on unique optical and chemical properties that, compared with standard fluorescein angiography, allow a more detailed examination of the choroidal circulation and of retinal and choroidal lesions that are obscured by blood or fluid (Leys & Horsman 2009, Yannuzzi 2011).

The first fundus angiography using ICG in humans was performed by Flower and Hochheimer in the early 1970s. ICG was approved for the use in angiography by the US Food and Drug Administration (FDA) in 1975. The first clinical applications of infrared absorption choroidal angiography in humans were then reported in 1976 (Flower & Hochheimer 1976, Chopdar et al. 1978). The production of the first commercially available camera system in 1980 and the introduction of video angiography in the 1990s were further developments to improve this examination technique. However, it was not until the 2000s that ICG angiography found a more widespread use. The advents of digital photography and scanning laser ophthalmoscopes (SLOs) significantly improved the image capture, resolution, and contrast compared with earlier video angiography or film-based techniques. In addition, review and interpretation of the images are now greatly facilitated by the use of computer-based rather than conventional film-based or video imaging systems. ICG angiograms can be reviewed immediately following the procedure on networked, high-definition monitors with the option of further magnification or contrast enhancement of selected images. With multimodal imaging, previous examination results and images acquired by other methods is now standard and more productive than the time-consuming review of printed images or video sequences on different reviewing stations, as was done just 10 years ago.

Over the past decade, several clinical applications have emerged in which ICG angiography not only provides useful additional information regarding the pathophysiology of chorioretinal diseases but also has a direct impact on treatment pathways and outcomes. ICG angiography is considered by leading medical retina specialists to be an essential examination technique in defined clinical situations (Yannuzzi 2011). However, its use varies significantly between centers. On the one hand, some retinal specialists perform an ICG angiography on a routine basis in a large proportion of patients, and on the other hand a significant number of specialists rarely or never perform an ICG angiography. The critics of the more widespread use of ICG angiography argue that at present there is not enough evidence-based clinical research to justify the significant additional costs of this relatively time consuming and invasive diagnostic test. They are of the opinion that, compared to the recent developments and popularization of several noninvasive imaging techniques [spectral domain optical coherence tomography (OCT), enhanced depth imaging OCT, autofluorescence], the use of ICG angiography will decrease or even become obsolete in the near future. Proponents of ICG angiography proclaim that the unique abilities of ICG angiography to detect changes in the choroidal circulation cannot be met by any other current or emerging imaging technique. With the expanding knowledge about ICG angiography and the escalating number of treatment options, they foresee a future for ICG angiography as an established part of a state-of-the-art multimodal imaging service.

A synopsis of the most commonly used indications of ICG angiography and typical findings is listed in **Table 2.1**.

ANATOMICAL AND PHYSIOLOGIC PRINCIPLES

Fluorescence describes the ability of substances to emit light following excitation by light of a different wavelength. Fluorescence angiography of the eye is currently performed with two different dyes: fluorescein and ICG. Following intravenous injection, they fill the blood vessels of the eye via the ophthalmic artery. The dye molecules are excited with light sources of a defined wavelength. Their capability to fluoresce is then used as a light source that can be traced and located by photographic documentation. The resulting image detects the dye molecules within the vascular structures, thus providing an outline of the blood vessels of the eye and potential pathological structures with a much higher contrast compared to standard photographic techniques. In addition, changes of the dye's location can be monitored over time. This provides additional information about pathological changes when compared to normal eyes. The ophthalmologist reviewing the angiogram compares potential changes in the location of dye and the amount of detectable dye (hyper- or hypofluorescence) to normal angiograms. Together with the findings of the clinical examination, other imaging techniques, and previous angiograms, the angiography is then interpreted as part of the diagnostic process.

The chemical and optical properties of ICG differ significantly from those of fluorescein (Leys & Horsman 2009). ICG is excited by light in the near-infrared range of 790–805 nm wavelength, resulting in an emission of light between 770 and 880 nm. Modern SLO-based angiography systems use an infrared diode laser with a wavelength of 795 nm for excitation and barrier filters at 810 nm. Compared with fluorescein, the optical characteristics of ICG allow a better transmission of emitted light through the retinal pigment epithelium, fluid, and blood. In addition, ICG has a significantly higher molecular weight (775 kD vs. 375 kD of fluorescein), and almost all ICG molecules are rapidly bound to plasma proteins following injection. As a consequence, ICG extravasates more slowly and in significantly lower proportions through the choroidal vasculature or leaking blood vessels. With ICG, the choroidal vasculature and perfusion status are imaged in greater detail than with fluorescein angiography. Clinical examples, with significant alterations of the choroidal circulation, include diseases with significant alterations of the choroidal perfusion (e.g. polypoidal choroidal vasculopathy, choroiditis, choroidal tumors, or central serous retinopathy). Further, choroidal or retinal neovascularizations are easier to identify because they are not obscured by the leaking fluoresceine that acts like a smokescreen in the early phases of the

JAYPEE BROTHERS

Table 2.1 Current indications for ICG angiography

Condition	Typical ICG findings	Advantage over FFA
Polypoidal choroidal vasculopathy (**Figures 2.20–2.22**)	Polypoidal dilatation of choroidal vessels Pulsating polyps on movie Branching vascular networks with points of focal dilatation	ICG necessary to diagnose polypoidal lesions
RAP (**Figures 2.23–2.25**)	Identification of retino-retinal or retinochoroidal anastomosis Significant leakage of ICG over RAP Movie demonstrates blood flow in RAP lesion Late hyperfluorescent spot over RAP lesion	Facilitates identification of RAP lesion
Occult AMD (**Figures 2.18–2.19**)	Identification of CNV Feeder vessel	May identify CNV not visible on FFA
Retinal pigment epithelial detachment	Identification of choroidal neovascularization	May identify CNV not visible on FFA
Non-AMD choroidal neovascularization	Identification of CNV	May identify CNV in ambiguous cases Definition of the extent of the CNV in areas covered by blood or exudates
Central serous retinopathy (**Figures 2.26–2.28**)	Focal leakage Staining of areas of previous hyperpermeability	Identifies areas of choroidal hyperpermeability not seen clinically or silent on FFA
Posterior uveitis (**Figures 2.13–2.17**)	Focal hypo- or hyperpermeability	Identifies disturbances of the choroidal circulation not visible clinically or on FFA
Choroidal hemangioma (**Figures 2.29–2.30**)	Early significant leakage Dye washout during the late phases	Higher sensitivity in identifying choroidal hemangioma

AMD, age-related macular degeneration; ICG, indocyanine green; FFA, fluorescein angiography; RAP, retinal angiomatous proliferation; CNV, choroidal neovascularization.

angiography. This is used for the identification of retinal angiomatous proliferations or choroidal neovascularizations in pigment epithelial detachments. And finally, vascular changes obscured by blood, lipids, or exudations in fluorescein angiograms can be identified with ICG angiography. This is of clinical importance in the identification of choroidal necovasularizations, polypoidal choroidal changes, or retinal macroaneurysms underlying a retinal hemorrhage that cannot be visualized with fluorescein angiography.

Following injection, ICG is not metabolized. It is exclusively excreted through the liver with a biphasic elimination curve. The initial half-life is 3–4 minutes, followed by a dose-related half-life of 60–80 minutes.

Although ICG provides an excellent outline of the retinal vasculature, it is mainly used for the detection of changes of choroidal blood flow. The choroid is situated between the retina and the sclera, thus forming the middle layer of the posterior segment. Anteriorly, it merges into the ciliary body and the iris. The thickness of the choroid varies between 0.25 mm in the macula and 0.1–0.15 mm at the equator (Richard 1992). It consists of several layers. Immediately attached to the basement membrane of the retinal pigment epithelium is Bruch's membrane. Bruch's membrane is only 2 µm thick and is composed of collagen and elastic fibers. Its composition and permeability seem to be important factors involved in the development of exudative and nonexudative age-related macular degeneration. Bruch´s membrane is bordered by the basement membrane of the choriocapillaris, which forms the next layer of the choroid. It consists of fenestrated capillaries that are organized in a unique segmental, lobular pattern. The size of the lobes varies with location and between patients. As a clinical guideline, the lobes average approximately 1/4 disc diameter in size. The lobes are fed by a central arteriole that then branches out into a meshwork of capillaries that run radially into the periphery of the lobe. The capillary diameter varies and is 9–20 µm at the posterior pole and 10–50 µm at the equator. Capillary size and number decrease with age. The endothelial cells of the capillaries are fenestrated with pores of 55–60 nm. The choriocapillaris blends into Sattler's layer (arterioles and venules of medium to small size) and then Haller's layer (larger arteries and veins). The arteries have a diameter of 40–90 µm, and the veins are around 20–100 µm in size. The vasculature is embedded in loose connective tissue that also incorporates melanocytes, lymphocytes, and nerve fibers. The outermost layer of the choroid is the lamina suprachoroidea that borders the sclera.

The blood supply of the choroid derives from the ophthalmic artery. Two to three branches of posterior ciliary arteries separate from the ophthalmic artery in the orbit (Richard 1992). They run near the optic nerve head and are divided, according to their anatomical location in relation to the optic nerve, into medial and lateral posterior ciliary arteries. In the majority of patients, the medial posterior ciliary artery arises together with the central retina artery as the first branch of the ophthalmic artery. The lateral posterior ciliary artery usually resembles the second branch. The lateral and the medial branches supply arterial vascular networks that are not connected. Thus, there is a 'watershed' of choroidal blood supply between the lateral and medial aspects of the choroid (Mori et al. 2008). The macula lies on the watershed between the lateral and medial blood supply. Before entering the globe, the medial and the lateral posterior ciliary arteries each divide into one long posterior ciliary artery and 10–20 short posterior ciliary arteries. The lateral short posterior ciliary arteries pierce through the sclera at the location of the macula and then run anteriorly in a radial fashion to supply the various segments of the choroid. The long posterior ciliary arteries run anteriorly to split at the level of the ora serrata and supply the major arterial circle of the iris.

The choroidal blood is drained via vortex veins. Venules arise at the edge of the lobes of the choriocapillaris, then unite into larger veins and finally form large vortex veins. In the majority of patients, four vortex veins (one in each quadrant) are present. They pierce the sclera posterior to the equator. In contrast to the arterial system, there

JAYPEE BROTHERS

are abundant anastomosis between different quadrants in the venous drainage system.

The choroid is also involved in supplying the blood supply to the optic nerve head. The prelaminar zone is supplied by branches of the peripapillary choroidal arteries. The lamina cribrosa is fed by short posterior ciliary arteries that form the vascular network of the circle of Zinn–Haller. Recurrent branches from the peripapillary choroid support the retrolaminar section of the optic nerve head. In contrast, the superficial nerve fiber layer on the optic nerve head is supplied by the branches of the central retinal artery.

TECHNIQUE

ICG angiography is an invasive and time-consuming diagnostic procedure that requires expensive equipment, specialized medical photographers, skilled ophthalmologists for interpretation of the angiogram, and the availability of emergency medical support in case of severe adverse reactions. Its use is, therefore, limited to tertiary centers specialized in the diagnosis and treatment of chorioretinal diseases. It should only be performed in selected cases to answer a particular clinical question based on the assessment of an ophthalmologist with significant experience in retinal disease.

There are no age restrictions, but patients must be fit and able to undergo the diagnostic procedure. This requires cannulation, pupillary dilatation, correct head positioning, and appropriate gaze at a slit lamp for several minutes. With the use of modern SLO imaging devices, there is relatively little light exposure. The examination causes only minor discomfort to the patient. However, patients may be apprehensive about the intravenous injection. A detailed explanation of the procedure, the nature, and low incidence of side effects and the required cooperation regarding head and eye positions are important prerequisites for obtaining high-quality angiograms. In most institutions, written consent is required. A comfortable positioning of the patient and the photographer should be assured before start of the angiography. Adequate pupillary dilatation and clear optical media are prerequisites for sufficiently good images, and reliable intravenous access is mandatory. If possible, the test should be performed before measurement of the intraocular pressure because this may negatively influence the clarity of the cornea and tear film. ICG angiography can be performed before or after fluorescein angiography. With multimodal imaging, the minutes between documentation of the various phases of the angiography are often used to capture additional images (e.g. OCT or color images). It must be kept in mind that autofluorescence images must be taken before fluorescein or ICG angiographies are performed (fundus autofluorescence before fluorescein angiography and near-infrared angiography before ICG angiography, respectively).

A point of ongoing discussion is whether ICG angiography is contraindicated in patients with known allergies to iodine-containing products (e.g. contrast media or disinfection products). Iodine is not part of the ICG molecule itself (Leys & Horsman 2009). However, the pharmacological product contains up to 5% sodium iodide required for the preparation of the product. These sodium iodide molecules are too small to cause an antibody response could trigger an allergic reaction. While most textbooks and manufacturer recommendations state that one should not perform an ICG angiography in patients who have a history of allergic reactions to iodine-containing products, this seems to be unjustified. Another myth is that patients with a known allergy to shellfish or seafood have a higher rate of allergic reaction to iodine-containing products than individuals with other known allergies.

In patients with hyperthyroidism, ICG angiographies should be performed with caution. The iodide uptake into the thyroid gland can be blocked by the application of sodium perchlorate 30 minutes before injection of the ICG. Radioactive iodine uptake studies should not be performed within 1 week after administration, as test results may be altered. Although ICG has been used in pregnant women without detectable side effects, ICG is classified as a 'pregnancy category C' drug with insufficient data to appraise the safety of ICG during pregnancy.

ICG is supplied as a sterile, lyophilized green powder in a vial. It is dissolved in sterile water and must be used within 5–8 hours. The manufacturer's guidelines recommend 0.1–0.3 mg ICG per kg body weight for diagnostic purposes (PULSION Medical Systems AG, Munich, Germany). However, it is common practice to use 25 mg ICG dissolved in 5 mL sterile water as a standard dose irrespective of body weight. In patients with increased pigmentation of the ocular fundus or for wide-angle angiographies, the dose can be increased to 50 or 75 mg. The drug is injected rapidly by the ophthalmologist or specialist nurse via a peripheral intravenous access, followed by a 5 mL saline flush.

Extravasated ICG is not associated with significant inflammatory reaction. Overall, ICG for angiography is associated with a low rate of minor side effects (< 1%) and is significantly better tolerated than fluorescein for angiography (Hope-Ross et al. 1994). Anaphylactic reactions are extremely rare, but fatal outcomes have been reported. The procedure must therefore be performed with appropriate safety measures under medical supervision.

PHOTOGRAPHY

ICG is less fluorescent than fluorescein. The resulting image is darker with less contrast than fluorescein angiographies. In addition, the time interval between choroidal arterial filling and arteriovenous transition via the choriocapillaris is much shorter than the retinal arteriovenous transition time and is almost impossible to capture with conventional angiography systems. Early applications of ICG angiography were flawed by dark, low-contrast angiograms that could not match the quality of fluorescein angiography and often missed useful images of the early phases of the angiography. This has changed dramatically since the introduction of SLO. Compared to the previously used film-based or video angiographies, amplification and modifications of the detectable fluorescence result in increasing brightness and contrast. In addition, high-speed photography (16 frames per second) allows the creation of digital angiography movie sequences. These can be used to analyze dye movement over time as well as review of every single image of the movie for a detailed analysis. Together with a higher image resolution and the reduction in reflections during image acquisition, the quality of ICG angiography has improved dramatically over the past decade.

ICG angiograms are nowadays almost exclusively captured on computer systems and stored in databases that enable review on multiple computer workstations within IT networks. With current multimodal imaging, considerable amounts of data are generated per patient session. When purchasing new imaging equipment, one has to realize that the IT network and backup structure are as important as the imaging system itself, to enable smooth and reliable review of high-quality images now and in the future.

The sequence and variables of image acquisition for ICG angiography depend on the underlying condition, the clinical question, the technical facilities, and the preferences of the reviewer. There is no standardized protocol. In order to obtain appropriate angiogram, the area of interest, the suspected diagnosis, and individual preferences regarding image acquisition should be communicated

JAYPEE BROTHERS

between the ophthalmologist and the medical photographer. Ideally, this is accompanied by a fundus drawing. Baseline demographic and clinical data are entered into the database to allow appropriate identification of the imaging session and comparison with previous and future examinations. The image is focused using the infrared setting of the imaging device (**Figure 2.1**). If needed, fundus autofluorescence and near-infrared autofluorescence images should be obtained before the angiography (**Figure 2.2**). Following dye injection, the timer is started and the initial arteriovenous dye transit is documented with high-speed photography during the first 10–30 seconds (**Figures 2.3–2.7**). Additional images are taken during the first minute (**Figure 2.8**). Most institutions routinely generate a movie sequence of the early transition phase. The venous and recirculation phases are documented with additional images at 5 and 10 minutes (**Figures 2.9–2.10**). Some specialists also perform late images, taken at 20 and 30 minutes, on a routine basis (**Figures 2.11–2.12**). In contrast to fluorescein angiography, the brightness of fluorescence shows greater variations during ICG angiography. The photographer commonly adjusts the camera settings during the angiography to obtain optimal results. This can cause variations in the intensity of the recorded fluorescence phenomena and has to be acknowledged when interpreting the results.

The size of the documented fundus area is determined by the choice of lens and varies with the clinical question. Most commonly, the three standard magnifications that are used for conventional fundus photography and fluorescein angiography are available. Setups vary with the cameras used, but usually consist of a 18–20° image (high magnification, detailed examination of the macula or optic nerve head), 30–35° (the posterior pole in between the vascular arcades) and 50–55° settings (the posterior pole with the macula, optic nerve head, and major vascular arcades). As a general rule, ICG

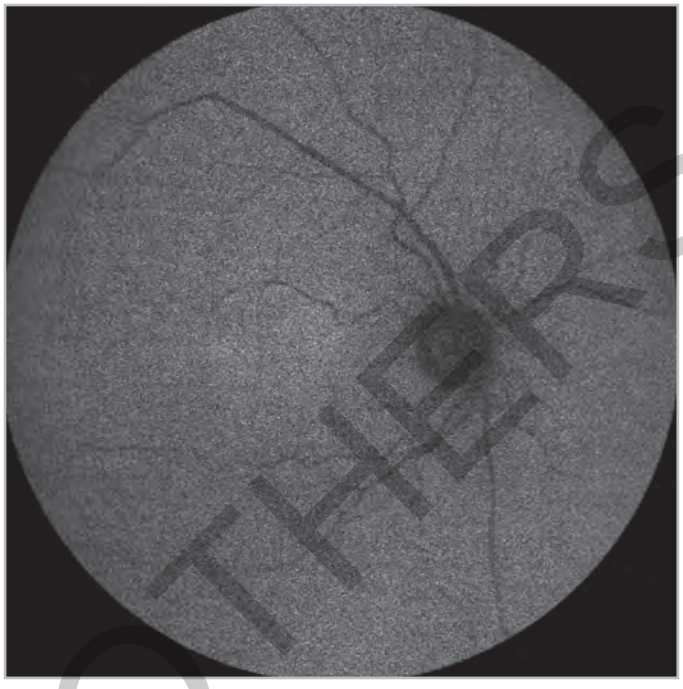

Figure 2.2 Normal near-infrared autofluorescence. In contrast to the autofluorescence images that are taken with the filters used for fluorescein angiography, the near-infrared autofluorescence is performed using the filter setting for indocyanine green (ICG) angiography. The main pigment depicted is melanin. The highest concentration is seen in the fovea, with decreasing intensity toward the periphery. The optic disc and retinal vessels show no autofluorescence. Near-infrared autofluorescence is performed before ICG angiography to identify areas of autofluorescence and pseudo-autofluorescence.

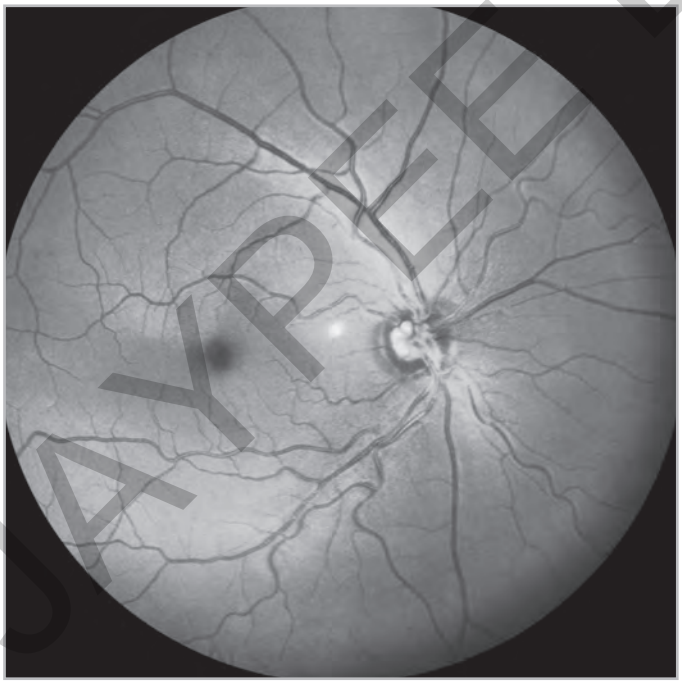

Figure 2.1 Near-infrared photography. This is a normal posterior pole image taken with the near-infrared photography setting of the scanning laser ophthalmoscope. This setting is used to focus the image and document a red-free fundus image for comparison with the images of the indocyanine green angiography.

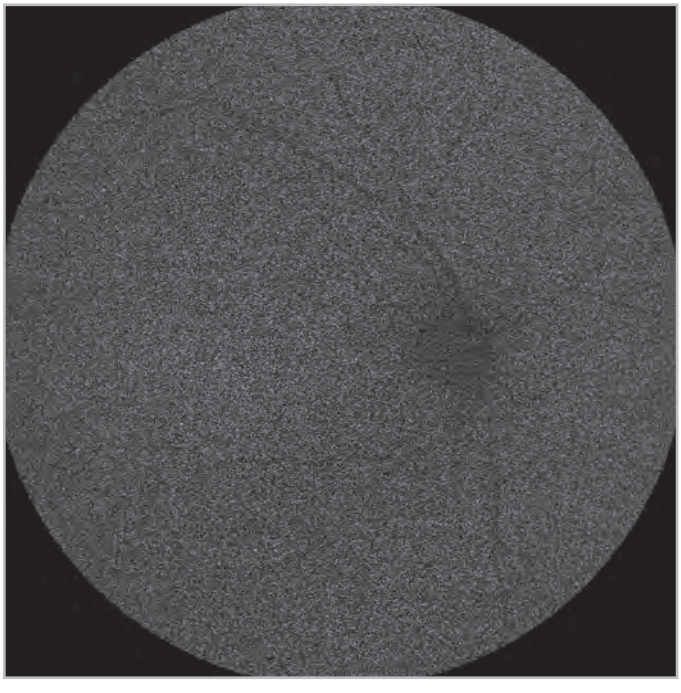

Figure 2.3 Normal indocyanine green (ICG) angiography (13 seconds; arterial phase). On a single image, the filling of the posterior ciliary arteries can only be guessed as a fuzzy fluorescence at the posterior pole around the macula. It is better appreciated on a movie sequence. The retinal arteries have not filled with ICG.

TAYLOR & FRANCIS GROUP

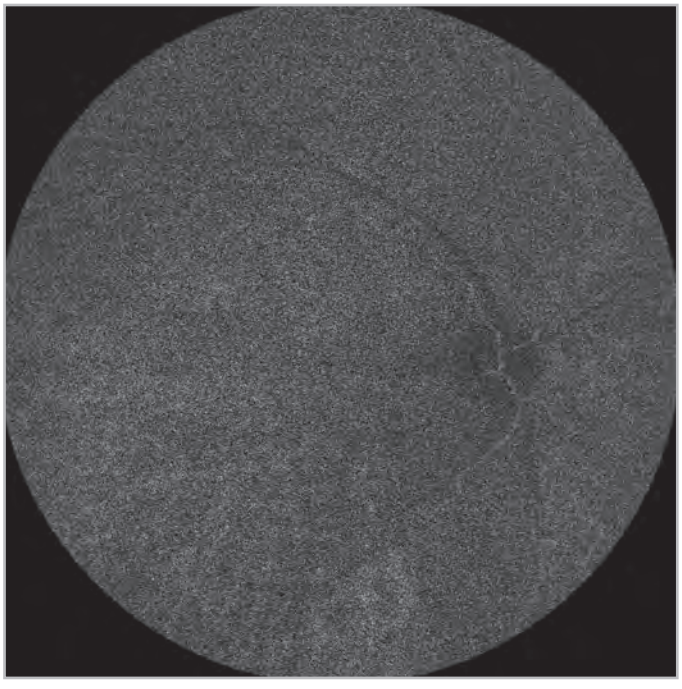

Figure 2.4 Normal indocyanine green angiography (20 seconds; early arteriovenous phase). The fluorescence is spreading radially in a lacelike pattern, filling the choroidal arterioles. The dye appears in the retinal arteries.

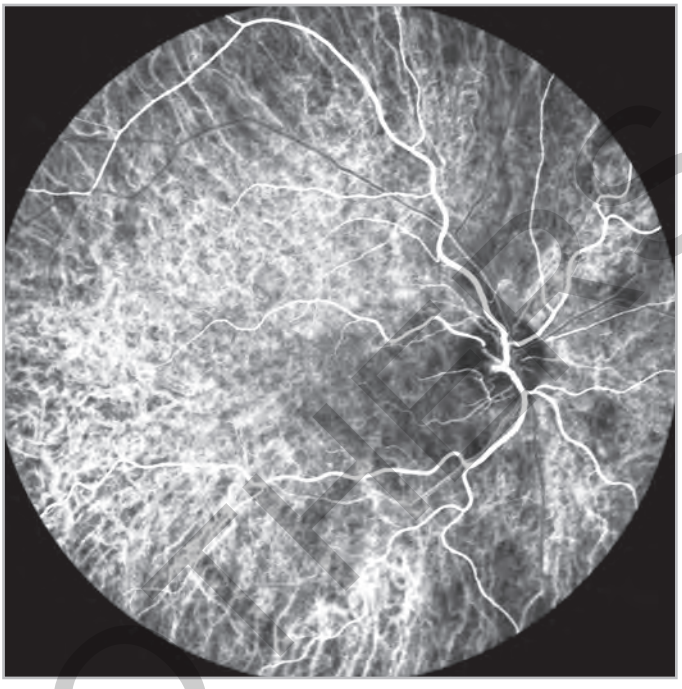

Figure 2.6 Normal indocyanine green (ICG) angiography (25 seconds; late arteriovenous phase). The choroidal venules are filling. There can be a blooming effect—the strong hyperfluorescence may obscure fundus details. A laminar flow of ICG can be detected in the retinal veins.

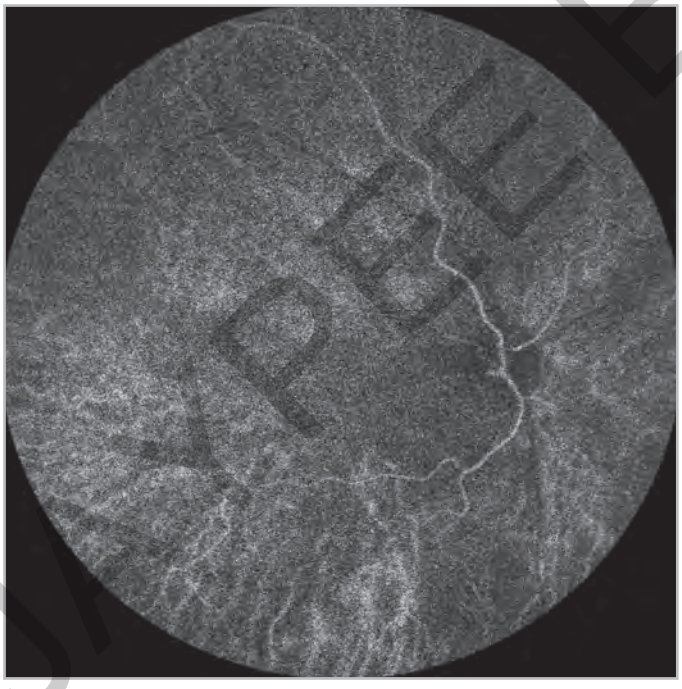

Figure 2.5 Normal indocyanine green angiography (21 seconds; arteriovenous phase). The dye has filled the choroidal arterioles and is entering the choroidal venules. Filling of the choriocapillaris is difficult to document on single frames but can seen on movie captures of the early phase.



Figure 2.7 Normal indocyanine green (ICG) angiography (40 seconds; venous phase). The large choroidal venules are now filled with dye, draining toward the vortex veins. There is isofluorescence of ICG in retinal arteries and veins.

SPRINGER BROCHURE

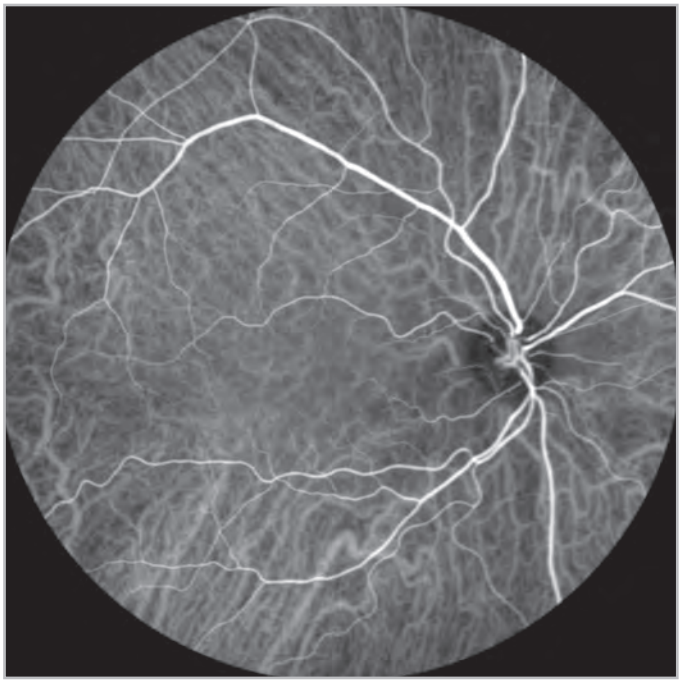

Figure 2.8 Normal indocyanine green angiography (1 minute; venous phase). There is a slight decrease in the fluorescence of the choroidal veins and less fluorescence in retinal arteries compared to retinal veins.

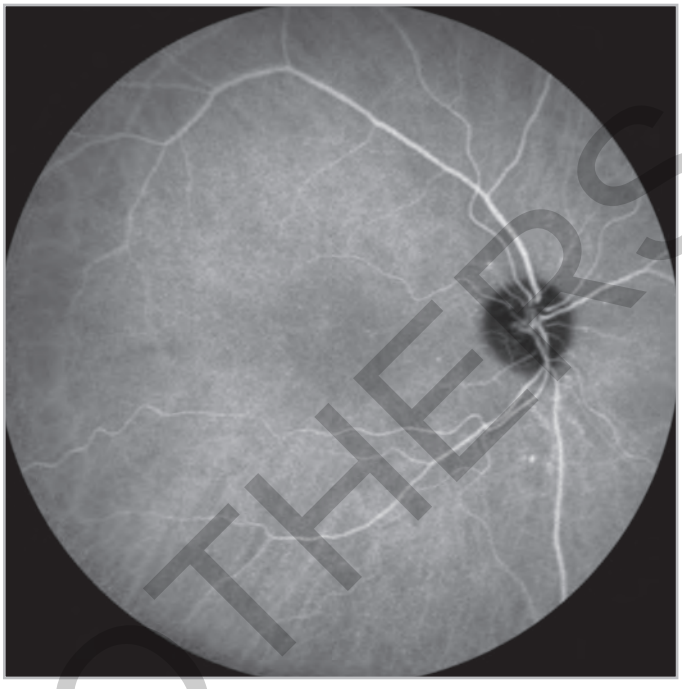

Figure 2.10 Normal indocyanine green (ICG) angiography (10 minutes). There is increasing background fluorescence, caused by extravasated ICG within the choroid. Intravascular ICG is still visible in the choroidal and retinal vasculature.

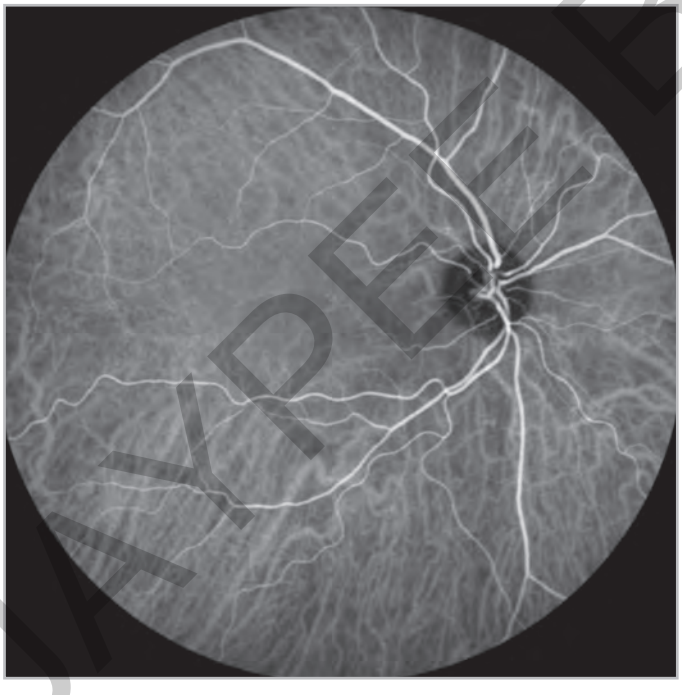

Figure 2.9 Normal indocyanine green angiography (5 minutes; venous phase). The choroidal veins, retinal arteries, and veins are still filled with dye. There is an overall decrease in the amount of fluorescence.

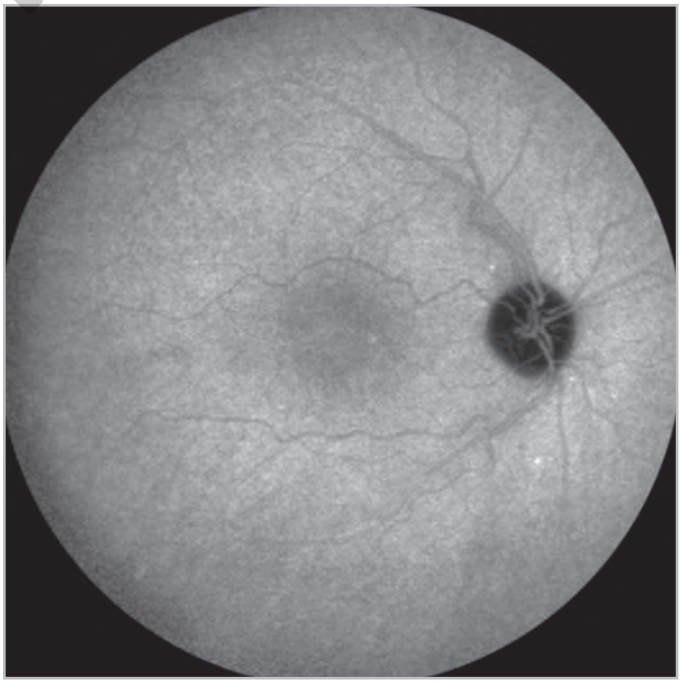

Figure 2.11 Normal indocyanine green (ICG) angiography (20 minutes). There is a decrease in background fluorescence. The choroidal vessels are outlined as shadows against the background fluorescence. A decrease in fluorescence of the retinal vessels is seen.

WILEY BROTHERS

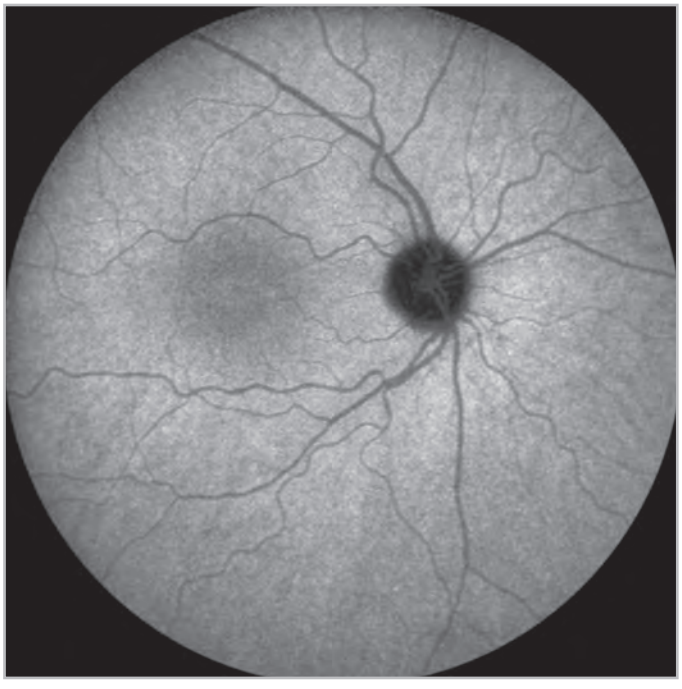

Figure 2.12 Normal indocyanine green angiography (30 minutes). There is a decrease in background fluorescence. The shadows of the choroidal vessels are still visible.



Figure 2.13 Indocyanine green angiography (early arterial phase). Radial filling of choroidal arteries is seen, beginning from the posterior pole and demarcating the watershed distribution between the medial and lateral choroidal vessels.

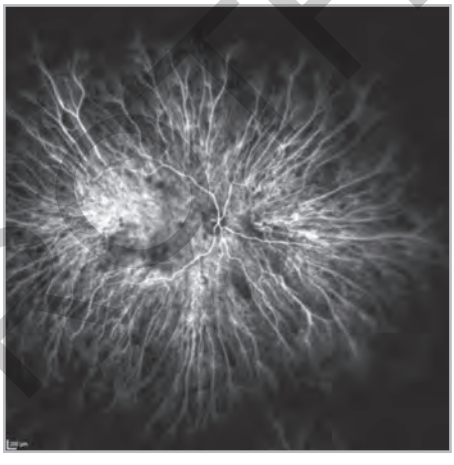

Figure 2.14 Indocyanine green angiography (arteriovenous phase). There is filling of choroidal arteries and veins. Areas of hypofluorescent spots are seen as an early indication of choroidal lesions.

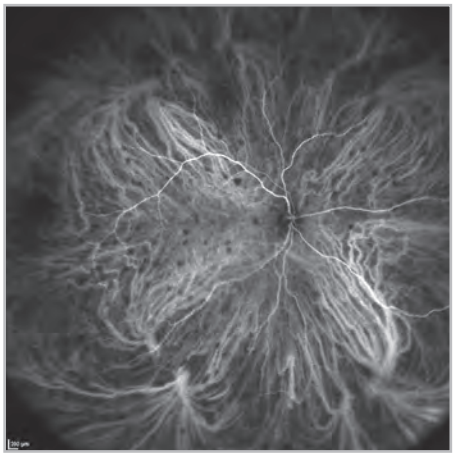

Figure 2.15 Indocyanine green angiography (venous phase). The choroidal veins are filled. The drainage to vortex veins in the mid-periphery of the fundus quadrants is clearly visible. Multiple hypofluorescent spots over the entire posterior pole are indicators of the choroidal pathology.

angiography is used more commonly to examine larger areas of the fundus than with fluorescein angiography. For example, polypoidal changes or choroidal filling defects are often located eccentrically or nasal to the optic disc. Our standard setting for ICG angiography is 55° compared with the most commonly used 30° for fluorescein angiography (**Figures 2.2–2.12**). Pseudo-stereo images are taken by varying the angle of the fundus camera in sequential images. Most imaging devices have a software and hardware option to generate, archive and review stereo images. The stereo effect is usually better with higher magnifications (30–35° images). An interesting option is to create a pseudo-stereo movie. By moving the angle of the camera during a movie capture of the venous phase of the ICG angiography, a pseudo-stereo effect is generated that can be appreciated during the review of the movie sequence.

An exciting new possibility is wide-angle ICG angiography. There are currently three ways to obtain such images. An increasing number of SLO-based imaging systems provide a montage software option that will stitch several images together to generate a wide-angle image. A 'true' wide-angle ICG angiogram over 150° can be performed using a contact lens (**Figures 2.13–2.17**). Finally, new lens optics are now available to provide ultra-wide ICG angiography with noncontact systems (**Figure 2.19**).

RECOGNIZING NORMAL RESULTS

ICG angiography is most commonly interpreted by dividing it into various phases (**Figures 2.2–2.12**). Following the conventional approach to interpretation of fluorescein angiographies, ICG angiography is separated into an early phase ('arterial phase,' from the first appearance of the dye in the ophthalmic circulation to arteriovenous transit, usually within 20 seconds), a mid phase ('venous phase,' between 20 seconds and 3 minutes), and a late phase ('recirculation phase,' 5–30 minutes). With the improvements in high-speed image capturing, the early phase can be subdivided into an arterial phase and an arteriovenous transit phase (Mori et al. 2008). This happens within few seconds following the initial appearance of the dye. Assessment of the early arteriovenous transit phase requires high-speed photography capabilities of modern imaging systems. Dynamic movies can be created and replayed at slower tempi. This enables the reviewer to assess the

JAYPEE BROTHERS

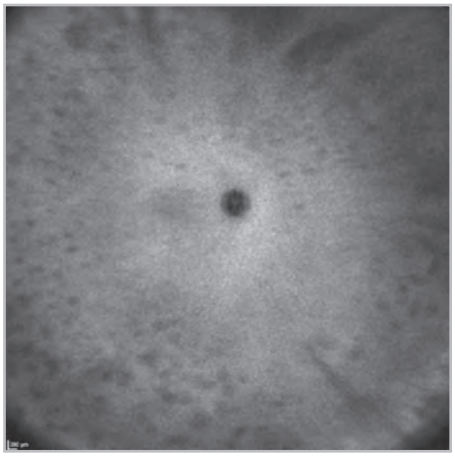

Figure 2.16
Indocyanine green (ICG) angiography (late phase). Numerous hypofluorescent spots are visible against the background fluorescence. There are significantly more spots identifiable than in the previous arteriovenous and venous phase. The ICG angiogram identifies the widespread choroidal pathology associated with the disease.

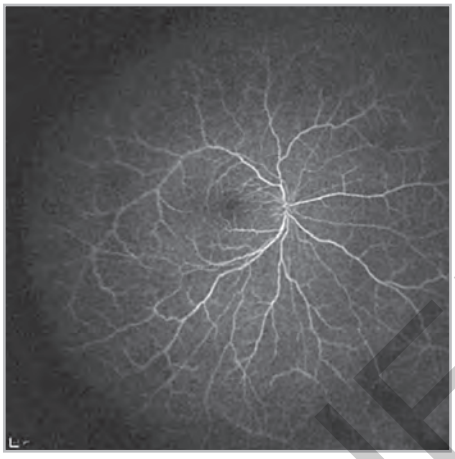

Figure 2.17
Fluorescein angiography (arteriovenous phase). In contrast to indocyanine green angiography, the choroidal lesions do not show up in fluorescein angiography. (Figures 2.13–2.17 patient with birdshot chorioretinopathy).

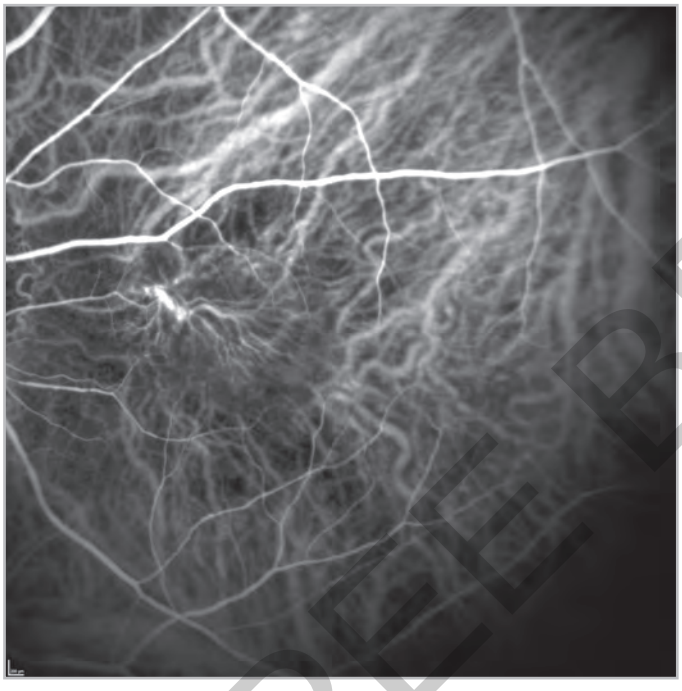

Figure 2.18 Indocyanine green (ICG) angiography (venous phase). This high-magnification view demonstrates the clear outline of the choroidal neovascularization and the feeder vessel at the posterior pole in a patient with age-related macular degeneration and occult choroidal neovascularisation.

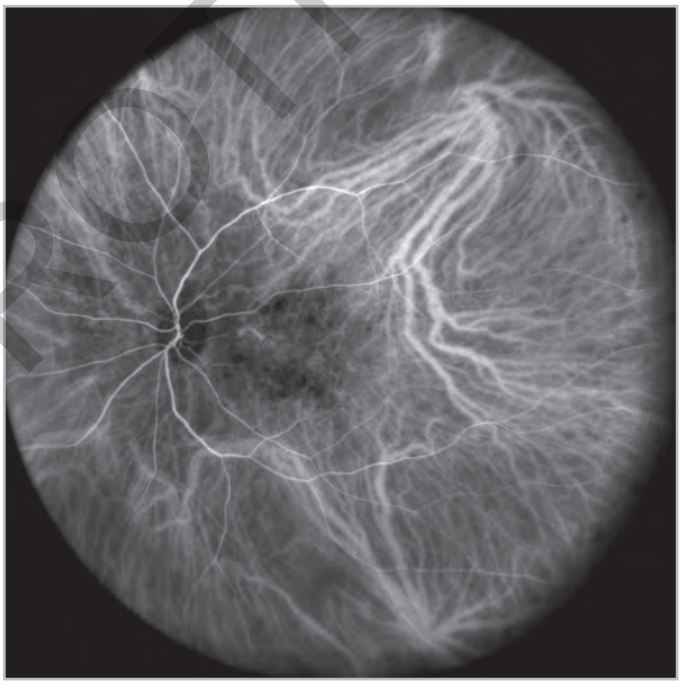

Figure 2.19 Indocyanine green (ICG) angiography (venous phase) using a new ultra-wide angiography with a noncontact lens. The neovascularization at the posterior pole as well as the vortex veins are visible (same patient as Figure 2.18).

early phase in greater detail, down to a frame-by-frame analysis. One of the difficulties of ICG angiography interpretation is that the three different vascular layers of the choroid (choriocapillaris, Sattler's and Haller´s layer) are superimposed on a two-dimensional image. Even with stereo angiography, the layers cannot be reliably separated in the majority of patients.

Before interpretation of the angiogram, preinjection images should be reviewed for signs of autofluorescence and pseudofluorescence. These can be caused by old hemorrhages, lipofuscin-like deposits, pigmented membranes, and long-lasting serous detachments (Piccolino et al. 1996). Artifacts can be caused by the blooming effect (increased fluorescence that obscures parts of the image during the initial filling of the choroidal vasculature). Increased fluorescence in the area of the crossing of blood vessels may be mistaken for hyperfluorescence and leakage.

After 12–15 seconds, ICG dye enters the choroidal circulation via the short posterior ciliary arteries. It can first be detected in the perimacular area, where it fills the posterior arterioles in a radial fashion toward the periphery. Corresponding to the variation in the diversion of the posterior ciliary arteries, watershed zones may be recognizable at this stage (Mori et al. 2008) (**Figure 2.13**). Filling of the choriocapillaris is difficult to detect. It most commonly appears as a 'haze' covering the previously filled arterioles. Shortly after the dye appears in the posterior ciliary arteries, ICG can be detected in the retinal circulation. The radial extension of retinal filling, arteriovenous transition, and laminar filling of retinal venules and veins

JAYPEE BROTHERS

corresponds to fluorescein angiography. After 15–20 seconds, the draining choroidal venules begin to fill with ICG. They appear larger than the arterioles. Typically, the venules and veins drain into four to six vortex veins. The intravascular amount of ICG fluorescence then decreases steadily during the mid phase due to extravasation, dilution, and clearance of the dye, resulting in lower contrast images between 5 and 10 minutes. During the late phase, the silhouettes of the hypofluorescent choroidal vessels can be observed against the hyperfluorescent extravascular space. At 20–30 minutes, an isofluroescent state (homogenous fluorescence) is reached. The optic disc remains hypofluorescent throughout the angiography.

INTERPRETING ABNORMAL SIGNS

The interpretation of ICG angiography is challenging even for experts in the field. Knowledge about pathological findings in various conditions is, compared with fluorescein angiography, still relatively limited, and there are much greater variations in the interpretation of results. However, due to improving imaging technology and more widespread use, knowledge of and clinical meaning of the test results are rapidly expanding.

When interpreting results of ICG angiography, it is advisable to interpret them in the context of the ophthalmologic history, the clinical picture, the OCT scan, and the fluorescein angiography to obtain as much information as possible about potential pathological changes. The interpretation of ICG angiograms begins with the identification of areas with an abnormally high (hyperfluorescence) or low (hypofluorescence) concentration of dye (**Figures 2.13–2.16**). In a second step, the anatomical location of these findings has to be identified. Finally, changes over the phases of the angiogram have to be assessed. Hyper- and hypofluorescence may increase or decrease in intensity or may change from hyper- to hypofluorescence and vice versa. An additional important step in ICG interpretation is review of early movie sequences to assess the dynamics of the occurring changes. Overall, the most important phase for interpretation of the angiogram is the mid or venous phase between 30 seconds and 3 minutes.

Compared with fluorescein angiography, hypofluorescent phenomena are less commonly observed and less pronounced. They are caused by blocked fluorescence (pigment, blood, exudations) or vascular filling defects. Because there is less blockage by blood or exudations in ICG angiography, hyperfluorescent spots underlying the blockage from neovascularizations or other pathology can often be visualized (**Figure 2.20–2.22**). Another unique feature of ICG angiography is the identification of hypofluorescent areas in the choroid that frequently cannot be detected on fluorescein angiography. This is used to identify areas of choroidal inflammation in the field of uveitis (**Figures 2.13–2.17**). Hyperfluorescence can be caused by abnormal retinal or choroidal vessels, leakage of dye, or an increased visibility through window defects. Compared to fluorescein, there is less leakage of ICG at sites of neovascularization. This facilitates the detection of vascular changes that may be missed on fluorescein angiography due to a 'smoke screen' effect from the leaking fluorescein.

At present, ICG angiography is most commonly used in the differential diagnosis of exudative age-related macular degeneration. It is particularly useful in identifying polypoidal choroidal vasculopathy, retinal angiomatous proliferations, and choroidal neovascularizations underneath pigment epithelial detachments. Additional indications include identification of choroidal neovascularization in ambiguous cases (high myopia, angioid streaks), central serous retinopathy, posterior uveitis, and choroidal tumors.

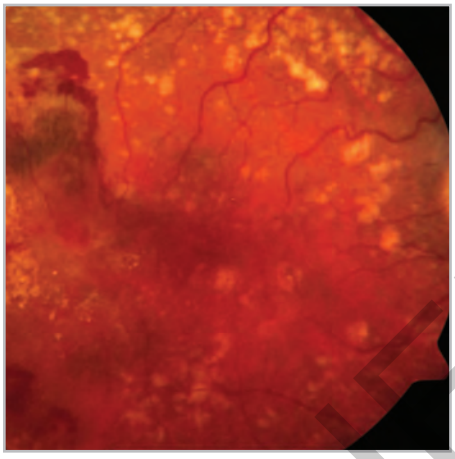

Figure 2.20 The right eye shows eccentric hemorrhages, pigment epithelial detachment and drusen at the posterior pole. (Figures 2.20–2.22 are from a patient with polypoidal choroidal vasculopathy).

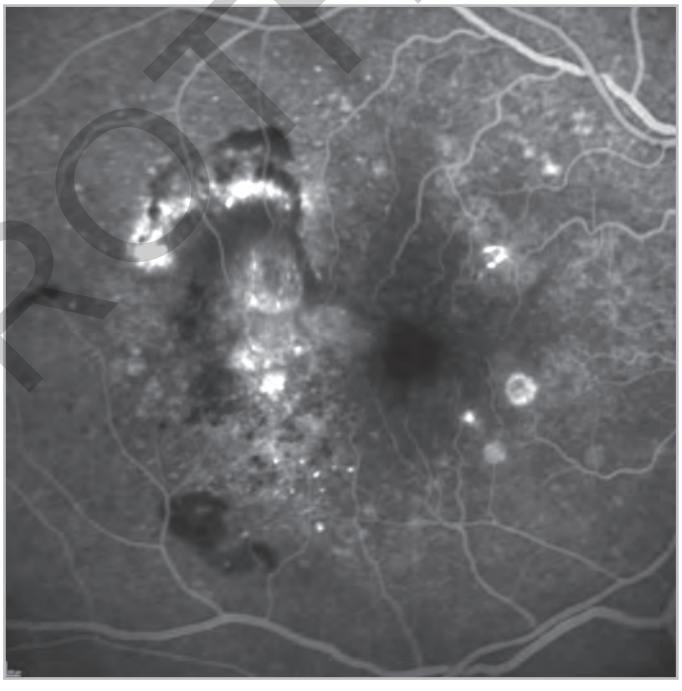

Figure 2.21 Fluorescein angiography. There is late leakage in the area of the fibrovascular pigment epithelial detachment, diffusely distributed over the posterior pole.

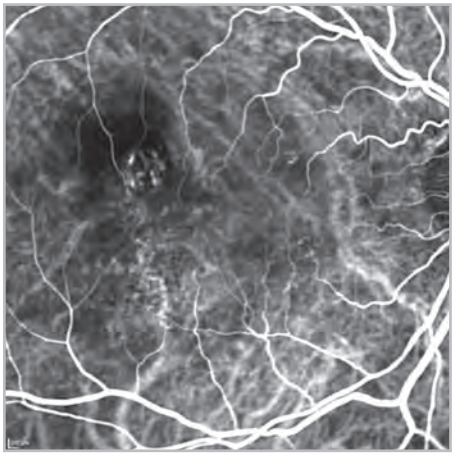

Figure 2.22 Indocyanine green (ICG) angiography reveals the underlying pathology of polypoidal choroidal vasculopathy.

TAYLOR & FRANCIS

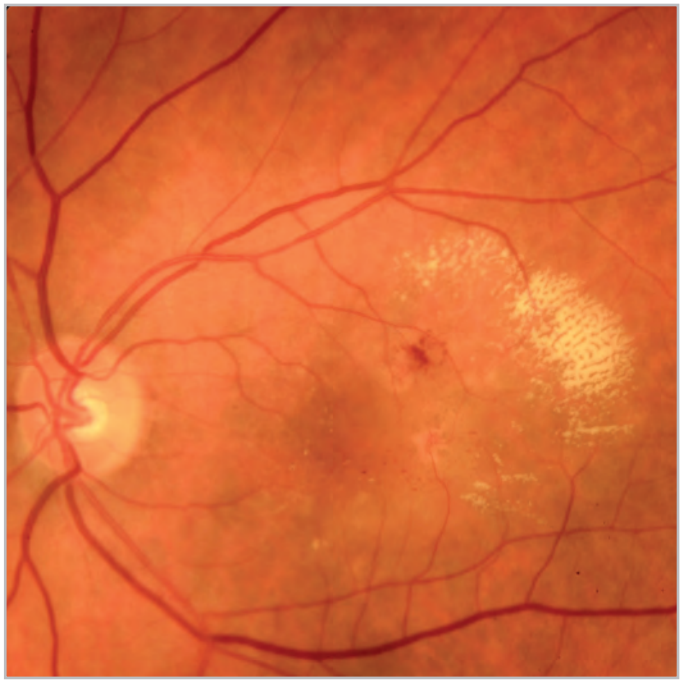

Figure 2.23 Retinal angiomatous proliferations (RAP lesions). The left eye shows eccentric hemorrhages and exudates suggestive of a possible retinal angiomatous proliferation lesion.

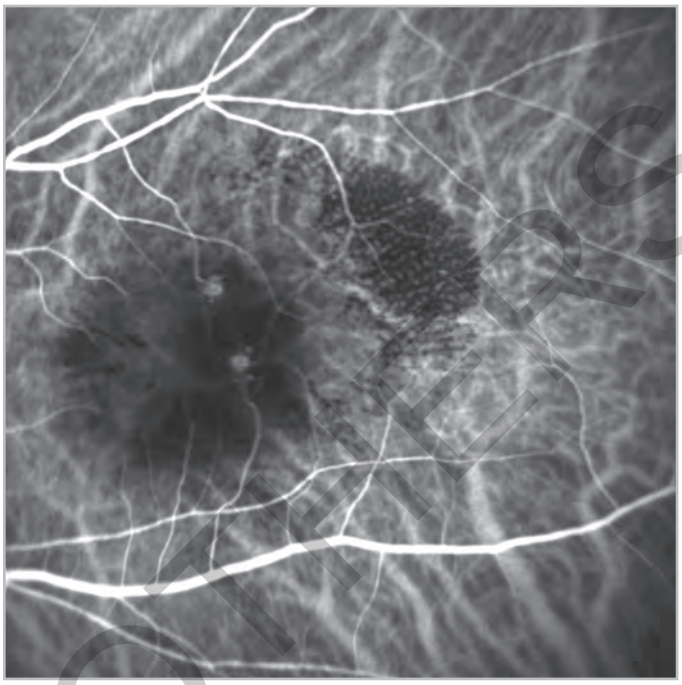

Figure 2.25 Retinal angiomatous proliferations (RAP lesions): indocyanine green (ICG) angiography. The multifocal retino-choroidal anastomosis can clearly be identified on ICG angiography.

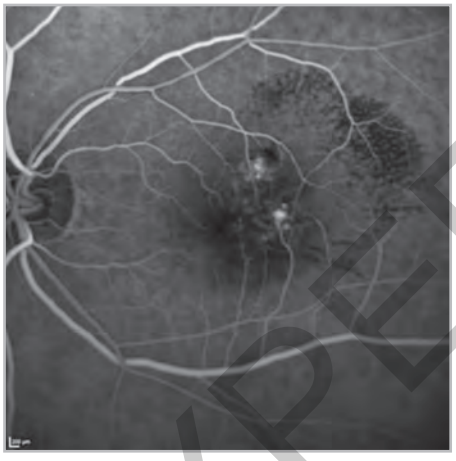

Figure 2.24
Retinal angiomatous proliferations (RAP lesions): fluorescein angiography. The late phase shows multifocal hyperfluorescent spots and late leakage.

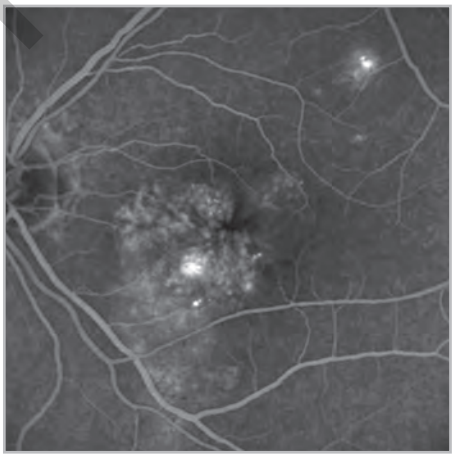

Figure 2.26
Central serous retinopathy: fluorescein angiography. There is an increase in multifocal hyperfluorescence in the actively leaking spots. Diffuse hyperfluorescence is seen in chronically damaged retinal pigment epithelium.

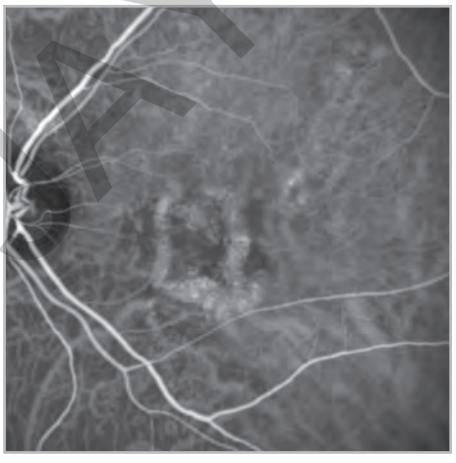

Figure 2.27
Central serous retinopathy: indocyanine green (ICG) angiography, venous phase. The actively leaking spots are surrounded by hypofluorescent choroid. There are ICG hyperfluorescent spots in the area of the active leakage as a sign of choroidal hyperpermeability underlying the defects in the retinal pigment epithelium.

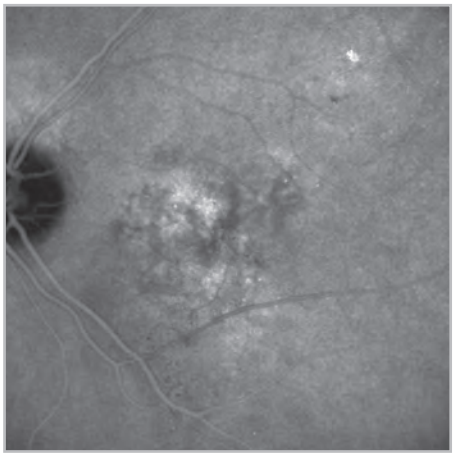

Figure 2.28
Central serous retinopathy: indocyanine green angiography (late venous phase). Diffuse hyperfluorescence surrounds the areas of active leakage and demonstrates the large areas of choroidal hyperperfusion and vascular pathology.

TYPE BROTHERS

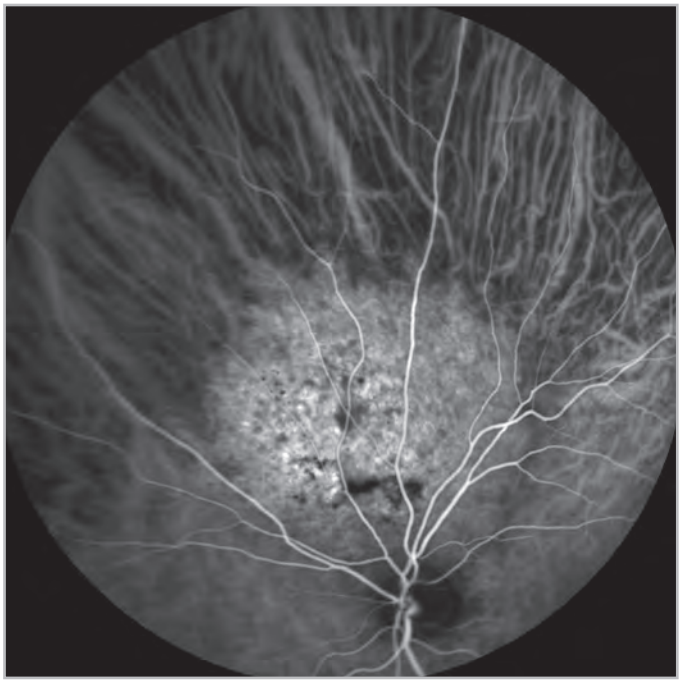

Figure 2.29 Circumscribed choroidal hemangioma, indocyanine green angiography (venous phase). Typical leakage is seen in the choroidal hemangioma during the early venous phase.



Figure 2.30 Circumscribed choroidal hemangioma after photodynamic therapy (PDT), indocyanine green (ICG) angiography (venous phase). This patient noticed a sudden visual loss 3 days following PDT for choroidal hemangioma. The ICG angiogram demonstrates a large area of hypofluorescence as an indicator of choroidal hypoperfusion corresponding to the area of PDT treatment.

REFERENCES

Chopdar A, Turk AM, Hill DW. Fluorescent infra-red angiography of the fundus oculi using indocyanine green dye. *Trans Ophthalmol Soc UK* 1978; **98**:142–146.

Flower RW, Hochheimer BF. Indocyanine green dye fluorescence and infrared absorption choroidal angiography performed simultaneously with fluorescein angiography. *Johns Hopkins Med J* 1976; **138**:33–42.

Hope-Ross M, Yannuzzi LA, Gragoudas ES, et al. Adverse reactions due to indocyanine green. *Ophthalmology* 1994; **101**:529–533.

Leys A, Horsman B (eds). Ophthalmic indocyanine green diagnostics study abstract book. Munich: PULSION Medical Systems, 2009.

Mori K, Yoneya S, Gehlbach PL. Indocyanine green angiography. In: Agrawal A (ed.), Fundus fluorescein and indocyanine green angiography. Thorofare, NJ: SLACK Incorporated, 2008:29.

Piccolino FC, Porgia L, Zinicola E, et al. Pre-injection fluorescence in indocyanine green angiography. *Ophthalmology* 1996; **103**:1837–1845.

Richard G. Choroidal circulation. New York: Thieme Medical Publishers, Inc., 1992:3–21.

Yannuzzi LA. Indocyanine green angiography: a perspective on use in the clinical setting. *Am J Ophthalmol* 2011; **151**:745–751.

JAYPEE BROTHERS

MULTIMODAL RETINAL IMAGING

Multimodal Retinal Imaging provides a comprehensive, practical overview of the various retinal imaging techniques available to the clinician. It gives trainee and practising ophthalmologists, as well as ophthalmic photographic technicians, the information they need to apply these techniques in everyday clinical practice and accurately interpret the results.

The first half of the book describes all the well-established modalities, such as fundus fluorescein angiography, but also includes newer techniques such as optical coherence tomography. It summarizes the history and development of each imaging technique and gives practical advice on its everyday use.

The second part of the book offers an overview of the retinal disorders, from macular degeneration to diabetic retinopathy and maculopathy. It describes how each condition presents and illustrates the multiple variations seen in clinical practice.

- Provides a definitive 'go to' reference for trainee and practising ophthalmologists
- Features a unique technique- and disease-based approach, with over 600 high-quality illustrations, giving a comprehensive but highly practical clinical reference
- Covers key areas of recent research and development, such as imaging of the outer retina and choroid and retinal imaging

JP medical publishers
www.jpmedpub.com
ISBN 978-1-907816-60-4
9 781907 816604