Musculoskeletal Imaging

Teik Chooi Oh
Matthew Budak
Rakesh Mehan

Foreword by Judith Adams

pocket tutor



JP

Contents

Foreword *v*
Preface *vii*
Acknowledgements *xii*

Chapter 1 Understanding normal results
1.1 Plain radiography 1
1.2 Ultrasound 4
1.3 Computerised tomography 7
1.4 Magnetic resonance imaging 10
1.5 Nuclear medicine 13

Chapter 2 Recognising abnormalities
2.1 Bony abnormalities 17
2.2 Tendon and ligament abnormalities 28
2.3 Muscular abnormalities 32
2.4 Soft tissue abnormalities 34

Chapter 3 Shoulder
3.1 Key anatomy 43
3.2 Shoulder dislocations 47
3.3 Acromioclavicular joint and clavicle injuries 50
3.4 Proximal humeral fractures 52
3.5 Rotator cuff pathology 55
3.6 Glenoid labral pathology 57

Chapter 4 Elbow
4.1 Key anatomy 61
4.2 Elbow trauma 64
4.3 Epicondylitis 67
4.4 Distal biceps tendon rupture 70

Chapter 5 Wrist and hand
5.1 Key anatomy 73
5.2 Distal forearm fractures 76
5.3 Carpal injuries 79
5.4 Hand injuries 84

5.5 De Quervain's disease 87
5.6 Triangular fibrocartilage complex pathology 89
5.7 Ulnar collateral ligament of thumb injuries 91

Chapter 6 Pelvic girdle and hip
6.1 Key anatomy 95
6.2 Avulsion fractures of the pelvis 98
6.3 Pelvic fractures 102
6.4 Femoral neck fractures 106
6.5 Developmental dysplasia of the hip 109
6.6 Acetabular labral pathology 111
6.7 Slipped upper femoral epiphyses 114
6.8 Perthes disease (Legg–Calvé–Perthes disease) 116
6.9 Avascular necrosis of the hip 118

Chapter 7 Knee
7.1 Key anatomy 123
7.2 Knee and tibial injuries 125
7.3 Meniscal pathology 129
7.4 Anterior cruciate ligament tears 132
7.5 Medial collateral ligament injuries 134
7.6 Quadriceps tendon injuries 136
7.7 Osgood–Schlatter disease 137
7.8 Baker's cyst 139

Chapter 8 Foot and ankle
8.1 Key anatomy 141
8.2 Ankle injuries 144
8.3 Foot injuries 149
8.4 Achilles tendon pathology 153
8.5 Tibialis posterior dysfunction 156
8.6 Morton's neuroma 158
8.7 Tarsal coalition 160

Chapter 9 Spine
9.1 Key anatomy 165
9.2 Atlantoaxial fractures 169
9.3 Vertebral fractures 173
9.4 Facet injuries 176

9.5 Scoliosis 180
9.6 Spondylolisthesis 182
9.7 Intervertebral disc herniation 186
9.8 Discitis 189
9.9 Spinal stenosis and cord compression 195

Chapter 10 Bony lesions
10.1 Bone tumours 201
10.2 Arthritides 219
10.3 Paget's disease 231
10.4 Medullary bone infarcts 236
10.5 Osteomyelitis 240
10.6 Osteochondritis dissecans 244
10.7 Rickets 247

Index *249*

chapter 4

Elbow

4.1 Key anatomy

The elbow is a hinge joint consisting of the humerus, the ulna and the radius. The trochlea articulates with the coronoid process and the olecranon. The capitellum articulates with the radial head. The proximal radioulnar pivot joint forms the 3rd elbow articulation, between the radial head and the radial notch of the ulna. This joint acts as a pivot for supination and pronation of the forearm.

The common flexor tendon arises from the medial epicondyle, and the common extensor tendon arises from the lateral epicondyle. The ulnar nerve passes through the cubital channel on the posterior surface of the medial condyle. The distal biceps tendon is lateral to the brachial vessels.

Imaging points

- Radiography remains the first-line imaging modality. Orthogonal anteroposterior radiography (**Figure 4.1**) and lateral radiography (**Figure 4.2**) are used in the routine assessment of the elbow.
- On both anteroposterior and lateral radiographs, the radiocapitellar line drawn through the mid radial neck must always pass through the capitellum (**Figure 4.1**).
- The anterior humeral line must pass through the middle third of the capitellum. Failure to do so suggests a displaced supracondylar fracture.
- The anterior fat pad is visible as a slim radiolucent area anteriorly (**Figure 4.2**). However, the posterior fat pad is never seen in a normal elbow.
- A number of ossification centres are visible in radiographs of children, depending on their age (**Table 4.1**).
- Computerised tomography is used primarily for presurgical planning for complex fracture patterns or for the detection of loose bodies. Computerised tomography may also help in the detection of occult fractures.

JAYPEE BROTHERS

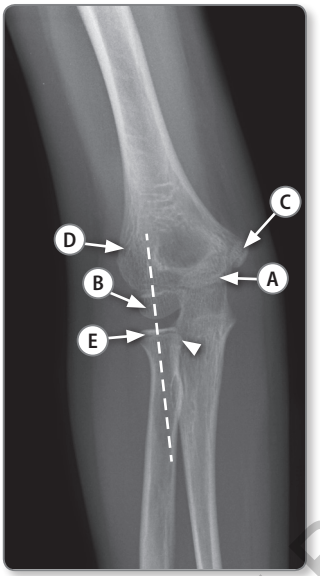

Figure 4.1 Anteroposterior radiograph of the right elbow, showing the trochlea (A), capitellum (B) and medial epicondyle (C). The lateral epicondyle ossification centre (which would be at point (D)) is not yet visible in this radiograph from a 9-year-old child. The radial head (E) articulates at the proximal radioulnar joint (arrowhead). The radiocapitellar line (dashed) crosses the capitellum.

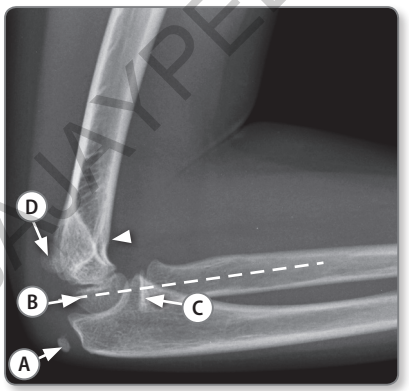

Figure 4.2 Lateral radiograph of the right elbow, showing the olecranon (A), capitellum (B) and radial head (C). The radiocapitellar line (dashed) crosses the capitellum. The medial epicondyle (D) is visible. A slim anterior fat pad (arrowhead) is present.

JAYPEE BROTHERS

Ossification centre	Approximate age (range) at which ossification centre appears (years)
Capitellum	1 (1–2)
Radial head	3 (2–4)
Internal (medial) epicondyle	5 (4–6)
Trochlea	8 (7–11)
Olecranon	9 (9–11)
External (lateral) epicondyle	11 (10–11)

Table 4.1 Ossification centres of the elbow in children

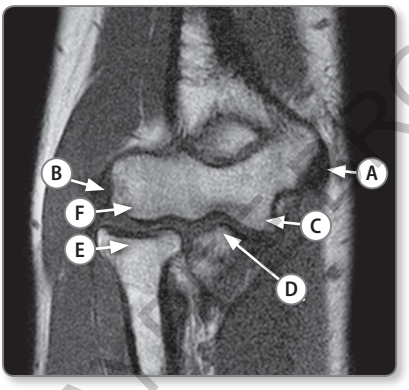

Figure 4.3 Coronal T1-weighted magnetic resonance imaging of the right elbow, showing the common flexor (A) and extensor (B) tendon origins, as well as bony structures including the trochlea (C), coronoid process (D), radial head (E) and capitellum (F).

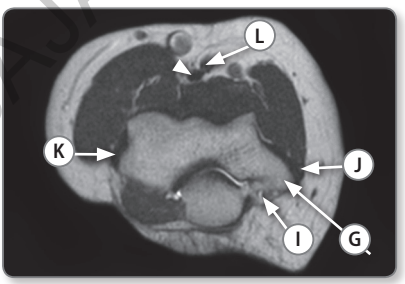

Figure 4.4 Axial T2-weighted magnetic resonance imaging of the right elbow, showing the common flexor (J) and extensor (K) tendon origins. Posterior to the medial epicondyle (G) lies the ulna nerve (I) within the cubital channel. The biceps tendon (L) is seen lateral to brachial artery (arrowhead).

JAYA BROTHERS

Clinical insight

If the olecranon ossification centre is visible but the medial (internal) epicondyle is not, this indicates an avulsion injury of the medial epicondyle. The epicondyle has been displaced; it is likely to be overlapping other bones.

- Magnetic resonance imaging (MRI) is good for visualising soft tissue, such as the common flexor and extensor tendon origins, the ulnar nerve and the distal biceps tendon (**Figures 4.3** and **4.4**).

4.2 Elbow trauma

The elbow is an important site for traumatic injuries as well as common chronic disorders (e.g. tennis elbow). Both fractures and dislocations occur at the elbow. When interpreting elbow radiographs, consider the patient's age; specific injuries tend to occur in certain age groups.

The following eponymous fractures are uncommon but often discussed. The Monteggia fracture is a fracture of the ulna and a dislocation of the radial head (**Figure 4.5**). The Galeazzi fracture is a fracture of the radial shaft (usually at the junction of the middle and distal third), with associated subluxation or dislocation of the distal radioulnar joint (**Figure 4.6**).

Key facts

- An elevated anterior fat pad (the sail sign) and the presence of a posterior fat pad (always abnormal) indicates a haemarthrosis and an intra-articular elbow fracture (**Figure 4.7**). Elevated fat pads may be the only radiographic finding in an occult fracture of the elbow.
- Elbow fractures in infants and young children are most commonly supracondylar (**Figure 4.8**). Many supracondylar fractures are radiographically occult.
- The most common elbow fractures in adults involve the radial head or neck (**Figure 4.7**). Any bone or bony process in the elbow (e.g. the coronoid process, olecranon or trochlea) can fracture.

JAYPEE BROTHERS

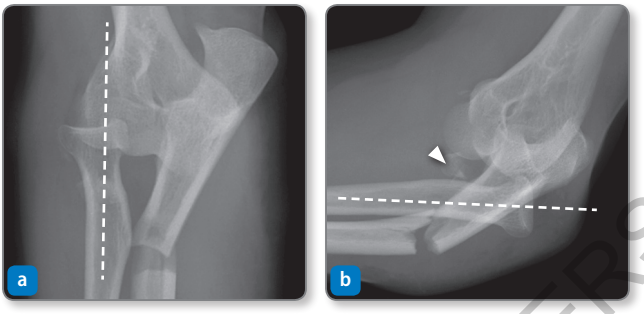

Figure 4.5 (a) Anteroposterior and (b) lateral radiographs of the right elbow, showing a Monteggia fracture. Dislocation of the ulna causes dislocation of the radial head, so that the radiocapitellar line (dashed) no longer crosses the capitellum. An associated fragment (arrowhead) was confirmed as a coronoid process fracture on computerised tomography (not shown).

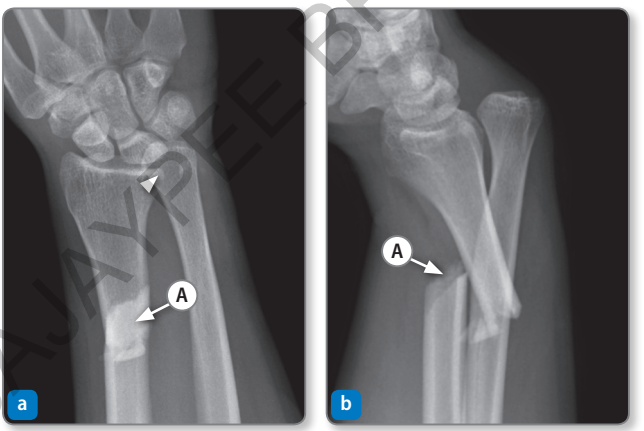

Figure 4.6 (a) Anteroposterior and (b) lateral radiographs of left wrist showing a Galeazzi fracture of the distal third of the radial shaft (A), with overlapping areas of increased opacity. There is disruption of the distal radioulnar joint (arrowhead) with a dislocated distal ulna.

JAYPEE BROTHERS

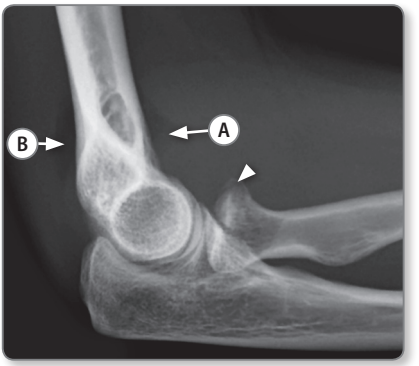

Figure 4.7 Lateral radiograph of the left elbow, showing the sail sign of an elevated anterior fat pad (A) and the presence of a posterior fat pad (B). These findings indicate haemarthrosis caused by a radial head fracture (arrowhead).

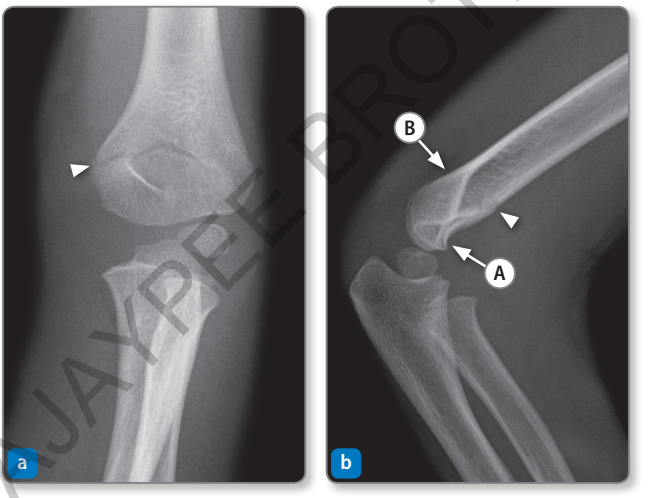

Figure 4.8 (a) Anteroposterior radiograph of the left elbow, showing a supracondylar fracture (arrowhead) in a child. (b) A lateral radiograph shows a subtle undisplaced cortical break (arrowhead) in this undisplaced fracture, but the underlying sail sign (A) and presence of a posterior fat pad (B) should alert the clinician to look for a supracondylar fracture.

JAYPEE BROTHERS

Radiological findings

Radiography Loss of cortical integrity, radiolucent lines and displaced bone fragments are seen in fractures of the elbow. Elbow dislocations involve loss of articulation between the radial head and the capitellum of the humerus (radial head dislocation; **Figure 4.5**), disassociation of the proximal ulna from the trochlea of the humerus (complete elbow dislocation), or both.

Key imaging findings

- A step in the cortex or a radiolucent line is seen in displaced fractures.
- In adults, the radiocapitellar line should always intersect the radial head and the capitellum (**Figures 4.1** and **4.2**). Misalignment indicates subluxation or dislocation of the radial head (**Figure 4.5**).

Treatment

Most simple fractures are treated by reduction and immobilisation. Complex injuries may need open reduction and internal fixation.

4.3 Epicondylitis

Epicondylitis is inflammation of the common extensor or flexor tendon of the elbow.

Key facts

- Lateral epicondylitis involving the common extensor tendon origin is known as tennis elbow and accounts for 80% of cases of epicondylitis.
- Lateral epicondylitis is typically an overuse injury caused by repetitive extension or flexion of the elbow.
- Imaging is reserved for cases refractory to non-surgical management.

JAYPEE BROTHERS

Radiological findings

Ultrasound A focal hypoechoic area or thickening (**Figure 4.9**) can be seen deep in the common tendon origin. There may be active Doppler flow, which indicates active inflammation. A minority of cases of epicondylitis involve discrete partial- or full-thickness tears.

Magnetic resonance imaging There is increased signal return at the common tendon origin on T2-weighted and short T1 inversion recovery sequences. Underlying bone marrow oedema may be visible. Focal linear fluid signal in the tendon indicates a tear (**Figure 4.10**).

Key imaging findings

- The common extensor or flexor tendon origin has a typical tendinopathic appearance.
- It is important to detect any associated partial- or full-thickness tears.

Treatment

Over 90% of cases of epicondylitis resolve in 4–6 weeks with simple oral analgesia, splints and physiotherapy. Corticosteroid

JAYPEE BROTHERS

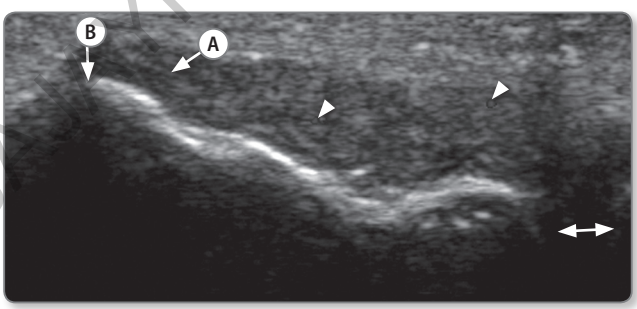

Figure 4.9 Longitudinal ultrasound view of the elbow, showing a thickened hypoechoic common extensor tendon (A) arising from the lateral epicondyle (B) proximal to the elbow joint (double arrows). Doppler flow is present in the inflamed tendon (arrowheads).

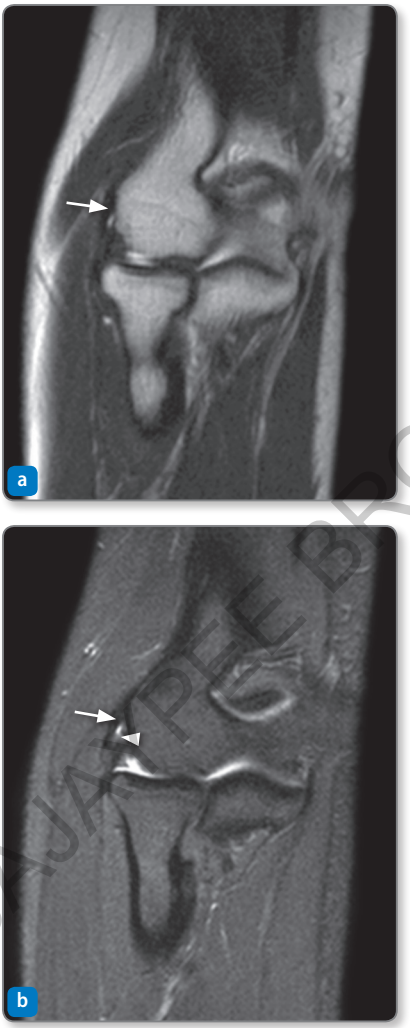

Figure 4.10 (a) Coronal T2-weighted and (b) short T1 inversion recovery (STIR) magnetic resonance imaging of the right elbow. The thickened common extensor tendon (arrows), with focal increased fluid signal (arrowheads), is consistent with a partial-thickness tear. These features are clearer in the STIR image.

JAYPEE BROTHERS

injections can be beneficial in recalcitrant cases. Surgical tendon release can help in non-responsive cases.

4.4 Distal biceps tendon rupture

The distal biceps tendon may rupture from its insertion on the radial tuberosity. The rupture usually presents as a painful, swollen elbow after a traumatic event. If a full-thickness tear is confirmed, identifying the site of proximal tendon retraction can help in surgical fixation.

Key facts

- Distal biceps tendon rupture usually occurs in middle-aged men. The injury presents with a sudden painful tearing sensation over the antecubital fossa.
- The mechanism of injury usually involves sudden extension when the forearm is flexed or supinated.

Radiological findings

Ultrasound Features of a tendon rupture are present, either a partial-thickness tear or a complete tear (**Figure 4.11**) with varying degrees of tendon retraction. Associated surrounding hypoechoic fluid suggesting oedema or haemorrhage is often seen.

Clinical insight

Patients tend to present with the so-called Popeye sign: a biceps muscle bunched-up from tendon retraction.

Clinical insight

In imaging studies, the brachial artery is a good landmark to use when identifying the distal biceps tendon. The tendon runs parallel to the artery.

Magnetic resonance imaging Partial-thickness tears retain some form of continuity, with surrounding high signal intensity on T2-weighted imaging (**Figure 4.12**). Full-thickness tears show tendinous discontinuity with retraction.

Treatment

Management of distal biceps tendon rupture depends on

JAYPEE BROTHERS

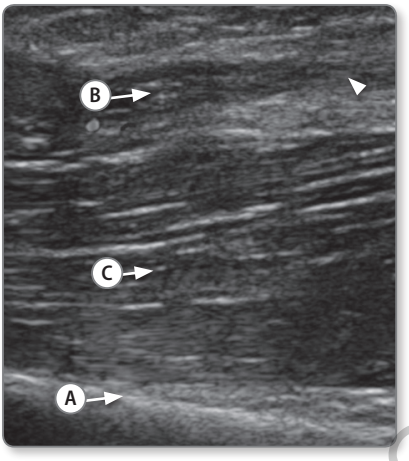

Figure 4.11 Longitudinal ultrasound view of the distal humerus (A), showing proximal retraction of the distal biceps tendon (B) caused by a full-thickness tear. An empty tendon sheath is visible distally (arrowhead). The underlying brachialis (C) is normal.

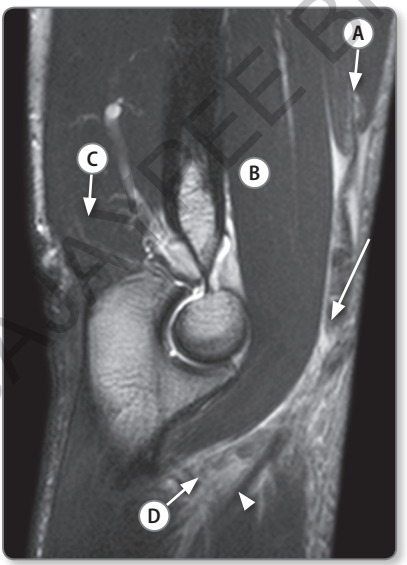

Figure 4.12 Sagittal T2-weighted magnetic resonance imaging of the right elbow, showing the biceps belly (A) and retraction of the proximal tendon (long arrow) caused by a partial-thickness tear. The distal tendon (D) is ill defined before the insertion (not shown). The brachial artery (arrowhead) is adjacent. (B) Underlying normal brachialis, (C) triceps muscle.

JAYPEE BROTHERS

the degree of tear, the amount of remnant function and the age of the injury. Surgery is indicated for patients unable to tolerate loss of supination strength with non-operative treatment.

JAJAYPEE BROTHERS