





REJUVENATION OF THE AGING FACE

Amir M Karam
Mitchel P Goldman

Contents

Preface v

Contributors ix

Chapter 1
Historical perspectives 1
Stephen Mandy

Chapter 2
The multicomponent approach to facial rejuvenation: skin, volume, and sagging 3
Amir M. Karam

Chapter 3
The multispecialty approach to treatment of the aging face 7
Amir M. Karam

Chapter 4
Fat transfer 9
Amir M. Karam, Samuel M. Lam

Chapter 5
Soft tissue augmentation with hyaluronic acid and calcium hydroxylapatite fillers 15
Sabrina Guillen Fabi, Mitchel P. Goldman

Chapter 6
Poly-L-lactic acid 25
Melanie D. Palm

Chapter 7
Upper eyelid blepharoplasty 39
Amir M. Karam

Chapter 8
Lower eyelid blepharoplasty 45
Amir M. Karam

Chapter 9
Lateral brow lift with superficial temporal fascia plication 55
Amir M. Karam

Chapter 10
Short-incision vertical face lift and neck lift 61
Amir M. Karam

Chapter 11
Neuromodulators 73
Derek H. Jones

Chapter 12
Chemical peels for aging faces of all skin types 79
Peter Paul Rullan, Amir M. Karam

Chapter 13
Fractionated CO_2 laser resurfacing and ablative skin rejuvenation 91
Jennifer D. Peterson, Mitchel P. Goldman

Chapter 14
Fractionated nonablative skin rejuvenation 105
Daniel P. Friedmann, Jennifer D. Peterson, Sabrina Guillen Fabi, Mitchel P. Goldman

Chapter 15
Treatment of red and brown pigmentation 117
Daniel P. Friedmann, Mitchel P. Goldman

Chapter 16
Multicomponent facial rejuvenation: case series 131
Amir M. Karam, Mitchel P. Goldman, Ana Marie Liolios

Index **139**

Chapter 4 Fat transfer

Amir M. Karam, Samuel M. Lam

JAYPEE BROTHERS

INDICATIONS/PATIENT SELECTION

Facial volume loss is a universal process in aging. From the age of 35 years onwards, facial fat begins to diminish in a predictable and progressive way. This leaves the face looking deflated, tired, and older. A youthful appearance is closely tied to the volumetric fullness and presence of soft convexities rather than concavities and hollows. Our understanding of this is relatively recent. Traditional surgery for facial rejuvenation has been almost exclusively predicated on lifting and excisional-based techniques, e.g. face lift, brow lift, blepharoplasty, and midface lift. Although gravitational forces are clearly at play (see Chapter 10), a major contribution of facial aging is volume loss and the subsequent deflation that represents the aged appearance. An understanding of the role of fat loss and the subsequent need to restore this lost volume has led to the development of various volume replacement methods over the last 10 years. However facial fat grafting is the only option that allows for the natural replacement of the lost fat. One of the major tenets of reconstructive surgery is that when given the opportunity it is always best to replace like with like. Autologous fat transfer allows this and advances in this specialty have radically changed our approach to treating the aging face. In the authors' practices, this application is used in both stand-alone cases, in which volume loss is the primary aging change, and in combination with other surgical techniques. In a modern approach, volume augmentation needs to be addressed as part of a well-balanced and holistic facial rejuvenation treatment plan.

PREOPERATIVE CONSIDERATIONS

Understanding volume loss

The first step in applying any form of volume restoration technique is to understand how the face loses volume and to recognize the importance of this process. Without doing so, it is very difficult to communicate the benefits of the treatment to the patient.

An effective way to assess the impact of volume loss is to compare the patient's current appearance with old photographs that show their younger face. By doing so, the physician is able to see the changes that have taken place. This makes communication with the patient much more efficient. Once these changes are communicated to the patient, he or she can then objectively see the effects of deflation that has resulted from senescent fat loss. This foundation is critical when trying to restore the patient's youthful look in a way that looks natural.

The volume loss pattern

Fat loss is predictable and affects the same facial regions in every individual.

Fat loss of the periorbital region affects the following:

- Temples
- Lateral brow
- Sub-brow
- Medial and lateral inferior rim
- Nasojugal region
- Anterior and lateral cheeks

Fat loss in this region leaves the eyes looking hollow and sunken, resulting in a tired, aged appearance. The midface, malar, and cheek region also suffer significantly from volume loss.

The exposure of the malar bone and the concurrent hollowness in the anterior cheek and lower eyelid are perhaps the most critical regions to replenish with fat grafting. Many individuals look tired as they age because of volume loss in the anterior cheek. In order to show a prospective patient the effect that volume gain in the anterior cheek can have on the brightness and alertness of the eyes, gently push the cheek upward with a finger from below to simulate the effect of volume addition (do not lift the cheek from above with a finger but push the cheek up to create the illusion of volume).

The lower face can also benefit from fat transfer. The segments of the lower face to evaluate are:

- Preauricular
- Buccal
- Precanine (premaxillary)
- Lips
- Prejowl
- Angle of mandible
- Chin
- Sublabial sulcus

Fat transfer can be used to soften the early presence of a jowl by filling its anterior soft tissue depression (the so-called prejowl) but this should not be thought of as a replacement for a lower face lift. The buccal and preauricular regions are important segments of the face that become excessively volume deficient, especially in thin patients.

Establishing patient expectations

Preoperative patient counseling sessions offer the physician an opportunity to discuss and manage the patient's expectations regarding potential recovery time, longevity of result, and expected changes following the procedure.

When it comes to recovery, it is important not to set time limits on how far the healing period will extend. The conservative rule of thumb is that most patients will not be happy at a week and others who see them may also be alarmed at their appearance. At 2 weeks, many patients are relieved that they look better, albeit a bit swollen, but they still may not like their appearance. By 3 weeks, there should be greater unanimity about the results of the procedure. However, a surgeon can never predict with absolute certainty how a patient or others will respond to the patient's healing process.

Further more, no matter what guidelines are established regarding recovery, three principles must be considered. Firstly, individuals recover differently. Secondly, different surgical techniques will account for differences in recovery. Finally, recovery is almost directly

proportional to the amount of fat transferred. It is the duty of the surgeon to help a prospective patient understand what to expect over the weeks, months, and years following a fat transfer. Postoperative edema remains for the first 1–3 weeks but becomes more subtle thereafter (it is normal to see some edema for the first 2 months). Thereafter, there can be a period of decreased edema, until the blood supply is fully intact after 6 months, when the benefits of the fat transfer may not be apparent. Patients should be warned that they may be disappointed with their result between the second and sixth months (or a wider interval of time). The surgeon must resist the temptation to perform a touch-up or revision procedure as this can lead to overinflation once the result of the original procedure bears fruit. Often, the result continues to improve after the first year until approximately 2 years after the procedure. With further aging, results can diminish slightly, but only appreciably so after many years. In terms of longevity, a fat transfer result is permanent, but facial fat that was present prior to the fat transfer does continue to diminish with age.

OPERATIVE TECHNIQUE

Preoperative planning

With the patient seated, mark injection entry points on the face (**Figure 4.1**). Next, mark the donor sites. The two main areas for harvesting are the lower abdomen and thighs (medial or lateral).

Anesthesia

Although fat grafting can be accomplished with the patient fully awake, it is performed with greater patient compliance and comfort when the patient is either sedated (orally or intravenously) or under general anesthesia.

Although various local anesthetic mixtures can be used with success, a common mixture consists of 5 mL of 1% lidocaine and 1:100,000 epinephrine with 15 mL of plain saline. Half of the 20 mL mixture is injected beneath the fat compartment and the other half is distributed superficially using 22 gauge spinal needle. For each site injected, use approximately 20 mL of solution. For example, if the lower abdomen is harvested, a total of 20 mL is used for anesthesia in that area; for the inner thighs, use 20 mL on each side.



Figure 4.1 Fat injection access points on the face. These are labeled A, B, and C. Additional access points can be made anywhere in order to reach difficult regions of the face, such as the medial aspect of the upper orbital rim.

The face (including the mental nerves, infraorbital nerves, and supraorbital nerves) is anesthetized with a regional anesthetic block to minimize discomfort. The entry sites for the face are then infiltrated with 1% lidocaine and 1:100,000 epinephrine.

Harvesting

The patient is preped and draped using sterile technique. Harvesting of fat is undertaken by hand suction. The entry site is accessed with a No. 16 Nokor needle or an 11 blade scalpel in a discrete location, e.g. the lower aspect of the umbilicus for the lower abdomen. A bullet-tipped harvesting cannula (Tulip Medical Inc, San Diego, CA) is commonly used to harvest the fat from the donor area. The cannula is outfitted on a 10 mL Luer-Lok syringe. Gentle negative pressure is used to harvest the fat. The surgeon should take care to keep the harvesting cannula within the center of the fat plane, thereby allowing the cannula to pass across the entire expanse of the area to be harvested. The surgeon's nondominant hand should not be used to cover the skin during harvesting as this can lead to contour irregularities. Instead, with the palm held flat against the skin in the area to be harvested, the nondominant hand can be used to stabilize the fat pad while moving the cannula. At the same time, care should be taken to remove the same amount of fat from the contralateral side, to minimize the chance of an asymmetric outcome.

Processing

Fat processing techniques vary between physicians: straining, centrifugation, and washing all have their proponents. As long as care is taken to handle the fat grafts carefully, any fat isolation technique can yield excellent results. Since centrifugation is a simple system to learn and reproduce, we will focus on this method.

Under sterile conditions the fat is collected, and the cannula is removed from the 10cc syringe and replaced with a Luer-Lok plug. The plunger is then removed and replaced with a tight-fitting cap. Syringes prepared in this way should be placed into sterile sleeves in a centrifuge and spun for approximately 3 minutes at 3000 rpm. Following centrifugation, the syringes are removed. Next, the supranatant is poured off of the plunger side, and then the infranatant is drained off from the Luer-Lok side. An open 4 × 4 gauze is inserted and held in the open plunger side for several minutes to remove any remaining supranatant. A sterile test-tube rack should be used to keep all the syringes close at hand during this phase of the procedure. The collected fat is then placed into a 20 mL syringe and the plunger inserted into the back of the 20 mL syringe. Take care not to squirt the fat into the air by tilting the Luer-Lok side of the 20 mL syringe upward and sliding the fat back toward the plunger while this is being inserted and the air column advanced out of the syringe. A female-to-female Luer-Lok transfer hub should be used to transfer the contents from the 20 mL syringe into individual 1 mL Luer-Lok syringes intended to infiltrate the fat into the face. The infiltration cannula, typically a 1.2 mm wide straight and blunt cannula (Tulip Medical Inc., San Diego, CA), is fitted onto the 1 mL Luer-Lok syringe, ready for fat injection. The total amount of harvested fat available should be quantified at this time to ensure that enough has been harvested and processed.

Injection

The entire procedure can be undertaken through any one of the following three entry sites: entry site A (midcheek), entry site B (near the lateral canthus), or entry site C (lateral to the prejowl) (Figure 4.1). Additional entry sites can be used for areas that are less frequently approached, e.g. the lateral canthus and lateral mandible. All entry points are accessed with a standard 18 gauge needle. **Figure 4.2** shows the di-

MAY BE BROTHERS

rection the cannula passes while filling the facial subunits listed below.

In general, we fill bilateral structures sequentially, e.g. the lower eyelid orbital rim on the left followed by the right. Using the filled 1 mL syringes, fat is injected into sensitive areas like the inferior orbital rim in miniscule quantities. In less sensitive areas like the cheek fat is injected in larger aliquots (approximately 0.1 mL). The injection is performed using gentle application of the thumb and can be undertaken in both directions, i.e. on entry or during exit of the cannula. Blunt injection cannulas are preferred because they are less likely than sharp cannulas or needles to cause intravascular penetration.

Inferior orbital rim

The inferior orbital rim is one of the most challenging sites for fat transfer. Too much volume placed in the wrong tissue plane can lead to poor results, such as contour problems that are difficult to manage From entry point A, guide the cannula up toward the orbital rim via the supraperiosteal plane. Use the nondominant index finger to protect the globe. No more than 0.01 mL of fat should be injected per pass of the cannula. In general, a total of no more than 3 mL should be placed on either side of the face. Sometimes it can be helpful to inject another 0.5 mL into the lateral canthal hollow, which is more easily approached from a separate lateral entry site. An additional 1 mL of fat can be placed into the nasojugal groove, or triangular soft tissue defect just inferior to the medial aspect of the inferior orbital rim, in order to augment this area of depression.

Anterior cheek

The anterior cheek is one of the most straightforward sites to fill in the midface. In many patients, a midcheek depression runs obliquely across the anterior cheek. Using the lateral canthal entry point, the surgeon can build up the deficit of the anterior cheek inferomedially, by moving the cannula back and forth across the malar ligament depression. Typically, 1–2 mL is adequate to build the anterior cheek dimension.

Lateral cheek

The lateral cheek is the area adjacent to the anterior cheek but it lies lateral to the malar bony prominence. The lateral cheek can be approached easily from the midcheek entry site while aiming the cannula superolaterally. Typically, 1–2 mL is adequate to build the lateral cheek dimension.

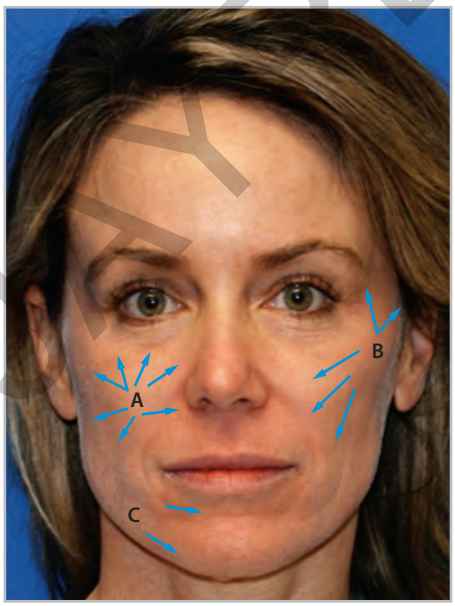

Figure 4.2 The vectors of fat injection through various entry points. The entire face can be injected through these points.

Temple area

This area can be used to soften the skeletonized appearance that develops as the fat is diminished and the zygomatic bone and lateral upper orbital rim become more prominent. The access point for injections here is through the lateral orbital rim. The fat is injected in very small quantities into the superficial temporal fascia plane. Typical volumes can range between 1 and 3 mL.

Superior orbital rim (infrabrow)

This is another very challenging area to inject. Injection should be from the lateral orbital rim position. Small threads of fat should be injected in a retrograde fashion. Typical volumes of 1–3 mL are needed to sufficiently address this region.

Buccal area

For patients with a gaunt midface, it is important to augment the buccal region simultaneously with the anterior cheek. If left untreated, the buccal area will appear more hollow. The buccal area can be easily approached from entry site A, aiming inferolaterally in the immediate subcutaneous plane. Between 1–4 mL of fat can be used depending on the degree of hollowness. Additional fat can be placed more laterally into the soft tissue hollow below the lateral zygoma (preauricular region) in order to produce a more balanced augmentation.

Anterior chin and prejowl sulcus

The anterior chin and prejowl sulcus are important areas for augmentation. Entry point C is used and the injection is made into the bony expanse of the anterior chin, above the bony mentum and below the lip, to fill a deficiency that develops with age along the mental crease. Approximately 2–4 mL of fat is injected into the anterior chin region in the subcutaneous plane using larger aliquots of 0.1 mL per pass. For the prejowl sulcus, approximately 2–3 mL is used to inject along the inferior mandible from an entry point just lateral to the prejowl sulcus.

Nasolabial groove/canine fossa

We believe that fat transfer is less successful in active areas like the nasolabial grooves and in the lips due to a high resorption rate of transferred fat. About 2–4 mL of fat can be injected into the nasolabial groove. Approaching from the midcheek entry point, 0.1 ml per pass of fat is placed in the immediate subcutaneous plane.

The surgeon should not only target the expanse of the nasolabial groove but also take care to augment the upper recess of the groove known as the canine fossa.

POSTOPERATIVE CONSIDERATIONS

Since there are no sutures on the face, postoperative care is minimal. Application of ice for the first 2 days can reduce postoperative edema,

MAYER BROTHERS

as can avoidance of excessive straining, bending over, and salt intake. While exercise in the immediate postoperative period is acceptable, the patient should be advised against exercises that involve bending (e.g. yoga) for 1–2 weeks following the procedure.

Postoperative visits should be scheduled for 1 week, 1 month, 3 months, 6 months, and 1 year following the procedure. As discussed previously, patients should be made aware of the changes that will occur for up to 18 months postoperatively. We routinely evaluate our patients with sequential photographs to show them these changes.

COMPLICATIONS

By adhering to the techniques outlined in this chapter, complications following fat transfer should be greatly diminished, but these can never be entirely eliminated. The four principal complications that can occur following fat transfer are lumps, bulges, overcorrection, and undercorrection. The first two involve contour problems due to technical error; the latter two result from inappropriate choice of total volume of fat injected into the face. One other rare complication is divoting at the injection site.

Lumps

A lump is a discrete, raised contour of transplanted fat usually resulting from the placement of too large a bolus of fat in a sensitive region, for example 0.1 mL or more (instead of 0.01 mL) into the inferior orbital rim during one pass of the cannula. Unlike nonsensitive areas like the buccal area, which can handle large boluses of fat per pass, the periorbital and temple regions must be augmented with very small aliquots to avoid visibility. If a discrete bolus arises postoperatively, the best approach is to wait for the the complication to dissipate. The need to intervene will be determined by patient compliance and the absence of signs of improvement. Ultimately excision of the offending lump may be required, though only after conservative measures have been employed. A dose of 5-fluorouracial (5-FU) 30 mg/mL should be injected, in small amounts (0.1–0.3 mL), into the mass to dissolve the fibrotic tissue responsible for the lump. Dilute steroid injections can also help, starting with half-strength triamcinolone acetonide (10 mg/mL is the standard strength) and then increasing the dosage over the following weeks and months to a concentration recognizes the risks of dermal atrophy. Often a lump can only be corrected with surgical excision. If the lump must be excised, a discreet incision should be made along relaxed skin tension lines and along defined linear depressions, such as the tear trough or along the inferior orbital rim. This will result in a more discrete linear scar. The less sebaceous the skin, the better camouflaged the surgical scar will be When the offending fat bolus is encountered and appears to be a discrete mass, it can be easily identified and removed. Incisions are always closed using a standard two layer closure technique.

Bulges

A bulge resembles a lump but has a different pathology. A bulge is typically a firm, fibrotic cigar roll arising across the inferior orbital rim due to placement of fat in the wrong plane or from an incorrect angle of entry (typically laterally based and parallel to the orbital rim). The firm and fibrotic nature of a bulge results from the scarring that is a principal component of the problem. A bulge is much more amenable to injection with 5-FU and/or triamcinolone (as needed) than a lump. In most cases, surgical excision is unnecessary. We recommend the same escalating dosage of 5-FU and then steroid for bulges as described above for the treatment of lumps. However, the outcome should be more successful with a bulge than with a lump.

Overcorrection (vs. malar edema)

A patient who appears overcorrected should be closely monitored, as the areas may simply look hypertrophied due to early edema. Unfortunately, overcorrection is very hard to correct entirely as the transplanted fat is difficult to remove. Microliposuction can be undertaken to reduce the overtransplanted areas, using the same infiltration cannula attached to a 10 mL syringe and manually extracting the transplanted fat in a uniform, fanning technique. Retract the syringe plunger almost all the way back for ease of use during microliposuction. Open liposuction with a 3–4 mm cannula can often lead to contour divots and should be undertaken with care. In general, microliposuction is the safest course of action for removal of overtransplanted fat. Sometimes a patient may appear overcorrected simply because he or she has gained weight following the procedure.

Patients should be within 17-20 pounds of their stable weight before undergoing a fat transfer. The best course of action if the patient appears overcorrected due to weight gain is to ask the patient to try to lose weight in order to return to an acceptable result. It is hard to provide concrete guidance on how much weight gain will affect a result, since height, muscle mass, and other factors can lead to variable results. In general, weight gain of more than 20 lb can lead to a demonstrably overcorrected result. In addition to being overcorrected, the transplanted fat may actually appear 'bulgy' since it hypertrophies differently from facial fat. Accordingly, fat transfer should not be performed to correct discrete facial deficits in order to limit this risk.

Another entity that can be confused with overcorrection is persistent malar edema. Often, this occurs in individuals who are predisposed toward cyclical edema. Such predisposition should be elicited while taking the patient's history preoperatively. Typically, patients will confirm that the edema in their cheek worsens and extends up to the lower eyelid in the morning, but then resolves later during the day. Salt intake can worsen this condition. In extreme cases, a poor skin quality is found which proportionately increases the postoperative edema in both extent and duration. If the problem persists, injection of dilute steroids (as prescribed above in the section describing management of lumps) can be initiated. The edema should dissipate within a few months.

Undercorrection

It is easier to add additional fat than to remove excess amounts. Remember also that the appearance of undercorrection between 2 and 6 months following the procedure may just result from f the edema resolving itself before the full result of the procedure becoming evident after 6 months. The surgeon should always wait for a result to mature before embarking on a premature and unnecessary correction.

Injection-site divot

This is a very rare occurrence that can arise at the cannula entry site. The tethering of the dermis to the underlying subcutaneous plane can be exacerbated, or become more noticeable during smiling or excessive animation. Using a standard 18 gauge needle to subcise the scar should be sufficient in most cases. However, a temporary spacer like hyaluronic acid may provide a long-term solution in cases of relapse.

CONCLUSIONS

Fat grafting can be a safe intervention for the aging face either as a standalone treatment or as a complement to more traditional lift-

JAYPEE BROTHERS

ing procedures. Understanding the role and sites of volume loss in facial aging is a prerequisite to refining one's technique. The current protocols described in this chapter can lead to safe and long-lasting outcomes provided the surgeon exercises proper technique and judgment.

ILLUSTRATIVE CASES

Case 1: Full-face fat transfer in a 47-year-old woman

A 47-year-old woman before (**Figure 4.3A**) and 18 months after full-face fat transfer (**Figure 4.3B**). This patient exhibits the usual aging changes related to volume loss. Note the improvement of every facial subunit, while her face remains natural looking, balanced and refreshed.

Case 2: Full-face fat transfer in a 36-year-old woman

A 36-year-old woman before (**Figure 4.4A**) and 5 years following full-face fat transfer (**Figure 4.4B**). Her preoperative photograph illustrates early volumetric changes consistent with facial fat loss. This leaves her with a fatigued appearance. The post treatment photograph shows a significant improvement in her appearance. It is noteworthy how stable the changes have been over the 5-year interval.



Figure 4.3 Full-face fat transfer in a 47-year-old woman. (A) Before and (B) 18 months after treatment.



Figure 4.4 Full-face fat transfer in a 36-year-old woman. (A) Before and (B) 5 years after treatment.

JAYPEE BROTHERS

FURTHER READING

Karam AM, Glasgold RA, Glasgold MJ, Lam SM. Fat grafting: a volumetric approach to midfacial rejuvenation In: Hartstein ME, Wulc AE, Holck DEE (eds). Midfacial Rejuvenation. New York: Springer, 2012.

Lam S, Glasgold M, Glasgold R. Complementary Fat Grafting. Philadelphia, PA: Lippincott, 2007.

Yaremchuk MJ , Kahn DM. Periorbital skeletal augmentation to improve blepharoplasty and midfacial results. Plast Reconst Surg 2009; 24:2151–2160.

JAYPEE BROTHERS

REJUVENATION OF THE AGING FACE

With our improved understanding of the aging process has come an increase not just in the demand for cosmetic procedures designed to manage the aging face, but also in the range of procedures available.

Rejuvenation of the Aging Face provides a comprehensive, practical guide to combining nonsurgical and surgical treatments in pursuit of the most natural result for patients. Starting with an overview of the physical changes that contribute to facial aging, later chapters describe the complete range of treatments available to the clinician, from new techniques such as fat transplant to fast-moving areas such as injectables and laser resurfacing.

Integrating the expertise of highly regarded facial plastic and dermatologic surgeons, *Rejuvenation of the Aging Face* is an indispensable resource for physicians wishing to combine both nonsurgical and surgical approaches to facial rejuvenation.

- Multidisciplinary author team describes latest best practice for established and emerging techniques
- Chapters provide framework for assessing the impact of aging on the structures of the face, then summarize the best treatment options
- Illustrative cases demonstrate real-life scenarios that highlight the benefits of employing the optimal combination of treatments

JP medical publishers

www.jpmedpub.com

ISBN 978-1-907816-79-6

9 781907 816796