FRCS (Tr & Orth): MCQs and Clinical Cases

MCQs and vivas from *The Bone & Joint Journal* (formerly *JBJS Br*)

Vikas Khanduja

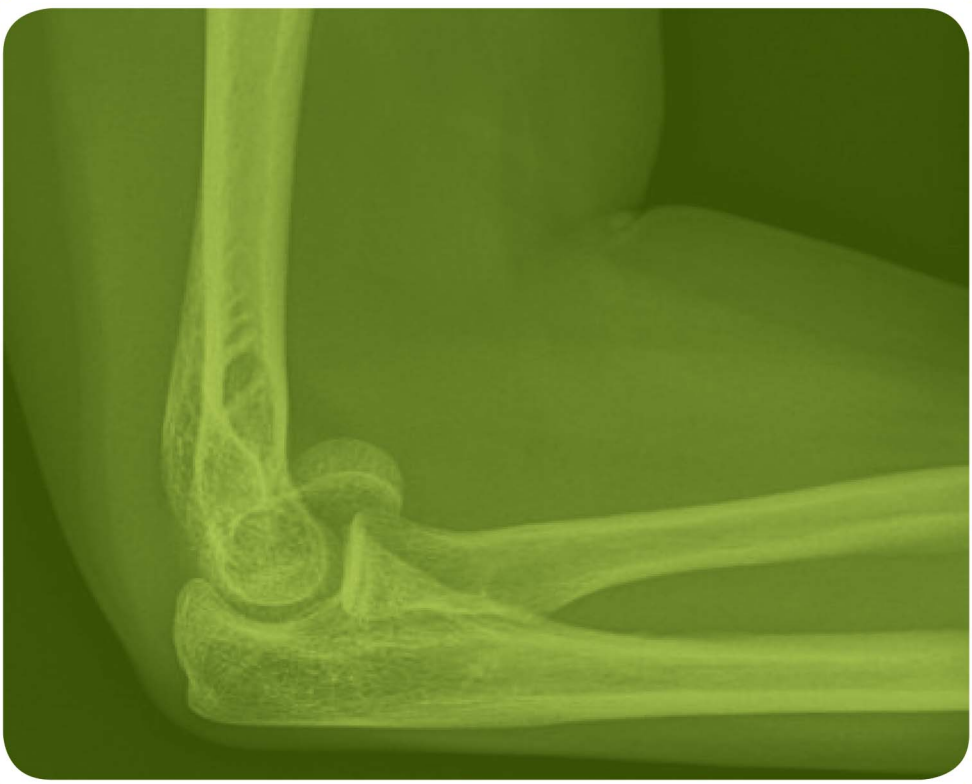

Contents

	Preface	v
	Acknowledgements	vi
	Contributors	viii
Chapter 1	SBA Questions	1
Chapter 2	SBA Answers	15
Chapter 3	Viva Questions: Adult pathology	31
Chapter 4	Viva Answers: Adult pathology	41
Chapter 5	Viva Questions: Trauma	61
Chapter 6	Viva Answers: Trauma	71
Chapter 7	Viva Questions: Hands	89
Chapter 8	Viva Answers: Hands	99
Chapter 9	Viva Questions: Children's orthopaedics	117
Chapter 10	Viva Answers: Children's orthopaedics	133
Chapter 11	Viva Questions: Basic science	145
Chapter 12	Viva Answers: Basic science	149
Index		169

Chapter 3

Viva Questions: Adult pathology

64. A 32-year-old woman presents with a history of pain and occasional clicking in her right hip. She gives a history of a skiing injury to her right groin 7 months earlier. This is her radiograph (Fig. 3.1).

A. Describe the abnormality on the radiograph in this patient with hip pain.

B. Describe the various angles that can be measured to document hip morphology.

C. What further investigations should be performed to investigate the hip pain?

D. What are the surgical options for management?

E. What are the classification systems for more severe cases?

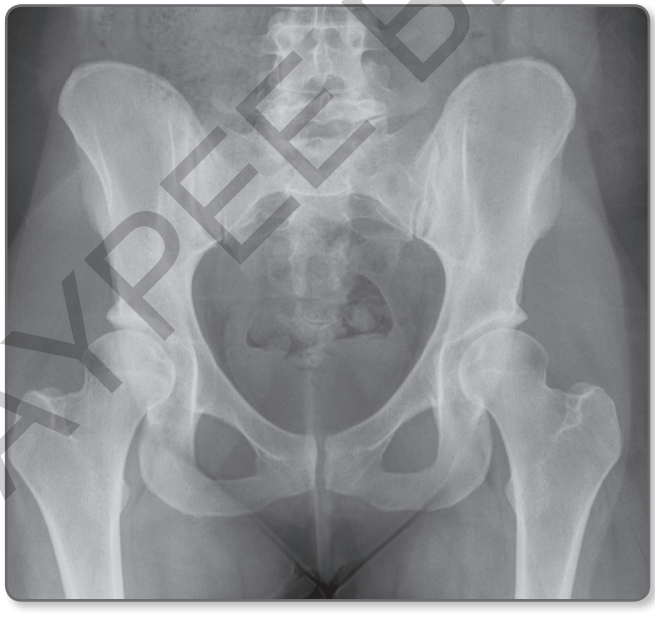

Figure 3.1

JAYPEE BROTHERS

65. A 58-year-old keen runner presents with a history of hip pain especially after running. This is the radiograph obtained in the clinic (Fig. 3.2).

A. Describe the abnormality on the radiograph.
B. Describe the likely presentation and mechanism of injury of this patient.
C. What further investigations should be performed?
D. What are the options for management?
E. Describe the blood supply to the femoral head.

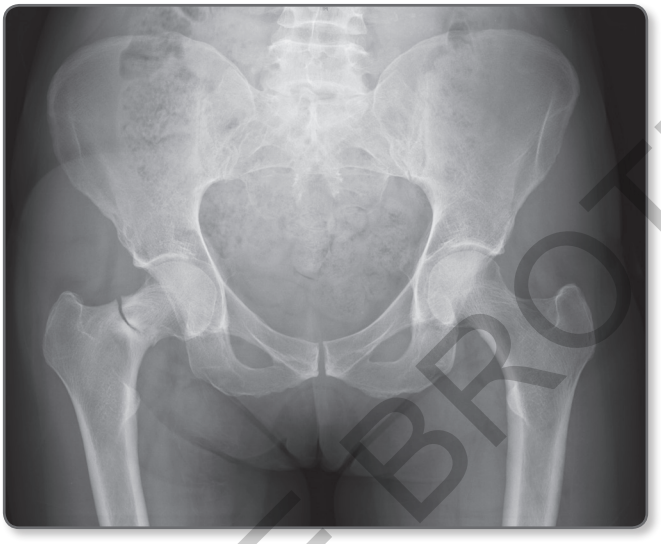

Figure 3.2

66. A 28-year-old man presents with pain in his chest and lower back. This is his radiograph (Fig. 3.3).

A. Describe the abnormality on the radiograph. What is your diagnosis?
B. How can we assess the severity of this condition?
C. What determines the prognosis?
D. What other investigation/s would you like to request and why?
E. Describe a classification system for this pathology.
F. What are the options for treatment?

JAYPEE BROTHERS

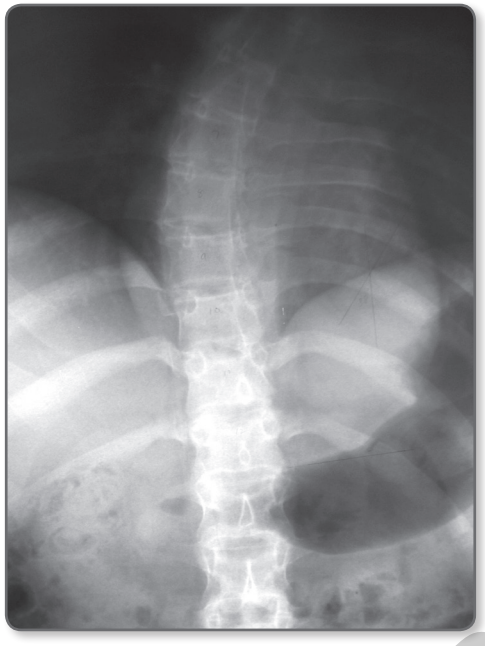

Figure 3.3

67. A. Describe the abnormalities on this radiograph (**Fig. 3.4**) taken one year after revision hip arthroplasty.

B. Describe the stages of the pathological process seen around the right hip.

C. What is the common classification used for this disease process?

D. What can be done to reduce the incidence of this process?

E. What are the consequences of the other abnormality?

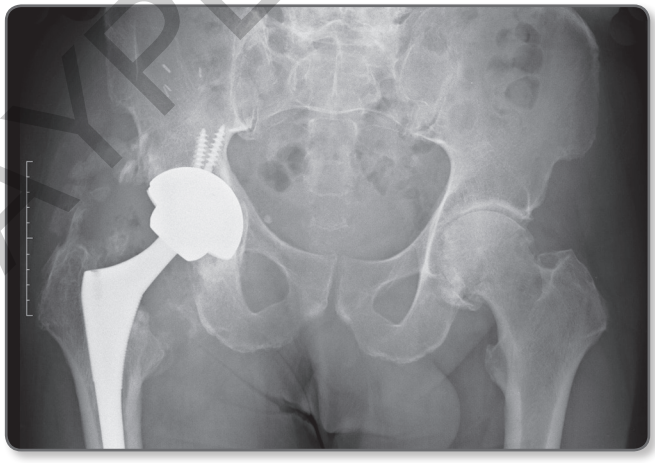

Figure 3.4

JAYPEE BROTHERS

68. A 68-year-old woman presents with a history of pain in the region of her thumb. This is her radiograph (Fig. 3.5).

A. Describe the radiograph. What is the diagnosis?

B. What are the causes of this condition?

C. What is the treatment for this condition?

D. What are the possible complications of surgical intervention in patients with this condition?



Figure 3.5

69. A 42-year-old female presents with a history of lower back and right leg pain. This is her radiograph (Fig. 3.6).

A. Describe the abnormalities seen in the radiograph.

B. What are the associations of this condition?

C. What is the approximate incidence of this abnormality in the general population?

D. What are the main surgical implications of this condition?

E. Describe the embryology of the spine.



Figure 3.6

JAYPEE BROTHERS

70. A 44-year-old microlight pilot sustained this injury (Fig. 3.7) in a crash landing.

A. Describe the radiograph.

B. There is an 8 cm clean laceration overlying the injury with a pale foot and no pulses. Describe your treatment strategy for this patient.

C. What is the common classification of talar fractures and what is the likely risk of nonunion in this case?

D. What is Hawkin's sign and what is the pathogenesis of this phenomenon?

E. Discuss the blood supply to the talus.

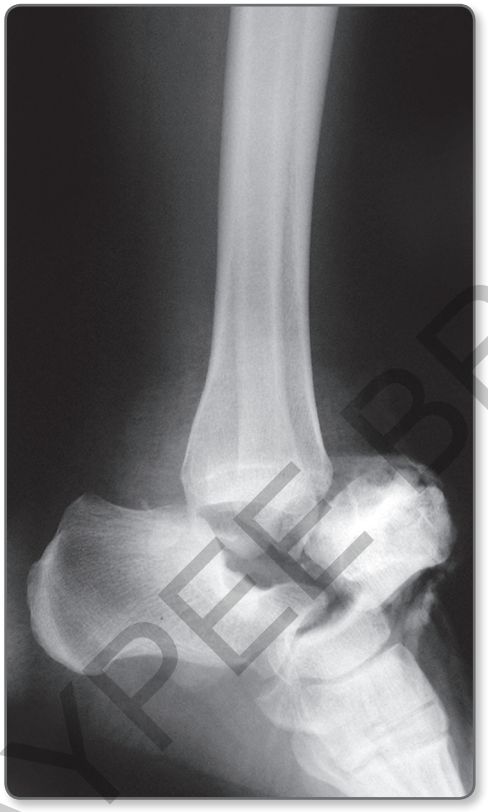

Figure 3.7

JAYPEE BROTHERS

71. A 72-year-old man presents with a long-standing history of knee pain, which is affecting his daily life and recreational activities. This is his radiograph (Fig. 3.8).

A. Describe the radiograph.

B. What other investigations are appropriate?

C. The patient has a significant fixed flexion deformity and fixed valgus. Assuming surgical intervention is appropriate discuss what form of knee replacement would be appropriate?

D. Describe a method of lateral ligament complex release and balancing the knee for valgus knees?

E. What is the importance of the possible medial joint line opening seen in the radiograph?



Figure 3.8

JAYPEE BROTHERS

72. A fit and well 65-year-old fell down stairs five years after a successful total hip replacement. He presents with pain in his right hip and an inability to bear weight. This is his radiograph (Fig. 3.9).

A. Describe the radiograph.

B. Describe a classification system for this injury that helps to guide management.

C. Where does this injury fit with the classification system you have described?

D. How would you treat this injury?

E. What is the expected outcome following treatment?

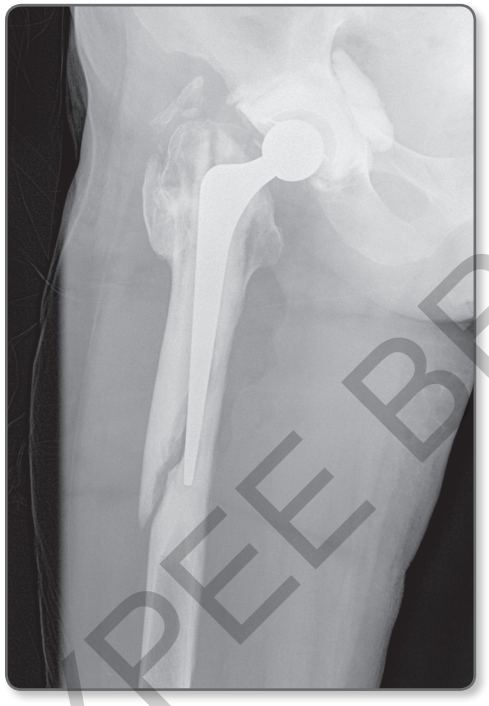

Figure 3.9

JAYPEE BROTHERS

73. A 75-year-old woman presents with acute pain in the right hip after attempting to tie her shoelaces. She had a total hip replacement 12 months previously. This is her radiograph (Fig. 3.10).

A. Describe the radiograph.

B. What factors influence the risk of dislocation following a total hip replacement?

C. What are the options for management of this patient?

D. What is the prognosis if the patient underwent a revision for this problem?

E. What are the options for treatment for recurrent dislocation following abductor insufficiency?

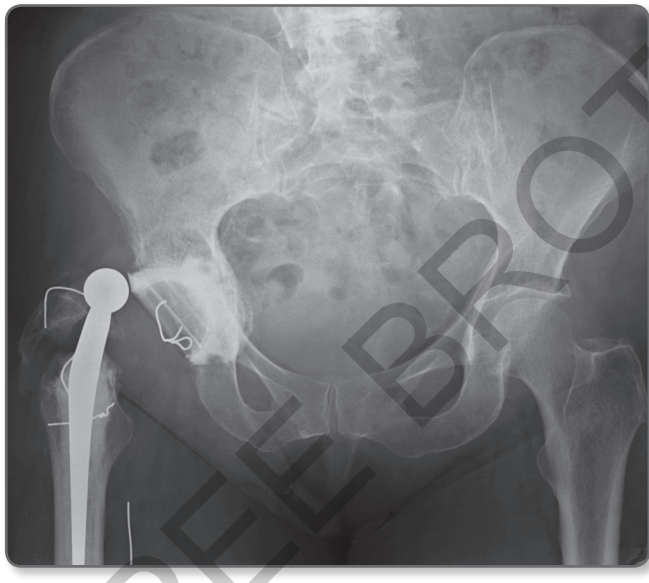

Figure 3.10

JAYPEE BROTHERS

74. A 54-year-old woman who underwent a mastectomy for breast cancer 12 months ago followed by adjuvant chemotherapy presents with a two week history of increasing mid-thoracic back pain. Over the last two days her legs have felt weak and she has struggled to walk. There is no history of urinary or faecal incontinence. She is otherwise fit and well.

This is the MRI of her spine (Fig. 3.11).

A. Describe the image.

B. What is the likely diagnosis and how would you manage this patient in the A&E department?

C. What are the options for definitive management?

D. What factors govern the decision making process?



Figure 3.11

JAYPEE BROTHERS

75. A 42-year-old woman presents with a history of anterior knee pain for the past three years. She has difficulty climbing up and down the stairs and also finds it fairly difficult to drive for long distances because of the pain. These are her radiographs (Figs 3.12a to c).

A. Describe the radiographs.

B. What is the diagnosis and what is the aetiology?

C. What are the options for management in this situation?

D. What factors govern the decision making process?

E. If you decided to go down the arthroplasty route, what prosthesis would you use and why?

F. How are patellofemoral joint replacements performing on the National Joint Registry in the UK?

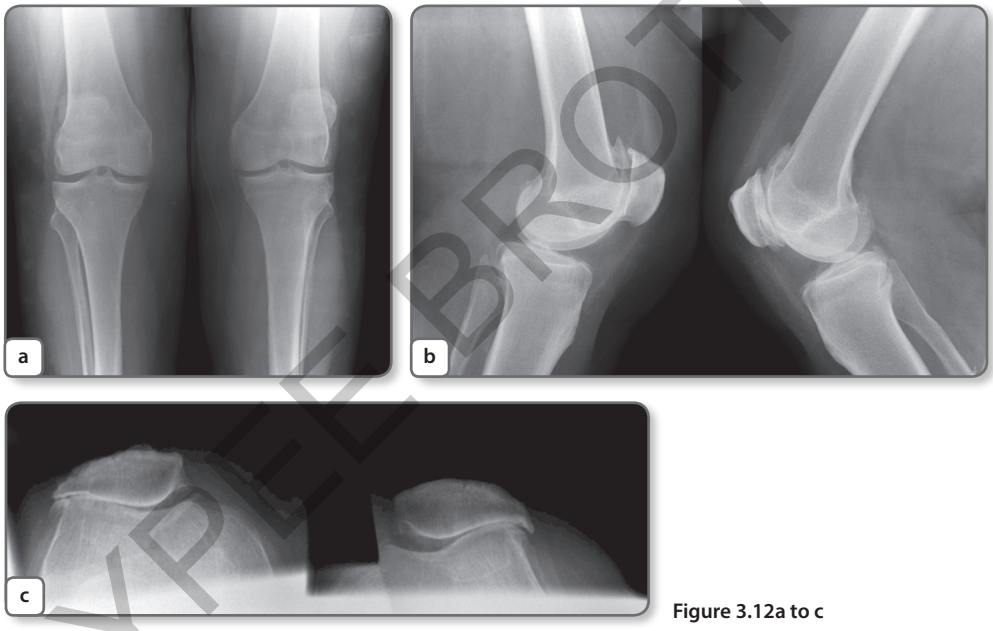

Figure 3.12a to c

JAYPEE BROTHERS

FRCS (Tr & Orth): MCQs and Clinical Cases

FRCS (Tr & Orth): MCQs and Clinical Cases offers a comprehensive set of over 120 practice questions and answers for trainees preparing for the FRCS Trauma & Orthopaedics exam, and similar exams in the Middle East, India, Australia, Africa and elsewhere. Chapters provide material in both the MCQ single best answer (SBA) and viva formats used in the exam.

Featuring a wealth of practice questions and fully descriptive answers containing explanatory tables and references, this book is an essential revision tool designed to maximise chances of exam success, whether in the UK or internationally.

- Content derived from the well-known 'Exam Corner' section of the leading international publication *The Bone & Joint Journal* (formerly known as *JBJS British Volume*), conveniently published together in one place for the first time
- Viva questions organised by the themes used in the exam – Adult pathology, Trauma, Hands, Children's orthopaedics, Basic science – enable you to focus on areas of weakness
- In-depth answers, with illustrations, help you consolidate knowledge and understand key concepts

JP medical publishers

THE BONE & JOINT JOURNAL

www.jpmedpub.com

ISBN 978-1-907816-93-2