Orthopaedics

Nicola Blucher
Katherine Butler
Simon Platt

pocket tutor



JP

Contents

Preface *v*
Dedications and acknowledgements *xi*

Chapter 1 General principles
1.1 Fractures and dislocations 1
1.2 Consent 6

Chapter 2 Clinical essentials
2.1 Common symptoms and how to take a history 11
2.2 Clinical signs and examination 21
2.3 Investigations 37
2.4 Management 45

Chapter 3 Spine
3.1 Clinical scenario 55
3.2 Anatomy 56
3.3 Examination 63
3.4 Cauda equina syndrome 67
3.5 Spinal fractures 70
3.6 Spinal cord injury 78
3.7 Spinal metastases 80
3.8 Other conditions 83

Chapter 4 Shoulder
4.1 Clinical scenario 85
4.2 Anatomy 87
4.3 Examination 96
4.4 Clavicular fractures 97
4.5 Acromioclavicular joint injuries 102
4.6 Scapular fractures 104
4.7 Shoulder dislocations 106
4.8 Rotator cuff injuries 111
4.9 Proximal humeral fractures 114
4.10 Humeral shaft fractures 118
4.11 Brachial plexus injuries 121
4.12 Biceps tendon injuries 123

Chapter 5 Elbow

5.1 Clinical scenario 125
5.2 Anatomy 127
5.3 Examination 128
5.4 Elbow dislocation 131
5.5 Supracondylar fractures (distal humeral fractures) 134
5.6 Olecranon fractures 137
5.7 Capitellum fractures 139
5.8 Radial head and neck fractures 141
5.9 Other conditions 144

Chapter 6 Wrist and hand

6.1 Clinical scenario 147
6.2 Anatomy 148
6.3 Examination 151
6.4 Mid-shaft fractures of the forearm 153
6.5 Distal radius fractures 156
6.6 Distal radioulnar joint injuries 160
6.7 Scaphoid fractures 162
6.8 Lunate and perilunate dislocations 166
6.9 Metacarpal fractures 170
6.10 Phalangeal fractures 173
6.11 Base-of-thumb fractures 176
6.12 Tendon (flexor and extensor) injuries of the wrist and hand 178
6.13 Flexor tendon sheath infection 182
6.14 Nail bed injuries 183
6.15 Paronychia 185
6.16 Other carpal fractures 185

Chapter 7 Hip

7.1 Clinical scenario 187
7.2 Anatomy 188
7.3 Examination 190
7.4 Hip dislocation 193
7.5 Neck of femur fractures 197
7.6 Femoral shaft fractures 209
7.7 Periprosthetic hip fractures 212
7.8 Osteoarthritis 214

7.9 Paget's disease of bone 217
7.10 Other conditions 218

Chapter 8 Pelvis
8.1 Clinical scenario 221
8.2 Anatomy 222
8.3 Examination 225
8.4 Pelvic fractures 226
8.5 Acetabular fractures 232
8.6 Sacral fractures 236
8.7 Coccygeal fractures 238

Chapter 9 Knee
9.1 Clinical scenario 239
9.2 Anatomy 240
9.3 Examination 246
9.4 Patellar fractures 248
9.5 Patellar dislocation 252
9.6 Tibial plateau fractures 253
9.7 Tibial shaft fractures 257
9.8 Distal femoral fractures 259
9.9 Quadriceps and patellar tendon injuries 261
9.10 Soft tissue injuries 263
9.11 Osteoarthritis 265
9.12 Knee dislocation 267

Chapter 10 Foot and ankle
10.1 Clinical scenario 271
10.2 Anatomy 272
10.3 Examination 274
10.4 Ankle fractures 279
10.5 Pilon fractures 285
10.6 Ankle sprains 289
10.7 Talus fractures 291
10.8 Calcaneal fractures 294
10.9 Achilles tendon ruptures 297
10.10 Lisfranc (tarsometatarsal) injuries 300
10.11 Metatarsal fractures 303
10.12 Phalangeal fractures 308
10.13 Other conditions 310

Chapter 11 Paediatric orthopaedics
11.1 Clinical scenario 313
11.2 Examination 315
11.3 Growth plate fractures 315
11.4 Supracondylar humeral fractures 319
11.5 Condylar fractures 322
11.6 Radial head and neck fractures 327
11.7 Radial head subluxation 329
11.8 Hip problems: slipped upper femoral epiphysis 330
11.9 Hip problems: Perthes' disease 333
11.10 Hip problems: transient synovitis 334
11.11 Femoral shaft fractures 335
11.12 Tibial fractures 338
11.13 Non-accidental injuries 339
11.14 Osteogenesis imperfecta 341

Chapter 12 Orthopaedic trauma
12.1 Clinical scenario 343
12.2 Advanced Trauma Life Support 345
12.3 Open fractures 346
12.4 Compartment syndrome 349
12.5 Vascular injuries 352

Chapter 13 Orthopaedic infections and other soft tissue problems
13.1 Clinical scenario 355
13.2 Septic arthritis 356
13.3 Osteomyelitis 358
13.4 Gangrene 360
13.5 Necrotising fasciitis 362
13.6 Postoperative wound infections 363
13.7 Cellulitis 364
13.8 Abscesses 365
13.9 Foot ulcers 367
13.10 Foreign bodies 369
13.11 Bite injuries 371
13.12 Neuropathic arthropathy 372

Index *375*

chapter 3

Spine

The spine provides structural support for the body and protection for the spinal cord and nerves, and allows a degree of mobility in several planes. At each vertebral level, paired spinal nerves exit the central nervous system; at this point they are especially vulnerable to compression. Furthermore, the dynamic, stress-bearing nature of the back and spine means that it is a common site of pain resulting from mechanical or neural injury.

3.1 Clinical scenario

Back pain

Background

A 58-year-old woman has had intermittent back pain over the past few years. While looking after her young grandson at the weekend, she tried to lift him but had sudden, severe lower lumbar back pain and could hardly move afterwards. Since then, she had been resting at home and taking painkillers. However, the pain has worsened, and she has had some weakness and numbness in her right foot as well as difficulty passing urine, so she has presented at the emergency department.

History

The patient has a past medical history of hypertension and long-standing back pain, for which she takes co-codamol as required. She lives with her husband; they are both retired but live independently, and her medical conditions do not limit her activities of daily living. She does not require walking aids.

Examination

Inspection finds normal alignment and no deformity. The pain means that the patient has difficulty walking. She has tenderness over her lower lumbar spine, and because of the pain is unable to fully flex or extend her back. On neurological examination, she has normal tone in both lower limbs.

The straight leg raise test gives a positive result on the right. Power is decreased on the right in ankle dorsiflexion and the long toe extensors. Sensation is decreased on the dorsum of the foot and the medial malleolus. An ankle reflex cannot be elicited, and the results of plantar reflex testing are equivocal.

On rectal examination, anal tone is decreased. A bladder scan confirms that the patient has urinary retention.

Differential diagnosis

Possible causes of the patient's symptoms and signs are:

- cauda equina syndrome
- conus medullaris infarction
- prolapsed vertebral disc
- spinal stenosis
- vascular claudication
- exacerbation of chronic degenerative disc disease
- musculoskeletal back pain

Given the abnormal neurology and urinary retention, cauda equina syndrome is the most likely diagnosis.

Clinical insight

The straight leg raise test confirms irritation of the lumbar nerve root when pain is elicited in the affected leg by passive elevation (usually by 30–60°) with the knee extended. Lower the leg until the pain passes. Passively dorsiflex the ankle. If the pain is reproduced, this is Lasègue's sign.

Investigations

An urgent MRI scan is requested to confirm any nerve root compression and its cause, including disc pathology, tumour or infection.

3.2 Anatomy

The spine comprises 33 vertebrae and associated ligaments, fibrocartilaginous intervertebral discs and facet joints. It is divided into five regions (**Figure 3.1**):

- the cervical region (7 vertebrae)
- the thoracic region (12 vertebrae)
- the lumbar region (5 vertebrae)
- the sacrum (5 fused vertebrae)
- the coccyx (4 fused vertebrae)

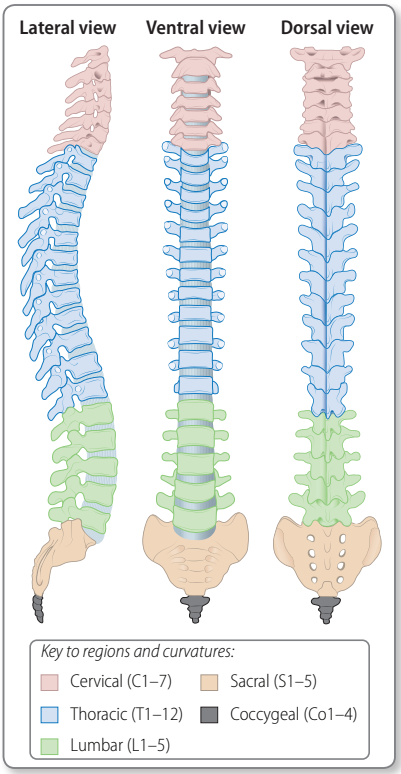

Figure 3.1 Regions of the spine.

The normal spine is curved in the sagittal plane. The cervical and lumbar regions curve anteriorly (lordosis), and the thoracic and sacral regions curve posteriorly (kyphosis).

Spinal columns

The spine is described in terms of three columns: anterior, middle and posterior.

The anterior column comprises:

- the anterior longitudinal ligament
- the anterior annular ligament
- the anterior half of the vertebral body

The middle column consists of:
- the posterior longitudinal ligament
- the posterior annular ligament
- the posterior half of the vertebral body

The posterior column comprises:
- the pedicles
- the spinous process
- the posterior ligaments
- the neural arch

Vertebrae

Individual vertebrae consist of an anterior part, the vertebral body, and a posterior part, the vertebral arch. The vertebral arch is made up of pedicles, laminae, transverse processes and a spinous process (**Figure 3.2**). The vertebral body and vertebral arch form the vertebral foramen.

Vertebrae differ in shape and size at various levels. For example, all 12 thoracic vertebrae have demifacets that articulate with the corresponding ribs, and their spinous processes are long and slope downwards, and lumbar vertebrae have large, strong vertebral bodies.

Intervertebral discs

Intervertebral discs form fibrocartilaginous joints between adjacent vertebral bodies. Each disc comprises a jelly-like inner

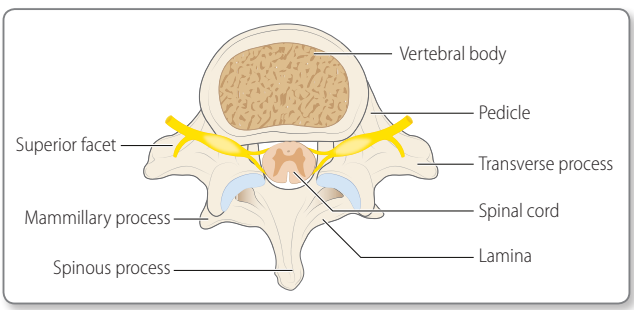

Figure 3.2 Cross-section of the spine.

nucleus pulposus and an outer fibrous ring called the annulus fibrosus. The disc acts as a shock absorber and also distributes pressure evenly to adjacent vertebrae under a compressive force. Superior and inferior facet joints on each vertebra increase stability and restrict movement.

Ligaments

Ligaments pass between the spinous processes and laminae of adjacent vertebrae (**Figure 3.3**). Two adjacent vertebral discs and their associated ligamentous structures form a functional spinal unit called a motion segment.

Spinal cord

The spinal cord passes through the spinal canal, the space formed by successive vertebral foramina. It is the main pathway connecting the brain to the peripheral nervous system. It transmits motor signals from, and conveys sensory information to the brain. It also contains the neural circuits responsible for reflexes, i.e. actions that occur independently of the brain. The spinal cord contains white matter peripherally and grey

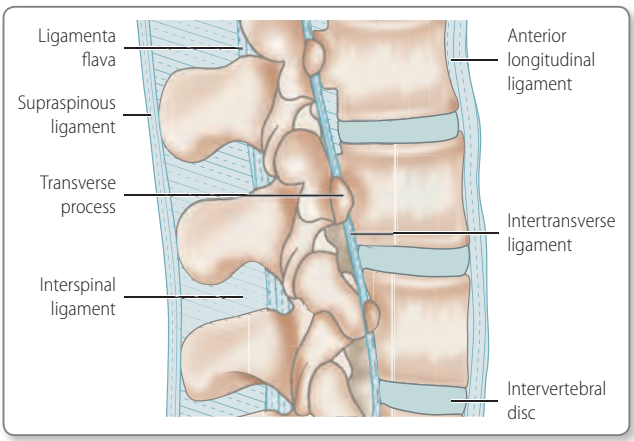

Figure 3.3 Ligaments of the spine.

matter medially (**Figure 3.4**). The white matter is neural tracts of sensory and motor neurones. The grey matter is neuronal cell bodies in a butterfly-shape around the central canal.

Meninges

The spinal cord and spinal nerve roots are covered by meninges within the spinal canal and intervertebral foramina. From superficial to deep, they are:

- the epidural space
- the dura mater
- the subdural space
- the arachnoid mater
- the subarachnoid space
- the pia mater

Levels of the spinal cord

The adult spinal cord extends from the foramen magnum and terminates as the medullary cone (conus medullaris) at vertebral level L1–L2 (**Figure 3.5**). The anterior and posterior nerve roots at each spinal level join one another and exit the intervertebral foramina, forming spinal nerves from C1 to S5; they are mixed sensory and motor. C1–C7 exit above the associated vertebrae, C8 exits below the C7 vertebrae and T1–S5 exit below their respective vertebrae.

The spinal cord normally ends at L1, so lower nerve roots course some distance before exiting the intervertebral foramina. This is relevant when considering the consequences of a spinal cord injury at a given level. The lower spinal nerves form the cauda equina (Latin, 'horse's tail'). The cauda equina ends at S2, with termination of the dural sac.

Sensory and motor tracts

Neural tracts ascend and descend the spinal cord, carrying neural signals to and from the brain. Generally, descending tracts carry motor information and ascending tracts carry sensory information (**Figure 3.4**).

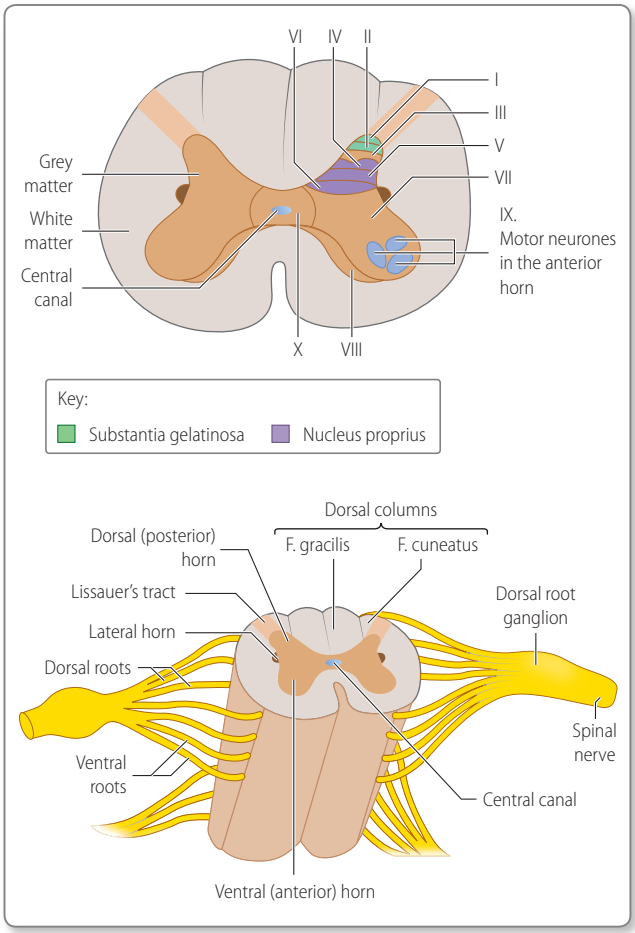

Figure 3.4 Internal anatomy of the spinal cord. The grey matter comprises three 'horns': the dorsal (posterior) horn carrying sensory fibres, the ventral (anterior) horn carrying motor fibres and the lateral horn carrying fibres of the sympathetic division of the autonomic nervous system; the grey matter is divided into laminae I–X.

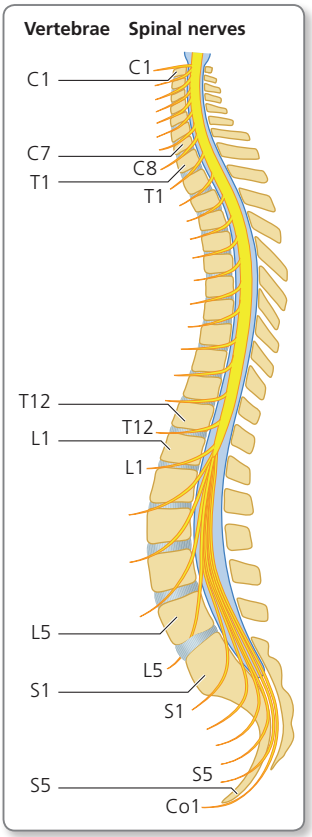

Figure 3.5 Levels of the spinal cord.

Sensory information is carried by sensory peripheral nerves. Each of these nerves is a projection of a neurone with a cell body in one of the dorsal root ganglia, clusters of neuronal cell bodies outside the spinal cord. These neurones synapse in the cord, decussate and ascend, synapsing again in the thalamus before terminating in the sensory cortex.

Motor neurones also decussate in the spinal cord. Their cell bodies are contained within the ventral grey matter of the cord. Peripheral nerves project from these neurones to innervate

muscle on the side of the body contralateral to the cortex initiating the signal.

Vascular supply

The spinal cord is supplied by three arteries that run along its length: the anterior spinal artery and the right and left posterior spinal arteries. These arise in the brain from the intracranial part of the vertebral artery. They are reinforced serially by the spinal branches from the ascending cervical artery, the cervical part of the vertebral artery, the posterior intercostal arteries and the lumbar arteries.

Surface anatomy

Several features of the spine can be palpated via the skin and are useful anatomical landmarks in examinations and procedures (**Figures 3.6 and 3.7**). The tips of the spinous processes are palpable within the midline groove of the back, especially during flexion.

The spinous processes and the spaces between them are used to mark the levels of underlying structures or planes and thereby help guide procedures for spinal anaesthesia. For example:

- C7 is the most prominent spinous process on the inferior neck
- T12 is at the medial end of the 12th rib
- L2 marks the inferior limit of the spinal cord in adults
- L4 marks the highest point of the iliac crest

Transverse processes mark the positions of spinal nerves. Therefore they are useful landmarks during procedures such as regional nerve or plexus anaesthesia.

3.3 Examination

Key signs

Key signs to assess for include gait abnormality, deformity, tenderness and abnormal neurology.

Examination sequence

Examination follows a system of 'look, feel and move' and a thorough neurological examination of the upper and lower limbs.

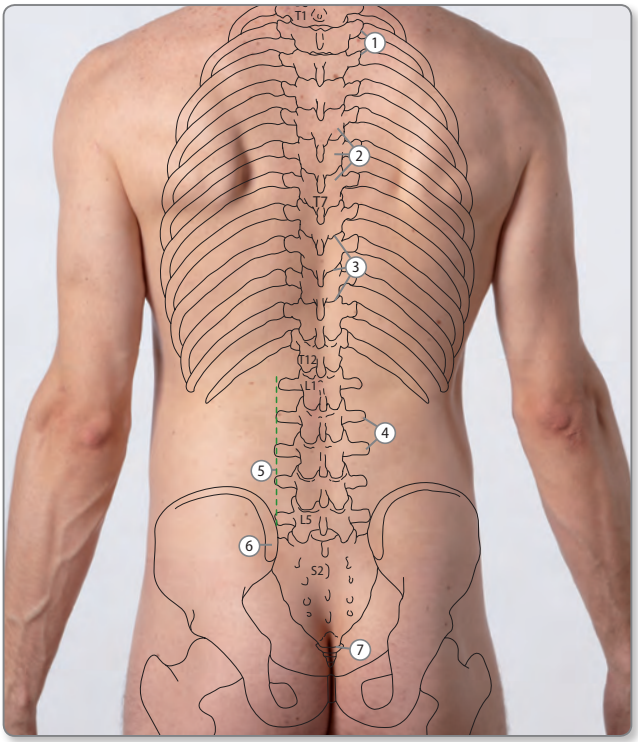

Figure 3.6 Posterior view of the vertebra and intervertebral joints. (1) Costotransverse joints, (2) vertebral laminae, (3) facet/zygapophyseal joints, (4) transverse processes, (5) vertical plane aligned with the posterior superior iliac spine landmarks the lumbar vertebral transverse processes, (6) posterior superior iliac spine, (7) sacrococcygeal joint.

Look

- Observe the overall alignment
- Is the patient's posture balanced?
- Assess the curvature of the spine; is it normal? Is there evidence of scoliosis or kyphosis?
- Are there any scars indicating previous spinal surgery?

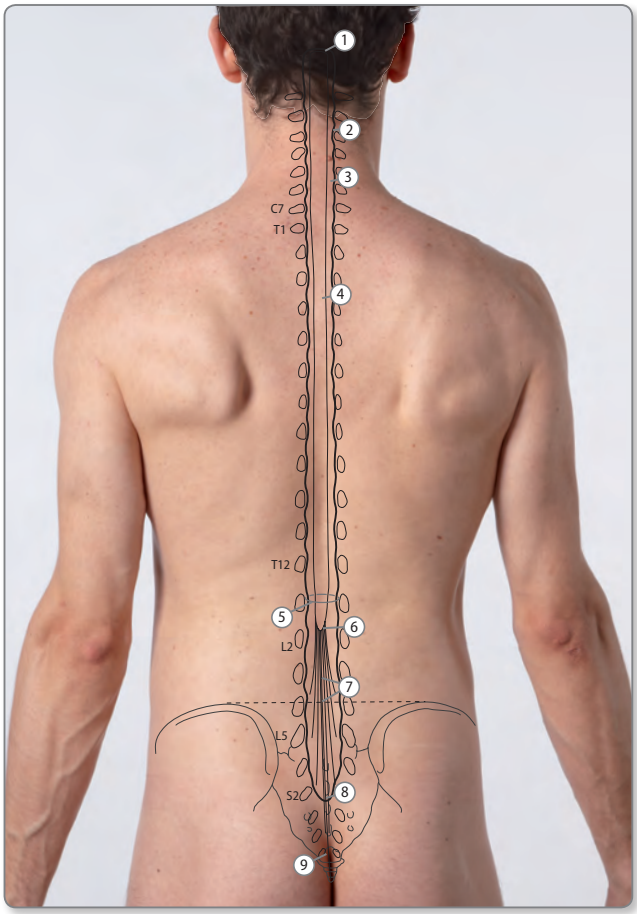

Figure 3.7 Meninges, spinal cord and spinal nerves within the vertebral canal (cutaway view). (1) Foramen magnum, (2) dura mater lined internally with arachnoid mater, (3) subarachnoid space filled with cerebrospinal fluid, (4) spinal cord covered in pia mater, (5) vertebral canal containing spinal cord and nerves within meningeal coverings, (6) conus medullaris (termination of spinal cord), (7) cauda equina, (8) termination of subarachnoid space, (9) sacral hiatus.

Clinical insight

After spinal trauma patients are immobilised and thoroughly examined. They are fully exposed to assess for abrasions, bruising or wounds, then 'logrolled' (manoeuvred without moving the spinal column) to assess for bruising, abrasions, spinal tenderness and deformity, and to perform a rectal examination. A neurological examination is performed and a sensory examination completed to determine whether the injury is in the anterior or dorsal column.

Clinical insight

The bulbocavernosus reflex is always checked; it is contraction of the anal sphincter in response to stimulation of the trigone of the bladder. This is done with a squeeze on the glans of the penis, a tap on the mons pubis or a pull on a urethral catheter. Absence of this reflex indicates spinal shock.

Feel

- Palpate along the length of the spine for bony tenderness over the spinous processes
- Palpate the sacroiliac joints
- Is there any muscular tenderness paraspinally?

Move

- Check movements of the cervical spine by asking the patient to flex and extend forwards and backwards, flex laterally and rotate (**Figure 3.8)**
- Check rotation of the thoracic spine (**Figure 3.9)**
- Ask the patient to flex and extend the lumbar spine; do they have pain or limited movement?
- Check lateral bend by asking the patient to run their hand down the outside of each leg
- Check rotation of lumbar spine

Function

- Is the patient's gait normal? Do they lean forwards (indicating spinal stenosis) or have a wide-based gait (indicating myelopathy)?
- Conduct a full neurological examination of the upper and lower limbs; test motor and sensory responses and reflexes; and carry out rectal examination (see page 36)

pocket tutor

Orthopaedics

pocket tutor Orthopaedics is the perfect companion for medical students, junior doctors, primary care practitioners and anyone seeking to improve their working knowledge of orthopaedic conditions.

- ✔ **Clinical essentials chapter** summarises examination techniques, investigative tools and practical clinical skills
- ✔ **Clearly labelled, high-quality image**s teach you to identify anatomical landmarks and clinical signs
- ✔ **Concise disease descriptions and clinical scenarios** help you identify and manage conditions commonly seen in practice

Make every spare moment count with the **pocket tutor** series of guides to clinical investigations, skills and specialties. From reminders of key first principles to tips on how to think like an expert, the step-by-step approach and handy pocket size help you reinforce knowledge fast: on attachment, in transit, during tutorials or before exams.

JP medical publishers

www.jpmedpub.com

ISBN 978-1-907816-99-4

9 781907 816994