

DIAGNOSTIC DERMATOPATHOLOGY

A GUIDE TO ANCILLARY TESTS BEYOND THE H&E

Gregory A Hosler

Contents

Foreword v
Preface vii
Contributors xi
Acknowledgements xii
Dedication xii

Section 1: Introduction

1 History of dermatopathology 1
Gregory A. Hosler

2 Hematoxylin and eosin 23
Gregory A. Hosler

Section 2: Special stains

3 Special stains: background 29
Ryan W. Hick

4 Applications in dermatopathology 47
Ryan W. Hick

Section 3: Immunohistochemistry

5 Immunohistochemistry: background 55
Marc R. Lewin, Robert Oliai

6 Immunohistochemical markers 61
Marc R. Lewin

7 Common immunohistochemical panels 103
Marc R. Lewin

Section 4: Point of care testing

8 Dermatological point of care tests 107
Travis Vandergriff

Section 5: Immunofluorescence

9 Immunofluorescence: principles **121**
Robert M. Law

10 Immunofluorescence: applications in dermatopathology **135**
Robert M. Law

Section 6: Electron microscopy

11 Electron microscopy: background **151**
Matthew Lewin

12 Electron microscopy: applications **155**
Gregory A. Hosler

Section 7: Molecular testing

13 In situ hybridization (non-FISH) **171**
Pamela M. Aubert

14 Fluorescence in situ hybridization **183**
Pamela M. Aubert

15 T/B gene rearrangement assays **205**
Gregory A. Hosler

16 PCR, sequencing, and gene expression profiling **233**
Gregory A. Hosler

Section 8: Conclusion

17 Final thoughts **247**
Gregory A. Hosler

Index **253**

Contributors

Pamela M Aubert MD
Dermatopathologist
Department of Dermatology
Panorama City Medical Center
Panorama City, CA
USA

Ryan W Hick MD
Dermatopathologist
Division of Dermatopathology, ProPath
Clinical Assistant Professor of Dermatology
The University of Texas Southwestern
Dallas, TX
USA

Gregory A Hosler MD PhD
Dermatopathologist
Division of Dermatopathology and Molecular Diagnostics, ProPath
Clinical Associate Professor of Dermatology and Pathology
The University of Texas Southwestern
Dallas, TX
USA

Robert M Law MD
Dermatopathologist
Division of Dermatopathology, ProPath
Clinical Assistant Professor of Dermatology and Pathology
The University of Texas Southwestern
Dallas, TX
USA

Marc R Lewin MD
Dermatopathologist
Division of Dermatopathology, ProPath
Clinical Assistant Professor of Dermatology
The University of Texas Southwestern
Dallas, TX
USA

Matthew Lewin MD
Surgical Pathologist
Division of Gastrointestinal and Renal Pathology, ProPath
Dallas, TX
USA

Bahram Robert Oliai MD
Surgical Pathologist
Division of Immunohistochemistry, ProPath
Dallas, TX
USA

Travis Vandergriff MD
Dermatopathologist and Assistant Professor of Dermatology
The University of Texas Southwestern
Dallas, TX
USA

3 Special stains: background

Ryan W. Hick

For over a century, pathologists have relied on routine hematoxylin and eosin (H&E) staining in the primary interpretation of tissue specimens. For just as long a variety of alternative staining methods, also known as 'special stains' in the jargon of histotechnologists and pathologists, have been used to demonstrate cell structure, foreign organisms, and other tissue structures. In many instances, these special stains depend upon affinities of dyes to particular macromolecules within tissue sections. Other special stains rely on chemical reactions to produce a visible color change against a background stain. With the advent of relatively newer immunohistochemical techniques with high specificity and sensitivity, some of these special stains have fallen by the wayside (i.e. consider the detection of *Treponema pallidum* by immunohistochemistry versus the Warthin–Starry silver stain). However, many of these older special stains remain comparatively inexpensive, sensitive and specific methods to assist the process of making a diagnosis. This is especially true in cases of infectious diseases and deposition disorders.

An understanding of the basic biochemical underpinnings of these special stain techniques will assist the aspiring or already experienced dermatopathologist in deciding which stains to use, in knowing the optimal circumstances for their use, and in recognizing the shortcomings of some stains or the possible sources of error in interpretation. This chapter places the development of special stains in a historical context relative to the development of other stains and ancillary tissue techniques.

Carbohydrates

Periodic acid–Schiff

The first histologic application of the periodic acid–Schiff (PAS) technique was published in 1946 by McManus (McManus, 1946; Titford, 2009). This method for detecting various carbohydrates and glycoproteins in histologic sections has become one of the most commonly used complements to routine H&E staining in the anatomic pathology setting. It is most routinely used by dermatopathologists as an adjunct to H&E for the detection of fungal organisms; however, it has other important, albeit less frequently utilized, applications.

The PAS technique relies upon a two-step process that allows for detection of carbohydrates composed of monosaccharides with 1,2-glycol bonds. In the first step, periodic acid (metaperiodic acid [HIO_4] or orthoperiodic acid [H_4IO_5]) cleaves the carbon bond between 1,2-glycols in an oxidation reaction that results in the formation of two aldehyde moieties (**Figure 3.1**). While other oxidants may be used, they may result in further oxidation of aldehydes to carboxylic acids, limiting the effectiveness of the second step in the reaction (Suvarna, 2013).

The second step relies upon a technique developed in the late 19th century by German-Italian chemist Hugo Schiff for the detection of aldehydes. This step involves the preparation of Schiff reagent from the magenta-hued basic fuchsine dye (a triarylmethane dye also referred to as pararosanaline) and aqueous sulfurous acid. The conjugation of a sulfonic acid group with the central carbon atom of the basic fuchsine results in loss of the dye's color in solution. However, when Schiff reagent is applied to tissue sections that have been treated with periodic acid, the highly concentrated aldehyde groups of structures rich in carbohydrates and proteoglycans remove the sulfonate group from basic fuchsine and restore the quinoid structure of the dye as well as its rich magenta color within those target tissue structures (**Figure 3.2**). Periodic acid oxidizes other alcohol groups including the terminal

JAYPEE BROTHERS

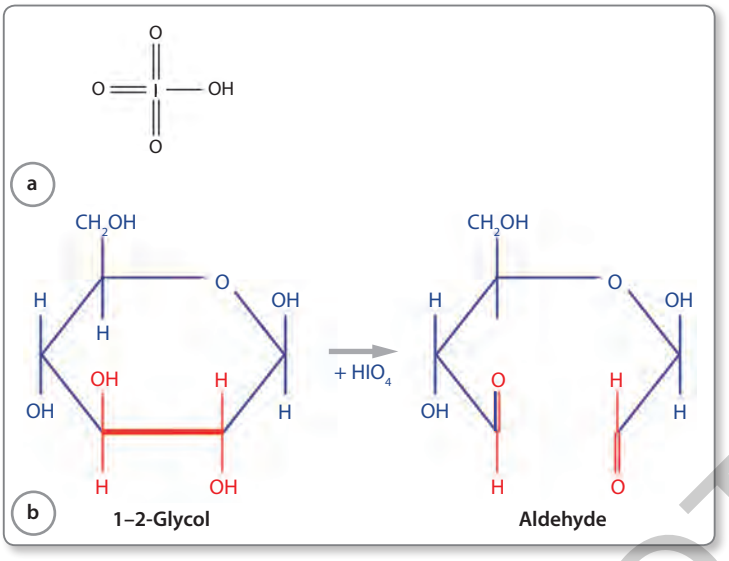

Figure 3.1 Periodic acid conversion of 1,2-glycol bonds in polysaccharide monomers to aldehyde moieites. (a) Periodic acid. (b) Periodic acid converts the 1,2-glycol bond within the monosaccharide to two aldehyde moieties.

amino alcohols of serine and threonine. Given the relatively low concentrations of these groups in tissue, the reactions are mostly insignificant (Suvarna, 2013).

The PAS stain is most frequently used by dermatopathologists to exclude the presence of fungal organisms. The stain targets the polysaccharide mannan in the cell wall of yeast, dermatophytes, and other fungi. The PAS stain also highlights the polysaccharide molecule glycogen, which often appears in mucosal epithelium, inflamed reactive epidermis, clear cell acanthoma, eccrine glands, and normal outer root sheath or tumors with outer root sheath differentiation (**Table 3.1**). Pretreatment with the enzyme diastase removes glycogen but the use of diastase may be more useful in cases where PAS is employed to detect neutral mucins in simple epithelia, and differentiation from glycogen is required. This application is not routine in the interpretation of skin specimens. Sulfated mucins and acid mucins, such as hyaluronic acid, are PAS-negative. The PAS stain is sometimes used to evaluate thickening of the basement membrane zone in cases of presumed connective tissue disease, such as discoid lupus erythematosus, as well as in conditions that cause thickening of the vascular basement membrane, such as porphyria cutanea tarda, lipoid proteinosis and erythropoietic protoporphyria. The thickened basement membrane zone is associated with increased numbers of glycoproteins, which can be detected with the PAS technique.

Hematoxylin and Fast Green FCF are counterstains most frequently used in conjunction with the PAS technique to provide a contrasting background. The former is useful for highlighting nuclear features of the surrounding tissue, whereas the latter may provide better contrast with some targets of the reaction, such as fungal organisms (**Figure 3.3**).

Alcian blue

Alcian blue was used as a textile dye well before its application as a histologic stain. The name 'alcian' likely represents a corruption of the chemical name phthalocyanine (who wants to be adding extra 'phth' at the beginning of words anyway?). The dye is a large molecule composed of a phthalocyanine ring with four linked isothiouronium groups. There is a central copper ion that imbues the blue color observed on microscopy (**Figure 3.4**). The isothiouronium groups are cationic bases that can bond with polyanionic groups of sulfated and non-sulfated mucins (Suvarna, 2013). For most skin

JAYPEE BROTHERS

applications, skin specimens are treated with alcian blue at pH 2.5 because the usual target substance is hyaluronic acid. Alcian blue fails to stain hyaluronic acid when used at pH 1.0.

The combination alcian blue-PAS (AB-PAS) stain is used most commonly in gastrointestinal pathology to differentially stain acid and neutral mucins, with alcian blue staining the former

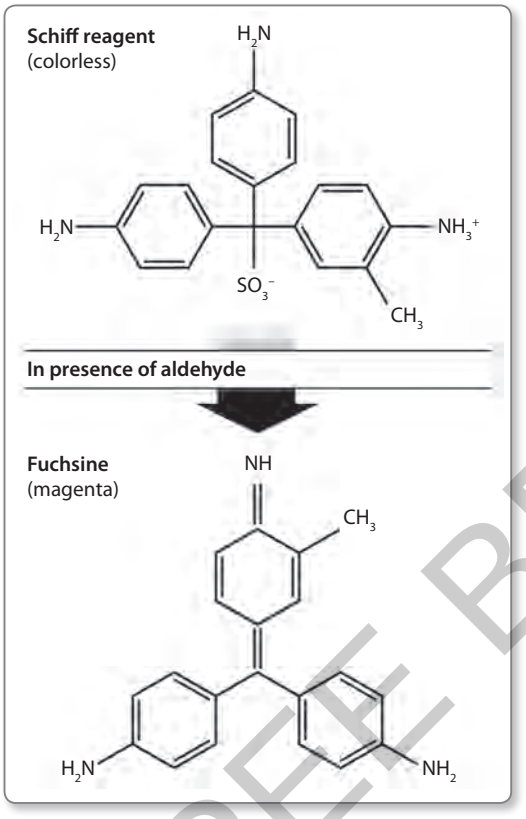

Figure 3.2 Conversion of Schiff reagent to basic fuchsine. Upon exposure to the aldehyde moieties of polysaccharides previously treated with periodic acid, Schiff reagent is converted back to magenta-hued basic fuchsine.

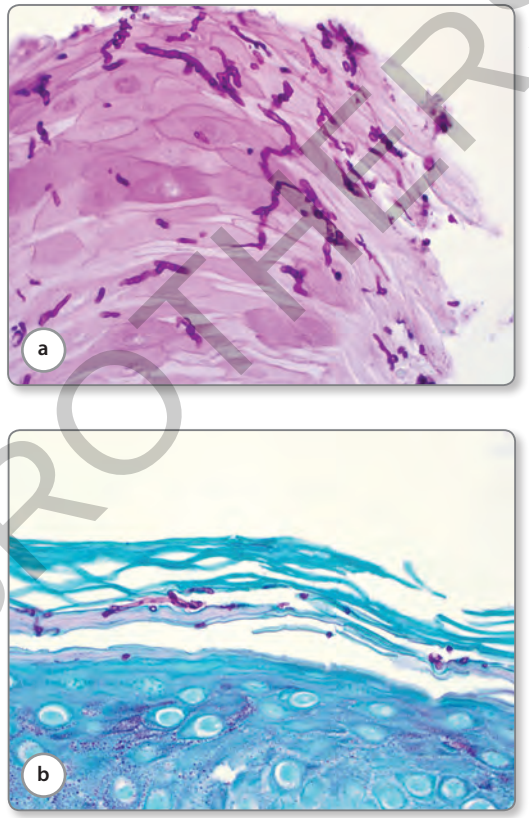

Figure 3.3 PAS stain for fungal organisms. (a) PAS stain of onychomycosis with hematoxylin counterstain (PAS 400×). (b) PAS stain of dermatophytosis with Green FCF counterstain (PAS-G, 400×). Melanin is often accentuated on PAS stain with either countertstain.

Table 3.1 Special stains for carbohydrates and mucopolysaccharides

	PAS	PAS-D	Alcian blue 2.5	Mucicarmine	Colloidal iron
Glycogen	+	-	-	-	-
Hyaluronic acid	-	-	+	-	+
Neutral mucin	+	+	-	-	-
Sialomucin	+/-	+/-	+	+	+
Sulfomucin	-	-	+	+	+

PAS, Periodic acid–Schiff; PAS-D, Periodic acid–Schiff following diastase

JAYPEE BROTHERS

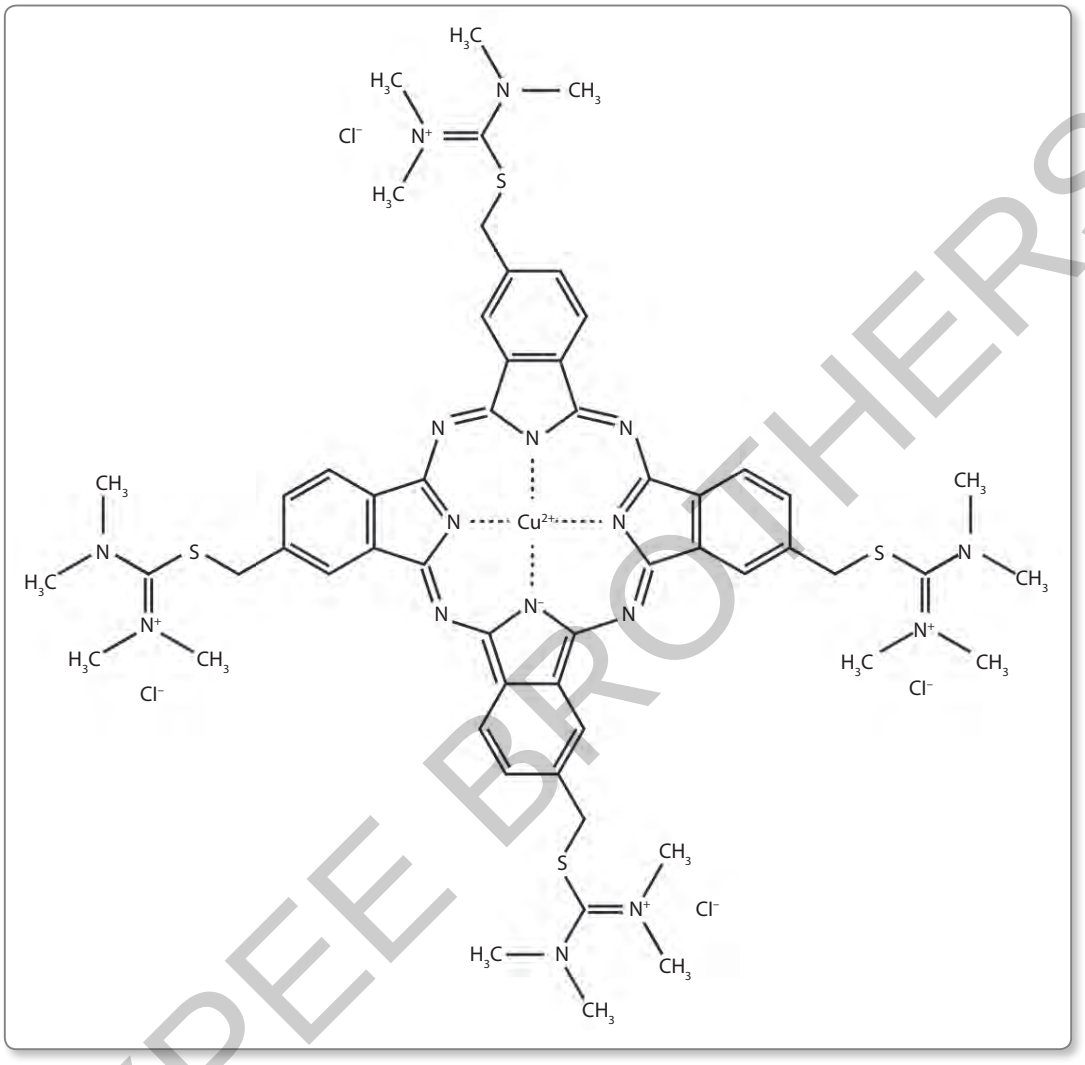

Figure 3.4 Alcian blue dye. The copper molecule at the center of the phthalocyanine ring imbues a blue color to the dye, which deposits in areas rich in sulfated, and acid mucopolysaccharides.

and PAS staining the latter. This combination may also be useful in cutaneous specimens. In cases of suspected connective tissue disease, AB-PAS may demonstrate increased dermal hyaluronic acid deposition and basement membrane zone thickening. The stain can also differentially highlight the mucinous capsule of *Cryptococcus neoformans* (blue) and the yeast form (magenta).

Colloidal iron

Hale published the initial application of a colloidal iron method for the detection of acid mucopolysaccharides in 1946 (Hale, 1946). The technique involves a two-step process. Firstly, a colloidal suspension of ferric oxide is applied to tissue sections allowing ferric ions (Fe^{3+}) to conjugate with carboxyl and sulfate

JAYPEE BROTHERS

anionic groups on acid mucopolysaccharides and proteoglycans. Secondly, the Perls reaction of potassium ferrocyanide with the tissue now infused with an excess of ferric ions is carried out, forming ferric ferrocyanide, a bright blue stain known as Prussian blue (**Figure 3.5**).

In the skin, this reaction primarily highlights hyaluronic acid, comprising the ground substance of the dermis. The papillary dermis, normally rich in acid mucins, serves as an internal positive control to which the amount of staining between collagenic bundles in the dermis or within the follicular epithelium can be compared. Perifollicular and perivascular zones, similar to the papillary dermis, are rich in hyaluronic acid and should not be confused for 'positive' staining. The presence of excess interstitial hyaluronic acid deposits between collagenic fibers in the dermis is considered abnormal and indicative of a pathologic process. Increased mucin deposition is also abnormal with the epidermis and adnexal epithelium (**Figure 3.6**). The staining pattern must be considered in the context of the tissue reaction pattern. In the setting of an interface dermatitis, increased interstitial dermal mucin supports a differential diagnosis that includes a connective tissue disease process. Increased interstitial hyaluronic acid deposition must be distinguished from solar elastosis in anatomic sites chronically exposed to ultraviolet radiation. Hyaluronic acid, due to dehydration during tissue processing, has a wispy appearance with beads along thin fibrils of material on both H&E and colloidal iron staining. On the contrary, solar elastosis appears merely as pale blue fibers of roughly the same caliber and thickness as adjacent collagen of the superficial reticular dermis.

Mucicarmine

The mucicarmine method was first published by Mayer in 1896 and later modified by Southgate in

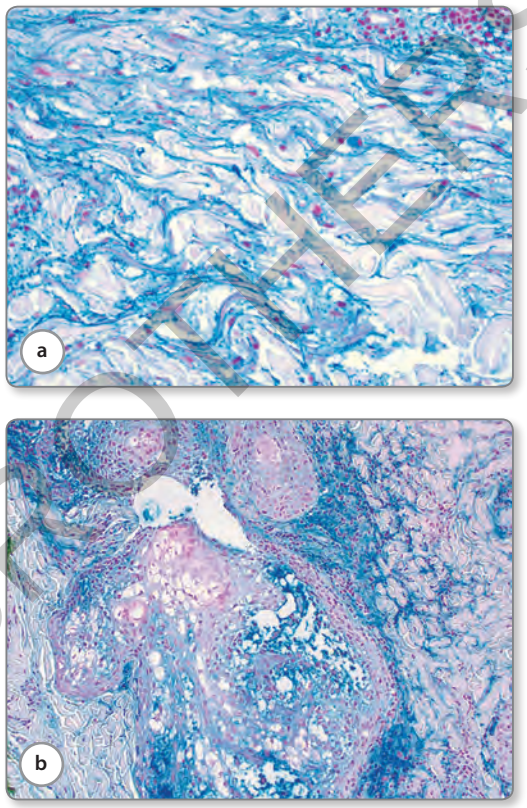

Figure 3.6 Colloidal iron stain. (a) In tumid lupus erythematosus there is an abundance of interstitial hyaluronic acid deposited between collagen bundles (colloidal iron, 200×). (b) In follicular mucinosis hyaluronic acid is deposited within follicular epithelium (200×).

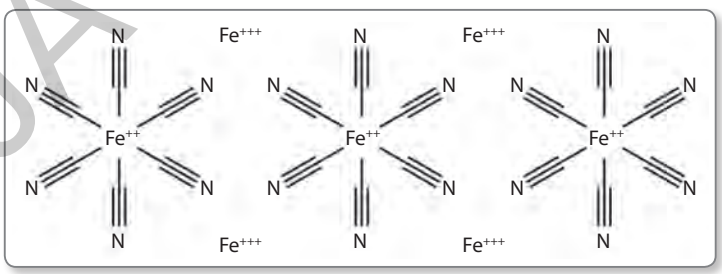

Figure 3.5 Ferric ferrocyanide. In the colloidal iron method, ferric ferrocyanide (Prussian blue) is produced by reaction of potassium ferrocyanide solution with ferric ions taken up by mucopolysaccharides from a colloidal iron solution.

JAYPEE BROTHERS

1927. Carmine is a naturally derived pigment that comes from crushed, desiccated female cochineal scale insects (*Dactylopius coccus*) (**Figure 3.7**). The mucicarmine stain remains, along with hematoxylin, one of the few naturally derived dyes still used in modern dermatopathology. The pigment is formed from an aluminum salt of carminic acid, a red glucosidal hydroxyanthrapurin (**Figure 3.8**). Indigenous people of Central America used carmine to dye textiles prior to European colonization but its use increased substantially following colonization. In addition to applications in medical diagnostics and biologic research, the pigment is used on a large scale in the cosmetics and food industries. As an example, the author recently noted carmine listed as an ingredient in his strawberry yogurt. Cochineal and carmine made news headlines when a prominent purveyor of coffee beverages announced it would no longer be using the insect-derived dye in its products because its consumption is prohibited by a number of vegetarian and religious groups. The use of carmine to stain animal tissue dates to the mid-19th century. Later modifications resulted in an application that is useful today as a stain to highlight epithelial mucins.



Figure 3.7 Cochineal scale insect. The cochineal scale insect is the source of carminic acid used in the mucicarmine stain.

In tissue reactions the aluminum-carmine complex bonds with negatively charged acid mucins including epithelial mucins (i.e. sialomucins found in tumors such as Paget disease and low grade mucoepidermoid carcinoma, among others) and the mucinous capsule of *Cryptococcus neoformans*. The primary component of the capsule is the complex polysaccharide glucuronoxylomannan (Zaragoza 2009). Neutral mucins and sulfated mucins either stain poorly or do not stain at all. A blue counterstain, such as alum hematoxylin, is typically used in order to differentiate nuclei.

Gomori/Grocott methenamine silver

Gyorgy Gomori first published a methenamine silver technique for detection of fungal organisms in 1946, followed by Grocott's modification in 1955 (Titford 2009; Suvarna 2013). The cell wall of fungi is primarily composed of the polysaccharide mannan. The mannose monosaccharides

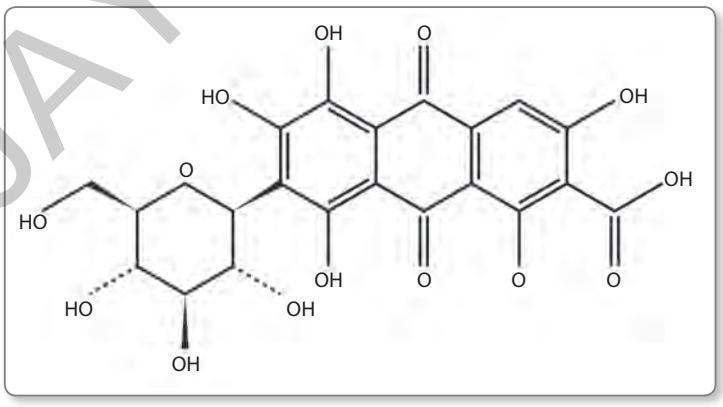

Figure 3.8 Carminic acid. This naturally produced red dye is useful in detecting epithelial mucins, as well as the mucinous capsule of *Cryptococcus neoformans*.

JAYPEE BROTHERS

comprising these long carbohydrate chains include a 1,2-glycol bond that can be oxidized into two aldehyde moieties.

In contrast to the periodic acid–Schiff method, the GMS technique utilizes chromic acid to carry out the oxidation of the 1,2-glycol bond to two aldehydes moieties. A silver solution composed of silver nitrate, borax, and methenamine is applied at high temperature to the tissue. Under these conditions, the aldehyde component reduces silver nitrate to metallic silver, which deposits in the tissue and appears black on microscopy (Suvarna, 2013). The tissue is typically counterstained light green (**Figure 3.9**). Since it is a natural reducing agent that is not readily soluble and complexes with constitutive proteins of basal keratinocytes and melanocytes, melanin pigment also appears black with this technique. Neutrophils and neutrophil debris, which frequently also stain black, may be misinterpreted as organisms by less-experienced dermatopathologists.

Melanin

Fontana–Masson

When present in sufficient quantities, melanin is readily identified in histologic sections of skin by its color (brown) and its typical distribution (overlying the nuclei of basal keratinocytes). It is important to identify abnormal distribution of melanin pigment. The Fontana–Masson technique remains useful as a fairly precise method of highlighting the distribution of melanin pigment and its relative quantity. The most common dermatoses for which this stain finds important application today include vitiligo, drug pigmentation, pigmentation of the nail unit (i.e. melanonychia), and post-inflammatory pigment alteration.

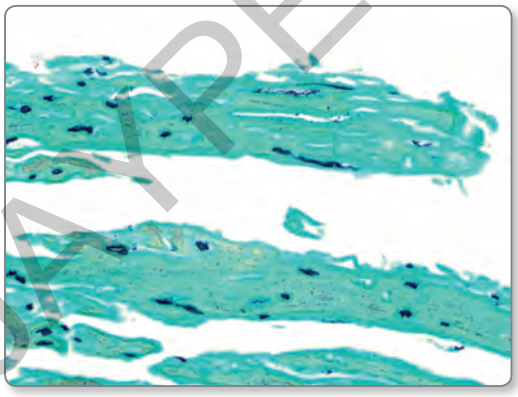

Figure 3.9 Grocott methenamine silver stain for fungal organisms. Silver nitrate is reduced to elemental silver in the presence of borax and methenamine after oxidation by chromic acid of 1,2-glycol moieties in the cell wall of fungal hyphae in onychomycosis (GMS, 400×).

The Fontana–Masson staining method relies on the argentaffin reaction. (*Argentum* is Latin for silver, so argentaffin literally means 'affinity for silver'). In this reaction, a silver salt solution is converted to elemental silver. The Fontana–Masson technique involves application of ammoniacal silver solution (Fontana's silver solution) to tissue sections followed by counterstaining with nuclear fast red. Melanin is a strong reducing agent that converts the ammoniacal silver to metallic silver. Impregnated in the tissue, elemental silver turns the already brown melanin pigment black (**Figure 3.10**) (Suvarna, 2013). The Fontana–Masson method is a very promiscuous stain that reacts with other tissue elements, including argentaffin, chromaffin, lipofuscin and fungi (**Table 3.2**).

Schmorl

As a strong reducing agent, melanin can reduce ferric ions (Fe^{3+}) to ferrous ions (Fe^{2+}). A subsequent reaction with potassium ferricyanide results in the production of ferrous ferricyanide (Turnbull blue or Prussian blue) similar to the colloidal iron and Perls staining methods discussed elsewhere in this chapter. This technique is used less commonly than the Fontana–Masson method for the detection of melanin.

Metal ions

Perls Prussian blue

Distinguishing among various pigments in histologic sections of skin is not always a simple task. The practiced eye can often discern subtle differences between endogenous and exogenous pigments, but in many instances it can be difficult to definitively differentiate melanin pigment from iron pigment. Hemosiderin is the hemoglobin-derived, iron-containing pigment most frequently encountered in skin biopsies. It generally appears

JAYPEE BROTHERS

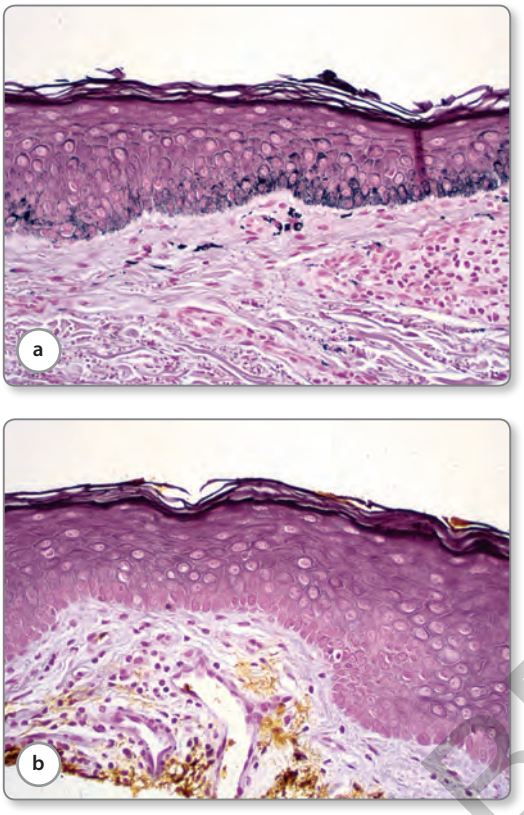

Figure 3.10 Fontana–Masson stain. (a) Fontana–Masson stain of normal uninvolved skin of a patient with vitiligo (FM, 200×). (b) Fontana–Masson stain of lesional skin of a patient with vitiligo (FM, 200×).

Table 3.2 Silver stains

Dieterle
Fontana–Masson
Gomori/Grocott methenamine silver
Steiner stain
von Kossa
Warthin-Starry

as slightly coarse, variably sized, refractile, golden-brown granules on H&E staining. Hemosiderin is present as ferric hydroxide ($Fe(OH)_3$). It forms complexes with proteins typically in an intracellular location (i.e. within macrophages). Formalin-based tissue fixation renders hemosiderin somewhat soluble in weak acid solutions, whereas ferric and ferrous forms

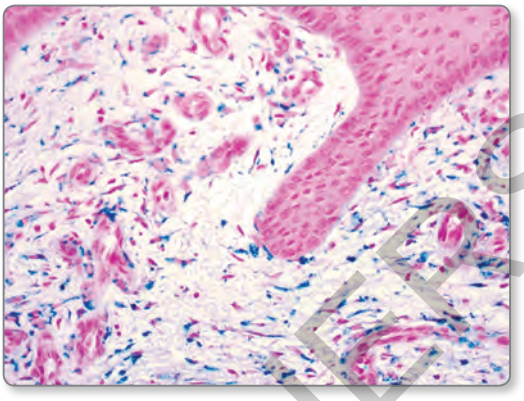

Figure 3.11 Perls Prussian blue iron stain in stasis dermatitis. In stasis dermatitis there is deposition of hemosiderin pigment within the dermis, predominantly in a perivascular distribution (Perls, 200×). Iron in hemosiderin reacts with the Prussian blue iron stain, whereas iron in hemoglobin is insufficiently soluble to react.

of iron in hemoglobin complexes are insoluble and will not react with staining solutions for iron pigment (Suvarna, 2013).

The Perls Prussian blue reaction allows demonstration of ferric iron ions (Fe^{3+}) in tissue sections. Treatment of tissue sections with a combination of dilute hydrochloric acid and potassium ferrocyanide allows the release of ferric hydroxide ($Fe(OH)_3$) from hemosiderin-protein complexes and subsequent conversion to ferric ferrocyanide ($Fe_4[Fe(CN)_6]_3 \cdot \times H_2O$) (i.e. Prussian blue). Ferric ferrocyanide is an insoluble blue pigment that is detected on light microscopy. The root word cyan (i.e. cyanide) is derived from the Greek *kyanos* meaning dark blue. Counterstaining for the Perls Prussian blue method is typically performed with nuclear fast red (**Figure 3.11**). Of note, the Prussian blue pigment has been used as a pigment in art since at least the early 18th century in Europe and perhaps in the well-known Japanese painting *The Great Wave Off Kanagawa* by Hokusai (c. 1830).

Von Kossa

Inorganic calcium salts in sections of skin are typically deposited as calcium phosphate or calcium carbonate salts. While free ionic calcium (Ca^{2+}) is to all intents and purposes not detectable

JAYPEE BROTHERS

using histochemical techniques, inorganic salts of calcium in tissue sections (i.e. calcium phosphate) can be demonstrated directly or indirectly. The dermatopathologist may find this stain most useful in identifying or confirming the presence of subtle calcification, as in calciphylaxis or pseudoxanthoma elasticum, as opposed to more grossly evident cases of calcinosis cutis.

The von Kossa method employs a silver staining technique, in which silver nitrate is applied to tissue sections. Silver cations (Ag^{1+}) precipitate with the phosphate and/or carbonate anions of the calcium salts (Suvarna, 2013). The stain is considered more sensitive but less specific than the alizarin red S method. For example, silver nitrate will stain melanin in treated sections in addition to the calcium salts. Given that melanin and calcium deposits are not frequently collocated, this does not typically cause significant errors of interpretation. Skin sections are typically counterstained with nuclear fast red (**Figure 3.12**).

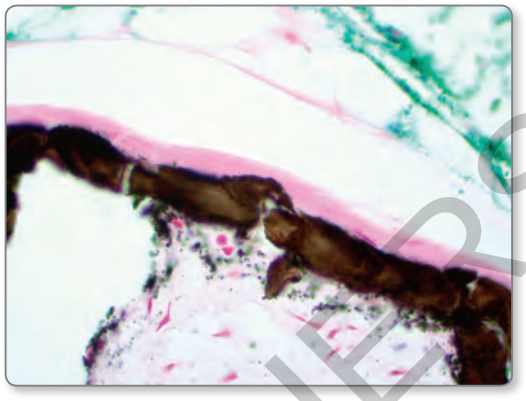

Figure 3.12 Von Kossa silver stain of calcinosis cutis. Calcium deposits in calcinosis cutis are demonstrated by precipitation of silver nitrate with phosphate and carbonate from calcium salts and subsequent reduction to elemental silver.

Alizarin red S

In contrast to the von Kossa method for the detection of inorganic calcium salts, alizarin red S represents a dye that directly stains calcium within tissue sections (**Figure 3.13**). Alizarin red S forms a chelate complex with calcium that appears red and is often paired with fast green FCF as a counterstain. A pH of 4.2 may improve the stain's ability to detect smaller particulate deposits of calcium.

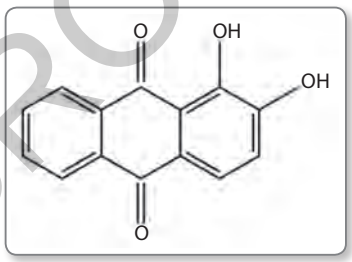

Figure 3.13 Alizarin red dye. This dye demonstrates calcium salt deposition directly through a chelation process.

Connective tissue

Verhoeff

The Verhoeff technique is a widely accepted method for detecting elastic fibers in formalin-fixed paraffin-embedded tissue sections. First published in 1908 by Frederick H. Verhoeff, this method permits the visualization of fine oxytalan fibers of the papillary dermis and elaunin fibers of the deeper reticular dermis (Titford, 2009).

The Verhoeff staining method takes advantage of the disulfide crosslinking between elastic fibers. These disulfide bonds are oxidized in the presence of iodine to anionic sulfonic acid. The iodine is applied in solution with alcohol hematoxylin and ferric chloride. The anionic sulfonic acid moieties have a higher affinity to iron and hematoxylin in the solution than the surrounding tissue during the subsequent decolorization step. So, as the dye is removed more readily from adjacent collagen and cellular elements, the result is deep blue or black staining of elastic fibers (Suvarna, 2013).

The van Gieson technique is commonly used as a counterstain with the Verhoeff method. This step employs picric acid with acid fuchsine resulting in black staining of nuclei and red staining of collagen (**Figure 3.14**) (Suvarna, 2013). Because of the frequent use of the van Gieson counter stain, this two-step process is typically known as the Verhoeff–van Gieson (VVG) or elastin–van Gieson (EVG) stain.

Masson trichrome

On routine H&E staining, the connective tissue comprising the dermis, including collagen,

JAYPEE BROTHERS

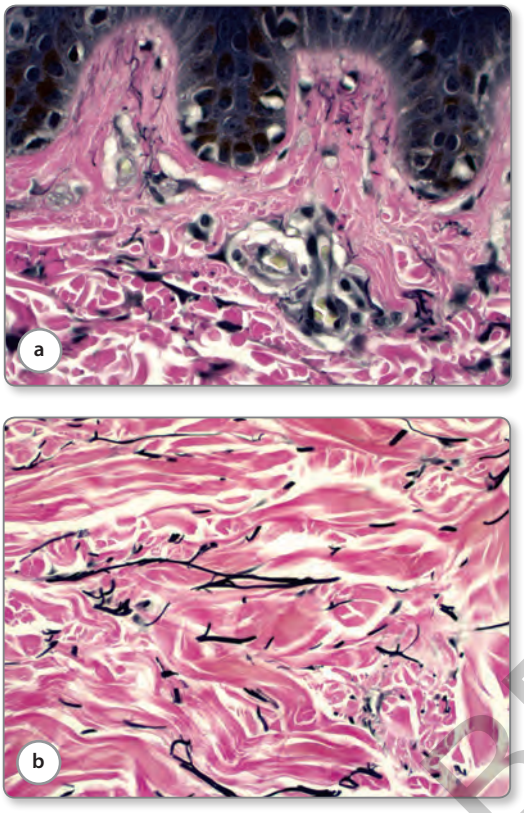

Figure 3.14 (a) Verhoeff-van Gieson stain. Verhoeff-van Gieson stain of normal papillary dermal elastin fibers (VVG, 400×). (b) Verhoeff-van Gieson stain of thicker elastin fibers in the reticular dermis (VVG, 200×).

smooth muscle, and nerve fibers, all appears in various shades of pink. Trichrome stains allow for differential staining of connective tissue structures. The Masson trichrome technique produces a very distinctive contrast between muscle (red) and collagen (blue/green). Historically, this stain was very useful for determining the lineage of soft tissue tumors, but that role has since been ceded to immunohistochemistry. In the skin, this is specifically useful for differentiating smooth muscle from collagen or for detecting collagen fibers entering the epidermis. The role of this technique is now somewhat limited to the confirmation of collagen fibers penetrating the epidermis in reactive perforating collagenosis. Some may still find it useful in the diagnosis of smooth muscle neoplasms and hamartomas as well. The stepwise application of various solutions is required to allow for differential staining of the tissue sections.

The Masson trichrome method begins with hematoxylin staining of nuclei, which will be resistant to subsequent applications of acidic solutions in preparation for other dyes to adhere to other tissue structures. Next, an acid fuchsine solution stains the tissue red. Phosphomolybdic acid or phosphotungstic acid are used to decolorize collagen fibers, but muscle tissue, fibrin, cytoplasm, and erythrocytes retain the red acid fuchsine stain. Finally, aniline blue (a mixture of methyl blue and water blue dyes) is applied, staining collagen fibers blue (Suvarna, 2013). Because of retention of the red acid fuchsine stain, the other structures are unaffected by the blue dye (**Figure 3.15**).

Several other histochemical techniques allow differential staining of additional connective tissue structures, including the van Gieson stain, phosphotungstic acid-hematoxylin (PTAH), Gomori trichrome, and Russel–Movat pentachrome. Other than the van Gieson stain, these additional methods are employed to detect finer details in nerve and muscle tissue. They are less frequently utilized in the realm of dermatopathology.

Amyloid

Congo red

Congo red is a long, symmetrical, sulfonated azo dye that was first used as a textile dye (**Figure 3.16**). The name of the dye was chosen not because of some exotic source in central sub-Saharan Africa, but rather because it served as a catchy name that might attract the interest of textile manufactures in the nineteenth century (Steensma, 2001). The molecular structure of Congo red permits situation of the dye between the anti-parallel strands of β-pleated sheets comprising amyloid fibrils. The linear arrangement of the dye confers the property of dichroism upon polarization microscopy. In other words, light with different polarization is differentially absorbed by the Congo red dye (Suvarna, 2013). Typically, Congo red-stained amyloid tissue appears brick red on routine light microscopy but can appear yellow-green (or 'apple green') with polarized light. Hematoxylin is used as a counterstain so that nuclei appear blue (**Figure 3.17**).

JAYPEE BROTHERS

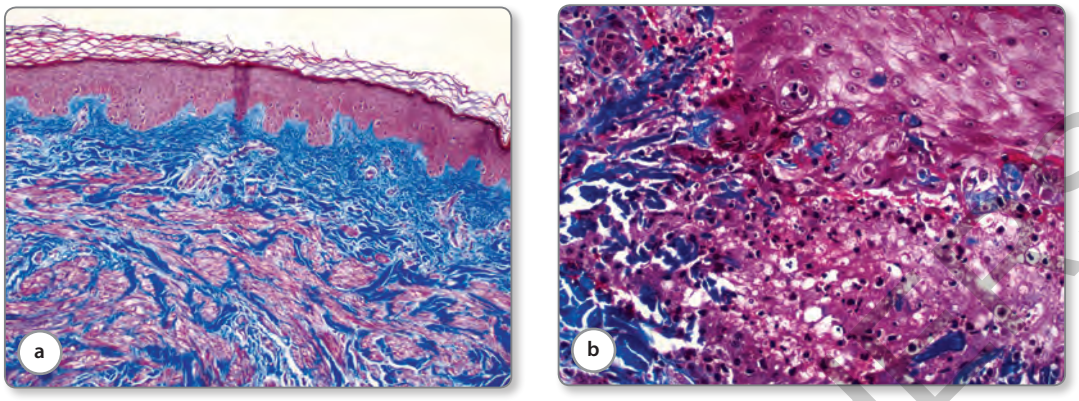

Figure 3.15 Masson trichrome stain. (a) Masson trichrome stain highlighting pink smooth muscle and adjacent blue collagen bundles in leiomyoma (Masson trichrome, 100×). (b) Masson trichrome stain demonstrating blue collagen fibers extending into pink epidermis (Masson trichrome, 200×).

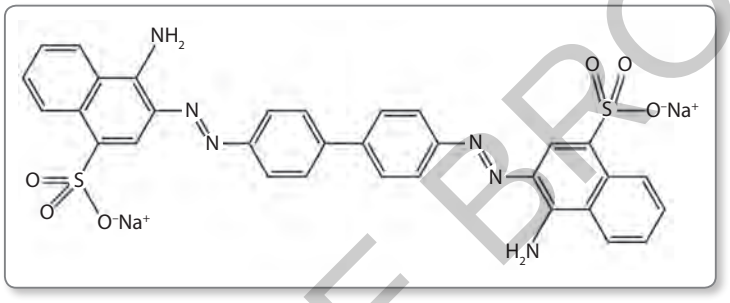

Figure 3.16 Congo red dye. The molecular structure of the Congo red dye allows for situation between the anti-parallel strands of β-pleated sheets of which amyloid deposits are composed.

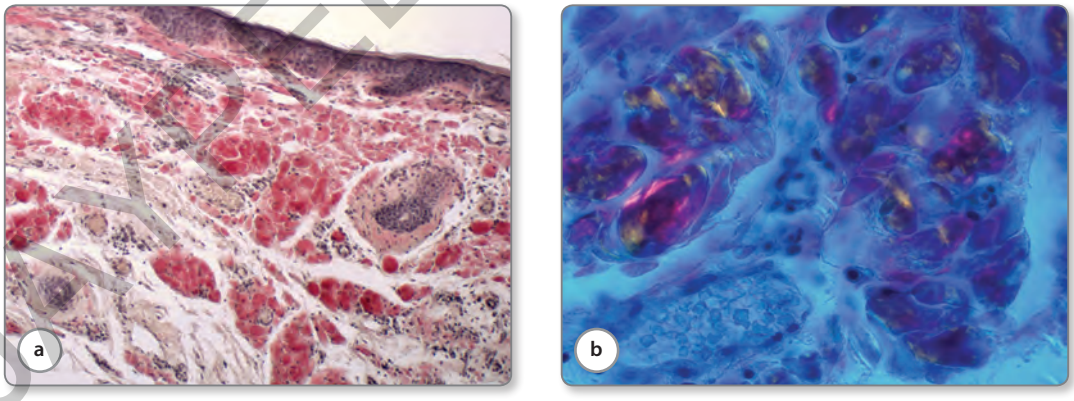

Figure 3.17 Congo red stain of amyloidosis. (a) Congo red staining of amyloid appears brick red with non-polarized light (Congo red, 100×). (b) However, with polarized light in the appropriate orientation amyloid deposits appear yellow-green (400×).

JAYPEE BROTHERS

It is important to recognize that in some cases collagen fibers or other structures may also pick up the Congo red dye. Because of false positive and false negative results, interpretation should be performed with adequate positive tissue controls and in conjunction with routine tissue staining with hematoxylin and eosin.

Lipids

The routine processing of skin biopsies received in neutral buffered formalin limits demonstration of lipids on paraffin embedded tissue. Processing through steps of dehydration with alcohols, acetones and xylene allows the diffusion of endogenous lipids from adipocytes, as well as interstitial injected lipids and lipid-like materials, out of the tissue. On routine H&E staining, the clear spaces observed within subcutaneous adipose tissue, matures sebocytes, and xanthomatized histiocytes result from this loss of lipids. Therefore, optimal demonstration of lipids in tissue sections demands the use of unfixed frozen tissue that has not been dehydrated with alcohols, xylene or paraffin. Some application of formalin-containing solution is sometimes required to allow fixation of the protein comprising the surrounding tissue. Lipids are not fixed in neutral buffered formalin. Aqueous mounting medium, and not xylene, should be used for coverslipping.

Oil Red O and Sudan Black B are both fat-soluble diazo dyes (**Figure 3.18**). Their use involves application of the dye dissolved in a hydrophobic solvent. When the dye solution is applied to the tissue, the dye migrates to lipid-rich areas in the tissue. This is followed by application of a hematoxylin counterstain. Oil red O application results in bright red fat; Sudan black B application results in blue-black triglyceride staining and gray staining of phospholipids (Suvarna, 2013). Practical applications of these lipid stains in routine dermatopathology are limited.

Infectious disease

Gram stain for bacteria

The Danish bacteriologist Hans Christian Gram published a technique for the visualization of bacteria under microscopy in 1884 (Titford, 2009). Because of differences in the composition of bacterial cell walls and membranes there is differential staining in different types of bacteria. Bacterial species are broadly divided into Gram-positive and Gram-negative categories based on their differential staining using this method. Techniques adapting the Gram stain for use on formalin-fixed paraffin-embedded tissue were published in the 1960s and 1970s and have subsequently been modified. Two of the more

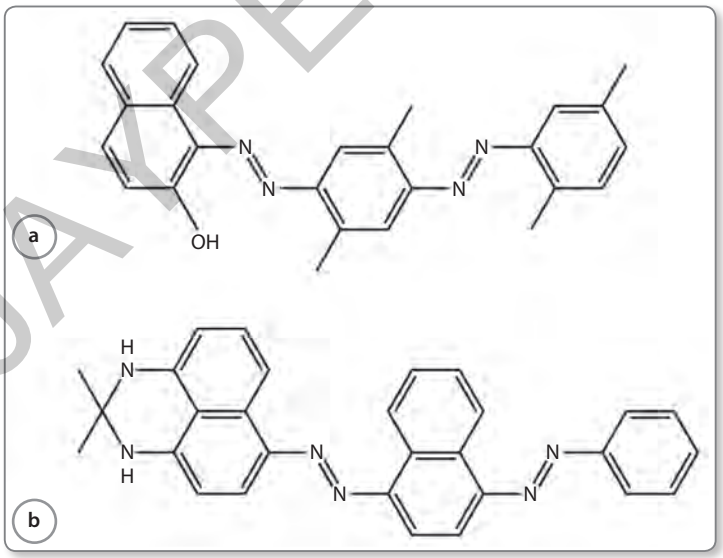

Figure 3.18 Oil red O and Sudan black dye. (a) Oil red O and (b) Sudan black are dyes that are used to highlight lipids in unprocessed tissue.

JAYPEE BROTHERS

commonly used of these tissue-based techniques include the Brown and Brenn method and the Brown-Hopps method (the Brown is a different individual in each and, conventionally, the latter is hyphenated and the former is joined by a conjunction).

The Gram stain and subsequent modifications rely on similar principles. A crystal violet solution is applied to the tissue staining the thick outer peptidoglycan layer of Gram-positive bacteria and the lipopolysaccharide layer of Gram-negative bacteria (**Figure 3.19**). Next, an iodine solution causes fixation of crystal violet to the peptidoglycan layer of Gram-positive bacteria. Decolorizing with alcohol-acetone solution follows, removing crystal violet from the lipopolysaccharide layer of Gram-negative bacteria. The tissue is then counterstained with magenta-hued basic fuchsine, which highlights the peptidoglycan layer of Gram-negative bacteria. Due to prior fixation of crystal violet with iodine, Gram-positive bacteria do not take up the basic fuchsine counterstain (Suvarna, 2013). Additional steps allow for staining of the background tissue with picric acid, which results in a yellow color (**Figure 3.20**).

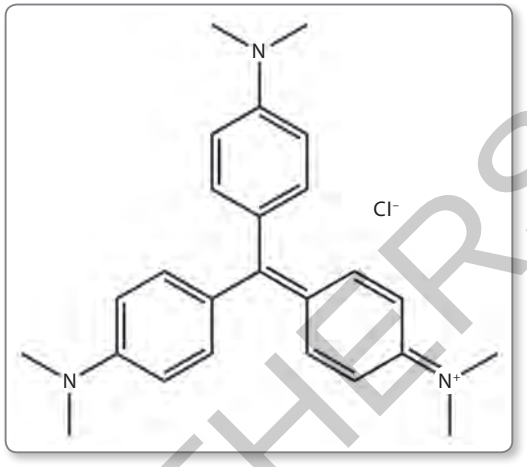

Figure 3.19 Crystal violet dye is used in bacterial Gram stain. Crystal violet binds to the peptidoglycan layer surrounding Gram-positive bacteria and the lipopolysaccharide layer of Gram-negative bacteria. The crystal violet dye is retained by Gram-positive organisms following iodine fixation, but is removed from Gram-negative bacteria during a decolorization step.

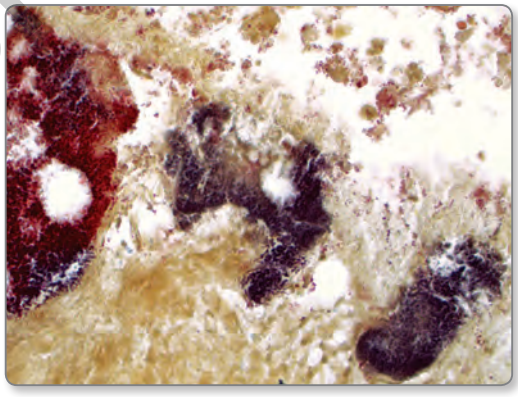

Figure 3.20 Brown-Hopps tissue Gram stain with Gram-positive and Gram-negative organisms. The Brown-Hopps tissue Gram stain allows the dermatopathologist to distinguish Gram-positive (purple) and Gram-negative (red) bacteria (B-H, 400×).

Ziehl–Neelsen and Kinyoun for acid-fast bacilli

The German bacteriologists Franz Ziehl and Friedrich Neelsen introduced the use of carbol fuchsine dye for detecting acid-fast bacilli in 1882. The stain's use allowed detection of the tuberculosis bacillus. In 1915 Joseph Kinyoun (K) published a modification of the Ziehl–Neelsen (ZN) method that allowed staining without the application of heat (Titford, 2009).

Carbol fuchsine is composed of a mixture of basic fuchsine and phenol. This red dye has a high affinity for hydrophobic mycolic acid in the fatty capsule surrounding the cell membranes of mycobacteria species and is not easily removed by application of acid alcohol (thus 'acid-fast') (Suvarna, 2013). A counterstain of methylene blue is typically employed, allowing the detection of red bacilli on a blue background (**Figure 3.21**). In addition to mycobacteria, the stain can detect some fungal organisms and filamentous bacteria (i.e. *Nocardia* and *Actinomyces* species) and often reacts with keratin in hair shafts and in the stratum corneum. In skin specimens, this latter finding can be used as an internal positive control.

Fite for acid-fast bacilli

Sometimes called the Fite–Faraco or Wade–Fite method depending on the procedure followed,

JAYPEE BROTHERS

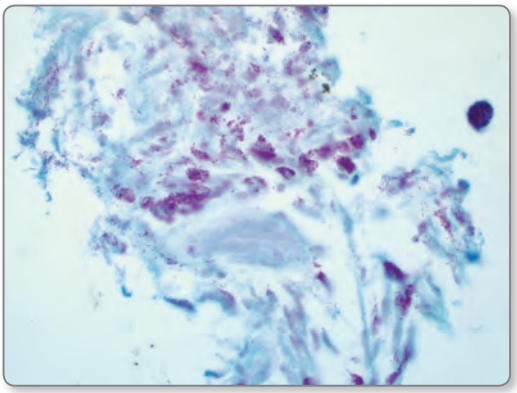

Figure 3.21 Kinyoun stain for acid-fast bacilli in an atypical mycobacterial infection. Most acid-fast bacilli and other bacteria (i.e. *Nocardia* spp.) are demonstrated by Kinyoun and Ziehl-Neelsen stains for atypical mycobacteria (Kinyoun, 400×).

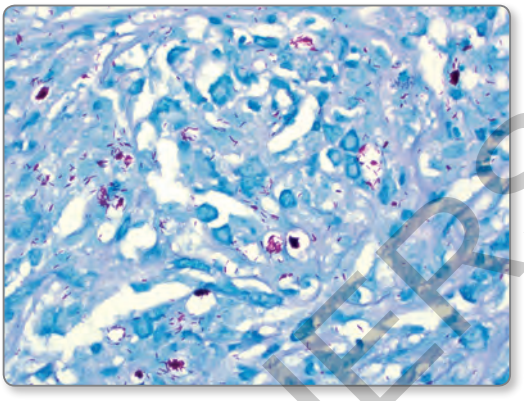

Figure 3.22 Fite stain for acid-fast bacilli in leprosy. The acid-fast bacilli *Mycobacterium leprae* is demonstrated in this biopsy from a leprosy skin lesion (Fite, 400×).

but often shortened colloquially to Fite, this method is exceptionally useful in detecting *Mycobacterium leprae* and other atypical mycobacteria in paraffin-embedded tissue sections.

This method differs from the other methods for staining acid-fast bacilli (Ziehl–Neelsen and Kinyoun) in two important regards. Firstly, deparaffinization is performed using xylene and peanut oil. The peanut oil allows better preservation of the far more fragile fatty acid layer surrounding the organisms, as *M. leprae* is much less acid-fast than other mycobacterial organisms. Secondly, rather than an acid alcohol solution, sulphuric acid is employed as a decolorizer. Methylene blue is also used as a counterstain with this method (**Figure 3.22**) (Suvarna, 2013). In the author's experience, the Fite method is more commonly used alone or in combination with the Ziehl-Neelsen or Kinyoun methods, as the former will detect both *M. leprae* and other mycobacterial organisms in cutaneous specimens.

Warthin–Starry, Dieterle, Steiner and Steiner

A method for detecting spirochetes, such as *Treponema pallidum* and *Bartonella henselae*, was first published in 1920 by Aldred S. Warthin and Allen C. Starry (Titford, 2009). A solution of silver nitrate is applied and taken up by spirochetes or other reactive bacteria. A reducing reaction, commonly using hydroquinone, allows conversion of the silver ions to elemental silver. In the Dieterle (1927) and Steiner (1944) methods, the specimen is pretreated with uranyl nitrate prior to application of a silver nitrate solution and gum mastic (Titford, 2009; Suvarna, 2013). The sections are then developed in a reducing solution with hydroquinone. On microscopy, the target organisms are stained black on a golden-yellow background (**Figure 3.23**). Because of a similar affinity for silver ions, melanin granules that have also reduced silver nitrate to elemental silver may obscure spirochete staining at the dermal-epidermal junction in secondary syphilis. The development of immunohistochemical stains for spirochetes such as *T. pallidum* has largely supplanted the use of these stains for cutaneous applications, although other applications for detection of *Legionella pneumophila*, *Bartonella henselae*, and *Borrelia burgdorferi*, remain.

Metachromatic stains

Metachromatic dyes, such as toluidine blue and methylene blue, are defined by their ability to change color in the presence of certain tissue components. The color change is most characteristically induced by closely grouped polyanionic moieties on carbohydrates, such as

JAYPEE BROTHERS

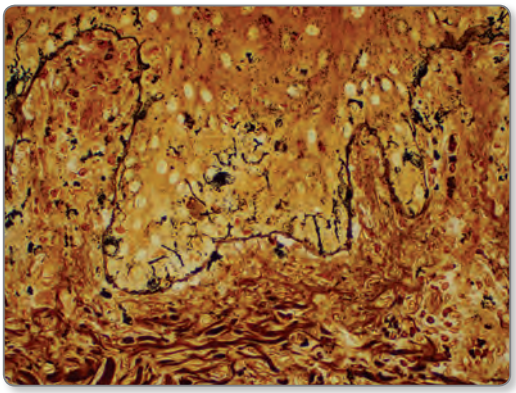

Figure 3.23 Warthin-Starry silver stain. Treponemal spirochetes in syphilis take up silver nitrate, which is reduced to elemental silver in a reaction with hydroquinone (W-S, 400×).

long-chain proteoglycans. When the sulfate and carboxylate polyanionic moieties of proteoglycans have a charge and repeat at regular intervals, the positively charged metachromatic dyes aggregate. The positioning of the dye molecules allows polymeric binding between them, altering the absorption and emission spectra from the background dye monomers in the remainder of the tissue.

Giemsa

In 1904, the German bacteriologist Gustav Giemsa published a modification of Dmitri Romanowsky's previously published method for differentially staining cells in tissue sections (Titford, 2009). The Giemsa technique and subsequent modifications involve staining by a stock solution composed of a mix of eosin Y (an acid dye) and methylene blue (a basic dye) (**Figure 3.24**) (Barcia, 2007). This method is useful in detecting mast cells through metachromatic staining of mast cell granules rich in the glycosaminoglycan heparin (**Figure 3.25**). The Giemsa stain has also been used for detecting parasitic organisms such as *Leishmania, Entamoeba* and *Toxoplasma* species. Tzank is a modified Giemsa, often used in dermatology. Other modifications of the original Romanowsky method, including the Wright, Leishman and Jenner methods, are more commonly used for blood smears because of the nuclear detail provided and their ability to detect hematogenous parasites.

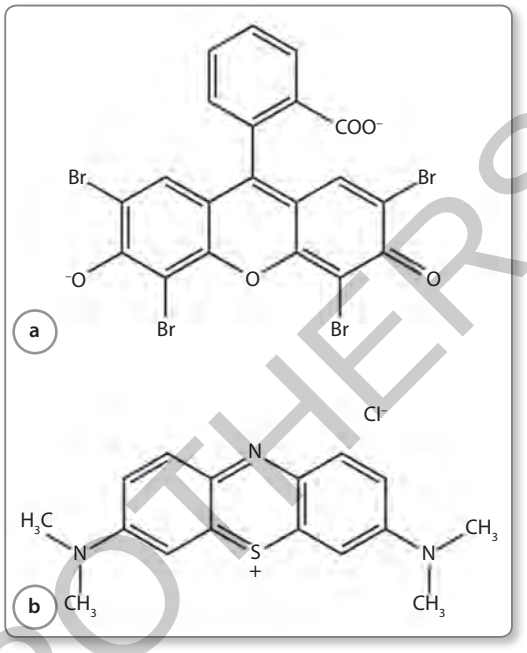

Figure 3.24 Giemsa stain. Giemsa solution is a mixture of (a) Eosin Y and (b) metachromatic methylene blue dyes.

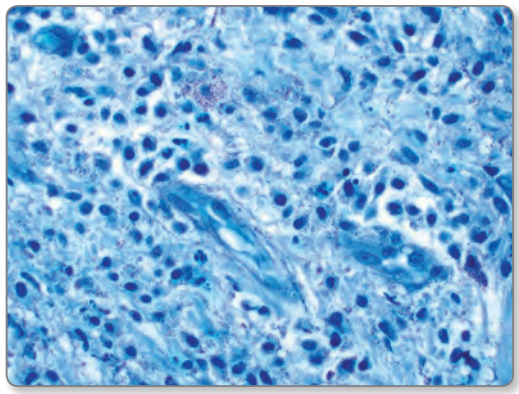

Figure 3.25 Giemsa stain of mastocytosis. Heparin within mast cell granules stain metachromatically in this example of cutaneous mastocytosis.

Toluidine blue

The metachromatic dye toluidine blue, also known as tolonium chloride, is a basic thiazine dye with limited application in routine dermatopathology (**Figure 3.26**). Like the

JAYPEE BROTHERS

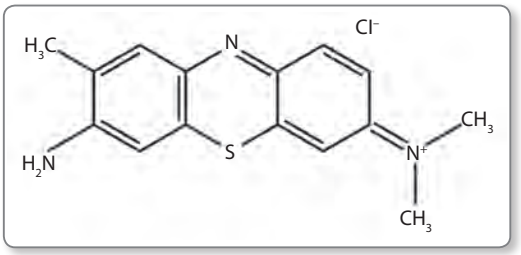

Figure 3.26 Toluidine blue dye. Toluidine blue stains mucopolysaccharides metchromatically and may have utility in Mohs surgery for basal cell carcinoma.

methylene blue used in the Giemsa method, toluidine blue appears red-purple in mast cell granules due to metachromatic properties (Sridharan, 2012). The proteoglycan hyaluronic acid is weakly metachromatic with toluidine blue staining and may be accentuated in the fibromyxoid stroma surrounding basal cell carcinoma. Toluidine blue also has a high affinity for nucleic acids, without metachromasia. These properties together may explain why some groups have found that toluidine blue may be useful as a stain in Mohs micrographic surgery for removal of basal cell carcinoma (Humpherys, 1996).

Miscellaneous

Leder

The Leder method relies on the retention of enzymatic activity of chloroacetate esterase in granulocyte and mast cell granules in formalin-fixed, paraffin-embedded tissue. The tissue is incubated in a solution containing naphthol AS-D chloroacetate and basic fuchsine. Chloroacetate esterase reacts with naphthol AS-D chloroacetate releasing naphthol, which subsequently acts on basic fuchsine to produce a bright magenta color (Patterson, 2016). The technique is both time- and resource-intensive. This method has been largely replaced by other special stains, like Giemsa and toluidine blue, or the immunohistochemical stain for mast cell tryptase. The method finds greater application today in hematopathology, but may be useful on occasion for the evaluation of leukemia cutis along with immunohistochemical stains for myeloperoxidase and lysozyme.

References

Barcia JJ. The Giemsa Stain: its history and applications. Int J Surg Pathol 2007;15:292–6.

Hale CW. Histochemical demonstration of acid polysaccharides in animal tissues. Nature 1946; 157:802.

Humpherys TR, Nemeth A, McCrevey S, Baer SC, Goldberg LH. A pilot study comparing toluidine blue and hematoxylin and eosin staining of basal cell and squamous cell carcinoma during Mohs surgery. Dermatol Surg 1996; 22:693–7.

McManus JFA. Histological demonstration of mucin after periodic acid. Nature 1946;158:202.

Patterson JW. Weedon's Skin Pathology, 4th ed. London: Elsevier, 2016.

Sridharan G, Shankar AA. Toluidine blue: A review of its chemistry and clinical utility. J Oral Maxillofac Pathol. 2012;16:251–5.

Steensma DP. 'Congo' red: out of Africa? Arch Pathol Lab Med 2001;125:250–2.

Suvarna SK, Layton C, Bancroft JD. Bancroft's Theory and Practice of Histological Techniques, 7th Ed. London: Churchill Livingstone, 2013.

Titford M. Progress in the development of microscopical techniques of diagnostic pathology. J Histotechnol 2009;32:9–19.

Zaragoza O, et al. The capsule of the fungal pathogen *Cryptococcus neoformans*. Adv Appl Microbiol 2009; 68:133.

JAYPEE BROTHERS

DIAGNOSTIC DERMATOPATHOLOGY

A GUIDE TO ANCILLARY TESTS BEYOND THE H&E

Dermatopathology has evolved from a reliance on the H&E section to include a wide range of newer diagnostic assays used either as stand-alone tests or in addition to the H&E. *Diagnostic Dermatopathology: A Guide to Ancillary Tests Beyond the H&E* is a practical guide to the most important of these new diagnostic techniques.

Following the opening chapters on the history of the specialty and the H&E stain, the book is arranged by sections covering each technique. Chapters within these sections offer insight into why each of these assays is performed, and practical guidance on how to use them in a clinical setting and how to interpret the results they provide.

Diagnostic Dermatopathology: A Guide to Ancillary Tests Beyond the H&E is an essential resource for trainee and practicing dermatopathologists, dermatologists and pathologists seeking an accessible guide to the full range of diagnostic methods used in conjunction with the H&E or as stand-alone tests.

- Covers the full range of diagnostic techniques in dermatopathology, aside from H&E, with a focus on practical information of relevance to clinical practice
- Includes special stains, immunohistochemistry, immunofluorescence, electron microscopy, molecular testing and point of care dermatologic tests
- Features numerous color photographs, diagnostic tips and clinical advice based on the authors' extensive personal experience

JP medical publishers

www.jpmedpub.com

ISBN 978-1-909836-12-9

9 781909 836129