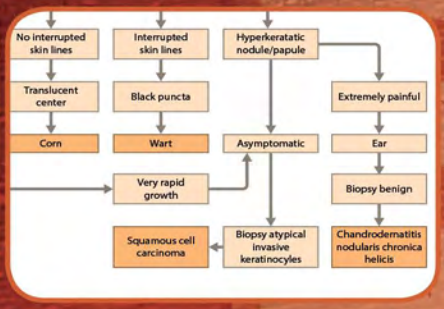





DIFFERENTIAL DIAGNOSIS IN DERMATOLOGY

SECOND EDITION

Klaus F Helm
Galen T Foulke
James G Marks Jr

JP

Contents

Preface v

PART 1: LOCALIZED RASHES

Chapter 1
Scalp 1

Chapter 2
Face 27

Chapter 3
Oral mucosa 49

Chapter 4
Hands and feet 65

Chapter 5
Nails 79

Chapter 6
Legs 89

Chapter 7
Genitalia 111

PART 2: GENERALIZED RASHES

Chapter 8
Papulosquamous diseases 129

Chapter 9
Excoriations 157

Chapter 10
Vesicular and bullous diseases 171

Chapter 11
Macular and urticarial rashes 193

Chapter 12
Generalized pustular eruptions 205

PART 3: NEOPLASMS

Chapter 13
Epidermal growths 215

Chapter 14
Pigmented growths 253

Chapter 15
Benign dermal neoplasms 281

Chapter 16
Malignant dermal neoplasms 299

PART 4: SELF ASSESSMENT

Chapter 17
Self-assessment 317

Index 337

Chapter 3 Oral mucosa

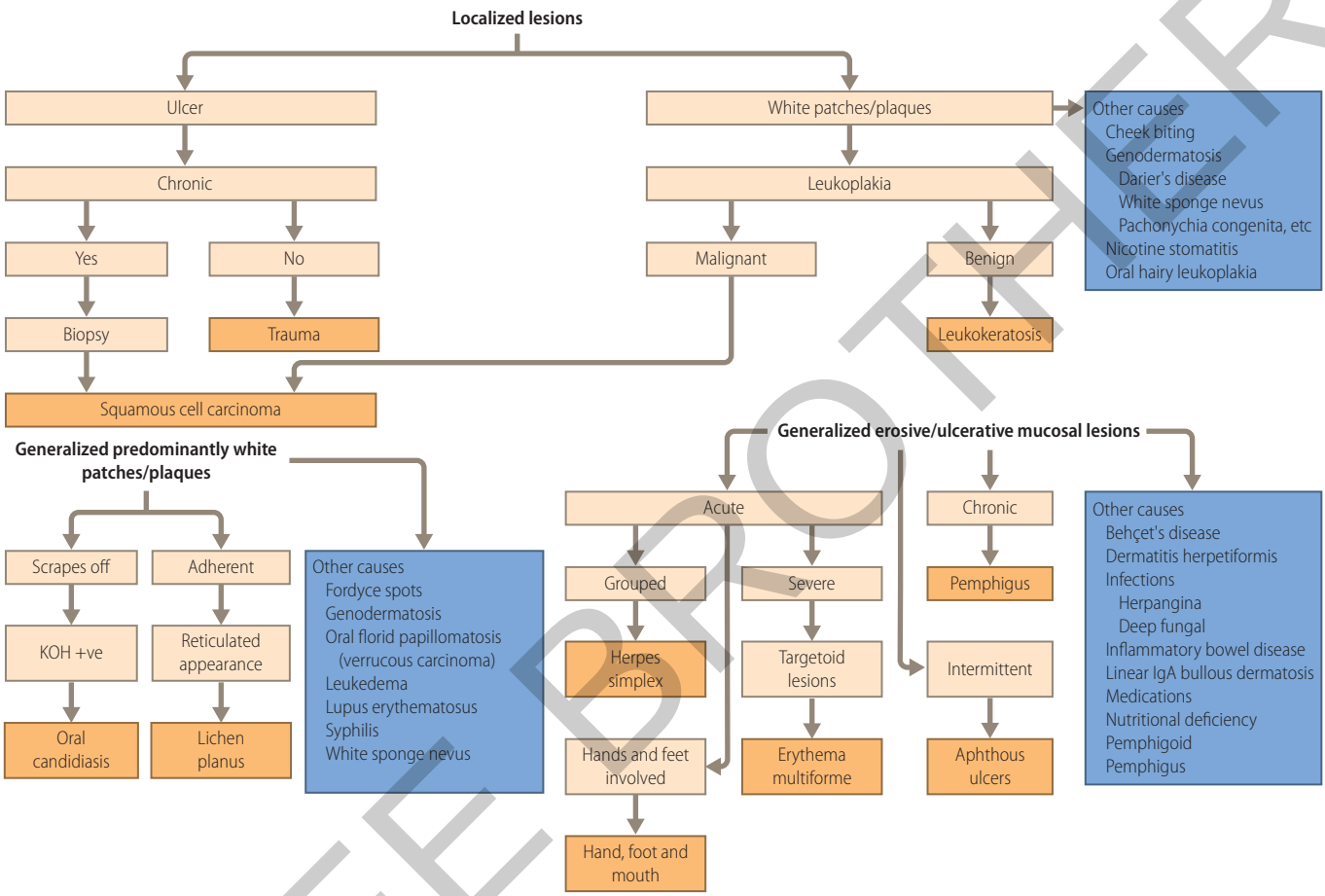

INTRODUCTION

Mucosal epithelium is different from the integument in that an outer keratinizing layer (stratum corneum) is not made in the absence of disease, adnexal structures are not present, and there is more rapid epithelialization. There is a limited repertoire of responses that mucosal epithelium can have to diseases. Therefore, oral diseases tend to look identical, and diagnoses made from clinical appearance and history may need to be supported by biopsy and blood test results. For example, white patches can be seen in entirely disparate diseases such as lichen planus, candidiasis, and squamous cell carcinoma. Oral lesions are especially important, since they can interfere with eating. In some diseases such as pemphigus, oral lesions may be the harbinger of a potentially fatal disease.

JAYPEE BROTHERS

1. LICHEN PLANUS VERSUS ORAL CANDIDIASIS

Features in common: white mucosal lesions

Figure 3.1.1 Lichen planus.



Figure 3.1.2 Oral candidiasis.



Distinguishing features

	Lichen planus	Oral candidiasis
Physical examination		
Morphology	White, reticulated plaque Ulcers commonly present White plaques do not rub off	White strands become confluent, forming plaques Ulcers rarely seen White plaques easily rub off
Distribution	Buccal mucosa, tongue, gingiva, palate, lips	Buccal mucosa, tongue, gingiva, palate, pharynx
History		
Symptoms	Asymptomatic or painful if ulcerated	Asymptomatic; occasionally burning mouth
Exacerbating factors	Iatrogenic: antimalarials, quinidine, β-blockers, diuretics, hypoglycemic agents Dental amalgams	Iatrogenic: steroids, antibiotics Immunosuppressant Dentures and implants
Associated findings	Violaceous papules and plaques on wrists, ankles, elsewhere in half of patients Nail dystrophy	Endocrine diseases: diabetes, thyroid, hypoparathyroidism Systemic diseases: lymphomas, autoimmune, immunodeficiencies (HIV)
Epidemiology	Adults	Any age
Biopsy	Yes Lichenoid infiltrate, irregular epidermal hyperplasia with sawtooth-like appearance, hypergranulosis	No Spores and pseudohyphae on surface of of epithelium (highlighted by periodic acid-Schiff stains)
Laboratory	None; KOH negative	Positive KOH
Outcome	Chronic course	Good response to therapy

HIV, human immunodeficiency virus; KOH, potassium hydroxide.

JAYPEE BROTHERS

Differential diagnosis of white oral plaques (leukoplakia)

Common causes
- Cheek biting (Morsicatio buccarum)
- Fordyce's spots
- Lichen planus
- Oral candidiasis
- Oral hairy leukoplakia
- Nicotine stomatitis
- Squamous cell carcinoma or dysplasia

Rarer causes
- White sponge nevus
- Oral florid papillomatosis
- Focal epithelial hyperplasia
- Leukoedema
- Mucous patch of syphilis
- White patches of genodermatosis: Darier's disease, pachyonychia congenita, dyskeratosis congenita



Figure 3.1.3 Lichen planus. *Clue to diagnosis:* reticulated white plaque on gingiva.



Figure 3.1.4 Lichen planus. *Clue to diagnosis:* ulcers in buccal mucosa with surrounding white reticulated plaques.



Figure 3.1.5 Lichen planus

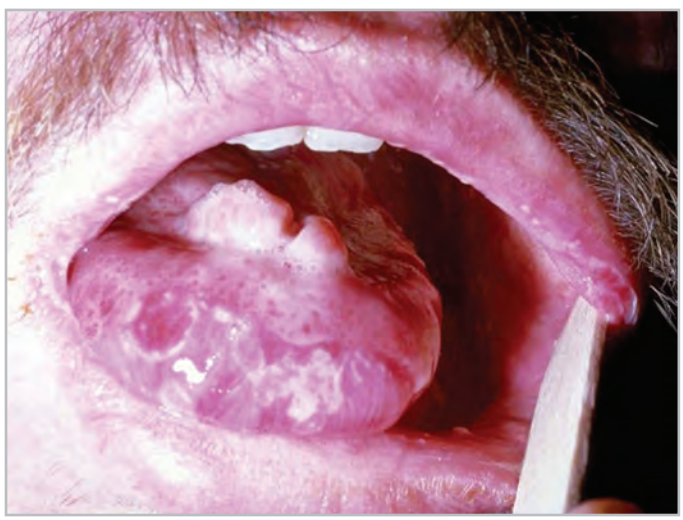

Figure 3.1.6 Chronic candidiasis in a patient with graft vs. host disease.

JAYPEE BROTHERS

2. APTHOUS ULCERS VERSUS PEMPHIGUS VULGARIS

Features in common: oral ulcer

Figure 3.2.1 Aphthous stomatitis.



Figure 3.2.2 Pemphigus vulgaris.



Distinguishing features

	Aphthous ulcers	Pemphigus vulgaris
Physical examination		
Morphology	Minor aphthae: 4–8 mm round or oval lesions, yellow center and erythematous rim Major aphthae: similar appearance but large 1–3 cm ulcers Herpetiform: grouped small 1-mm erosions that coalesce into large ulcers	Large (often several centimeters in size) in coalescent ulcers and erosions Vesicles not grouped
Distribution	Buccal mucosa and occasionally tongue, soft palate, oropharynx	Buccal mucosa, tongue, palate, gingiva, occasionally oropharynx
History		
Symptoms	Intermittent oral sores Four stages: premonitory, preulcerative, ulcerative, healing Premonitory stage: asymptomatic or paresthesia and burning sensation Preulcerative and ulcerative stage: pain	Chronic oral sores Severe pain and discomfort
Exacerbating factors	Stress, nutritional deficiencies, food allergy, infections, trauma	Occasionally drug-induced: penicillamine, penicillin, captopril, phenobarbital
Associated findings	Ulcers of genital mucosa occasionally (if uveitis consider Behçet's disease)	Erosions in glabrous skin Positive Nikolsky's sign
Epidemiology	Common Can occur at any age, but most prevalent in young adults	Rare Primarily affects middle-aged adults
Biopsy	No Nonspecific ulceration	Yes Epidermal acantholysis, eosinophilic infiltrate, tombstoning of the basal epithelial layer
Laboratory	Occasionally vitamin B12, folic acid, iron deficiency	Positive indirect and direct immunofluorescence results
Outcome	Chronic relapsing course	Mortality of 60–90% prior to glucocorticoid treatment Chronic disease

JAYPEE BROTHERS

Differential diagnosis of oral ulcers

- Aphthous stomatitis
- Autoimmune blistering
  - Cicatricial pemphigoid
  - Dermatitis herpetiformis
  - Linear IgA bullous dermatosis
  - Pemphigus vulgaris
- Behçet's syndrome
- Cytotoxic drugs (e.g. methotrexate, 6-mercaptopurine)
- Epidermolysis bullosa
- Infections
  - Herpetic gingivostomatitis
  - Candidiasis
  - Herpangina
  - Hand-foot-and-mouth disease
  - Deep fungal infections
- Lichen planus
- Neoplasia carcinoma
- Nutritional deficiency
  - Noma
- Trauma
- Ulcerative colitis
- Vasculitis
  - Wegener's granulomatosis

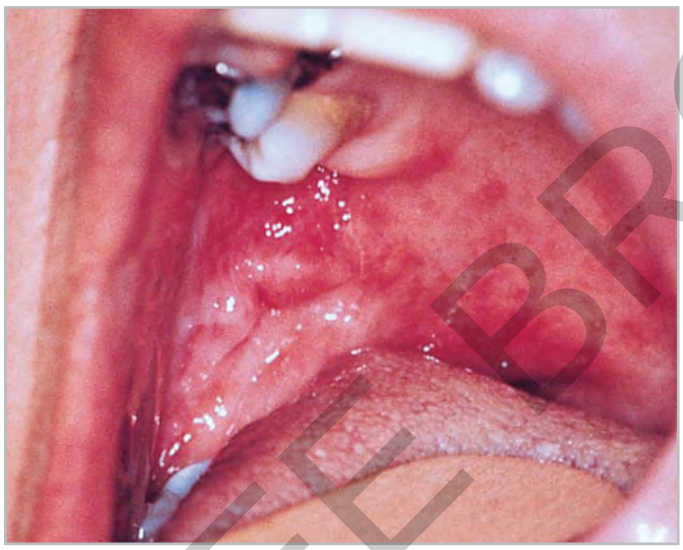

Figure 3.2.3 Pemphigus vulgaris. *Clue to diagnosis:* chronic unremitting oral ulcers.

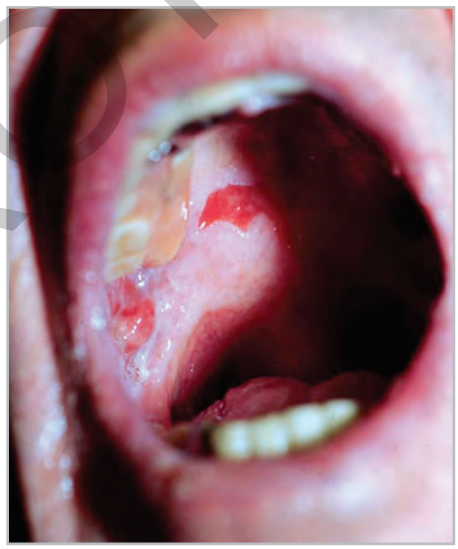

Figure 3.2.4 Pemphigus vulgaris.

JAYPEE BROTHERS

3. LICHEN PLANUS VERSUS LEUKOPLAKIA

Features in common: white mucosal lesions

Figure 3.3.1 Lichen planus.



Figure 3.3.2 Leukoplakia.



Distinguishing features

	Lichen planus	Leukoplakia
Physical examination Morphology	White reticulated plaque Erosions/ulcers commonly present	Localized white patch/plaque Lesions may be small or large Ulcers only after long-standing duration or trauma Lesions become leathery and thick with time Erythematous speckled or warty appearance in premalignant lesions
Distribution	Buccal mucosa, tongue, gingiva, palate, lips	Buccal mucosa, retrocommissural mucosa, alveolar ridge, tongue, hard palate, rarely sublingual area and gingiva
History Symptoms	Not related to tobacco products Asymptomatic or painful if ulcerated	Smokers or tobacco chewers Asymptomatic
Exacerbating factors	Iatrogenic: antimalarials, quinidine, β-blockers, diuretics, hypoglycemic agents Dental amalgams	None
Associated findings	Violaceous papules and plaques on wrists, ankles, elsewhere in half of patients Nail dystrophy	Squamous cell carcinoma Occasionally poor dental hygiene
Epidemiology	Men and women	Predominantly men
Biopsy	Occasionally Lichenoid infiltrate, sawtoothing of epithelium, hypergranulosis	Yes Epithelial acanthosis with varying amounts of dysplasia
Laboratory	None	Occasionally candida overgrowth found on potassium hydroxide test
Outcome	Chronic disease	May regress upon stopping tobacco use or may develop into squamous cell carcinoma

JAYPEE BROTHERS

Differential diagnosis of white oral plaques (leukoplakia)

Common causes
- Cheek biting (morsicatio buccarum)
- Fordyce's spots
- Lichen planus
- Oral candidiasis
- Oral hairy leukoplakia
- Nicotine stomatitis
- Squamous cell carcinoma or dysplasia

Rarer causes
- White sponge nevus
- Oral florid papillomatosis
- Focal epithelial hyperplasia
- Leukoedema
- Mucous patch of syphilis
- White patches of genodermatosis:
- Darier's disease, pachyonychia congenita, dyskeratosis congenita



Figure 3.3.3 Squamous cell carcinoma arising within a plaque of leukoplakia. Clue to diagnosis: crusted nodule and erythema within an area of leukoplakia.



Figure 3.3.4 Squamous cell carcinoma of the tongue arising in leukoplakia.

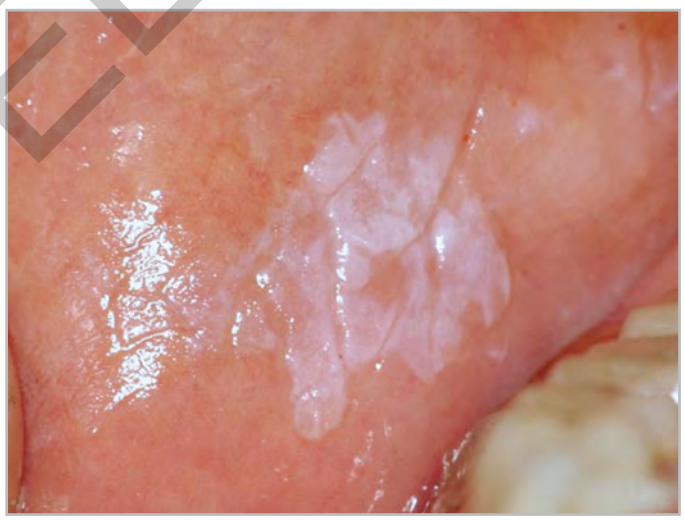

Figure 3.3.5 Leukoplakia.

JAYPEE BROTHERS

4. HERPES STOMATITIS VERSUS ERYTHEMA MULTIFORME

Features in common: oral erosions and vesicles

Figure 3.4.1 Herpes stomatitis.



Figure 3.4.2 Erythema multiforme.



Distinguishing features

	Herpetic gingivostomatitis	Erythema multiforme
Physical examination		
Morphology	Generalized mucosal grouped vesicles and erosions Scalloped border may be present	Generalized erosions and ulcers with pseudomembrane formation No scalloped border
Distribution	Entire oral mucosa in primary infection Other mucosal surfaces not involved No target lesions Localized lymphadenopathy	Entire oral mucosa Involvement of other mucosal surface common (eyes, nose) Targetoid lesions on skin Generalized lymphadenopathy
History	History of exposure to herpes virus 2 – 10 days previously (in some cases)	Occasional prodromal upper respiratory tract infection Ingestion of new medication
Symptoms	Fevers, malaise commonly present Cannot eat or drink Pain and discomfort	Fever rarely, presents more commonly with prodrome, malaise Cannot eat or drink Pain and discomfort
Exacerbating factors	Immunosuppression	None
Associated findings	None	Over 50 reported associations including the following: Infections: *Mycoplasma pneumoniae*, herpes simplex Most common medications: nonsteroidal anti-inflammatory agents, antibiotics, barbiturates Rarely associated with neoplasm or connective tissue disease
Epidemiology	Primarily involves children	Primarily involves young adults aged 20–40 years
Biopsy	No Ballooning necrosis of epidermis Multinucleated giant cells within epidermal vesicles	Occasionally Necrotic keratinocytes with areas of epidermal necrosis, interface lymphocytic dermatitis
Laboratory	Positive culture for herpes simplex Tzanck preparation: multinucleated giant cells	Chest X-ray if pulmonary symptoms Tzanck test and culture negative unless secondary to herpes infection
Outcome	Good Resolves over 1–2 weeks No scarring	Usually good Resolves over 4–6 weeks May have residual scarring Eye involvement may lead to blindness Occasionally fatal due to secondary sepsis

JAYPEE BROTHERS

Differential diagnosis of erosive oral disease

- Aphthous stomatitis
- Autoimmune blistering
  - Cicatricial pemphigoid
  - Dermatitis herpetiformis
  - Linear IgA bullous dermatosis
  - Pemphigus vulgaris
- Behçet's syndrome
- Cytotoxic drugs (e.g. methotrexate, 6-mercaptopurine)
- Epidermolysis bullosa
- Infections
  - Herpetic gingivostomatitis
  - Candidiasis
  - Herpangina
  - Hand-foot-and-mouth disease
  - Deep fungal infections
- Lichen planus
- Neoplasia carcinoma
- Nutritional deficiency
  - Noma
- Trauma
- Ulcerative colitis
- Vasculitis
  - Wegener's granulomatosis



Figure 3.4.3 Erythema multiforme. *Clue to diagnosis:* involvement of other mucosal skin.

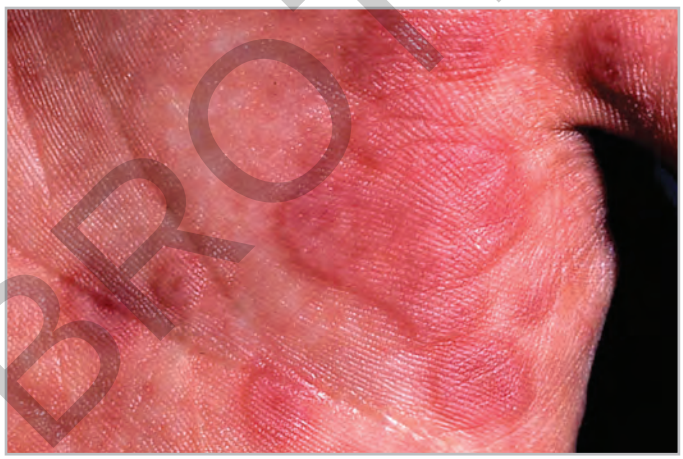

Figure 3.4.4 Erythema multiforme. *Clue to diagnosis:* targetoid lesions on palms.



Figure 3.4.5 Herpes infection in a patient with AIDS.



Figure 3.4.6 Herpes labialis. Resolving herpes labialis. Note scalloped borders.

JAYPEE BROTHERS

5. LOCALIZED LESIONS



Figure 3.5.1 Oral hairy leukoplakia.

6. GENERALIZED PREDOMINANTLY WHITE PATCHES/PLAQUES



Figure 3.6.1 White atrophic plaques of lupus erythematosus.

JAYPEE BROTHERS

7. GENERALIZED EROSIVE/ULCERATIVE MUCOSAL LESIONS

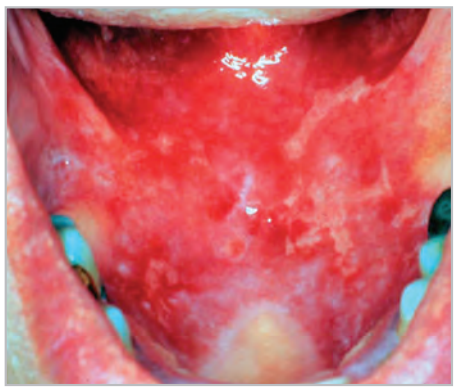

Figure 3.7.1 Cicatricial pemphigoid.



Figure 3.7.2 Desquamative gingivitis secondary to cicatricial pemphigoid. Other causes of desquamative gingivitis includes lichen planus and pemphigus.



Figure 3.7.3 Hand-foot-and-mouth disease.

8. OTHER EXAMPLES



Figure 3.8.1 Geographic tongue.



Figure 3.8.2 Gingival hyperplasia secondary to Dilantin. Other drugs that can produce gingival hyperplasia include cyclosporine and calcium channel blockers.



Figure 3.8.3 Mucosa hyperpigmentation secondary to minocycline.



Figure 3.8.4 Black hairy tongue (lingua nigra).

JAYPEE BROTHERS

DISEASE DISCUSSION

Apthous stomatitis

Definition and etiology

Recurrent aphthous stomatitis, commonly called a canker sore, is an ulcerative disease of the oral mucosa of unknown cause.

Clinical features

Aphthous ulcers are the most common ulcerative disease of the oral mucosa. Twenty percent of the general population may suffer from aphthous ulcerations at some time in their lives.

Patients with aphthous ulcers commonly experience a tingling or burning sensation at the site of the initial lesions. The ulcers are most commonly seen on the buccal mucosa but can also involve the lips, tongue, soft palate, and oropharynx. Morphologically, aphthous ulcers can be classified as minor, major, or herpetiform lesions. Minor aphthae, the most common form, are characterized by small ulcers a few millimeters in size covered with a yellow scab and surrounded by erythema. The lesions usually heal without scarring in 7–10 days, but recurrences are common. Major aphthous ulcers (Sutton's disease) have a similar appearance to minor aphthae; however, they are a few centimeters in size and persist up to one month. Scarring can also occur. In patients with the herpetiform variant, small, grouped popular vesicles that coalesce into a larger plaque are present. Herpes culture is negative.

The differential diagnosis includes other ulcerating diseases such as herpes simplex stomatitis and pemphigus vulgaris. Herpes gingival stomatitis usually involves children. Skin involvement is not seen, and the lesions have a characteristic grouped appearance. The herpetiform variant of aphthous ulcers can be distinguished only by means of culture or skin biopsy; however, herpes gingivostomatitis, unlike herpes labialis, is usually not a recurrent disease. Autoimmune blistering diseases such as pemphigus vulgaris and cicatricial pemphigoid usually are chronic, not recurrent. In both pemphigus vulgaris and cicatricial pemphigoid, skin involvement can occur. In cicatricial pemphigoid, conjunctival, nasal, or pharyngeal involvement occurs in a majority of patients. Other causes of oral ulcers (such as medications, a nutritional deficiency state, or inflammatory bowel disease) can usually be excluded based upon the history.

Treatment (Table 3.1)

Since the ulcers in aphthous stomatitis are usually self limited, treatment is usually only palliative. Hot, spicy, and acidic foods should be avoided. Topical anesthetics can provide temporary relief from the pain but also numb the taste buds resulting in tasteless dining. Topical steroids are also frequently prescribed. For severe cases systemic treatment is necessary.

Table 3.1 Treatment of aphthous stomatitis

Treatment	Precautions
Mild/moderate disease	
Fluocinonide gel 0.05%, triamcinolone in benzocaine 20% paste (Orabase) qid	Secondary *Candida* infection (thrush)
Dyclonine hydrochloride solution 1% prn	Loss of taste
Lidocaine jelly 2% prn	Loss of taste
Severe disease	
Intralesional triamcinolone 10 g/mL	
Prednisone: start at 40–60 mg/day and taper	Avoid long term – hyperglycemia, insomnia, hypertension, fluid retention, infection, osteoporosis
Colchicine 0.6 mg daily or bid	Gastrointestinal – nausea, vomiting, diarrhea, myelosuppression
Pentoxifylline 400 mg tid	Renal or hepatic impairment

Oral candidiasis

Definition and etiology

Oral candidiasis, also known as oral thrush or acute pseudomembranous candidiasis, is infection of the oropharyngeal cavity with *Candida albicans*, a yeast.

Clinical features

Oral candidiasis can be seen in any age group. Candidiasis starts as small, white, droplike macules and papules on the buccal mucosa, tongue, gingiva, palate, and pharynx. The lesions have been described as resembling milk curds or cottage cheese. With time and in severe cases, large plaques with pseudomembranes, erosions, or ulcers may develop. The base and surrounding mucosa are often erythematous.

Other diseases with white plaques include morsicatio buccarum (cheek biting), lichen planus, leukoplakia, leukoedema, oral florid papillomatosis, white sponge nevus, and squamous cell carcinoma. Unlike in the other diseases, the white plaques in candidiasis usually are easily rubbed off. In morsicatio buccarum, white plaques are produced owing to chronic cheek biting of the buccal mucosa, and white patches are oriented parallel to the gum line. Leukoedema is an idiopathic, asymptomatic swelling of the oral mucosa and lips. The diffuse white discoloration of the mucosa disappears upon stretching the skin. White sponge nevus is an autosomal dominant disease in which white patches are found mainly on the buccal mucosa. In oral florid papillomatosis, a cancerous condition of the oral cavity caused by a papillomavirus infection, localized white papillomatous cauliflower-like vegetations are seen on the buccal mucosa. In lichen planus (discussed in greater detail later in this chapter), the white plaques are arranged in a reticular and lacelike pattern. Finally, in both leukoplakia and squamous cell carcinoma, localized white plaques are found. The plaques may ulcerate or may have a vegetative appearance.

Oral candidiasis is commonly seen in newborns and infants when the mucosa becomes colonized by yeast from the mother's birth canal. In children and adults, oral candidiasis is commonly secondary to underlying systemic disease or is iatrogenically produced. Some common systemic diseases associated with candidiasis include endocrine disorders (diabetes, hypoparathyroidism, hypothyroidism), immune deficiencies (human immunodeficiency virus infection, acquired immunodeficiency syndrome), nutritional deficiencies, and malignancies. Iatrogenic factors include broad-spectrum antibiotics, corticosteroid therapy, immunosuppressive agents, cytotoxic agents, dentures, and other prostheses.

Treatment (Table 3.2)

The first caveat of treatment is to identify and, when possible, eliminate any predisposing factors. The next step is to eliminate the causative organisms by using either topical or systemic therapy. Topically, a 2- to

JAYPEE BROTHERS

DIFFERENTIAL DIAGNOSIS IN DERMATOLOGY

SECOND EDITION

Differential Diagnosis in Dermatology, Second Edition is a unique resource designed to help clinicians who treat skin disease by guiding them through a series of algorithms and 'compare and contrast' tables to reach an accurate diagnosis.

The book is arranged into three sections – localized rashes, generalized rashes, and neoplasms – and then into chapters devoted to a particular region, morphologic appearance or pathology.

Each chapter opens with a diagnostic algorithm that guides the reader through the likely causes of the patient's lesion. Tables, lists and clinical photographs are then used to compare the signs of frequently encountered diseases and narrow down the differential diagnosis. Finally, short sections describe the etiology, clinical features and therapy for the clinically most important differentials.

Fully updated, this edition has also been expanded to include not only discussions of therapy but also a new self-assessment chapter. *Differential Diagnosis in Dermatology*, Second Edition offers a logical and easy to use system to help dermatologists and primary care physicians who wish to optimize the care of their patients.

- Highly structured format leads the clinician from identifying lesion morphology to management of the underlying condition
- Extensively illustrated with diagnostic algorithms, 'compare and contrast' photographs and tables to help the clinician reach an accurate diagnosis
- New self-assessment chapter allows the reader to test their ability to recognize physical signs in dermatology

JP medical publishers

www.jpmedpub.com

ISBN 978-1-909836-19-8

9 781909 836198