

FEMALE INFERTILITY

CORE PRINCIPLES AND CLINICAL MANAGEMENT

Bryan Woodward
Jayant Mehta

Contents

Preface v

Contributors ix

Chapter 1
Anatomy and physiology 1
Fidelis T Akagbosu

Chapter 2
Investigation of female infertility in primary care 9
Corinne Hargreaves, Jayant Mehta

Chapter 3
Investigations in secondary care 19
Sara Rodríguez López, Masoud Afnan

Chapter 4
Pre-conceptual nutrition and health 27
Melanie Brown

Chapter 5
Ovarian reserve and anti-Müllerian hormone 37
Stamatina Iliodromiti, Scott M Nelson

Chapter 6
Polycystic ovary syndrome 47
Roy Homburg

Chapter 7
Endometriosis 53
Simone Ferrero, Annalisa Racca, Umberto Leone Roberti Maggiore

Chapter 8
Drug-induced ovulation 61
Kieren Wilson, William Ledger

Chapter 9
The human oocyte: characteristics, collection and fertilization 65
Bryan Woodward

Chapter 10
Oocyte donation 75
Maria Jesus López, Juan José Guillén, Rita Vassena, Amelia Rodriguez Aranda

Chapter 11
Implantation 85
Mariano Mascarenhas, Mohan S Kamath, Sesh Kamal Sunkara

Chapter 12
Surrogacy – a method of family building 91
Wendy Norton

Chapter 13
Support and counseling 99
Susan Seenan, Kate Brian

Chapter 14
Management of early pregnancy 105
Karen Sohan

Chapter 15
Management of genetic disorders 111
Semra Kahraman, Caroline Pirkevi

Chapter 16
Noninvasive prenatal testing 123
Kathryn Sanders, Tony Gordon

Chapter 17
Deriving oocytes from stem cells 129
Gustavo Tiscornia, Montserrat Barragán, Rita Vassena

Chapter 18
Mitochondrial DNA disease 137
Louise Hyslop

Chapter 19
Uterine transplantation 143
Benjamin P Jones, Srdjan Saso, J Richard Smith

Chapter 20
Fertility preservation: oocytes 151
Greta Verheyen, Ingrid Segers, Neelke De Munck, Dominic Stoop, Michel De Vos

Index 159

Chapter 3 Investigations in secondary care

Sara Rodríguez López, Masoud Afnan

INTRODUCTION

An estimated 1 in 7 couples seek medical advice for difficulties conceiving.[1]

The aim of investigations in secondary care is to quickly and accurately categorize patients into the correct diagnosis group. The clinician can then provide clear guidance on the chances of conceiving and on treatment options available, with the risks and benefits of each one made clear. Only then can an informed decision be made about how to proceed.

Many people will seek medical advice early on in their quest for a child. Consequently, background pregnancy rates are reasonably high, even in patients waiting for procedures such as in vitro fertilization (IVF). Furthermore, up to 40% of couples will not proceed with any additional treatment after the female has undergone hysterosalpingogram (HSG). It is therefore important to consider the costs and invasiveness (in terms of risks) of the initial investigations.[2]

Whilst this book focuses on female infertility for heterosexual couples it is important to consider the couple as a whole obtaining semen analysis results early on will often guide the diagnostic and therapeutic plan. For example, if the man has severe oligozoospermia, an option for the couple is intracytoplasmic sperm injection (ICSI), and the investigations will be geared to optimizing outcomes from that treatment.

Even if a cause is clearly identified in one partner, there may be a problem with the fertility of the other partner too. This is because approximately a quarter of couples will have borderline problems in both partners (odds multiply, so significantly decreasing the chances of pregnancy). Of the remaining three quarters, it is estimated that one quarter of couples will have male factor, one quarter female factor and one quarter unexplained infertility, with no obvious cause.

In the case of the female partner, basic investigations in secondary infertility care will involve three major areas: tubal patency, uterine cavity and ovulation. In the past, fertility specialists looked for cervical factors, for example by doing a postcoital test, or did repeated follicle tracking or performed tests on the semen, such as antisperm antibodies. However, questions have been raised regarding the reliability and cost-effectiveness of these tests, and whether the results alter management. They have therefore fallen out of favor and are no longer routinely carried out.

CHECKING THE FALLOPIAN TUBES

Tubal disease accounts for 20–25% of all female infertility, with pelvic inflammatory disease (PID) the most common cause (**Table 3.1**). PID is often asymptomatic, and a common cause is due to a sexually transmitted infection (STI) such as *Chlamydia trachomatis* infection.[3,4] Another important infection to consider is gonorrhea

Table 3.1 Sexually transmitted infections that can cause pelvic inflammatory disease (PID) and tubal blockage

Disease	Examples	Organism	Prevalence	Treatment
Chlamydia	*Chlamydia trachomatis*	Bacteria	>20% in sexually active men and women aged <24 years	Azithromycin: 1 g orally in a single dose or doxycycline: 100 mg orally twice a day for 7 days
Gonorrhea	*Neisseria gonorrhoeae*	Bacteria	0.6% per 100,000 men and women between the ages of 20–24 in the USA (2016)	Centre for Disease Control (USA) recommends dual therapy, or using two drugs, to treat gonorrhea – a single dose of 250 mg of intramuscular ceftriaxone and 1 g of oral azithromycin
Syphilis	*Treponema pallidum*	Bacteria	9.5 cases per 100,000 population in the USA (2017). Men account for most cases of syphilis, with the majority of cases occurring among men who have sex with men (MSM)	A single intramuscular injection of long-acting benzathine penicillin G (2.4 million units administered intramuscularly) will cure a person who has primary, secondary or early latent syphilis. Three doses of long-acting benzathine penicillin G (2.4 million units administered intramuscularly) at weekly intervals is recommended for individuals with late latent syphilis or latent syphilis of unknown duration. Treatment will kill the syphilis bacterium and prevent further damage, but it will not repair damage already done
Mycoplasma	*Ureaplasma urealyticum Mycoplasma genitalium*	Mycoplasma	10–30% in women with clinical cervicitis	1 g single dose of azithromycin is significantly more effective against *Mycoplasma genitalium*
Tuberculosis	*Mycobacterium tuberculosis*	Bacteria	2.8 cases per 100,000 population in the USA (2017). Tuberculosis (TB) can cause latent TB infection and TB disease. If not adequately treated, TB disease can be fatal	Anti-tuberculous therapy, dependent on extent and area of infection

(*Neisseria gonorrhoeae*), with the reported incidence of this condition increasing.[5] The significance of mycoplasma (*Ureaplasma urealyticum*) is unclear. In developing countries tuberculosis must also be considered.

The other main cause for tubal infertility is previous pelvic pathology (e.g. peritonitis from a burst appendix), and pelvic surgery (e.g. ovarian cystectomy or tubal surgery for an ectopic pregnancy). Previous sterilization is also a significant cause, though less so nowadays, as there are many reliable, reversible methods of contraception on the market. A less common cause for tubal disease is endometriosis, which can cause scarring in the tubal wall (see Chapter 7).

Distal tubal blockage is the most common form of tubal disease, and is usually caused by PID or previous surgery. It is important to identify and treat distal tubal disease which has resulted in a hydrosalpinx (either with occlusion or salpingostomy), prior to IVF, as this untreated condition can halve pregnancy rates.[6]

Approximately 10-15% of the cases of tubal disease are due to proximal tubal blockage from different etiologies such as salpingitis isthmica nodosa (SIN), intraluminal fibrosis or endometriotic scarring in the muscle of the tube. Mucus plugs or spasm of the tube may also be responsible for apparent obstruction when assessing tubal patency.

There are three main techniques to assess tubal patency: hysterosalpingography (HSG), laparoscopy and ultrasound assessment using specially designed contrast agents.

Investigations for tubal patency

Hysterosalpingography

Hysterosalpingography is the most widely used procedure to check tubal patency, primarily because it is minimally invasive, and easily carried out in the outpatient setting (**Figure 3.1**). It is the preferred investigation for those patients without a known risk factor, such as known endometriosis, history of PID or previous ectopic pregnancy. A contrast medium is injected through the cervix into the uterine cavity to assess radiologically, the uterine cavity and the patency of fallopian tubes.

The HSG is a reliable test to exclude tubal disease, with a negative predictive value of 98%.[7,8] It has a positive predictive value of 54%, best when assessing proximal occlusion substantial for distal obstruction and hydrosalpinx and moderate to poor for adhesions.[7,8]

Hysterosalpingo sonography: contrast versus foam (HyCoSy versus HyFoSy)

Like HSG, HyCoSy and HyFoSy are minimally invasive procedures that allow the evaluation of the uterine cavity and tubal patency. Again like HSG, in HyCoSy a contrast saline-based medium is injected through the cervix to assess, in this case by ultrasound, the uterine cavity and the fallopian tubes. For HyFoSy, a hyperechogenic foam is used rather than a medium. HSG, HyCoSy and HyFoSy have comparable positive and negative predictive value, although many physicians prefer HSG on the grounds that it provides more details about the state of the fallopian tubes, such as mucosal patterns. Conversely, HyCoSy and HyFoSy are considered to have some advantages over HSG, as they have greater sensitivity and specificity for the detection of intrauterine pathologies, such as fibromas, polyps and synechiae in subfertile populations. At the same time they allow for assessment of the ovaries and myometrium.[9,10] Some consider that HyFoSY offers enhanced contrast visualization and enables clearer delineation of tubal anatomy. This may enhance confidence in the diagnosis of tubal patency, reduce false occlusion results, and improve the diagnostic yield of the test.[11]

Many clinics routinely performing an HSG may also offer a separate pelvic ultrasound.

In practice, the decision as to whether to do HSG or HyCoSy as a first-line uterine and tubal assessment will depend mainly on the expertise of and the facilities available to the physician.

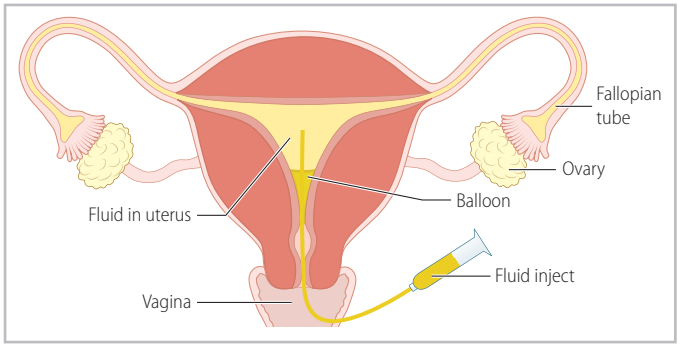

Figure 3.1 Hysterosalpingography.

Management of patients with abnormal HSG or HyCoSy

Laparoscopy and hydrotubation

Laparoscopy and hydrotubation require a general anesthetic and carry a risk of visceral injury so are not usually considered as first-line investigation for patients without a risk factor. The risk of serious complications is estimated 1 in 1,000. Furthermore, both HSG and HyCoSy/HyFoSY have a good negative predictive value. Laparoscopy is therefore only recommended for patients with suspected tubal disease in order to gain a more accurate diagnosis to guide management.[12]

Patient management is only changed in about 5% of the patients who receive a normal HSG result.[13]

Tubal disease

There are different treatment options for tubal disease management, depending on: the type of disease; whether there is complete occlusion; the patient's age; and other fertility parameters (e.g. duration of trying for a baby). Tubal disease can be treated via salpingectomy or IVF. Nowadays, however, IVF is the most commonly used fertility treatment if there is a tubal pathology, and consequently surgical expertise in tubal surgery has declined.

This is to be lamented, as in the right hands, and with good patient selection, excellent pregnancy rates can be achieved, and of course successive pregnancies can be safely and cheaply obtained, without further intervention.[14]

For apparent proximal tubal disease, selective salpingography is an excellent and simple outpatient diagnostic procedure, and if true blockage is identified, a guidewire and catheter are used to unblock the tube radiologically at the same time (Figure 3.2). The procedure can also be carried out hysteroscopically. Both treatments increase the chances of pregnancy depending on the extent of the underlying tubal damage.

Patients with distal tubal occlusion can either be treated via IVF or tubal surgery. In the case of unilateral hydrosalpinx, treatment of hydrosalpinx is recommended to maximise the chances of conceiving with a contralateral tube (**Figure 3.3**). With bilateral hydrosalpinges, both tubes should be treated before proceeding to IVF. If the tubes are too damaged, treatment should be via salpingectomy or tubal

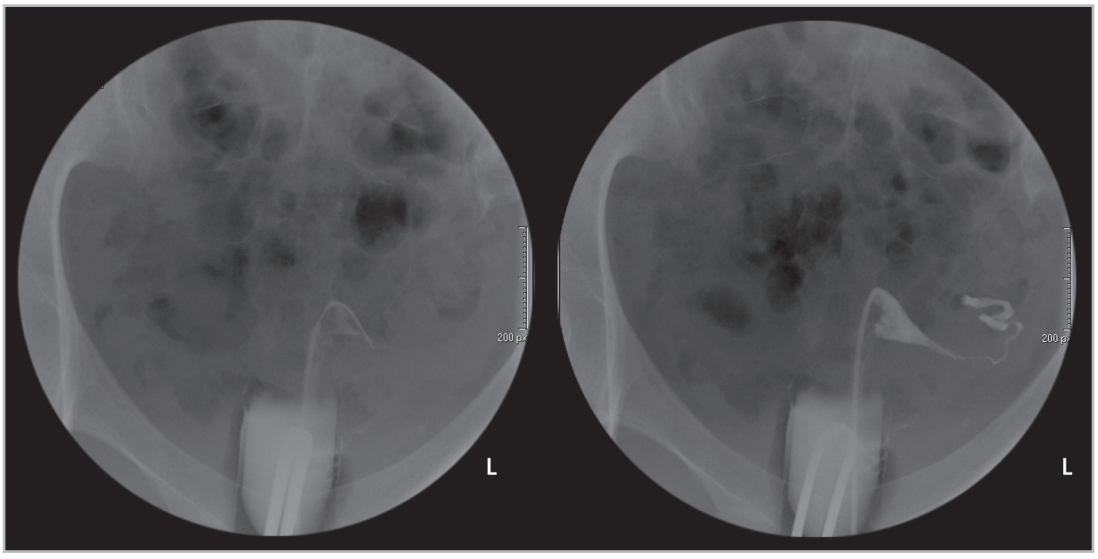

Figure 3.2 X-ray plate images during selective salpingography.

clipping, since there is good evidence that not doing so can halve the background pregnancy rates. This may be due to fluid from the hydrosalpinx draining back into the uterine cavity, which can make the environment toxic to embryo development and implantation.

A recent systematic review of salpingostomy, reported cumulative clinical pregnancy rates of 20% at 12 months after salpingostomy to treat hydrosalpinx.[15] However, there is a high risk of re-occlusion, so it is important to carefully evaluate the hydrosalpinx before undertaking salpingostomy. The risk of ectopic pregnancy following salpingostomy is also higher compared with IVF. If after 6–12 months of surgery pregnancy does not occur, IVF is indicated.

CHECKING THE UTERUS

The uterine cavity can be assessed as described above by HSG or HyCoSy/HyFoSy. In the absence of any significant clinical history of intrauterine procedures which might cause uterine synechiae, a plain transvaginal ultrasound to determine endometrial thickness and the absence of distortion of the endometrial lining can offer a satisfactory check. If a laparoscopy is being performed, then it is reasonable to simultaneously perform a diagnostic hysteroscopy to assess the cavity by direct visualization.

A pelvic ultrasound can often be used to detect uterine conditions such as the presence of fibroids; calcification in the myometrium which would indicate adenomyosis; and whether the patient has uterine malformations such as an arcuate uterus, a uterine septum, unicornuate or bicornuate uterus. Depending on the pathology, subsequent investigations to consider include a hysterosonogram (to check for submucosal fibroids) (**Figure 3.4**), an MRI (to determine the size and location of fibroids, and adenomyosis), or a laparoscopy and hysteroscopy. The latter provides a complete assessment of congenital anomalies, and in particular can be used to differentiate between a septate uterus and a bicornuate uterus. If intrauterine synechaie are suspected, then a diagnostic hysteroscopy can be performed, with the possibility to proceed at the same sitting to a hysteroscopic adhesiolysis.

Treatment of uterine fibroids, intrauterine synechiae or a significant uterine septum is generally via surgery. Arcuate uterus, bicornuate and unicornuate uterus do not usually benefit from treatment. There is no currently available therapy for adenomyosis.

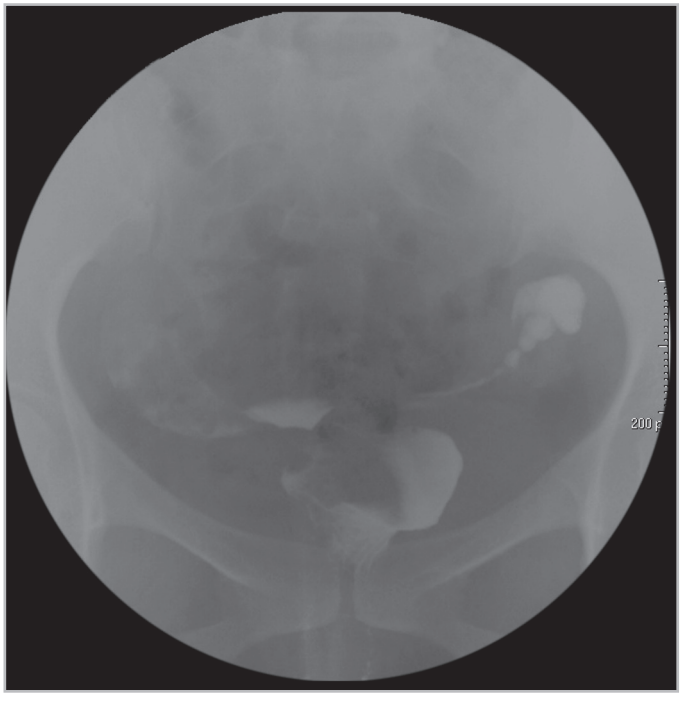

Figure 3.3 A hydrosalpinx.

Endometrial polyps are common, and may often resolve spontaneously as the endometrium is shed each month. In some cases they can persist, and if they measure over 2 cm in diameter may significantly affect the chances of conception. Between 1–2 cm in diameter, the impact is less certain, but it is reasonable to remove them if they persist. Polyps less than 1 cm in diameter are probably of little clinical significance. However, there remains a lack of clarity regarding the clinical significance of endometrial polyps. For example, endometrial polyps are highly prevalent in all types of abnormal uterine bleeding (AUB), yet they are also commonly found in women without AUB.[16]

It is important to consider the endometrial hyperplasia in patients with anovulation, and who have heavy frequent periods, which are



Figure 3.4 Evidence of submucosal fibroid on hysterosonogram.

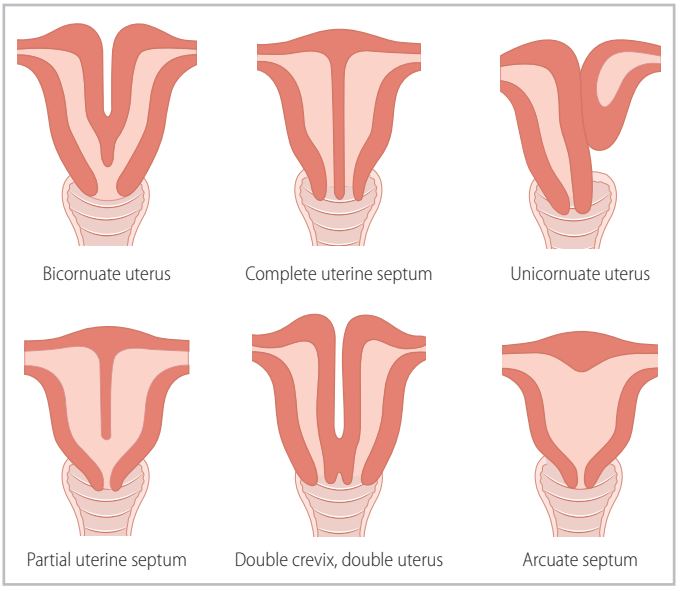

Figure 3.5 Failure of fusion of the Müllerian ducts.

indicative of high, unopposed estrogen stimulation of the endometrium. A proportion of women will have endometrial hyperplasia with atypia, which if left unchecked may progress to endometrial cancer.[17] Diagnosis is made by taking a sample of the endometrium using an endometrial sampler in the outpatient clinic.

Uterine malformations

Uterine malformations occur in about 4% of the population, with approximately the same prevalence amongst infertile women, though it is higher (10–20%) among women with recurrent miscarriage.[18] They occur either as a result of failure of fusion during fetal development (bicornuate or unicornuate uterus) or resorption (arcuate or septate uterus) of the Müllerian ducts (**Figure 3.5**). Consequences of uterine malformations may include altered vascularity; abnormal intrauterine pressure; decreased ability of the uterus to expand; cervical incompetence; and altered endometrial receptivity.

The commonest type of abnormality is the septate or arcuate uterus. Patients with these abnormalities have a higher (double) miscarriage rate, which appears to revert back to normal rates after hysteroscopic excision.[19] Unicornuate or bicornuate uterus may cause intrauterine growth retardation, fetal malposition and malpresentation later in the pregnancy. There is no useful treatment for these types of uterus. Neither type of abnormality is said to affect the chances of conception.

CHECKING THE CERVIX

The cervix is best assessed by physical examination, though occasionally cervical polyps can be observed on ultrasound and not visualized directly (**Figure 3.6**). The most common finding is a cervical ectropion, which is a physiological distal shifting of the squamocolumnar junction under estrogenic influence. This condition does not need to be treated, and does not affect chances of conception. Small cervical polyps will normally resolve on their own. Persistent polyps may be avulsed in the outpatient clinic. Cervical intraepithelial neoplasia should be treated prior to fertility treatment, and if excision cone biopsies are performed, may result if large or repeated, in cervical incompetence. Cervical treatment (such as excision, cautery, or laser) for premalignant cells on the cervix may also result in abnormal (reduced) cervical mucus, which might affect future fertility.

The 'tight' cervix will not cause infertility, but may make it difficult to pass a catheter for procedures such as HSG or embryo transfer.



Figure 3.6 Cervical polyp seen on transvaginal ultrasound.

Evaluation of the cervix can be performed before embarking on IVF treatment if a difficult embryo transfer is anticipated.

Consideration should be given to STIs, such as chlamydia and gonorrhea, which are harbored in the cervix in high risk women (under the age of 25 years), as instrumentation of the cervix may cause further spread of the infection. Such patients should either be screened or given prophylactic antibiotics.

Finally, the role of post-coital testing is controversial, with professional societies from different countries giving different assessments of its utility. This may be because of inconsistencies in how the post-coital test is performed, and the management of the patient with cervical factor and 'unexplained' infertility is the same (IUI or IVF).

CHECKING THE OVARIES

The ovaries are the primary organs of the female reproductive system. The importance of the ovary is not only as a gonad responsible for the production of oocytes, but also as a gland responsible for the secretion

of hormones such as estrogen and progesterone that have an essential role in the menstrual cycle.

The ovaries are whitish-colored organs laying on the ovarian fossa of the female pelvis on both side of the uterus; each ovary is connected to the uterus through the ovarian ligament and attached to the fallopian tubes (for a detailed description of the anatomy and physiology, see Chapter 1).

Checking morphology

Transvaginal ultrasound is the most common procedure to check ovarian morphology (see Figure 2.7), and to monitor follicular development through the menstrual cycle. As a follicle enlarges, it becomes more vascular; ovulation is followed by collapse of the follicle, and formation of the echogenic corpus hemorrhagicum and subsequently corpus luteum.

Ultrasound scans can help to identify abnormal cysts (**Table 3.2**), which can be functional (essentially, a follicle that has not developed normally, and which will normally resolve over time), to persistent cysts, which can be benign or malignant. One type of cyst is an ovarian endometrioma, which appears as an opaque cyst because it is filled with old blood.

Ultrasound can also identify the number of small antral follicles present in each ovary, which gives a measure of the ovarian reserve, and in the case of polycystic ovaries is increased (see Figure 2.7).

Luteal phase deficiency

Luteal phase deficiency (LPD) is a condition in which not enough progesterone is secreted, resulting in failure to develop normal secretory endometrium for embryo implantation and growth, whereby the luteal phase is shortened. However, a short luteal phase can occur in up to 5% of healthy fertile women, and there is no significant increase seen among sub-fertile women.[20]

Abnormal luteal function may occur as a result of underlying abnormal thyroid function, so women with a short luteal phase should be investigated for this. As women near the menopause, the luteal phase often becomes shorter. Obesity and anorexia have also been implicated.

Repeated luteal progesterone level tests and endometrial biopsies have been used to diagnose LPD, however, the validity of these tests has been questioned.

While progesterone is important for implantation and maintenance of early pregnancy, no treatment for luteal phase insufficiency has been shown to improve pregnancy outcomes in natural, unstimulated cycles. The treatment options for patients with suspected LPD are the same as for those patients with unexplained infertility, therefore efforts to diagnose LPD are not currently justified.[21,22]

ANOVULATION

Ovulatory disorders (anovulation or infrequent ovulation) are responsible for approximately 20–25% of female infertility. A normal menstrual cycle relies upon normal ovarian cycle, with a coordinated shedding of the endometrium at the end of the luteal phase. In the absence of normal ovulation, the patient will have irregular cycles. The pattern of bleeding will reflect the patient's baseline estrogen levels.

If the patient has no periods, her estrogen level will be very low whereas infrequent periods (oligomenorrhea) are usually associated with slightly higher estrogen level that tend to oscillate: if the level is above the threshold, this causes some proliferative changes in the endometrium. If the level is below the threshold, this causes a withdrawal bleed. Heavy, frequent periods reflect high estrogen levels which act unopposed (by progesterone) on the endometrium, causing endometrial proliferation until the point when it cannot maintain its own architecture and the endometrium breaks down in an uncoordinated way.

As well as considering fertility implications, it is important to consider other health-related issues such as consequences of prolonged hypoestrogenism on the cardiovascular and skeletal symptoms; the effect of prolonged, unopposed hyperestrogenism and the risk of developing endometrial cancer and anemia from heavy frequent periods.

Types of anovulation

The World Health Organization (WHO) classifies anovulation into 3 groups (**Table 3.3**):

WHO I hypogonadotropic-hypogonadism

This group accounts for 10% of anovulatory disorders. Selective failure of the pituitary gland affects the production of luteinizing hormone (LH) and follicle-stimulating hormone (FSH). The most common cause is hypothalamic amenorrhea due to anorexia nervosa or excessive exercise. Other causes include pituitary microadenoma or prolactinoma, as prolactin suppresses the secretion of gonadotropin-releasing hormone (GnRH) from the hypothalamus. These patients may experience other symptoms such as galactorrhea, headaches and visual field disturbances.

Rare causes include infarction of the anterior pituitary, such as Sheehan's syndrome, or congenital conditions causing hypopituitarism

Table 3.2 Types of ovarian cysts

Cyst	Cause
Corpus luteum cysts	Post-ovulation, the corpus luteum closes prematurely causing fluid to accumulate
Hemorrhagic cyst	Blood fills the follicle/corpus luteum, possibly causing pain
Follicular cysts	If the luteinizing hormone surge does not cause ovulation, the follicle retains clear fluid
Cystadenomas	An epithelium-lined cyst derived from ovarian tissue containing secretory material. Can be either serous (containing clear fluid) or mucinous (usually benign, with mucin-containing cavities)
Dermoid cysts	Develops from totipotent germ cells which proliferate, forming different types of tissue and structures, e.g. hair and teeth. Large cysts may cause ovarian torsion. Require surgical removal
Endometrioma / 'chocolate cysts'	Endometriotic tissue inside the ovary causes blood-filled cysts, which become viscous and brown. Cyst rupture causes pelvic pain and induce adhesions
Multiple cysts – polycystic ovaries	Polycystic ovary syndrome causes many small cysts to form on the periphery of the ovary

Table 3.3 Anovulation. The World Health Organization (WHO) provides a practical classification of anovulatory states into three groups (I, II and II) based on gonadotropin secretion

Hormone	WHO I Hypothalamic – pituitary failure	WHO I Hyper-prolactinemia	WHO II PCOS	WHO II Ovulatory dysfunction	WHO III Ovarian failure
Follicle-stimulating hormone	Very low	Normal or low	Normal	Normal	Very high
Luteinizing hormone	Very low	Normal or low	High	Normal	Very high
Prolactin	Normal	High	Normal	Normal	Normal
Thyroid-stimulating hormone	Normal	Normal or high	Normal	Normal	Normal
Testosterone	Normal	Normal	High	Normal	Normal
Anti-Müllerian hormone	Normal	Normal	High	Normal	Very low

including Kallmann's, Prader-Willi and Laurence-Moon-Biedl syndromes. These patients have estrogen levels in the postmenopausal range, with normal to low FSH levels and normal prolactin levels.

WHO II normogonadotropic, normogonadism

This group accounts for 85% of ovulatory disorders and includes patients with polycystic ovary syndrome (PCOS). Approximately 80% of oligomenorrheic and 30% of those with amenorrhea have polycystic ovaries.[23]

The primary anomaly is failure of small antral follicles to respond to normal concentrations of FSH, and therefore follicle recruitment and ovulation rarely take place. This results in a large number of small antral androgen-dominated follicles. In addition to irregular periods, PCOS patients may present with signs of androgen excess, such as hirsutism and acne. In addition, at least a third will be overweight.

PCOS is an endocrine disorder that affects 15–20% of women of fertile age. It is the commonest cause of amenorrhea and oligomenorrhea.

The symptoms are variable but some of the most common clinical manifestations are irregular or absent cycles, hirsutism, acne, insulin resistance, obesity and infertility. 80–90% of women presenting with oligomenorrhea have PCOS; on the other hand, 30% of PCOS patient will have normal cycles.[24]

According to the European Society of Human Reproduction and Embryology (ESHRE) and American Society for Reproductive Medicine (ASRM), to diagnose PCOS, two out of three criteria should be present:

- Oligo- and/or anovulation (cycle >35 days)
- Clinical and/or biochemical signs of hyperandrogenism
- Polycystic ovary morphology (12 or more follicles and/or ovarian volume of >10 mL) in at least one ovary[25]

More recent studies suggest that the threshold of 12 follicles is insufficient to distinguish PCOS patients from healthy women and propose a substantially higher threshold of 26 follicles.[26]

WHO III hypergonadotropic hypogonadism

This group accounts for 5% of anovulatory disorders and includes patients with premature ovarian failure. These patients present with elevated FSH and LH and postmenopausal levels of estrogen. Many cases are of unknown origin, but some will have sex chromosome abnormalities such as Turner syndrome, metabolic disorders such as hypergalactosemia, or be autoimmune in origin.

Women are born with a predetermined number of primordial follicles; this number reaches a peak before the birth, at 20 weeks of gestation, and starts decreasing from then. At the time women reach puberty only around 5% of primordial follicles remain; menopause occurs when all the follicles are exhausted.

Premature ovarian insufficiency (POI), is defined by the presence of oligoamenorrhea for at least 4 months and two determinations of FSH in the menopausal range (at least 1 month apart) in women younger than 40 years.

POI can be caused by follicle depletion or dysfunction (also known as resistant ovary syndrome) when even though there are follicles, they do not function normally. The cause is often unknown (90%), but may be due to ovarian autoimmunity, G protein mutation, enzyme deficiency or a defect on the signal receptor of FSH or LH.[27]

Genetic testing such as a karyotype analysis or testing for an *FMR1* premutation, which is responsible for fragile X syndrome (FXS), may be helpful to identify a cause, but usually does not alter management. It is reasonable to screen for autoimmune conditions in other endocrine glands such as the thyroid or adrenal, in order to check for early disease.

Treatment options

Women with amenorrhea (absence of periods), or oligomenorrhea (irregular cycles/ >35 days cycles) should be fully investigated to understand which type of anovulation they are suffering from in order to better recommend treatment options.

WHO anovulation group 1

The appropriate treatment to achieve ovulation for patients with anovulatory disorders will depend on the etiology of anovulation. For WHO I group patients, normalisation of weight or decreasing exercise may help women to resume periods. Alternatively, treatment with pulsatile administration of GnRH can be considered if the pituitary is intact, or gonadotropins can be used directly. Both LH and FSH stimulation is necessary for normal steroidogenesis.

For women with hyperprolactinemia, medical treatment with dopamine agonists, such as bromocriptine, cabergoline or quinagolide restores ovulation.

WHO anovulation group 2

In those PCOS patients presenting with obesity, weight loss should be recommended before starting treatment, not only because weight loss improves fertility and obstetric outcomes but also because obese women require more stimulation to achieve ovulation.[28]

The first-line of treatment for PCOS is oral ovulation induction (OI). Clomiphene citrate (CC) has for many years been the initial of treatment for PCOS. CC is an antiestrogen which binds to estrogen receptors, blocking the negative feedback to the hypothalamus, and therefore increasing the production of gonadotropins, particularly FSH, leading to follicle recruitment and ovulation (see Figure 6.1).

Recently, letrozole has been shown to produce better outcomes, with higher ovulation and pregnancy rates. Letrozole is an aromatase inhibitor that reduces oestradiol production by diminishing the androgen conversion to estradiol in the granulosa cell. Consequently, there is less negative feedback on the hypothalamic-pituitary axis, so FSH stimulation of the follicle is increased. Legro and colleagues reported cumulative live birth rates of 27.5% in patients with letrozole compared with 19.1% in those patients on CC.[29] It is hypothesized that letrozole has better results because of the negative effect of CC on the endometrium and cervical mucus.

For those who do ovulate with OI but fail to achieve a pregnancy after 6 months of treatment, OI and IUI may be offered.

For those who fail to ovulate with oral OI, injectable gonadotropin (hMG or FSH) can be used to stimulate follicular development. This requires close follicle monitoring as it carries a high risk (16%) of multiple births and a 1% risk of ovarian hyperstimulation syndrome.[30]

Ovarian drilling is a procedure performed by laparoscopy that involves the creation of small holes with diathermy, which appears to trigger ovulation. For those patients that fail to ovulate on CC or letrozole, diathermy ovarian drilling may be offered as a treatment option. Ovulation rates of up to 80% have been reported, with the effect lasting up to 2 years. Of significance, as there is no external ovulation induction, these are usually single ovulatory cycles.

Finally, IVF is an option for patients who do not conceive with the treatment strategies outlined above.

WHO anovulation group 3

For anovulatory women due to a premature ovarian failure or who are perimenopausal, OI is not recommended and the most appropriate treatment is donor oocytes.

As well as the emotional impact for women diagnosed with POI, there are many other health issues to consider such as low bone density and higher risk of heart disease because of the prolonged estradiol deficiency. Therefore, hormone replacement therapy (HRT) should be offer to women suffering POI.

Unexpected pregnancies have been reported in 5–10% of patients diagnosed with POI.[27] For patients who actively wish to achieve conception, oocyte donation is the only treatment option that should be offered.

CONCLUSION

Management of the infertile couple has been revolutionized in the last 25 years by the advent of IVF and ART. In place of extensive, detailed, repeated diagnostic assessments, we are now able to offer rapid diagnostic assessment within a single menstrual cycle to categorize patients into a diagnostic group and subsequently offer effective treatment. Simpler, more cost-effective treatment options should be offered where possible, resorting to IVF treatment as an effective final step. Much of the focus in infertility investigation research therefore has been to ensure the effectiveness of the diagnostic process, reduce waste and reduce costs. This has largely been achieved. Future work will be directed to the social trend of delayed childbearing, and the implications for the chances of conception.

At every step of the diagnostic process, the competent physician should be able to discuss with their patients the increased likelihood of conceiving, in percentage terms. This patient-centerd, patient-informed approach will do much to ensure only appropriate investigations are conducted.

REFERENCES

1. Leaver RB. Male infertility: an overview of causes and treatment options. Br J Nurs 2016; 25:S35–S40.
2. Duthie EA, Cooper A, Davis JB, et al. A conceptual framework for patient-centered fertility treatment. Reprod Health 2017; 14:114
3. Rogstad K. Complications in the female and their management. In: Moss T (Ed.) International handbook of Chlamydia, 3rd edn. Alden Press, Haslemere, UK 2008:111–121.
4. Peipert JF. Clinical practice. Genital chlamydial infections. N Engl J Med 2003; 349:2424–2430.
5. Suay-García B, Pérez-Gracia MT. Drug-resistant Neisseria gonorrhoeae: latest developments. Eur J Clin Microbiol Infect Dis 2017; 36:1065–1071.
6. Strandell A, Lindhard A, Waldenstrom U, Thorburn J. Hydrosalpinx and IVF outcome: cumulative results after salpingectomy in a randomized controlled trial. Hum Reprod 2001; 16:2403–2410.
7. Berker B, Şükür YE, Aytaç R, et al. Infertility work-up: To what degree does laparoscopy change the management strategy based on hysterosalpingography findings? J Obstet Gynaecol Res 2015; 41:1785–1790.
8. Papaioannou S, Bourdrez P, Varma R. Tubal evaluation in the investigation of subfertility: A structured comparison of test. BJOG 2004; 111:1313–1321
9. Papaioannou S, Bourdrez P, Varma R, et al. Tubal evaluation in the investigation of subfertility: a structured comparison of tests. BJOG 2004; 111:1313-1321.
10. Saunders RD, Shwayder JM, Nakajima ST. Current methods of tubal patency assessment. Fertil Steril 2011; 95:2171–2179.
11. Rajesh H, Lim SL, Yu SL. Hysterosalpingo-foam sonography: patient selection and perspectives. Int J Womens Health 2016; 9:23–32.
12. National Institute for Health and Care Excellence (NICE). Fertility problems: assessment and treatment. London: NICE, 2013.
13. Lavy Y, Lev-Sagie A, Holtzer H, Revel A, Hurwitz A. Should laparoscopy be a mandatory component of the infertility evaluation in infertile women with normal hysterosalpingogram or suspected unilateral distal tubal pathology? Eur J Obstet Gynecol Reprod Biol 2004;114:64-68.
14. Johnson N, van Voorst S, Sowter MC, Strandell A, Mol BW. Surgical treatment for tubal disease in women due to undergo in vitro fertilisation. Cochrane Database Syst Rev 2010:CD002125.
15. Chu J, Harb HM, Gallos ID, et al. Salpingostomy in the treatment of hydrosalpinx: a systematic review and meta-analysis. Hum Reprod 2015; 30:1882–1895.
16. Clark TJ, Stevenson H. Endometrial polyps and abnormal uterine bleeding (AUB-P): What is the relationship, how are they diagnosed and how are they treated? Best Pract Res Clin Obstet Gynaecol 2016; 40:89–104.
17. Royal College of Obstetricians and Gynaecologists. Long-term Consequences of polycystic ovary syndrome. Green-top Guideline No. 33. London: RCOG; 2014.
18. Prior M, Richardson A, Asif S, et al. Outcome of assisted reproduction in women with congenital uterine anomalies: a prospective observational study. Ultrasound Obstet Gynecol 2018; 51:110-117.
19. Sugiura-Ogasawara M, Ozaki Y, Suzumori N. Müllerian anomalies and recurrent miscarriage. Curr Opin Obstet Gynecol 2013; 25:293–298.
20. Lenton EA, Landgren BM, Sexton L. Normal variation in the length of the luteal phase of the menstrual cycle: identification of the short luteal phase. Br J Obstet Gynaecol 1984; 91:685–689.
21. Practice Committee of the American Society for Reproductive Medicine. The clinical relevance of luteal phase deficiency: a committee opinion. Fertil Steril 2012; 98:1112–1117.
22. Bukulmez O, Aric A. Luteal phase defect: myth or reality. Obstet Gynecol Clin North Am 2004; 31:727–744.

23. Vander Borght M, Wyns C. Fertility and infertility: Definition and epidemiology. Clin Biochem 2018. pii: S0009-9120(18)30220-0.
24. Sirmans SM, Pate KA. Epidemiology, diagnosis and management of polycystic ovary syndrome. Clin Epidemiol 2014:6 1–13
25. Rotterdam ESHRE/ASRM-Sponsored PCOS consensus workshop group. Revised 2003 consensus on diagnostic criteria and long- term health risks related to polycystic ovary syndrome (PCOS). Hum Reprod 2004; 19:41–47.
26. Lujan ME, Jarrett BY, Brooks ED, et al. Updated ultrasound criteria for polycystic ovary syndrome: reliable thresholds for elevated follicle population and ovarian volume. Hum Reprod 2013; 28:1361–1368.
27. Nelson LM. Primary ovarian insufficiency. N Engl J Med 2009; 360:606–614.
28. Balen AH, Platteau P, Andersen AN, et al. The influence of body weight on response to ovulation induction with gonadotrophins in 335 women with World Health Organization group II anovulatory infertility. BJOG 2006; 113:1195–1202.
29. Legro RS, Brzyski RG, Diamond MP, et al. Letrozole versus clomiphene for infertility in the polycystic ovary syndrome. N Engl J Med 2014; 371:119–129.
30. Legro RS. Ovulation induction in polycystic ovary syndrome: current options. Best Pract Res Clin Obstet Gynaecol 2016; 37:152-159.

FEMALE INFERTILITY

CORE PRINCIPLES AND CLINICAL MANAGEMENT

Female infertility has a broad range of causes, including lifestyle factors, gynecological disorders, STIs, genetic and chromosomal abnormalities, and chemotherapy. Preliminary assessment and diagnosis thus require a wide array of genetic, laboratory and imaging investigations. These are evolving rapidly, as are treatment options.

Female Infertility: Core Principles and Clinical Management provides a comprehensive understanding of how best to investigate and overcome female infertility. It opens with an introduction to anatomy and physiology of the female reproductive system. Subsequent chapters describe how to secure optimum functionality of the ovaries, stimulation protocols and the process of oogenesis and oocyte collection. Because polycystic ovarian syndrome and endometriosis have such adverse impact on oocyte quality and implantation, each of these has a chapter dedicated to its treatment.

Concluding chapters review fast-moving and future technologies, including the derivation of oocytes from stem cells, the three-parent concept for management of mitochondrial disease and the transplantation of cryopreserved ovaries.

Richly illustrated throughout, this is a key resource for all clinicians, nurses and clinical scientists whose work has an impact on women who are seeking to overcome infertility.

- Written and edited by an international team of leading experts in the field
- Covers all aspects of oocyte assessment, management and fertilization
- Reviews cutting-edge techniques such as uterine transplantation and oocyte cryopreservation, and their potential in infertility practice

JP medical publishers

www.jpmedpub.com

ISBN 978-1-909836-50-1

9 781909 836501