

# DENTAL TRAUMA

## A PRACTICAL GUIDE TO DIAGNOSIS AND MANAGEMENT



Serpil Djemal

# Contents


Dedication v
Preface vii
Contributors xi

Chapter 1
First principles 1

Chapter 2
Splinting 9

Chapter 3
Infractions and enamel fractures 17

Chapter 4
Enamel–dentine fractures 25

Chapter 5
Enamel–dentine–pulp fractures 31

Chapter 6
Crown-root fractures 41

Chapter 7
Root fractures 49

Chapter 8
Concussion and subluxation 61

Chapter 9
Extrusion 69

Chapter 10
Lateral luxation 75

Chapter 11
Intrusion 85

Chapter 12
Avulsion 97

Chapter 13
Dentoalveolar fractures 105

Chapter 14
Long-term consequences of dental trauma 117

Index 133

# 4 Enamel–dentine fractures

*Lakshmi Rasaratnam, Ravi Chauhan*

## Introduction

An enamel–dentine fracture is the loss of enamel and dentine resulting from a traumatic dental injury. It is also known as an uncomplicated crown fracture and can be seen in the diagrammatic representation in **Figure 4.1**.

## Epidemiology

There were 1,769 patients treated at the Specialist Adult Dental Trauma Clinic at King's College Hospital between 2012 and 2018. A total of 3,912 teeth sustained 4,062 traumatic dental injuries of which uncomplicated crown fractures accounted for 31% (1,273).

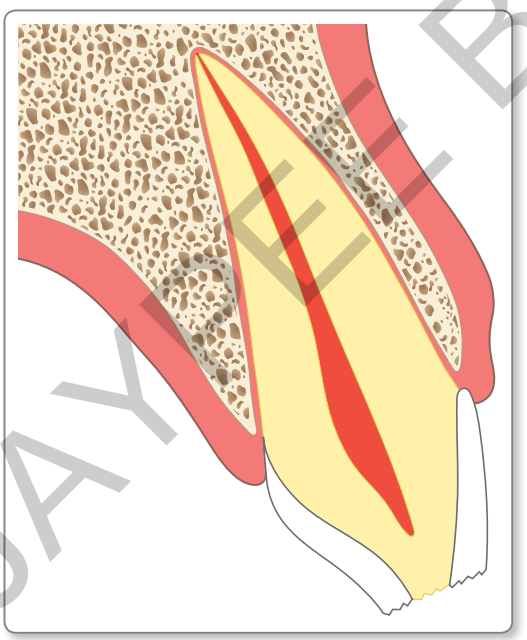

**Figure 4.1** Diagrammatic representation of an enamel–dentine fracture.

## Assessment

### History

A full history will ascertain the extent and magnitude of force of the impact of the trauma and help anticipate the extent of the injuries (see Chapter 1).

### Clinical features

Features common to enamel–dentine fractures include:

- Loss of enamel and dentine without pulpal exposure
- Sensitivity to cold air
- Positive response to sensibility testing
- Teeth with physiological mobility

### Imaging

A periapical radiograph of a tooth with an enamel–dentine fracture will show loss of enamel and dentine. In the absence of any other injuries, the periodontal ligament will be intact.

If there is a lip laceration and the tooth fragment is not accounted for, a soft tissue radiograph will rule out the possibility of the missing tooth fragment being embedded in the lip as outlined in Chapter 1.

## Diagnosis

The clinical and radiographic features described above will lead to a diagnosis of an enamel–dentine fracture.

## Management

If the tooth fragment is available, the possibility of fragment reattachment should be considered (see Chapter 5 for technique).

JAYPEE BROTHERS

If the fragment is reattached, there will initially be a shade mismatch, particularly if the fragment was kept dry. The reattached fragment will return to its former shade once it has rehydrated over the next few days.

If the tooth fragment is not available the fractured tooth can be built up with composite resin and restored back to its original form.

## Post-operative care

Try to keep the advice simple. Patients should be advised:

- Not to bite anything hard or soft with their traumatised teeth
- To resume normal tooth brushing as soon as possible
- When their next appointment is likely to be
- What the follow-up protocol is and what it will entail
- Who to call if they have any problems

## Follow-up

Enamel–dentine fractured teeth should be reviewed at 3, 6, 12 months and annually thereafter.

The follow-up protocol is designed to diagnose pulp necrosis. Only request a radiograph if the clinical signs or symptoms suggest that it would be helpful for diagnosis.

Two signs or symptoms are required to diagnose pulp necrosis and sensibility tests should not be relied on in isolation.

## Case study 1: Enamel–dentine fractures, open apices

### Presentation

A 6-year-old boy knocked his upper front teeth when he slipped while attempting to climb up a wet slide. He fractured both upper central incisors (UR1 and UL1 or 11 and 21). His dentist temporarily covered the exposed dentine with glass ionomer (**Figure 4.2**) and referred him to a specialist trauma unit.

Three days later he was asymptomatic but reported some sensitivity to cold drinks from his UR1 and UL1 (11, 21).



**Figure 4.2** Enamel–dentine fractures with glass ionomer placed or both upper central incisors.



**Figure 4.3** Glass ionomer bandages not interfering with the occlusion.

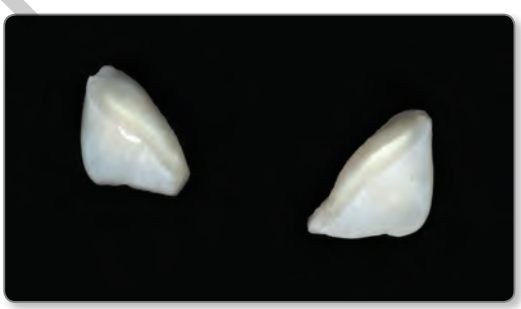

**Figure 4.4** Tooth fragments of UR1 and UL1 (11, 21).

Intraoral examination revealed that there were no signs of displacement of the UR1 and UL1 (11, 21). Glass ionomer bandages were seen on both teeth with no disturbance of his occlusion (**Figure 4.3**). Neither of the teeth were tender to percussion or palpation and they did not respond to sensibility testing. He had the tooth fragments (**Figure 4.4**) and his parents wondered if it was possible to reattach them.

### Imaging

A periapical radiograph (**Figure 4.5**) of the UR1 and UL1 (11, 21) revealed:

JAYPEE BROTHERS



**Figure 4.5** Periapical radiograph showing incomplete root formation of the UR1 and UL1 (11, 21).

- Open apices with two-thirds of the root length formed
- Thin root walls with no obvious root fractures
- Developing (unerupted) upper lateral incisors

## Diagnosis

From the clinical presentation and radiographic findings, a diagnosis of enamel–dentine fractures of the UR1 and UL1 (11, 21) was made.

The patient and his parents were advised of the diagnosis together with details of the proposed management and the recommended postoperative follow-up period and possible complications to expect.

## Management

Under local anaesthetic the glass ionomer temporary fillings were removed and the fragments tried in until they could be relocated perfectly.

The fragments were etched, washed and unfilled resin was applied and cured. The teeth were then treated in the same way and flowable composite was used to reattach the tooth fragments into position. His occlusion was checked and no interferences were seen (**Figure 4.6**).

At the 12-month review, the patient was asymptomatic. The UR1 and UL1 fragments remained attached and had rehydrated, matching the natural tooth colour (**Figure 4.7**). The teeth were not tender to percussion or palpation and sensibility tests were inconsistent.

The periapical radiograph at 12 months revealed continued root formation of the UR1 and UL1 (11, 21) (**Figure 4.8**).



**Figure 4.6** Tooth fragments UR1 and UL1 (11, 21) reattached into position. Occlusion is checked for interferences.



**Figure 4.7** One-year review of fragment reattachment UR1 and UL1. Note the natural colour of the tooth fragments has returned.



**Figure 4.8** Periapical radiograph taken one year after treatment showing ongoing root development of the UR1 and UL1 (11, 21) with no evidence of apical pathology.

It was assumed that the pulps were vital because the teeth were asymptomatic with no signs or symptoms. Continued root development was confirmed on the periapical radiograph.

JAYPEE BROTHERS

# Case study 2: Enamel–dentine fractures, closed apices

## Presentation

A 22-year-old woman tripped over her shoe laces while out shopping, fell to the ground and knocked the right side of her mouth on the pavement.

She attended a trauma clinic complaining of slight sensitivity from the upper right central incisor (UR1 or 11), but was otherwise asymptomatic.

Intraoral examination revealed loss of tooth tissue on the incisal third of the crown with exposed dentine in the upper right central incisor (UR1 or 11) and upper right canine (UR3 or 13) which had been mesialised by previous orthodontic treatment to mask a missing lateral incisor (**Figure 4.9**). Both the traumatised teeth were firm, there was no tenderness on percussion or palpation and the occlusion was not disturbed.



**Figure 4.9** Fractured UR1 and UR3 (11, 13) with the UR3 (13) in the lateral incisor position.

Minor infraction lines were seen around the fracture lines in the UR1 and UR3 (11, 13), shown in **Figure 4.10**.

## Imaging

A periapical radiograph of the upper incisors (**Figure 4.11**) revealed:

- Good bone levels
- Fully-formed roots with no widening of the periodontal ligament space
- No radiolucent lines in the roots or surrounding alveolus

## Diagnosis

From the clinical presentation and radiographic findings, diagnoses of enamel–dentine fractures of the UR1 and UR3 (11, 13) were made.

The patient was advised of the diagnosis, prognosis and details of the acute management, the recommended postoperative follow-up period and possible complications to expect (see Chapter 14).



**Figure 4.11** Periapical radiograph of upper anterior teeth showing good bone levels and visible fractures to UR1 and UR3 (11, 13).



**Figure 4.10** Minor infraction lines visible around the fracture lines of UR1 and UR3 (11, 13).



**Figure 4.12** Composite resin build up of the UR1 and UR3 (11, 13).

JAYPEE BROTHERS

## Management

Under local anaesthetic the fractured edges were bevelled and the UR1 and UR3 (11, 13) were restored with composite resin (**Figure 4.12**).

At the 12-month follow-up, the teeth were asymptomatic and clinical and radiographic examinations were unremarkable.

# Case study 3: Enamel–dentine fractures, closed apex with discolouration

## Presentation

A 27-year-old woman tripped running for a train, and fell and hit her upper teeth on a ramp.

She attended a trauma clinic complaining of slight sensitivity from the upper left central incisor (UL1 or 21) and discolouration of the tooth. She was very concerned about the appearance of her broken tooth.

Intraoral examination revealed loss of the mesial corner of the UL1 (21) with exposed dentine (**Figure 4.13**). There was a fixed orthodontic retainer on the palatal aspect of the upper incisors.



**Figure 4.13** Fractured UL1 (21) with a pink hue.



**Figure 4.14** Minor infractions visible in the cervical region UL1 (21).

The UL1 (21) was still attached to the retainer and had a pink hue. There was no tenderness to percussion or palpation.

Minor infractions were seen in the cervical region of the UL1 (21), as seen in **Figure 4.14**.

## Imaging

A periapical radiograph of the upper incisors (**Figure 4.15**) revealed:

- Good bone levels
- Fully-formed roots with no widening of the periodontal ligament space
- No radiolucent lines in the roots or the surrounding alveolus

## Diagnosis

From the clinical presentation and radiographic findings, a diagnosis of enamel–dentine fracture of the UL1 (21) with transient discolouration was made and at this stage, root canal treatment is not indicated.

The patient was advised of the diagnoses together with details of the proposed management of the injury, the recommended postoperative follow-up period and possible complications to expect.

## Management

Under local anaesthetic the fractured corner of the UL1 (21) was built up using composite resin matched to the UR1 (11), as seen in **Figure 4.16**.

The patient was advised that the pink hue of UL1 (21) was likely to resolve but would be reviewed at the follow-up appointment.



**Figure 4.15** Periapical radiograph of upper anterior teeth showing good bone levels and evidence of a fracture UL1 (21) with no apical pathology.

JAYPEE BROTHERS



**Figure 4.16** Clinical photograph after direct composite resin restoration of the UL1 (21) matched to the shade of the UR1 (11).

## Further reading

Andreasen JO, Andreasen FM, Andersson L. Textbook and Color Atlas of Traumatic Injuries to the Teeth, 4th edn. Oxford, UK: Wiley-Blackwell; 2007. p. 280–313.

Bourguignon C, Cohenca N, Lauridsen E, et al. International Association of Dental Traumatology guidelines for the management of traumatic dental injuries: 1. Fractures and luxations. Dent Traumatol 2020; 36:314–330.

Djemal S, Singh P, Polycarpou N, Tomson R, Kelleher M. Dental Trauma 2. Acute management of fracture injuries. Dent Update 2016; 43:916–926.

JAYPEE BROTHERS

# DENTAL TRAUMA

## A PRACTICAL GUIDE TO DIAGNOSIS AND MANAGEMENT

When patients damage their teeth and supporting structures as a result of trauma, it is vitally important that early and effective treatment is provided to maximise the chances of saving existing dentition and avoiding more costly and invasive treatments later on.

*Dental Trauma: A Practical Guide to Diagnosis and Management* has been written to provide clear, practical guidance on how to assess, diagnose and effectively manage the most commonly encountered traumatic dental injuries.

Chapters discuss each type of trauma in a consistent manner to enable rapid access to information at the point of care. As well as summarising how best to assess the patient and manage the presenting problem, the book also describes post-operative care and recommended follow up. Each chapter also features a clinical case example designed to highlight salient points for consideration in clinical practice.

Highly illustrated with over 400 clinical photos and explanatory artworks, *Dental Trauma: A Practical Guide to Diagnosis and Management* is the ideal companion for practitioners seeking to improve their clinical understanding of dental injuries and adopt the most effective treatment plans in daily practice.



JP medical publishers

www.jpmedpub.com

ISBN 978-1-909836-66-2

9 781909 836662