MRCS Part A: 550 SBAs and EMQs

SECOND EDITION

Edited by
Pradip Datta
Sherif Elsobky



Contents

Preface v
Contributors xiii
Introduction to the MRCS Part A xv
How to answer SBAs and EMQs xvi
Acknowledgements xviii

Section A APPLIED BASIC SCIENCES

Applied anatomy

Chapter 1 **Skull and brain** 3
Pradip K Datta

Chapter 2 **Head and neck** 9
Pradip K Datta

Chapter 3 **Upper limb and breast** 15
Andrew Duckworth

Chapter 4 **Thoracic cavity** 25
Pradip K Datta

Chapter 5 **Abdomen** 31
Pradip K Datta

Chapter 6 **Pelvis** 37
Pradip K Datta

Chapter 7 **Lower limb** 43
Andrew Duckworth

Applied physiology

Chapter 8 **Homeostasis, coagulation and bleeding** 51
Sherif Elsobky

Chapter 9 **Temperature regulation** 57
Sherif Elsobky

Chapter 10 **Metabolic pathways and abnormalities** 63
William FM Wallace

Chapter 11 **Fluid balance** 69
Catherine Collinson

Chapter 12 **Sepsis and shock** 75
Catherine Collinson

Chapter 13 **Central nervous system** 81
Catherine Collinson

Chapter 14 **Cardiovascular system** 89
Ian Leeuwenberg and Alastair May

Chapter 15 **Respiratory system** 95
Ian Leeuwenberg and Alastair May

Chapter 16 **Gastrointestinal system** 99
William FM Wallace

Chapter 17 **Genitourinary system** 105
Sherif Elsobky

Chapter 18 **Endocrine system** 113
Sherif Elsobky

Chapter 19 **The liver** 121
William FM Wallace

Applied pathology

Chapter 20 **Inflammation** 125
Marilyn A Armstrong

Chapter 21 **Cellular injury and infection** 131
Sherif Elsobky

Chapter 22 **Wounds and wound healing** 137
Pawanindra Lal

Chapter 23 **Disorders of growth and differentiation** 143
Pradip K Datta

Chapter 24 **Neoplasia** 151
Pradip K Datta

Chapter 25 **Surgical immunology** 157
Marilyn A Armstrong

Chapter 26 **Surgical microbiology** 161
Pradip K Datta

Chapter 27 **Surgical haematology** 169
Sherif Elsobky

Chapter 28 **Surgical biochemistry** 173
William FM Wallace

Chapter 29 **Central nervous system** 179
Pradip K Datta

Chapter 30 **Cardiovascular system** 183
Pradip K Datta

Chapter 31 **Respiratory system** 189
Pradip K Datta

Chapter 32 **Gastrointestinal system** 193
Pradip K Datta

Chapter 33 **Genitourinary system** 199
Sherif Elsobky

Chapter 34 **Endocrine system** 205
Pradip K Datta

Chapter 35 **Breast disorders** 211
Pradip K Datta

Chapter 36 **Musculoskeletal system** 215
Andrew Duckworth

Chapter 37 **Lymphoreticular system and liver** 223
Pradip K Datta

Chapter 38 **Orthopaedic pathology** 229
Anirudh Sharma

Section B PRINCIPLES OF SURGERY IN GENERAL

Principles of surgery in general

Chapter 39 **Perioperative care** 241
Catherine Collinson

Chapter 40 **Postoperative management and critical care** 247
Catherine Collinson

Chapter 41 **Surgical technique and technology** 255
Pawanindra Lal

Chapter 42 **Management and legal issues in surgery** 261
Christopher JK Bulstrode

Chapter 43 **Clinical microbiology** 269
Christopher JK Bulstrode

Chapter 44 **Emergency medicine and trauma management** 275
Andrew Duckworth

Chapter 45 **Principles of surgical oncology** 285
Pradip K Datta

Chapter 46 **The abdomen** 295
Pradip K Datta

General surgery

Chapter 47 **Upper gastrointestinal surgery** 307
Pradip K Datta

Chapter 48 **Hepatobiliary and pancreatic surgery** 321
Yan Mei Goh and Yan Li Goh

Chapter 49 **Surgery of the small and large bowel** 331
Pradip K Datta

Chapter 50 **Endocrine and breast** 345
Pradip K Datta

Chapter 51 **Vascular surgery** 355
Pradip K Datta

Chapter 52 **Genitourinary surgery** 367
Sherif Elsobky

Chapter 53 **Transplantation** 375
Yan Li Goh and Yan Mei Goh

Chapter 54 **Head and neck** 385
Iain Nixon

Chapter 55 **Surgical conditions of the skin** 395
Rong R Khaw

Chapter 56 **Hand disorders** 413
Andrew Duckworth

Chapter 57 **Surgical disorders of the brain** 423
Pradip K Datta

Chapter 58 **The paediatric surgical patient** 429
Sherif Elsobky

Chapter 59 **Upper limb trauma** 441
Anirudh Sharma

Chapter 60 **Lower limb and spinal trauma** 451
Anirudh Sharma

Chapter 61 **Elective orthopaedics** 461
Anirudh Sharma

Chapter 3

Upper limb and breast

Questions

For each question, select the single best answer from the five options listed.

1. A 29-year-old man presents complaining of pain in his left neck and shoulder region following a forced abduction injury to his arm, resulting from a fall from his motorbike at high speed. Subsequent imaging demonstrates an upper brachial plexus lesion.

Which of the following nerves is a branch of the lateral cord of the brachial plexus?

A Axillary
B Musculocutaneous
C Radial
D Thoracodorsal
E Upper subscapular

2. A 35-year-old woman presents with winging of the right scapular due to paralysis of the serratus anterior muscle.

A lesion to which nerve would result in this presentation?

A Dorsal scapular
B Long thoracic nerve of Bell
C Nerve to subclavius
D Suprascapular
E Thoracodorsal

3. A 23-year-old man presents following a fall onto his left shoulder whilst playing rugby. He complains of pain throughout the shoulder and on examination has weakness when testing internal rotation of the arm compared to the contralateral side. Radiographs are negative.

Injury to which tendon would explain his symptoms?

A Deltoid
B Infraspinatus
C Subscapularis
D Supraspinatus
E Teres minor

JAYPEE BROTHERS

4. A 38-year-old woman presents following a twisting injury during a fall from her horse at low speed. She complains of pain in the region of the fracture and on examination has a wrist drop in the ipsilateral hand. Radiographs reveal a fracture of the humeral diaphysis.

An injury to which nerve would explain her presentation?

A Axillary
B Median
C Musculocutaneous
D Radial
E Ulnar

5. An 18-year-old man presents following a deep penetrating stab injury to the anterior aspect of his left forearm.

Which of the following muscles of the forearm is supplied by the ulnar nerve?

A Flexor carpi radialis
B Flexor carpi ulnaris
C Flexor digitorum superficialis
D Palmaris longus
E Pronator teres

6. An 18-year-old man presents with a posterior dislocation of the left elbow. He complains of decreased sensation and weakness throughout the left hand. On examination, there is a weakness to abduction and adduction of the fingers.

Which of the following nerves has been injured as a result of the dislocation?

A Anterior interosseous
B Posterior interosseous
C Median
D Radial
E Ulnar

7. A 48-year-old woman presents with a 1-year history of numbness and tingling affecting the radial three and half digits of her left hand. She has signs of atrophy to the thenar eminence of the hand and has a positive Tinel's and Phalen's tests.

Compression of which structure is causing the patient's symptoms?

A Flexor carpi radialis tendon
B Flexor digitorum profundus tendons
C Flexor digitorum superficialis tendons
D Flexor pollicis longus tendon
E Median nerve

JAYPEE BROTHERS

8. A 49-year-old woman has a unilateral mastectomy for carcinoma of the breast.

Which of the following is the primary contributor to the arterial supply of the female breast?

A Dorsal scapular artery
B Internal thoracic artery
C Suprascapular artery
D Thoracodorsal artery
E Transverse cervical artery

JAYPEE BROTHERS

Answers

1. B Musculocutaneous

The brachial plexus is formed from the ventral rami of the lower four cervical nerve roots (C5–C8) and the first thoracic nerve root (T1). It provides muscular and cutaneous innervation to the pectoral girdle as well as to the rest of the upper limb. The plexus is divided into zones with roots (C5–T1), trunks (superior C5–C6, middle C7, inferior C8–T1), divisions (anterior or posterior divisions of the three trunks) and cords (lateral, posterior, medial). The cords are named according to their location in relation to the second part of the axillary artery. Branches arise from these zones as shown in **Figure 3.1**. The branches of the posterior cord include the upper subscapular nerve that supplies subscapularis, the lower subscapular nerve that supplies subscapularis and teres major, the thoracodorsal nerve that supplies latissimus dorsi, the axillary nerve that supplies teres minor and deltoid, and the radial nerve that supplies the extensors of the elbow, wrist and hand. The musculocutaneous nerve is a branch of the lateral cord, which also gives rise to the lateral pectoral nerve, along with the medial cord and the median nerve.

There are three types of injury that can occur to the brachial plexus: upper, lower or whole. Excessive lateral flexion of the neck (downward traction of arm) away from the pectoral girdle can lead to an upper plexus injury (C5/C6). The clinical presentation is known as an Erb–Duchenne paralysis with the arm in a 'waiter's tip' position due to dysfunction of the suprascapular nerve, musculocutaneous nerve and axillary nerve leading to paralysis of the rotator cuff muscles and unopposed elbow extension and forearm pronation. A forced traction injury on an abducted arm (upward traction) can lead to a lower plexus injury (C8/T1) and the clinical presentation is known as Klumpke's palsy. A characteristic sign is that of an ipsilateral clawed hand due to loss of the ulnar nerve leading to paralysis of the intrinsic

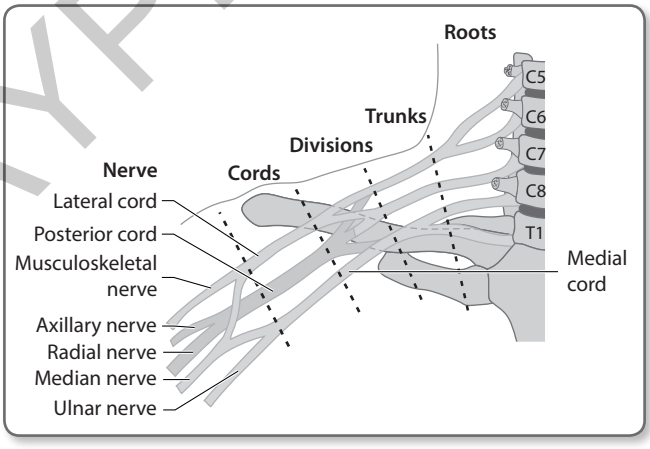

Figure 3.1 The brachial plexus. The roots are located between scalenus anterior and medius, the trunks in the posterior triangle of the neck, the divisions posterior to the clavicle and the cords in the axilla.

JAYPEE BROTHERS

muscles of the hand. T1 involvement can lead to Horner's syndrome (sympathetic chain involvement) with ptosis, miosis and anhydrosis. Such a presentation can be associated with a cervical rib or Pancoast's tumour.

The reflexes of the upper limb are:

- Biceps (C5–C6, musculocutaneous, biceps)
- Triceps (C7–C8, radial, triceps)
- Supinator (C7–C8, radial, brachioradialis)

2. B Long thoracic nerve

The serratus anterior muscle originates on the surface of the first 8–9 ribs on the lateral aspect of the chest wall and inserts on the anterior medial border of the scapula. The muscle protracts and stabilises the scapula, and also assists with arm abduction past 120° by rotating the scapula and forcing the glenoid cavity to point superiorly. A winged scapula (scapula alata) is caused by paralysis of the serratus anterior muscle, commonly secondary to a lesion of the long thoracic nerve of Bell (C5–C7, see **Figure 3.1**). Injury can be traumatic (blunt trauma, subscapular bursitis, or iatrogenic, e.g. mastectomy with axillary clearance), nontraumatic (viral illness, radiculopathy, coarctation of the aorta) or idiopathic. A palsy of the accessory nerve (affecting the trapezius muscle) and dorsal scapular nerve (rhomboid) can lead to a clinical winged scapula also.

3. C Subscapularis

The rotator cuff is a mesh of four tendon insertions that insert into the greater and lesser tuberosity of the humerus, covering the shoulder capsule and reinforcing the stability of the glenohumeral joint. The four muscles of the rotator cuff are:

- Subscapularis
- Infraspinatus
- Supraspinatus
- Teres minor

Features of the four muscles are shown in **Table 3.1**.

Table 3.1 Origin, insertion, innervation and action of the four rotator cuff muscles

Muscle	Origin	Insertion	Innervation	Movement
Subscapularis	Scapular subscapular fossa	Lesser tuberosity	Upper and lower subscapular nerve (C5–C6)	Internal rotation
Infraspinatus	Scapula infraspinous fossa	Greater tuberosity (middle facet)	Suprascapular nerve (C5–C6)	External rotation
Supraspinatus	Scapula supraspinous fossa	Greater tuberosity (superior facet)	Suprascapular nerve (C5–C6)	Abduction
Teres minor	Lateral border of scapula	Greater tuberosity (inferior facet)	Axillary nerve (C5)	External rotation

JAYPEE BROTHERS

4. D Radial

The radial nerve arises from the posterior cord of the brachial plexus (C5–T1), passes through the lower triangular space of the axilla, passes posteriorly between the long and medial head of triceps, enters the arm posterior to the axillary artery and branches to give the posterior cutaneous nerve of the arm. It travels on the posterior medial aspect of the humerus giving a branch to the medial head of biceps and then passes into spiral groove of the humerus, circumnavigating the humerus with the deep brachial artery and providing innervation to the lateral head of triceps. It emerges posteriorly on the lateral aspect of the distal humerus and pierces the lateral intermuscular septum, running between brachialis and brachioradialis in the anterior compartment of the arm. During this course, motor innervation to elbow extensors (anconeus, triceps), brachioradialis and extensor carpi radialis longus are provided, as well as sensory cutaneous branches to the posterior forearm and the lateral arm. It then passes anterior to the lateral epicondyle of the humerus, traversing the antecubital fossa posterior to brachioradialis, entering the forearm. The nerve divides into a deep and superficial branch, with the deep branch continuing as the posterior interosseous nerve after penetration of the supinator muscle and innervates the muscles in the posterior compartment of the forearm. The superficial branch of the radial nerve descends the forearm posterior to brachioradialis, emerges just above the wrist and then provides sensory cutaneous innervation to the lateral dorsum of the hand including the first dorsal web space.

Injury to the radial nerve predominantly occurs at two levels with a distinct clinical picture:

- At the axilla, resulting in loss of elbow extension, wrist extension and metacarpophalangeal joint (MCPJ) extension
- At the spiral groove of the humerus, resulting in loss of wrist extension and MCPJ extension, but with preservation of elbow extension

5. B Flexor carpi ulnaris

The muscles of the flexor compartment of the forearm are divided into a superficial and deep layer, as outlined in **Table 3.2**.

The muscles of the flexor compartment of the forearm are supplied by the median nerve except for:

- Flexor carpi ulnaris (ulnar nerve)
- Flexor digitorum profundus medial two digits (ulnar nerve)

6. E Ulnar

The ulnar nerve arises from the medial cord of the brachial plexus (C8–T1), entering the arm medial to the axillary artery. It travels down the posterior medial aspect of the humerus (medial to brachial artery), pierces the medial intermuscular septum, and descends distally anterior to the triceps, giving off no branches in the arm. It passes posterior to the medial epicondyle of the humerus, entering the anterior compartment of the forearm between the two heads of flexor carpi ulnaris. The nerve

JAYPEE BROTHERS

Table 3.2 Origin and insertion of the muscles of the flexor compartment of the forearm

	Muscle	Origin	Insertion
Superficial	Pronator teres	Medial epicondyle of humerus	Lateral body of radius
	Flexor carpi radialis	Medial epicondyle of humerus	Bases of 2nd and 3rd metacarpals
	Palmaris longus	Medial epicondyle of humerus	Palmar aponeurosis
	Flexor carpi ulnaris	Medial epicondyle of humerus	Pisiform
	Flexor digitorum superficialis	Medial epicondyle of humerus	Base middle phalanges four fingers
Deep	Flexor digitorum profundus	Upper third of volar ulna	Base distal phalanges four fingers
	Flexor pollicis longus	Middle third of volar radius	Base distal phalanx thumb
	Pronator quadratus	Anteromedial surface ulna	Anterolateral surface radius

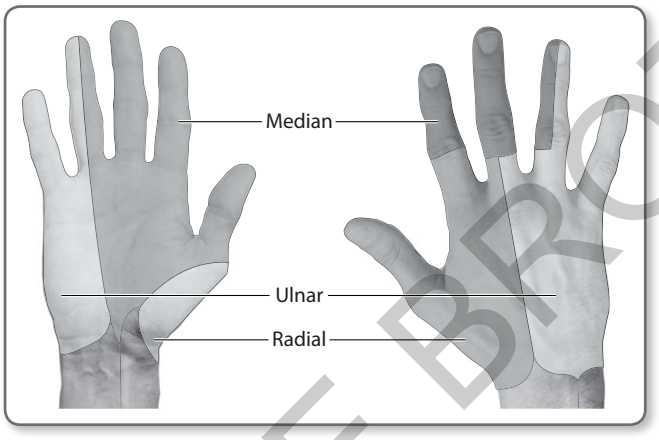

Figure 3.2 Cutaneous nerve supply to the hand.

descends through the forearm alongside the ulna and ulnar artery deep to flexor carpi ulnaris, which it innervates along with the medial two digits of the flexor digitorum profundus. Approximately 5 cm above the wrist, the nerve gives off the palmar and dorsal branches of the ulnar nerve, which provide cutaneous innervation to the hand (**Figure 3.2**). At the wrist, the ulnar nerve and artery pass through Guyon's canal, superficial to the flexor retinaculum. In the hand the superficial and deep branches of the ulnar innervate the intrinsic muscles of the hand (hypothenar muscles, 3rd and 4th lumbricals, adductor pollicis, interossei). The interossei muscles are responsible for abduction (dorsal) and adduction (palmar) of the fingers. Dysfunction of the ulnar nerve in the hand can also be tested using Froment's sign (test pinch grip and patient compensates by flexing the interphalangeal joint of thumb using flexor pollicis longus, which is innervated by the median nerve).

When severe lesions of the ulnar nerve occur at the wrist a classic clawing appearance to the hand is observed. However, if the lesion is more proximal at the elbow, the claw like appearance of the hand is reduced due to the loss of innervation to flexor digitorum profundus medial two digits. This is known as the ulnar paradox.

JAYPEE BROTHERS

7. E Median nerve

The carpal tunnel is found on the volar or palmar aspect of the wrist and connects the anterior forearm to the volar aspect of the hand. It is formed through the flexor retinaculum and its attachments radially to the scaphoid tubercle and the trapezium, and on the ulnar side to the pisiform and hook of hamate. The contents of the carpal tunnel include the median nerve, four tendons of flexor digitorum profundus, four tendons of flexor digitorum superficialis and the tendon of flexor pollicis longus. The tendon of flexor carpi radialis is adjacent to, but not within the carpal tunnel.

The median nerve arises from the medial and lateral cords of the brachial plexus (C6–T1), entering the arm anterior to the distal third of the axillary artery. It travels down the arm lateral to the brachial artery, moving to the medial side at the mid-humeral level. The median nerve exits the antecubital fossa and passes into the forearm between the heads of pronator teres, giving off the anterior interosseous nerve. It then travels down the forearm between flexor digitorum superficialis and flexor digitorum profundus, before emerging near the wrist medial to flexor carpi radialis and entering the carpal tunnel. In the forearm the nerve innervates some of the muscles in the flexor compartment of the forearm along with one of its branches (anterior interosseous nerve). It then enters the hand via the carpal tunnel (inferior to the flexor retinaculum) and innervates some of the small muscles of the hand (thenar eminence, 1st and 2nd lumbricals). The palmar cutaneous branch of the median nerve is given off prior to the carpal tunnel and explains the preservation of sensory innervation to the central and radial aspect of the palm in patients with carpal tunnel syndrome (**Figure 3.3**).

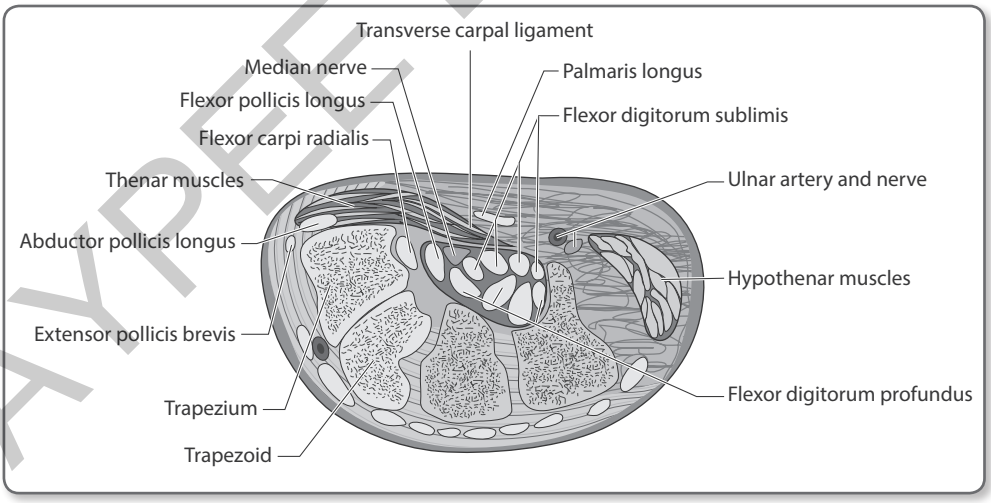

Figure 3.3 The carpal tunnel.

JAYPEE BROTHERS

8. B Internal thoracic artery

The arterial supply of the female breast is through the:

- Internal mammary/thoracic artery
- Intercostal arteries
- Axillary artery (lateral thoracic and acromiothoracic)

The dorsal scapular artery arises from the subclavian artery and supplies the levator scapulae, rhomboids, and trapezius. The thoracodorsal artery is a branch of the subscapular artery and supplies the latissimus dorsi. The transverse cervical artery is an upper branch of the thyrocervical trunk and has contributions to trapezius and sternocleidomastoid. The suprascapular artery is a lower branch of the thyrocervical trunk and has contributions to supraspinatus, sternocleidomastoid and subclavius.

JAYPEE BROTHERS

MRCS Part A: 550 SBAs and EMQs

SECOND EDITION

MRCS Part A: 550 SBAs and EMQs offers a comprehensive selection of practice questions for trainees preparing for the MRCS Part A written exam. Covering applied basic sciences and principles of surgery, the chapters are mapped to the syllabus to assist structured revision.

Thoroughly updated and expanded to include 200 new questions and new chapters on orthopaedic and trauma surgery, **MRCS Part A: 550 SBAs and EMQs** is the 'go-to' revision tool for the MRCS Part A exam.

- Chapters organised by anatomy, physiology, pathology, principles of surgery and general surgery, to help you focus on areas of weakness
- Provides in-depth answers, with illustrations, to help consolidate surgical knowledge and understand key concepts
- Gives practical advice on how to approach revision and useful tips to improve exam technique

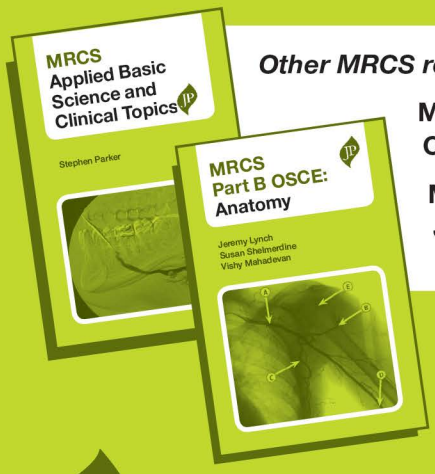

Other MRCS revision resources from JP Medical:

MRCS Applied Basic Science and Clinical Topics Stephen Parker

MRCS Part B OSCE: Anatomy Jeremy Lynch *et al*

JP medical publishers

www.jpmedpub.com

ISBN 978-1-909836-67-9