FRCS General Surgery Section 1: 500 SBAs and EMIs

SECOND EDITION

Alasdair Wilson • Diane Hildebrand

Foreword by **Emad H Aly**

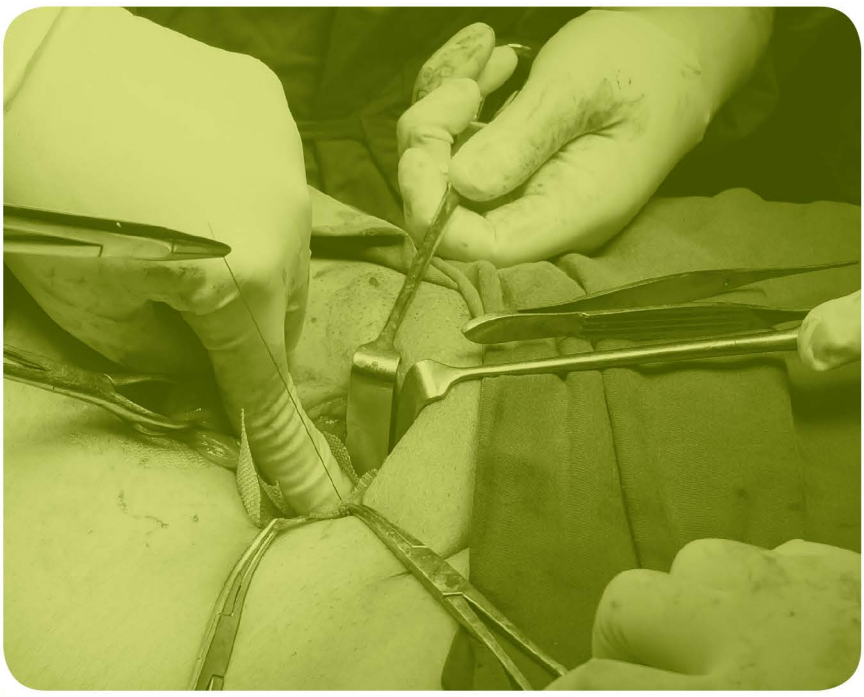

15/02/2018 15:45

Contents

Foreword		v
Preface		vii
Glossary		xi
Recommended reading		xiii
Acknowledgements		xv
Chapter 1	General and emergency surgery	1
Chapter 2	Breast surgery	85
Chapter 3	Colorectal surgery	111
Chapter 4	Endocrine surgery	139
Chapter 5	Hepatobiliary surgery	175
Chapter 6	Transplantation surgery	207
Chapter 7	Upper gastrointestinal surgery	231
Chapter 8	Vascular and endovascular surgery	251
References		279

Chapter 3

Colorectal surgery

Questions: SBAs

For each question, select the single best answer from the five options listed.

1. A 75-year-old man, 2 years postradiation therapy for prostate cancer, presents to the outpatient clinic with anaemia and tenesmus. Flexible sigmoidoscopy reveals mucosal pallor and vascular telangiectasia.

What is the most likely diagnosis?

A *Campylobacter* enteritis
B *Chlamydia trachomatis* infection
C Ischaemic colitis
D Radiation proctitis
E Ulcerative colitis

2. A 70-year-old man presents with an acute onset of severe generalised abdominal pain with few clinical signs. Routine blood tests show raised inflammatory markers.

What is the most likely diagnosis?

A Acute mesenteric ischaemia
B Acute pancreatitis
C Diverticular disease
D Perforated duodenal ulcer
E Ruptured abdominal aortic aneurysm

3. A 33-year-old man presents with recurrent episodes of severe pain which is localised to the anus. The pain lasts for seconds and completely resolves in between attacks.

What is the most appropriate management?

A Barium enema
B Colonoscopy
C CT of abdomen and pelvis
D Reassurance
E Topical glyceryl trinitrate 0.2%

JAYPEE BROTHERS

4. Which of the following statements best describes hereditary non-polyposis colorectal cancer?

A It accounts for 3–5% of all colorectal cancers
B It can present with a Desmoid tumour
C It is associated with Gardner's syndrome
D It results in mutation of chromosome 5q21
E Prophylactic colectomy and ileal pouch anal-anastomosis before age 20 years is recommended

5. A 14-year-old boy is diagnosed with familial adenomatous polyposis.

Which is the most appropriate recommended management step?

A Surveillance colonoscopy every 1–2 years from the age of 16 years onwards
B Surveillance colonoscopy every 1–2 years from the age of 25 years onwards
C Surveillance annual flexible sigmoidoscopy from age 13 years until age 30 years
D Surveillance annual flexible sigmoidoscopy is recommended from age 30 years onwards
E Upper gastrointestinal endoscopy from the age of 15 years

6. Treatment for mainstay of remission of ulcerative colitis includes aminosalicylates.

Which of the following statements best describes aminosalicylates?

A They are not available in topical preparations for treatment of colitis
B 5-aminosalicylic acid (5-ASA) can lead to male infertility
C 5-ASA is a purine analogue
D Mesalazine products have been shown to increase the risk of colorectal cancer
E Osteoporosis can occur in up to 50% of patients using aminosalicylates

7. Azathioprine and 6-mercaptopurine are used to maintain remission in ulcerative colitis and Crohn's disease.

Which statement does not describe thiopurine therapy?

A Purines affect folic acid synthesis and also DNA synthesis
B It takes up to 6 weeks to show a clinical effect
C Thiopurines are generally given orally based on a dose-weight regimen
D Up to 66% of patients will respond to treatment with purines
E Up to one-third of patients are intolerant, with nausea being the most common side effect

8. Following a diagnosis of acute fulminant colitis, a patient is commenced on cyclosporin.

Which of the following statements best describes cyclosporine therapy?

A Careful monitoring of serum drug concentration and renal function is required
B It should be given as an oral preparation
C It is given on an 8-weekly basis by intravenous infusion
D It is the first licensed biological treatment
E Treatment should only be given for 48 hours

JAYPEE BROTHERS

9. A 64-year-old man presents with a small asymptomatic parastomal hernia 6 months after an abdominoperineal resection.

What is the next appropriate management step?

A CT of the abdomen
B Laparotomy and mesh repair of parastomal hernia
C Laparotomy and resiting of stoma
D Localised repair of parastomal hernia
E Reassurance and stoma nurse input

10. An 82-year-old woman is reviewed at outpatient clinic complaining of a lump at her anus and faecal incontinence. Examination reveals concentric folds of mucosa protruding from her anus which can be manually reduced.

What is the most likely diagnosis?

A Anal cancer
B Circumferential skin tags
C Full thickness rectal prolapse
D Haemorrhoidal prolapse
E Mucosal prolapse

11. A 64-year-old man is newly diagnosed with solitary rectal ulcer syndrome, having undergone flexible sigmoidoscopy and biopsies which confirmed the diagnosis.

What is the next appropriate management step?

A Anterior resection
B Biofeedback
C Glyceryl trinitrate 0.2%
D Local ulcer excision
E Ventral rectopexy

12. A 40-year-old man presents with severe anal pain on defecation and fresh per rectal bleeding, which he only notices on the toilet paper. He is too sore to tolerate a per rectal examination at clinic.

What would be the most appropriate initial management?

A 50 U botulinum toxin injections locally to the anus
B Anal dilatation
C Colonoscopy
D Lateral internal sphincterotomy
E Glyceryl trinitrate (0.2–0.4%) applied topically

JAYPEE BROTHERS

13. A 66-year-old woman undergoes adjuvant chemotherapy, following an anterior resection for Dukes stage C colonic cancer.

Which of the following statements best describes adjuvant treatment of colorectal carcinoma?

A Adjuvant treatment is started 1 year after surgery
B Capecitabine is selectively converted to 5-fluorouracil (5-FU) by enzymes present in tumour cells
C 5-FU is given alone
D Oxaliplatin belongs to a family of drugs called antimetabolites
E The decision for adjuvant treatment is taken by the surgeon alone

14. Which of the following is not a side effect of 5-fluorouracil?

A Diarrhoea
B Photophobia
C Constipation
D Dysgeusia
E Palmar–plantar syndrome

15. A 65-year-old woman is diagnosed with an anal squamous cell cancer after an examination under anaesthesia and biopsies of an anal lesion.

Which is the next most appropriate management step?

A Anterior resection
B 5-Fluorouracil and mitomycin C chemotherapy for 1 year
C 5-Fluorouracil and mitomycin-C chemotherapy in combination with radical pelvic radiotherapy
D Localised excision alone
E Pelvic radiotherapy

16. Which of the following statements describes carcinoid of the colon and rectum?

A Carcinoid usually occurs in the caecum
B One-third of patients have nodal disease or distant spread at diagnosis
C Surgery is not usually indicated
D The median age at presentation is between 30 and 40 years old
E Usual presentation is with carcinoid syndrome

17. Which of the following statements describes colonic lymphoma?

A It accounts for 10% of all malignant large bowel neoplasms
B It is more common in women
C Hodgkin's lymphoma is the most common cause
D Localised disease can be treated by surgical resection
E The rectum is the most commonly affected site

JAYPEE BROTHERS

18. A 68-year-old man with no past medical history undergoes polypectomy at 80 cm for a pedunculated polyp. Histopathological examination has shown invasive malignancy with carcinoma invading into the submucosa of the bowel wall but not through the muscularis propria. The site has been marked with Indian ink tattoo.

How would you proceed?

A Colonic resection
B Colonoscopic evaluation and repeat biopsy at 3 months
C Transanal endoscopic microsurgery
D Chemoradiotherapy
E Colonoscopic surveillance 6 monthly

19. A 65-year-old man undergoes colonoscopy and is found to have a large sessile adenoma within the rectum which is removed piecemeal. The rest of the colon is normal. Histopathology confirms no invasive malignancy.

What is the most appropriate management?

A 3-monthly flexible sigmoidoscopy and re-examination of site
B 6-monthly colonoscopy
C 3-yearly colonoscopy
D Annual colonoscopy
E CT of abdomen and pelvis

20. A 72-year-old man undergoes colonoscopy for investigation of a change in his bowel habit. At colonoscopy two small polyps are removed from the sigmoid colon. The rest of the colon is normal. Histopathology subsequently confirms <1 cm adenomas.

What is the most appropriate management?

A 1-yearly colonoscopy
B 3-yearly colonoscopy
C CT of abdomen and pelvis
D No follow-up
E Repeat colonoscopy in 2 months

21. A 68-year-old man is undergoing 3-yearly surveillance colonoscopy. He had three small adenomas excised in the past, one of which was greater than 1 cm. He has now had two consecutive negative examinations.

What is the most appropriate management?

A Annual colonoscopy
B Continue 3-yearly surveillance
C No further surveillance
D 3-yearly barium enema
E 5-yearly colonoscopy

JAYPEE BROTHERS

22. An 84-year-old woman with chronic obstructive pulmonary disease undergoes a successful colonoscopy and removal of four sessile polyps all <1 cm. Histopathology confirms them all to be adenomas.

What is the most appropriate management?

A 3-yearly colonoscopy
B 5-yearly colonoscopy
C 6-monthly colonoscopy
D Annual colonoscopy
E No further surveillance

23. A 23-year-old man has been diagnosed with an anal fissure, which has failed to heal with first line treatment.

What is the next most appropriate treatment?

A 5–10 units of botulinum toxin injected into the external sphincter
B 15–30 units of botulinum toxin injected into the external anal sphincter
C 15–30 units of botulinum toxin injected into the internal anal sphincter
D 45 units of botulinum toxin injected into the external anal sphincter
E Prescription of 0.6% topical glyceryl trinitrate

24. A 24-year-old man is diagnosed with an intersphincteric fistula-in-ano during an examination under anaesthetic.

Which is the most appropriate treatment?

A Biopsies of rectal mucosa only
B Insertion of a 'cutting' seton
C Insertion of a 'loose' seton
D Laying open of the fistula
E No surgical intervention and MRI of pelvis

25. A 33-year-old man presents with a perianal abscess at the 6 o'clock position.

Which of the following is the most appropriate management?

A CT of the abdomen
B Examination under anaesthetic and drainage of sepsis
C Flexible sigmoidoscopy
D Intravenous antibiotics
E MRI of the pelvis

26. Which of the following statements best describes Crohn's disease (CD)?

A >90% of patients with CD will require surgery
B >90% of patients with ileocaecal CD will ultimately require resection
C In 50% of cases of colitis it is not possible to differentiate between CD or ulcerative colitis (UC)
D Oral ulceration is present is 15% of patients
E The small intestine alone is involved in 80% of patients with CD

JAYPEE BROTHERS

27. Which of the following statements best describes ulcerative colitis?

A Approximately 60% of patients present with proctitis
B Hypoalbuminaemia is only found in mild cases
C Pancolitis affects 40% of patients with ulcerative colitis
D The risk of colon cancer with pancolitis is 5% at 10 years
E The risk of colon cancer with pancolitis is 10% at 20 years

28. A 35-year-old man has severe acute ulcerative colitis which is not responding to maximal medical therapy. He is hypotensive and tachycardic with peritonitis.

What is the most appropriate treatment?

A Emergency panproctocolectomy only
B Emergency panproctocolectomy with ileo-pouch anal anastomosis
C Emergency subtotal colectomy and ileorectal anastomosis
D Emergency subtotal colectomy and ileostomy
E Increase dose of intravenous steroids

29. An 85-year-old woman presents with rectal prolapse. She is physically frail but mentally bright. Areas of the prolapsed rectal mucosa are necrotic.

What is the best treatment?

A Reduction of the prolapse, high fibre diet and stool softeners
B Anal encirclement procedure under local anaesthetic
C Resection rectopexy
D Perineal rectosigmoidectomy
E Sutured rectopexy

30. A newborn baby fails to pass meconium within 48 hours. A full thickness rectal biopsy is diagnostic of Hirschsprung's disease.

Which of the following are incorrect?

A Both the myenteric and submucosal plexuses are absent
B The RET protooncogene is implicated
C Hirschsprung's disease is most common in premature infants
D Hirschsprung's disease is associated with trisomy 21
E Hirschsprung's disease is associated with multiple neuroendocrine syndrome II

JAYPEE BROTHERS

Questions: EMIs

Theme: Rectal bleeding

A Anal cancer
B Anal fissure
C Diverticular disease
D Fistula-in-ano
E Haemorrhoids
F Ischaemic colitis
G Radiation proctitis
H Rectal cancer
I Rectal prolapse
J Solitary rectal ulcer syndrome
K Upper gastrointestinal source
L Vascular malformation

Instructions: For each of the following scenarios, choose the single most likely diagnosis from the list above. Each option may be used once, more than once or not at all.

31. A 26-year-old man is investigated for rectal bleeding. A flexible sigmoidoscopy is undertaken and biopsies reveal that the lamina propria is replaced with smooth muscle and there is thickening and disruption of the muscularis propria.

32. A 40-year-old woman presents to the outpatient clinic with severe anal pain. Examination reveals a linear spilt in the mucosa of the anal canal.

33. A 28-year-old man presents with a recurrent perianal abscess. He undergoes incision and drainage of this, but it fails to heal and continues to discharge daily.

Theme: Infective diarrhoea

A *Campylobacter*
B *Clostridium difficile*
C *Cryptosporidium hominis*
D *Entamoeba histolytica*
E *Escherichia coli*
F *Giardia lamblia*
G *Salmonella typhi*
H Schistosomiasis
I *Shigella dysenteriae*
J *Strongyloides stercoralis*
K Viral
L *Yersinia enterocolitica*

Instructions: For each of the following descriptions, choose the single most likely infection from the list above. Each option may be used once, more than once or not at all.

34. A 79-year-old woman develops acute diarrhoea and is found to be Toxin A and B positive.

35. The most common cause of acute gastrointestinal infections.

36. An 18-year-old woman nursery nurse has developed symptoms including dermatitis, coughing, wheezing and abdominal pain.

JAYPEE BROTHERS

Theme: Constipation

A Amyloidosis
B Anal stricture
C Collagen vascular disease
D Diverticular disease
E Hirschsprung's disease
F Inflammatory bowel disease
G Irritable bowel disease
H Megacolon (e.g. Chagas' disease)
I Ogilvie's syndrome
J Rectal prolapse
K Scleroderma
L Slow-transit constipation

Instructions: For each of the following descriptions, choose the single most likely diagnosis from the list above. Each option may be used once, more than once or not at all.

37. A 65-year-old woman has been in intensive care for 6 days with severe pneumonia. She has required invasive ventilation and haemofiltration. She develops abdominal distension. An abdominal X-ray reveals colonic distension with her caecum measuring 11 cm in diameter.

38. A 35-year-old man underwent open haemorrhoidectomy 1 year ago.

39. A 40-year-old woman presents with painful fingers and oesophageal reflux. Human leukocyte antigen gene mutation is present.

Theme: Polyposis syndromes

A Desmoid tumour
B Familial adenomatous polyposis
C Gardner's syndrome
D Hyperplastic polyposis
E Juvenile polyposis
F Lynch I
G Lynch II
H Muir–Torre syndrome
I Osteomas
J Peutz–Jeghers syndrome
K Turcot's syndrome
L Wegener's granuloma

Instructions: For each of the following scenarios, choose the single most likely diagnosis from the list above. Each option may be used once, more than once or not at all.

40. A 24-year-old woman is diagnosed with multiple colonic polyps after a colonoscopy, but is also noted to have skin lesions which include epidermoid cysts and keratoacanthoma.

41. A 13-year-old girl is found to have colonic polyps and is advised to have an annual flexible sigmoidoscopy.

42. A 12-year-old girl presents with multiple intestinal polyps and mucocutaneous pigmentation on her skin.

JAYPEE BROTHERS

Theme: Bowel preparation

A Fybogel (isphagula)
B Glycerine
C Loperamide (Imodium)
D Klean-Prep
E Lactulose
F Magnesium citrate
G None
H Phosphate enema
I Arachis oil enema
J Senna (Senokot)
K Sodium phosphate
L Sodium picosulphate

Instructions: For each of the following descriptions, choose the single most likely treatment from the list above. Each option may be used once, more than once or not at all.

43. Improves the outcome of patients undergoing colorectal surgery.

44. A polyethylene glycol which, when made up to 4 L, can affect tolerability and compliance.

45. Can cause significant changes in electrolytes and should be avoided in patients with cardiac or renal problems.

Theme: Agents in the treatment of colorectal cancer

A Capecitabine
B Cetuximab
C Corticosteroids
D 5-fluorouracil
E Folinic acid
F Gabapentin
G Mitomycin C
H Oxaliplatin
I Radiofrequency ablation
J Radiotherapy
K Tegafur–uracil
L Vascular endothelial growth factor

Instructions: For each of the following descriptions, choose the single most likely agent from the list above. Each option may be used once, more than once or not at all.

46. A 65-year-old man has been increasing pelvic pain from an advanced rectal cancer.

47. This is given along with a pyrimidine analogue to enhance its effect by inhibiting thymidylate synthase.

48. A 67-year-old man is receiving adjuvant treatment for a high-risk Dukes stage B adenocarcinoma and develops significant side effects of neutropenia and sensory neuropathy.

JAYPEE BROTHERS

Theme: Anal fissure

A Anal advancement flap
B Anal dilatation
C Onabotulinumtoxin A (Botox)
D Calcium channel blocker
E Diltiazem
F Glyceryl trinitrate (GTN)
G Hyperbaric oxygen therapy
H Loperamide (Imodium)
I Lateral internal sphincterotomy
J Local excision
K Nothing
L Abdominoperineal resection

Instructions: For each of the following descriptions, choose the single most likely treatment from the list above. Each option may be used once, more than once or not at all.

49. A 33-year-old woman remains symptomatic from her fissure despite two courses of topical based therapies. She is recommended treatment which causes inhibition of acetylcholine at the neuromuscular junction by binding to presynaptic cholinergic nerve terminals.

50. Is as equally effective as the other topical therapy belonging to the calcium channel blocker drug group in the treatment of chronic anal fissure but is associated with higher rate of side effects.

51. A 66-year-old man has a chronic anal fissure and is being counselled that this course of treatment predisposes to incontinence of flatus and faecal soilage in up to 35% of patients.

Theme: Surveillance of colorectal conditions

A Annual colonoscopy with 3-yearly upper gastrointestinal (GI) endoscopy
B Annual colonoscopy ongoing
C Annual colonoscopy until age 25 years
D Annual flexible sigmoidoscopy
E Biennial total colonic surveillance
F 3-yearly colonoscopy
G 3-yearly colonoscopy and upper GI endoscopy
H 3-yearly barium enema and sigmoidoscopy
I 5-yearly colonoscopy ongoing
J 5-yearly sigmoidoscopy ongoing
K 5-yearly colonoscopy until age 60 years
L No surveillance recommended

Instructions: For each of the following descriptions, choose the single most likely surveillance from the list above. Each option may be used once, more than once or not at all.

52. A 25-year-old woman is newly diagnosed with hereditary non-polyposis colorectal cancer.

53. A 14-year-old boy who has been diagnosed with familial adenomatous polyposis.

54. A 16-year-old boy who has a strong family history of juvenile polyposis syndrome but is asymptomatic himself.

JAYPEE BROTHERS

Theme: Inflammatory bowel disease treatment

A Azathioprine
B Cyclosporin
C Ciprofloxacin and metronidazole
D Hydrocortisone
E Imodium
F Infliximab
G Observation only
H Panproctocolectomy
I Prednisolone
J Subtotal colectomy and ileostomy
K Subtotal colectomy and ileorectal anastomosis
L Sulphasalazine

Instructions: For each of the following scenarios, choose the single most likely treatment from the list above. Each option may be used once, more than once or not at all.

55. A 28-year-old woman has had 5 days of intravenous steroid and monoclonal antibody therapy. Her bowel movements have decreased to 5 times per day, but she is now hypotensive and tachycardic.

56. A 44-year-old woman has an ileal pouch anal anastomosis and presents shortly after closure of ileostomy with frequency, urgency and liquid stool.

57. The first licensed biological treatment for Crohn's disease.

Theme: Anorectal pathophysiology

A Anal fissure
B Anal stenosis
C Anismus
D Carcinoma
E Fistula-in-ano
F Haemorrhoid
G Internal rectal prolapse
H Pruritus ani
I Pudendal pain syndrome
J Rectal sensory dysfunction
K Rectocoele
L Solitary rectal ulcer syndrome

Instructions: For each of the following scenarios, choose the single most likely diagnosis from the list above. Each option may be used once, more than once or not at all.

58. A 29-year-old woman presents to the outpatient clinic complaining of a burning sensation in the perineum which is constant. She reports that she needs to remain upright, as any pressure on the area when sitting exacerbates the pain. An MRI of her pelvis is normal.

59. A 56-year-old woman presents to clinic complaining of incompletely evacuating her rectum at defecation and having to digitate her vagina to defecate. A flexible sigmoidoscopy is normal, but she goes on to have a defecting proctogram which reveals prolapse of the rectum anteriorly.

60. A 60-year-old man has a defecting proctogram which shows a space-occupying lesion in the contrast filled rectum, despite a previously normal flexible sigmoidoscopy.

JAYPEE BROTHERS

FRCS General Surgery Section 1: 500 SBAs and EMIs

SECOND EDITION

FRCS General Surgery Section 1: 500 SBAs and EMIs offers a comprehensive selection of practice questions for trainees preparing for the FRCS General Surgery Section 1 written exam. Covering general and emergency surgery, the chapters are mapped to the syllabus to assist structured revision.

Thoroughly updated and including 50 new questions, **FRCS General Surgery Section 1: 500 SBAs and EMIs** is the 'go to' revision tool for the FRCS General Surgery exam.

- 500 SBAs and EMIs reflect the scenario-based formats and the range of difficulty of questions encountered in the exam
- In-depth answers explain why each option is correct or incorrect
- Illustrations and tables help consolidate surgical knowledge and understanding of key concepts discussed in the answers

JP medical publishers

www.jpmedpub.com

ISBN 978-1-909836-69-3

Wilson500SBAs_2eAW.indd 1