Second Edition

Surface Anatomy

Richard Tunstall
S. Ali Mirjalili

Foreword by Susan Standring

pocket tutor

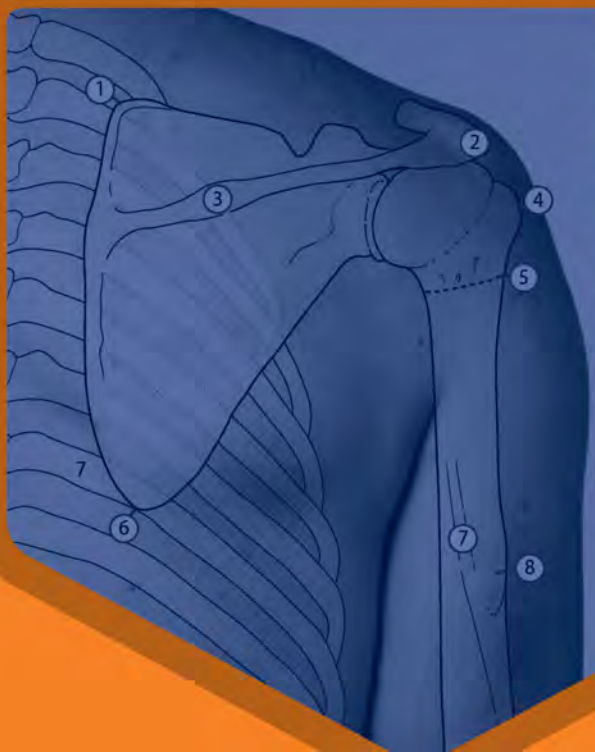

JP

Contents

Foreword *v*
Preface *vii*
How to learn surface anatomy *ix*
Key references *x*
Acknowledgements *xiii*

Chapter 1 Introduction
1.1 The anatomical position and planes 3
1.2 Anatomical movements 7
1.3 Sensory innervation 22

Chapter 2 Head and neck
2.1 Bones and bony landmarks 29
2.2 Intracranial structures 39
2.3 Muscles of the head and face 42
2.4 Nose, nasal cavity and paranasal sinuses 46
2.5 Nerves of the face 49
2.6 Viscera of the face 55
2.7 Oral cavity and oral vestibule 61
2.8 Triangles of the neck 65
2.9 Neurovasculature 70
2.10 Neck viscera 79
2.11 Neck lymphatics 81
2.12 Ectopic neck viscera and neck lumps 84

Chapter 3 Thorax
3.1 Bony landmarks, joints and cartilages 88
3.2 Muscles 92
3.3 Lines and folds 94
3.4 Mediastinum 98
3.5 Neurovasculature and lymphatics 100
3.6 Viscera 104

Chapter 4 Upper limb
4.1 Pectoral girdle, shoulder and arm 121
4.2 Elbow, cubital fossa and forearm 136
4.3 Wrist and hand 149

Chapter 5 The vertebral column and back
5.1 Vertebral column 169
5.2 Muscles 189

Chapter 6 Abdomen
6.1 Bony landmarks, joints and ligaments 200
6.2 Reference planes and regions 205
6.3 Muscles, tendons and aponeuroses 207
6.4 Inguinal canal 210
6.5 Neurovasculature and lymphatics 213
6.6 Surgical access via the abdominal wall 219
6.7 Viscera 222

Chapter 7 Pelvis and perineum
7.1 Bones, joints and ligaments 236
7.2 Perineum 241
7.3 Female 248
7.4 Male 253
7.5 Perineal neurovasculature 259

Chapter 8 Lower limb
8.1 Pelvic girdle, gluteal region and thigh 267
8.2 Knee, popliteal fossa and leg 289
8.3 Ankle and foot 307

Chapter 9 Neonatal surface anatomy
9.1 Thorax 323
9.2 Abdomen 336
9.3 Pelvis and perineum 340
9.4 Head and face 342
9.5 Vertebral column 344
9.6 Limbs 345

Index *347*

chapter 3

Thorax

The thorax is the superior part of the trunk, located between the neck and abdomen. The region is surrounded by the thoracic wall, formed by the ribs, costal cartilages, intercostal muscles, skin, fascia and 12 thoracic vertebrae. The thoracic wall encloses the thoracic cavity, which extends from the superior thoracic aperture to the diaphragm inferiorly.

The thorax contains the heart, lungs, associated vasculature and nerves, oesophagus, thymus and tracheobronchial tree. The mediastinum is the central region of the thorax located between the lungs, diaphragm, vertebral column and superior thoracic aperture.

Function

The thoracic wall serves as an attachment point for muscles of the upper limb, back and abdominal wall, protects the thoracic viscera and assists in the mechanism of breathing and venous return to the heart. The inferior region of the thoracic wall together with the diaphragm and costodiaphragmatic recess cover and protect several abdominal organs (see Chapter 6).

Variability

The surface markings stated in this chapter are representative of an average-sized supine patient during quiet breathing. Remember that percussion, palpation, auscultation and ultrasound guidance can be used to further guide surface placement of underlying structures. The surface markings of thoracic viscera may vary depending on:

- Body position and associated gravity-induced changes
- Disease states, e.g. pulmonary hyperinflation

Clinical insight

Chest wall deformities including pectus carinatum or excavatum can alter normal thoracic surface anatomy.

JAYPEE BROTHERS

- Deep inspiration and expiration
- Body mass

3.1 Bony landmarks, joints and cartilages

Superior thoracic aperture (thoracic inlet)

The superior thoracic aperture is an anteroinferiorly angled imaginary plane that is bordered by rib 1, T1 vertebral body and the jugular (suprasternal) notch (**Figure 3.1**). The inlet opens into the superior thorax and mediastinum. The spinous process of C7 (vertebra prominens) is the most prominent in the lower neck and overlies the vertebral body of T1.

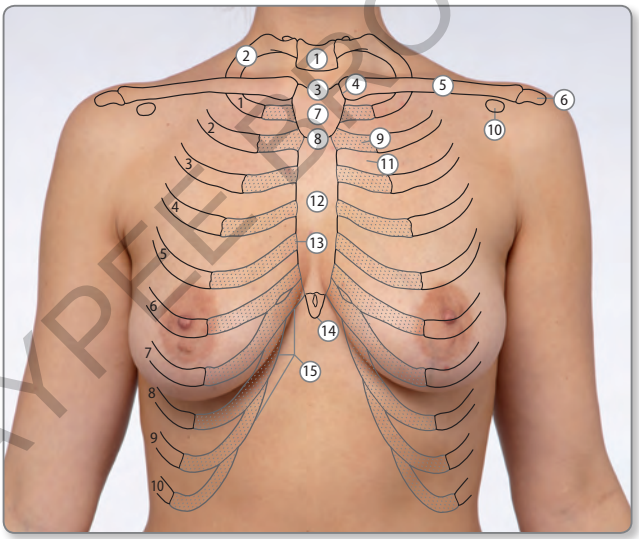

Figure 3.1 Osteology of the anterior thoracic wall. (1) T1 vertebra, (2) 1st rib, (3) jugular (suprasternal) notch of manubrium, (4) sternoclavicular joint, (5) clavicle, (6) acromion, (7) manubrium, (8) sternal angle (manubriosternal joint), (9) 2nd costal cartilage, (10) coracoid process, (11) 2nd intercostal space, (12) sternal body, (13) sternocostal joint, (14) xiphoid process, (15) costal margin (arch).

JAYPEE BROTHERS

Sternum

The sternum sits anteriorly in the midline where it is palpable (**Figure 3.1**). It is formed, from superior to inferior, by the sternal manubrium, body and xiphoid process. The jugular (suprasternal) notch of the manubrium is palpable on its superior surface between the clavicles. Posteriorly directed palpation at the notch reveals the trachea in the midline. The sternal body is a long plate of bone located inferior to the manubrium. The xiphoid process is located inferiorly and can protrude into or away from the abdominal wall muscles. The 7th costal cartilage lies lateral to the xiphoid process. Sternal features can be used to identify vertebral levels (**Table 3.1**).

Clavicle and coracoid process

The clavicle is palpable and visible on the upper thorax between the acromion and manubrium (**Figure 3.1**). Its medial end forms the lateral border of the jugular notch and joins the manubrium at the prominent sternoclavicular joint. The coracoid process is an anteriorly pointing bony prominence of the scapula that forms a palpable rounded mass ~2 cm inferior to the lateral clavicle.

Clinical insight

Although the sternoclavicular joint is easily palpable and accessible, CT guidance is often used during aspiration and injection to prevent entry into the superior mediastinum and damage to pleura or great vessels.

Ribs

The ribs articulate with the thoracic vertebrae posteriorly (**Figure 3.2**) and curve

Sternal feature	Vertebral level
Jugular (suprasternal) notch	T2–T3
Sternal angle (manubriosternal joint)	T4 to upper half of T5
Xiphoid process and xiphisternal joint	T9

Table 3.1 Vertebral levels marked by the sternal features (see **Figure 3.9**). The manubrium extends between the jugular notch and sternal angle, and the sternal body between the sternal angle and xiphisternal joint.

JAYPEE BROTHERS

anteroinferiorly in adults around the thorax to join their respective costal cartilage on the anterior thoracic wall (**Figure 3.1**). In children the rib position is relatively horizontal, which affects surface positioning of the ribs and of the viscera within the thorax and upper abdomen (see page 323). Knowledge of a rib angulation aids radiographic identification, e.g. the posterior part of a rib appears to curve inferolaterally and is the most visible part (**Figure 3.3**). The angle of the rib is palpated posteriorly, a few centimetres lateral to the vertebral spinous processes. The angle is a useful marker for the lateral cutaneous nerves and vessels, which emerge just lateral to it and can be anaesthetised in the region.

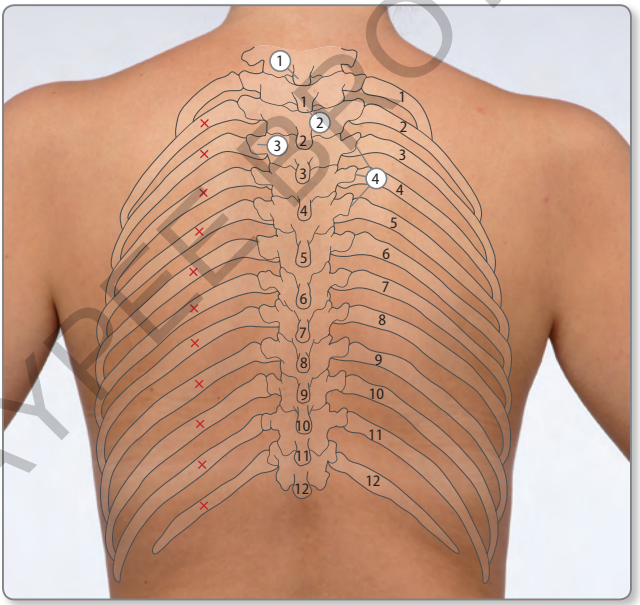

Figure 3.2 Osteology of the posterior thoracic wall. (1) C7 spinous process, (2) T1 spinous process, (3) T3 transverse process, (4) costotransverse joints, × rib angle. The thoracic vertebrae and ribs are numbered 1–12.

JAYPEE BROTHERS

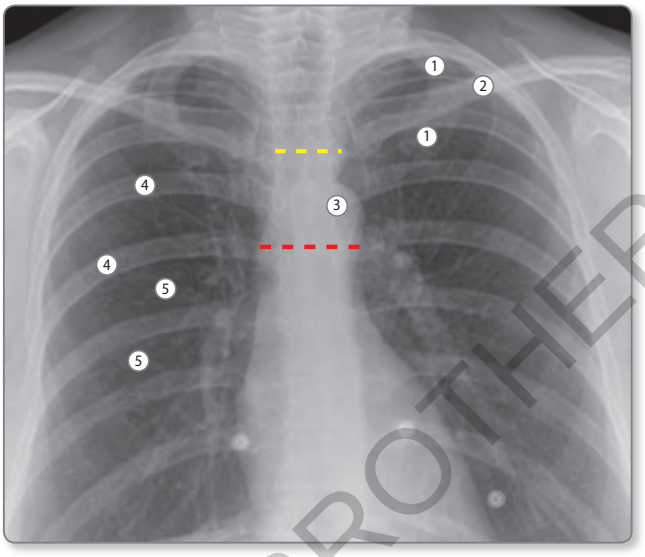

Figure 3.3 Postero-anterior (PA) thoracic radiograph. (1) 1st rib, (2) clavicle, (3) aortic arch, (4) posterior part of rib, (5) anterior part of rib, sternal plane (red dashed line). Level of jugular (suprasternal) notch (yellow dashed line).

Being able to count ribs is important for landmarking and safe thoracic access. Ribs 4–10 can be palpated in the midaxillary line starting with rib 4 at the skin of the axillary floor. Rib 10 is continuous with the costal margin. The free lateral ends of ribs 11 and 12, the floating (free) ribs, can be palpated posteriorly in lean individuals and can be traced medially to help identify the T11 and T12 vertebrae.

Costal cartilages and costal margin

The costal cartilages These connect the distal parts of ribs 1–10 to the sternum or adjacent costal cartilage

Clinical insight

A thoracotomy incision at the level of rib 5 provides upper thoracic access, whereas at the level of rib 6 or 7 it provides posterior mediastinal and diaphragmatic access.

JAYPEE BROTHERS

(**Figure 3.1**). In lean individuals the cartilage of ribs 1–7 vertebrosternal can be identified at the sternum and serve as useful markers of underlying structures. The cartilages pass medially, or superomedially, to the sternum and can be identified on radiographs by their direction of travel and relative radiolucency.

Costal margin (arch) This refers to the free inferior border of the anterior and lateral thoracic cage formed by the distal ends of costal cartilages 7–10. It can be palpated inferolaterally from the xiphoid process to rib 10, and is a useful landmark in abdominal examination.

Intercostal spaces

The intercostal spaces are located between adjacent ribs and/or costal cartilages, and are numbered according to the superiorly located rib (**Figure 3.1**). The 2nd costal cartilage, located lateral to the sternal angle, acts as a useful landmark when counting intercostal spaces. The 1st intercostal space sits superiorly and the 2nd sits inferiorly.

3.2 Muscles

Muscles of the thorax act on the ribs, upper limb or both (**Figure 3.4**).

Pectoralis major This is attached to the medial half of clavicle, costal cartilages 1–6 and the corresponding sternum, and passes laterally to attach to the upper humerus. It is seen and palpated on the anterior thoracic wall, and its free inferior border forms the anterior axillary fold along which the tail of the breast is palpated.

Pectoralis minor This is located deep to pectoralis major. It passes from ribs 3–5 in the midclavicular line to the coracoid process of the scapula, which is palpable beneath the lateral clavicle.

Subclavius This is located between the 1st rib and the inferior surface the clavicle, to around its middle third. It separates the subclavian vessels from the clavicle, and can protect them in a clavicular fracture. Subclavius is at risk of damage during

JAYPEE BROTHERS

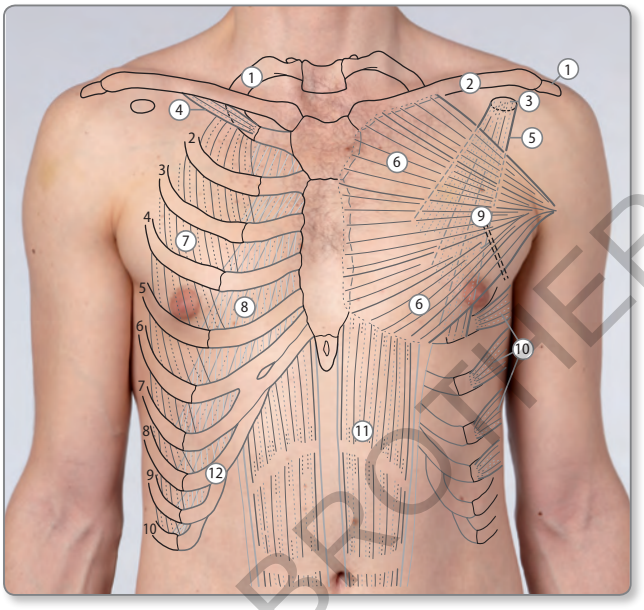

Figure 3.4 Muscles of the anterior thoracic wall. (1) Acromion, (2) clavicle, (3) coracoid process, (4) subclavius, (5) pectoralis minor, (6) pectoralis major, (7) external intercostal muscle, (8) internal intercostal muscle deep to external intercostal membrane, (9) probe position for ultrasound shown in **Figure 3.13b** (black dashed lines), (10) serratus anterior, (11) rectus abdominis, (12) costal margin (arch). Ribs are numbered (right side).

catheter insertion into the subclavian vein via an infraclavicular route.

Intercostal muscles These are located between the ribs and/or cartilages of each intercostal space and are palpated as a soft depression. There are three layers of intercostal muscles ordered external, internal and innermost intercostal, from superficial to deep. The muscles can be incised to access the thorax.

Serratus anterior This arises as fleshy strips from the upper eight ribs around the midaxillary line. The lower five strips can normally be palpated. It passes under the scapula and attaches

JAYPEE BROTHERS

to its medial border. Injury to the long thoracic nerve paralyses the muscle resulting in scapula winging.

Rectus abdominis This is a paired midline strap muscle, passing from the pubic symphysis and crest to the xiphoid process and costal cartilages 5–7. In lean patients its segmented appearance is visible. Its function and strength can be examined by getting the supine patient to raise their head and flex their neck.

The diaphragm This attaches to the lower border of the thoracic cage and arches superiorly into the thorax. During quiet respiration the dome of the diaphragm normally reaches the level of the 5th rib or 5th intercostal space anteriorly on the right side **(Figure 3.8)** and the 5th intercostal space or 6th rib anteriorly on the left side, although this ranges from the 4th intercostal space to below the costal margin.

3.3 Lines and folds

Vertical lines

Several vertical lines can be drawn across the thoracic wall (**Figures 3.5** and **3.6**). These lines can serve as marker points for underlying structures and help demarcate safe zones for invasive procedures.

- The midclavicular line passes vertically through the midpoint of the clavicle. It serves as a marker point for both thoracic and abdominal viscera and is often used to divide the abdomen into regions
- The midsternal line and midvertebral lines pass vertically along the midline (median plane) of the anterior and posterior surfaces of the body, respectively
- The paravertebral line passes vertically along the ends (tips) of the vertebral transverse processes
- The scapular lines pass vertically through the inferior angle of the scapula

Axillary lines and folds

Axillary lines and folds (**Figure 3.7**) help position nerves, lymph nodes, breast tissue and planes for instrument or

JAYPEE BROTHERS

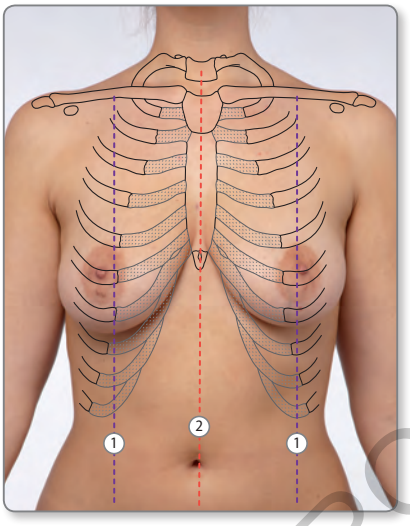

Figure 3.5 Anterior thoracic wall: vertical body lines. (1) midclavicular line, (2) midsternal line (median plane or midline of body).

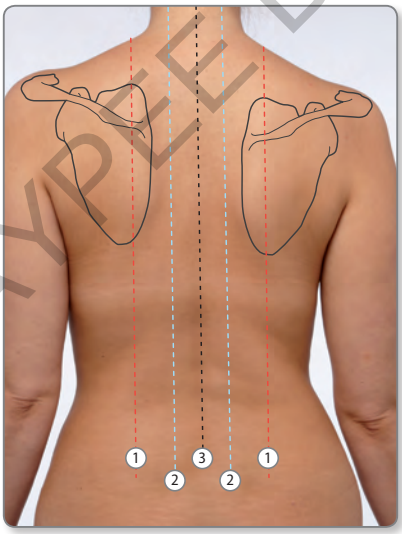

Figure 3.6 Posterior thoracic wall: vertical body lines. (1) scapular line (passes through the inferior angle of the scapula), (2) paravertebral line (passing through the ends of transverse processes of vertebrae), (3) midvertebral line (median plane or midline of body).

JAYPEE BROTHERS

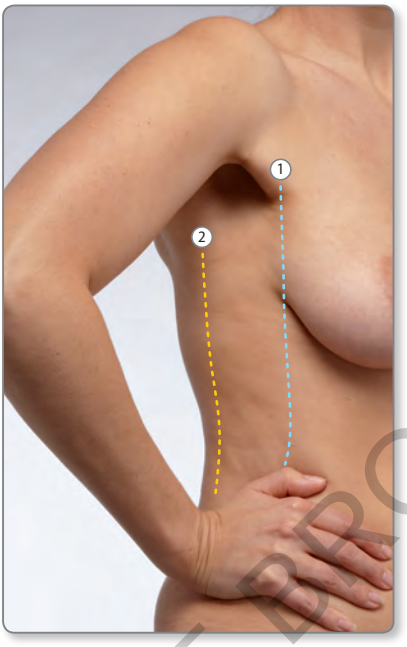

Figure 3.7 Lateral thoracic wall: axillary lines and folds. ① Anterior axillary fold and line (blue dashed line), ② Posterior axillary fold and line (yellow dashed line).

trocar insertion. The axillary folds are best seen and palpated with the upper limb in resisted adduction such as when pressing the hands onto the hips during breast examination. Thoracostomy is performed within the revised 'triangle or zone of safety' located between the anterior axillary fold, the midaxillary line (to avoid the long thoracic nerve) and superior to the 5th (ideally within the 4th) intercostal space to avoid the costodiaphragmatic recess

Clinical insight

Anterior thoracotomy incisions, sited in the 4th intercostal space and passing from the lateral sternal edge to anterior axillary line, provide access to the middle lobe (ligula).

Posterolateral thoracotomy incisions, sited in the 4th or 5th intercostal space from anterior axillary line to ~3 cm below the inferior scapula, provide access to the lung hilum and oesophagus.

JAYPEE BROTHERS

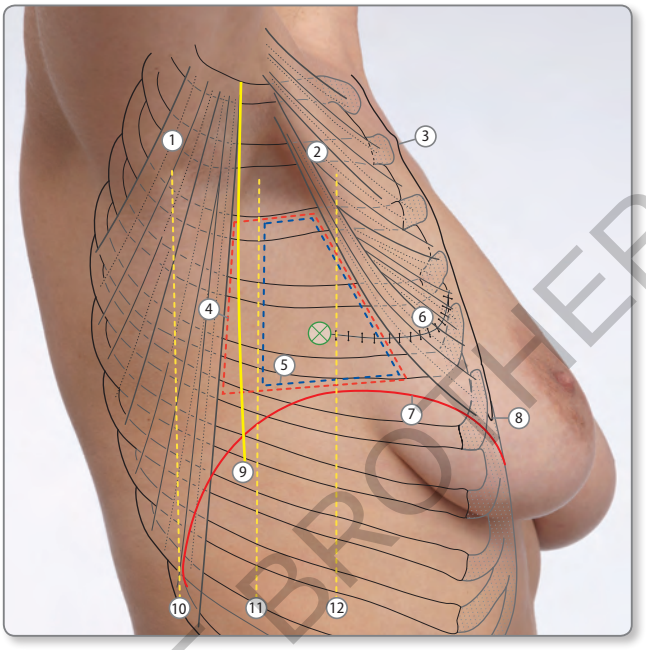

Figure 3.8 Lateral thoracic wall: safe zone/triangle. (1) Posterior axillary fold, (2) anterior axillary fold, (3) sternal angle, (4) borders of the classic safe triangle for thoracentesis (red outline), (5) borders of the revised and recommended triangle of safety (blue outline), (6) emergency thoracotomy incision line, (7) diaphragm (at 5th intercostal space level anteriorly, right side), (8) xiphoid process, (9) long thoracic nerve, (10) posterior axillary line, (11) midaxillary line, (12) anterior axillary line, ⊗ site for thoracostomy incision (4th intercostal space between midaxillary line and anterior axillary fold).

and sub-diaphragmatic organs, the intercostal space first being located on the anterior thoracic wall and traced around to the axillary region (**Figures 3.8** and **3.10**). Originally the posterior axillary fold was used as the posterior border of the triangle of safety, however, this is no longer recommended because incision posterior to the midaxillary line risks damage to the long thoracic nerve.

JAYPEE BROTHERS

Midaxillary line

The midaxillary line passes vertically down the lateral thoracic wall from the apex of the axilla. The inferior limit of the lung sits on the line at the 8th rib and the costodiaphragmatic recess extends between the 8th and 10th ribs on the line and overlies abdominal viscera.

Anterior axillary line and fold

The anterior axillary line passes vertically inferiorly from the anterior axillary fold. The anterior axillary fold is the free inferior border of the anterior axillary wall, which is formed by the tail of the breast overlying the inferolateral border of pectoralis major as it spans from the thorax to the humerus. The tail of the breast and lymph nodes must be examined in this region.

Posterior axillary line and fold

The posterior axillary line passes vertically inferiorly from the posterior axillary fold. The posterior axillary fold is the free inferior border of the posterior axillary wall, which is formed by the inferior borders of latissimus dorsi and teres minor as they span from the thorax and scapula to the humerus.

3.4 Mediastinum

Location and borders

The mediastinum is the central region of the thoracic cavity located between the lungs. It mainly contains cardiovascular structures, which can be examined via the surface and identified on radiographs. The mediastinum is bordered (**Figure 3.9**):

- Anteriorly by the sternum
- Posteriorly by the thoracic vertebrae
- Superiorly by the superior thoracic aperture
- Inferiorly by the diaphragm
- Laterally by the pleurae covered lungs

Superior and inferior mediastinum

The sternal plane (T4–upper half of T5; often higher in females than in males) divides the mediastinum into superior and inferior parts (**Figures 3.3** and **3.9**):

JAYPEE BROTHERS

pocket tutor

Second Edition

Surface Anatomy

pocket tutor Surface Anatomy is the ideal companion for medical students, junior doctors and anyone seeking to master the topographical and positional anatomy required to examine patients, perform interventional procedures and interpret medical images.

- ✔ **Over 200 high-quality photographs with labelled overlays** demonstrate key anatomical structures
- ✔ **High-yield text** provides a systematic, concise review of core anatomy, focussing on structures relevant to clinical skills, procedures and imaging
- ✔ **Clinical insight boxes and medical images** help relate surface anatomy to clinical practice
- ✔ New to this edition: **positional variability data** is included, **ultrasound images** help correlate underlying structures with surface location, and **a new chapter on neonatal surface anatomy** aids understanding of age-related differences

pocket tutor is the best-selling series that reinforces knowledge fast: in practice, in tutorials, before exams. Reminders of key underlying principles, insightful clinical scenarios and an accessible format mean you can trust pocket tutor to provide you with the right answer, whenever you need it.

JP medical publishers

www.jpmedpub.com

ISBN 978-1-909836-82-2

9 781909 836822