Understanding OCT Angiography

From Pathophysiology to Clinical Imaging

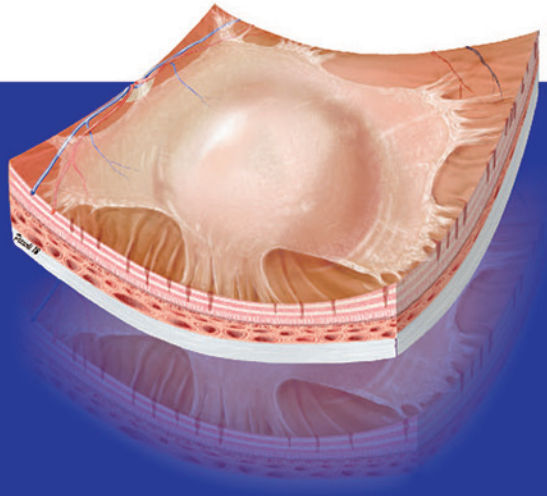

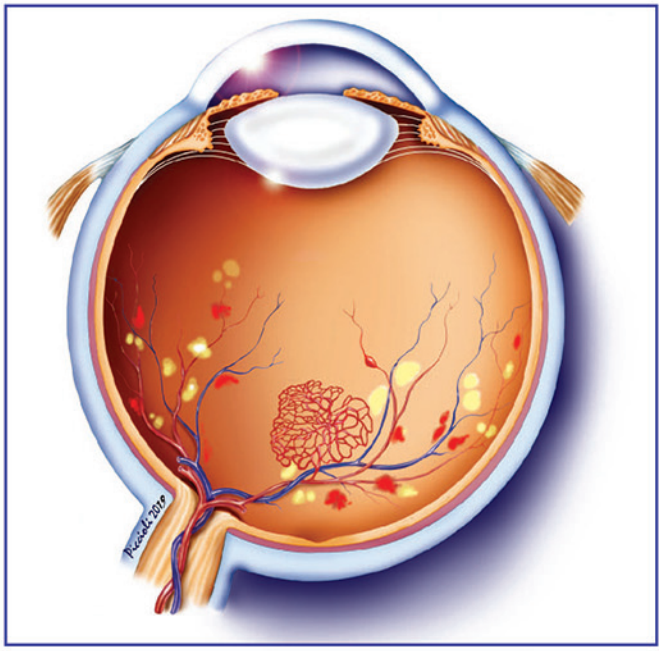

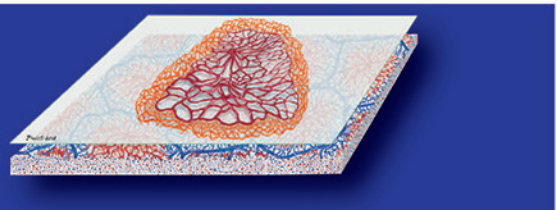

Bruno Lumbroso
David Huang
Eric H Souied
Maria-Cristina Savastano
Yali Jia
Marco Rispoli

Contents

Preface v
Contributors xi
Acknowledgements xiii

Introduction 1
Bruno Lumbroso, David Huang, Eric H Souied, Maria Cristina Savastano, Yali Jia, Marco Rispoli

Chapter 1
Technology principles and terminology 3
David Huang, Yali Jia

Chapter 2
Performing a correct OCTA examination 9
Marco Rispoli, Bruno Lumbroso

Chapter 3
Optical coherence tomographic angiography: prospects and challenges 13
Tristan T Hormel, Yali Jia

Chapter 4
OCT angiography quantitative assessment 19
Bruno Lumbroso, Marco Rispoli

Chapter 5
Normal retinal anatomy and OCT angiography 23
Bruno Lumbroso, Maria Cristina Savastano

Chapter 6
Pathophysiology of age-related macular degeneration 35
Bruno Lumbroso

Chapter 7
AMD drusen and pseudodrusen 39
Bruno Lumbroso, Marco Rispoli

Chapter 8
Dry AMD and geographic atrophy 45
Bruno Lumbroso, Marco Rispoli

Chapter 9
Vascularized drusen 51
Vittorio Capuano, Eric H Souied

Chapter 10
OCT angiography in fibrocellular and fibrovascular phenotypes of neovascular age-related macular degeneration in remission 55
Lea Querques, Mariacristina Parravano, Enrico Borrelli, Adele Chiaravalloti, Massimiliano Tedeschi, Riccardo Sacconi, Ilaria Zucchiatti, Francesco Bandello, Giuseppe Querques

Chapter 11
CNV pathophysiology, definition and classification 61
Bruno Lumbroso

Chapter 12
Exudative choroidal neovascularization 73
Bruno Lumbroso, Marco Rispoli

Chapter 13
Nonexudative, silent, subclinical, quiescent choroidal neovascularization clinical features and practical implications 85
Bruno Lumbroso, Marco Rispoli, Maria Cristina Savastano

Chapter 14
Non-exudative choroidal neovascularization 89
David Huang, Yali Jia, Steven T Bailey

Chapter 15
Exudative CNV evolution after treatment, CNV activity, CNV quiescence 91
Bruno Lumbroso, Marco Rispoli

Chapter 16
CNV in lesions of Bruch's membrane with normal thickness choroid 103
Bruno Lumbroso, Marco Rispoli

Chapter 17
Pachychoroid 1: Polypoidal choroidal vasculopathy 107
Bruno Lumbroso, Marco Rispoli

Chapter 18
Pachychoroid 2: CNV in central serous chorioretinopathy 113
Bruno Lumbroso, Maria Cristina Savastano, Marco Rispoli

Chapter 19
High myopia, myopic CNV 125
Bruno Lumbroso

Chapter 20
Pathophysiology of diabetic retinopathy 125
Maria Cristina Savastano

Chapter 21
Diabetic retinopathy 131
Bruno Lumbroso, Maria Cristina Savastano

Chapter 22
Central retinal vein occlusion branch retinal vein occlusion retinal artery occlusion 145
Marco Rispoli, Bruno Lumbroso

Chapter 23
Retinal microcirculation pathology, DRIL, AMN, PAMM 159
Dmitrii S Maltsev, Alexei N Kulikov, Maria A Burnasheva

Chapter 24
Macular telangiectasia type 1 and 2 169
Bruno Lumbroso, Marco Rispoli

Chapter 25
Hereditary macular dystrophies, Stargardt disease 173
Bruno Lumbroso, Marco Rispoli

Chapter 26
Cystoid macular edema after surgery: Irvine–Gass syndrome 179
Bruno Lumbroso, Marco Rispoli

Chapter 27
Dome-shaped macula 181
Bruno Lumbroso, Marco Rispoli

Chapter 28
Epiretinal membranes 183
Maria Cristina Savastano, Bruno Lumbroso

Chapter 29
Retinitis pigmentosa, inherited retinal dystrophies 189
Enzo Maria Vingolo, Federico Anselmucci, Lorenzo Casilio

Chapter 30
Glaucoma 195
Luca Di Antonio, Luca Agnifili, Lorenza Brescia, Barbara Scatena, Leonardo Mastropasqua

Chapter 31
Neurodegenerative diseases 209
Gilda Cennamo, Daniela Montorio

Chapter 32
How to write a clinical OCT angiography report 215
Marco Rispoli, Bruno Lumbroso

Chapter 33
The future 219
Bruno Lumbroso

Suggested reading 223

Index 225

4 OCT angiography quantitative assessment

Bruno Lumbroso, Marco Rispoli

Introduction

Optical coherence tomography (OCT) angiography quantitative assessment is currently an obligatory phase in any optical coherence tomographic angiography (OCTA) examination whereas dye angiography cannot provide quantitative data. Dye staining and leakage conceal the neovascular network morphology.

Flow qualitative imaging should be associated in the same examination to quantitative analysis for immediate assessment and follow-up. AngioAnalytics software allows to measure quantitatively OCT angiography data. Quantitative parameters may be measured dependably and recurrently. Comprehensive analysis of OCTA parameters is not limited to flow area, nonflow area and vessel density map, but it includes other important factors: vessel diameter, vessel perimeter index, blood vessel tortuosity, area of foveal avascular zone, and parafoveal avascular density.



Figure 1 The choroidal neovascularization area is delimited by a ring line, inside which the new vessels flow appears in yellow. The software prints the value of the area outlined by the operator alongside with the value of the neovascular yellow area. (Optovue)

Flow area

The OCT angiography quantifies flow in the vascular structures of the segmented volume. The operator outlines the neovascular membrane after selecting the right volume and segmentation slab (**Figure 1**). The software automatically identifies and measures the outlined area and the flow it contains. Measurements should be made to help monitoring (**Figure 2**). This is useful in the follow-up of neovascular membranes, before and after treatment and in the study of the evolution of preretinal and prepapillary new vessels (treated or not treated).

Nonflow area, vascular dropout area

After selecting the right volume, the operator should click any point in the nonflow area and the software automatically delimits the area where pixels have the same value (**Figures 3** and **4**). The nonperfused areas may be highlighted in yellow. This technique allows measuring vascular "dropout" in areas where blood flow is lower than normal due to relative or total ischemia. It is possible and useful clinically to study separately dropout areas in the superficial and in the deep vascular networks. Dropout measurement is advantageous in all vascular disorders.

Flow density map

The flow density map measures the flow in vascular areas on *en face* angiograms. Density map shows areas of flow and no flow. The ratio is expressed numerically and shown on a scale of false colors (**Figure 5**). The warm colors are given

JAYPEE BROTHERS

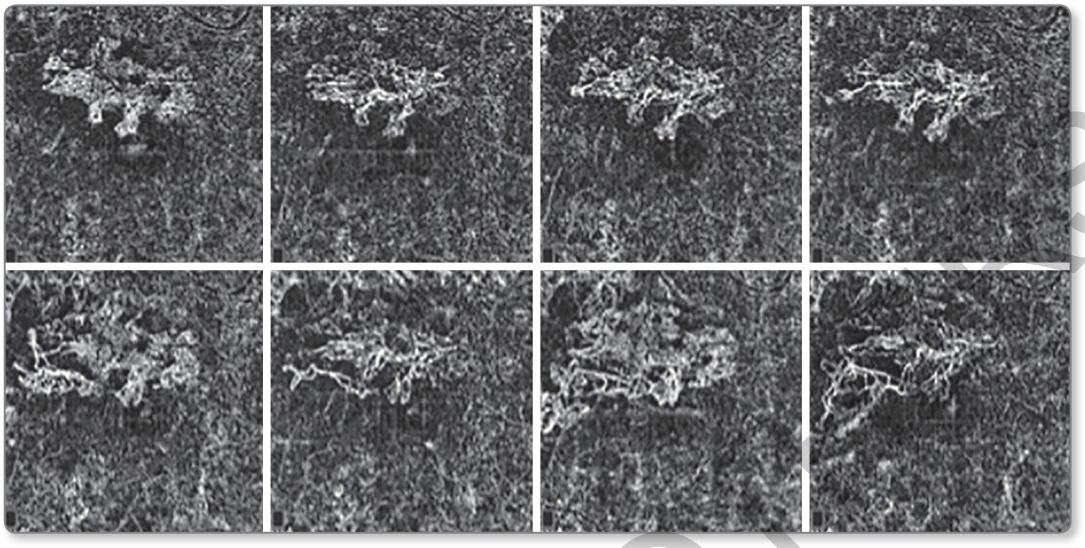

Figure 2 Monitoring CNV evolution during treatment. In this choroidal neovascularization (CNV) case, the successive images allow to follow vascular growth areas and areas of regression. Measurement of the neovascular area made at every examination allows immediate qualitative and quantitative comparison. (Optovue)



Figure 3 Branch venous occlusion of a branch with vascular dropout in the superficial vascular plexus. The nonflow areas are highlighted in yellow, measured in square millimeters and may be compared with successive examinations. (Optovue)

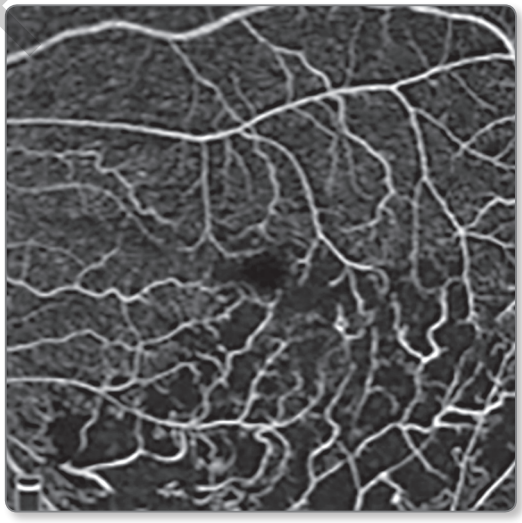

Figure 4 Branch venous occlusion with vascular dropout in the superficial vascular plexus. (Optovue)

JAYPEE BROTHERS



Figure 5 Branch venous occlusion. Same case. Vascular density map at the superficial vascular plexus level. The numerical values expressed in the upper right table refer to the circular grid superimposed onto the angioflow image. (Optovue)

to high density vascular areas, and the cold colors show low flow or no flow density. An average vascular density value is obtained for each sector of the map.

Vascular density may be calculated separately for the superficial and the deep vascular networks.

Box 1: OCT angiography quantitative parameters today

- Flow area
- Nonflow area
- Vessel density map

Box 2: OCT angiography quantitative parameters in future

- Flow speed
- Vessel diameter
- Vessel perimeter index
- Blood vessel tortuosity
- Area of foveal avascular zone
- Contour irregularity
- Parafoveal avascular density

Flow speed

The flow speed measurement software is not yet clinically available. It will be expressed numerically and shown on a scale of false colors. The warm colors are given to high speed vascular areas, and the cold colors show low flow speed (**Boxes 1** and **2**).

JAYPEE BROTHERS

JAYPEE BROTHERS

Understanding OCT Angiography

From Pathophysiology to Clinical Imaging

Ophthalmology stride of progress largely outperforms other medical domains. Advances in "*en face*" optical coherence tomography (OCT); structural OCT, OCT angiography (OCTA) and their extensive application in everyday practice have improved diagnosis, treatment and monitoring of most retinal disorders. OCTA brings a new understanding in the pathological process of ophthalmological disorders.

Most clinicians have begun translating the new OCTA technology into clinical practice. These tools are safer, faster, cheaper, and better than fluorescein angiography. Quantitative OCTA vascular evaluation is nowadays part of the basic assessment and follow-up of most retinal disorders. In addition OCTA has been progressively used in glaucoma diagnosis and in neuro-ophthalmology.

This handbook intends to teach OCTA interpretation for routine everyday use, diagnosing retinal pathologies. In each chapter are included sections on: pathophysiology, clinical features, imaging (structural OCT, "*en face*" OCT, OCTA) and updated management. This book is Illustrated with numerous drawings, outlines, structural and functional OCT figures.

This volume will bring the incredibly fast changes in OCT and OCTA to residents in ophthalmology, postgraduate students and to all ophthalmologists who want to keep abreast with the advances in their field. It will be suitable for a general audience of eye specialists seeking a clear, state-of-the-art and comprehensive description of OCTA. It will interest also orthoptists and optometrists who are attracted in using the latest devices.

Bruno Lumbroso MD is an ophthalmologist specialized in medical retinal diseases. He was Director of the Department of Ophthalmology of the Rome Eye Hospital and Lecturer (Professor LD of Clinical Ophthalmology) in the University of Rome La Sapienza. He is now Director of the Private Centro Italiano Macula for Retinal Diseases, Rome. He is involved in medical education in ocular imaging. His main interests are in logical methods of retinal imaging analysis and interpretation, and in clinical applications of OCT technology for retinal disorders. He is the founder and primary organizer of the International OCTA and "En Face" OCT Congress held annually in Rome in December since 2012. This Congress has an attendance of 1500 ophthalmologists from around the world.

David Huang MD PhD is the Peterson Professor of Ophthalmology and Professor of Biomedical Engineering at the Casey Eye Institute, Oregon Health and Science University (OHSU). Dr Huang earned an MD from Harvard and a PhD from MIT. He is a co-inventor of OCT and pioneered advances such as polarization-sensitive OCT, anterior segment OCT, Doppler OCT, and OCTA.

Eric H Souied MD PhD is head of Department of Ophthalmology at both "Hopital Intercommunal de Créteil" and "Henri Mondor" hospital, in France. His main topics are Medical Retina (AMD, inherited macular and retinal dystrophies) and ophthalmic surgery (retina and cataract). He identified the first mutations associated with retinitis pigmentosa in France in 1994 and the first polymorphism associated with AMD (ApoE) in 1988. Pr Eric Souied is also visiting professor at University of Hainan, China and Sackler University, Tel Aviv, Israel.

Maria-Cristina Savastano MD PhD is in on staff of Centro Italiano Macula, Rome, Italy. She is interested the study and development of the innovative methodology of Angiography-OCT thanks to the clinical-scientific collaboration with Professor Lumbroso and Marco Rispoli. She has written text books and many publications in peer-reviewed journals. She teaches OCT and OCTA interpretation.

Yali Jia PhD is the Jennie P Weeks Professor of Ophthalmology and Associate Professor of Biomedical Engineering at the Casey Eye Institute, Oregon Health and Science University (OHSU). She is known for her innovations in OCTA and the application to eye diseases. She owns six issued patents in the area of OCTA. Her research interests include biophotonics and imaging, OCT, OCTA, spectroscopic OCT and their clinical applications in ophthalmology.

Marco Rispoli MD is in on staff of the Ophthalmology Department Rome Eye Hospital and in Centro Italiano Macula, Rome, Italy. He is expert and pioneer in OCTA and imaging specialist, interested in developing ocular imaging technology. He has written more than 25 handbooks on retinal imaging interpretation of time domain OCT and spectral domain OCT.

JP medical publishers

www.jpmedpub.com

ISBN 978-1-909836-93-8

9 781909 836938