Valery N. Kornienko
Igor N. Pronin

Diagnostic Neuroradiology



Springer

Contents

1 Neuroradiology: History and New Research Technologies 1
in collaboration with L. Fadeeva, S. Takush, and P. Rodionov

1.1 Introduction 1
1.2 History of Russian Neuroradiology 2
1.3 New Functional Methods in Neuroradiology 3
1.4 Perfusion-Weighted Imaging 11
1.5 Functional MRI 15
1.6 Proton MR Spectroscopy 17
1.7 Phosphorus MR Spectroscopy 22
1.8 Neuroradiology and Information Technologies 23
1.9 Navigation in Neurosurgery 25

2 Congenital Malformations of the Brain and Skull 29
in collaboration with V. Ozerova

2.1 Introduction 29
2.2 Organogenesis Impairment 29
2.3 Impairment of Brain Diverticulation 41
2.4 Impairment of Gyri and Sulci Formation 46
2.5 Changes in Brain Size 53
2.6 Destructive Brain Lesions 53
2.7 Histogenesis Impairment 60
2.8 Arachnoid Cysts 69
2.9 Congenital Anterior Cranial Malformations 80

3 Cerebrovascular Diseases and Malformations of the Brain 87
3.1 Stenosis and Thrombosis of the Cerebral Vessels 87
3.2 Cerebral Ischaemia 101
3.3 Lacunar Infarction 139

3.4 Chronic Ischaemic Brain Disease 154
3.5 Stroke in Children 158
3.6 Non-Atherosclerotic Stenosis and Occlusion of Cerebral Arteries 160
3.7 Thrombosis of the Venous Sinuses 172
3.8 Haemorrhagic Infarction 175
3.9 Intracerebral Haemorrhages 176
3.10 Extracerebral Non-traumatic Haemorrhages 188
3.11 Intratumoral Haemorrhages 193
3.12 Hypertense Haemorrhages 196
3.13 Hypertense Encephalopathy 197
3.14 Rare Causes of Intracerebral Haemorrhage 197
3.15 Intracranial Arterial Aneurysms 199
3.16 Intracranial Vascular Malformations 247
3.17 Carotid–Cavernous Fistulas 302
3.18 Cavernous Angioma 309
3.19 Capillary Telangiectasias 316
3.20 Venous Malformations 320

4 Supratentorial Tumours 333
4.1 Introduction 333
4.2 Supratentorial Tumours 333
4.3 Neuroepithelial Tumours 335
4.4 Neuronal and Mixed Neuronal–Glial Tumours 418
4.5 Embryonic Neuroepithelial Tumours 425
4.6 Primary Lymphoma of the CNS 432
4.7 Metastatic Tumours 440
4.8 Supratentorial Cysts 464
4.9 Eosinophilic Granuloma 476
4.10 Myeloma (Kahler's Disease, Plasmacytoma) 481

5 Pineal Region Tumours 489
5.1 Introduction 489
5.2 Germ Cell Tumours 490
5.3 Pineal Parenchymal Tumours 503
5.4 Glial Tumours 510
5.5 Other Histological Types of Tumours 510

6 Sellar and Parasellar Tumours 529
6.1 Introduction 529
6.2 Anatomy 529

6.3 Pituitary Anomalies 531
6.4 "Empty" Sella Turcica 531
6.5 Pituitary Adenomas 535
6.6 Craniopharyngioma 556
6.7 Gliomas of the Optic Nerves, Chiasm, and Hypothalamus 573
6.8 Germinomas 579
6.9 Teratoma, Epidermoid Tumours, and Dermoid Tumours 580
6.10 Chordoma 585
6.11 Hamartomas of the Tuber Cinereum 585
6.12 Langerhans Cell Histiocytosis 591
6.13 Ratke's Cleft Cysts 592
6.14 Meningioma 594
6.15 Neurinoma of the Fifth Cranial Nerve 594
6.16 Metastases 598
6.17 Paragangliomas 598
6.18 Arachnoid Cyst 598
6.19 Vascular Disorders: Aneurysm 605
6.20 Inflammatory Disorders 605

7 Infratentorial Tumours 617
7.1 Introduction 617
7.2 Intra-Axial Tumours 617
7.3 Extra-Axial Tumours 651
7.4 Brainstem Lesions 680
7.5 Metastases 705

8 Tumours of the Meninges 719
8.1 Meningioma 719
8.2 Non-Meningothelial Tumours 785

9 Head Trauma .....
in collaboration with A. Potapov, A. Kravchuk, and N. Zaharova
9.1 Introduction .....
9.2 Primary Brain Injuries .....
9.3 Secondary Injuries .....

10 Hydrocephalus 919
in collaboration with V. Ozerova and N. Aroutiunov
10.1 Physiology of the Cerebrospinal Fluid System 919

10.2 Techniques for Neuroimaging of CSF Spaces and Quantitative Measurement of CSF Circulation 921
10.3 Quantitative Techniques for Measurement of CSF Flow Velocity by PC MRI 921
10.4 Clinical Studies 924
10.5 Complications 933

11 Intracranial Infections 945
11.1 Introduction 945
11.2 Bacterial Infection 946
11.3 Granulomatous Infections 964
11.4 Fungal Infection (Mycosis) of the CNS 969
11.5 Viral Infections 975
11.6 Parasitogenic Disorders 988

12 Toxic and Metabolic Disorders 1003
in collaboration with S. Serkov
12.1 Introduction 1003
12.2 Primary Toxic and Metabolic Encephalopathies 1003

13 Demyelinating Diseases of the Central Nervous System 1033
in collaboration with S. Serkov
13.1 Introduction 1033
13.2 Primary Demyelinating Diseases 1034
13.3 Disorders with Secondary Demyelination and/or Destruction of White Matter ... 1063

14 Neurodegenerative Disorders of the Central Nervous System 1075
in collaboration with S. Serkov
14.1 Introduction 1075
14.2 Synucleinopathies 1076
14.3 Taupathies 1078
14.4 Cerebral Amyloidoses 1080
14.5 Spinocerebellar Degenerations 1084
14.6 Huntington's Disease 1084
14.7 Hereditary Spastic Paraplegias 1085
14.8 Amyotrophic Lateral Sclerosis 1086

15 Spine and Spinal Cord Disorders 1093
15.1 Imaging Modality and Normal MRI Anatomy 1093
15.2 Specific Features of the Spine and Spinal Cord in Children 1096

15.3 Congenital Spinal Pathology 1097
15.4 Spinal Cord Tumours 1122
15.5 Intramedullary Tumours 1124
15.6 Extramedullary–Intradural Tumours 1150
15.7 Extradural Tumours 1184
15.8 Traumatic Spine and Spinal Cord Injuries 1261
15.9 Degenerative Spinal Diseases 1267

16 Subject Index 1285

Neuroradiology: History and New Research Technologies

1

1.1 Introduction 1
1.2 History of Russian Neuroradiology 2
1.3 New Functional Methods in Neuroradiology 3
1.4 Perfusion-Weighted Imaging 11
1.5 Functional MRI 15
1.6 Proton MR Spectroscopy 17
1.7 Phosphorus MR Spectroscopy 22
1.8 Neuroradiology and Information Technologies 23
1.9 Navigation in Neurosurgery 25

1.1 Introduction

Neuroradiology is a part of general radiology that is dedicated to the diagnostic examination of the brain and spinal cord. The history of neuroradiology, as a whole, reflects the history of radiology development. The birthday of radiology could be considered as 8 November 1895; it was on this day that W. K. Roentgen was experimenting with a cathode tube and discovered a new type of radiation (emission) with high penetrating capacity. Eventually he named this new type of radiation the "X-ray".

Roentgen made the first X-ray image—a skull—in December 1895. In the beginning of January 1896, after 2 months of painstaking research, he published the article "On a New Kind of Rays", and on 23 January he made a presentation on his discovery to a session of the Würzburg Physics–Medical Society. He showed images of bony skeleton structures, created by X-rays passed through a human body to the surface of the photographic plate.

Roentgen's discovery gave powerful impetus to research in physics, and the world's scientific community of physicists, mathematicians, biologists and physicians welcomed this breakthrough. For his discovery of X-rays, he received the first Nobel Prize in physics in 1901. X-rays promptly became the new tool in physics research, and in medicine, they provided many opportunities to visualise the internal structures of the human body. Commonly, X-rays were named "Roentgen rays", the cathode tubes "Roentgen tubes" and the machines for obtaining the images of the internal structure "Roentgen machines".

The first diagnostic machine was revealed in Germany on 26 January 1896. It could capture the image of bone structures, formed on the photographic layer of specially prepared plate by passing X-rays through the body. For more than a century, medicine has been able to visualise internal organs and bones via X-rays. This method is known as *radiography*. The successful application of X-rays for visualisation of high-contrast bone structures facilitated the emergence of the new section of medicine: *radiology*.

In Russia, the first roentgenograms (X-ray films) were obtained in the physics laboratories of St. Petersburg (12–13 January 1896) and Moscow (15–16 January 1896). The first Russian X-ray machine for medical diagnostics was designed by A.S. Popov at the end of February 1896, set up in the Krondshtadt Sea Hospital.

At the beginning of the twentieth century, X-ray machines were available in many Russian cities: St. Petersburg (St. Petersburg University, the St. Petersburg Military Medical Academy, and the Clinical Institute of St. Petersburg), Moscow (the Moscow University), Kiev (St. Vladimir's Imperial University) and Kazan, among others. In 1896, in St. Petersburg's Military Medical Academy and in the Surgical Clinic of the Kiev University, the first operations were performed in the removal of foreign bodies, detected with the help of radiography.

The first issue of the radiological magazine, *Herald of Radiology*, was produced in July 1907 in Odessa, and the first all-Russian Congress of Radiologists took place in Moscow in December 1916; thus, radiology became an independent speciality in Russia. The State Radiological and Cancer Institute was founded in 1918 in St. Petersburg; its first president was the well-known physicist A.F. Ioffe.

After a year, the Physics Department of the Institute became an independent institution, the Institute of Radiology and Roentgenology, and M.I. Nemenov was appointed to the position of its director. In front of the Institute, on 29 January 1920, the first-ever monument dedicated to Roentgen was erected. The first radiological clinic was established in the Institute; later, similar clinics emerged in Paris's Curie Institute and in the Forsell Institute in Stockholm.

The diffusion tensor is symmetrical, i.e. $D_{xy} = D_{yx}$ for any pair of indexes. This property reflects physical properties of the real environment, namely, diffusion properties would not change from the initial and final points of a diffusing molecule trajectory. Thanks to the diffusion tensor's symmetry, the six tensor coefficients (three diagonal and three non-diagonal) are sufficient for characterisation of diffusion properties of water molecules. Six coefficients of diffusion tensor define the form of a diffusion ellipsoid, its sizes and its orientation in space (Pierpaoli 1996; Mori and van Zijl 2002).

The diffusion isotropy means that diffusion motion of molecules does *not* depend on the orientation of environment, and during observation, the molecule would not leave the limits of sphere with a radius D, where $D = (D_{xx} + D_{yy} + D_{zz})/3 = ADC$.

Diffusion anisotropy assumes that, during the observation, due to orientation of environmental elements, the molecule would not leave the borders of the "diffusion ellipsoid" with half-axes λ_1 λ_2 and λ_3; here λ_1 λ_2 and λ_3 are the values of diffusion tensor (eigenvalues). The diffusion anisotropy can be quantitatively estimated with the use of the difference between the diffusion ellipsoid and the sphere with radius D_{cp}, for instance, with the help of the fractional anisotropy (FA) coefficient, relative anisotropy (RA) coefficient, index of anisotropy (IA) and so forth (Pierpaoli 1996). Diffusion tensor MRI (DTI) is used to visualise the anisotropy of water diffusion in the tissue.

In DTI, the line of nerve fibres forming the nerve tracts (paths) may be visualised via the diffusion ellipsoids' orientation, by connecting the vectors of diffusion tensor (Fig. 1.4). Connection algorithms are relatively complex, and therefore the various methods of calculation like structural modelling (structural modelling involves following the main diffusion directions), connective models (anatomical and functional connectivity), methods of integrated transformations and spherical harmonics (*Q*-space spherical harmonics), stochastic models (probabilistic models) and so forth are utilised (Mori and van Zijl 2002; Sen and Basser 2005; O'Donnell 2006).

These methods enable the tracing of multiple nerve fibres forming a neural tract; therefore, DTI is often called tractography—a demonstration of neural tracts visualisation. In the simple form, partial diffusion anisotropy is coded by colour, and visualisation of the direction of water molecule diffusion motion in tissue is carried out by colouring the pixels a certain colour, depending on orientation of their respective vector (red for the *x* axis, green for *y* and dark blue for *z*) (Fig. 1.5).

DTI is a tool of detection of structural communications between brain departments. Establishing such communication is especially important in the case of volumetric processes and the diseases deforming the anatomic structure or destroying white matter, such as tumours, brain injury, arteriovenous malformations, epilepsy and demyelinating diseases.) (Hesseltine et al. 2007; Holshouser 2006).

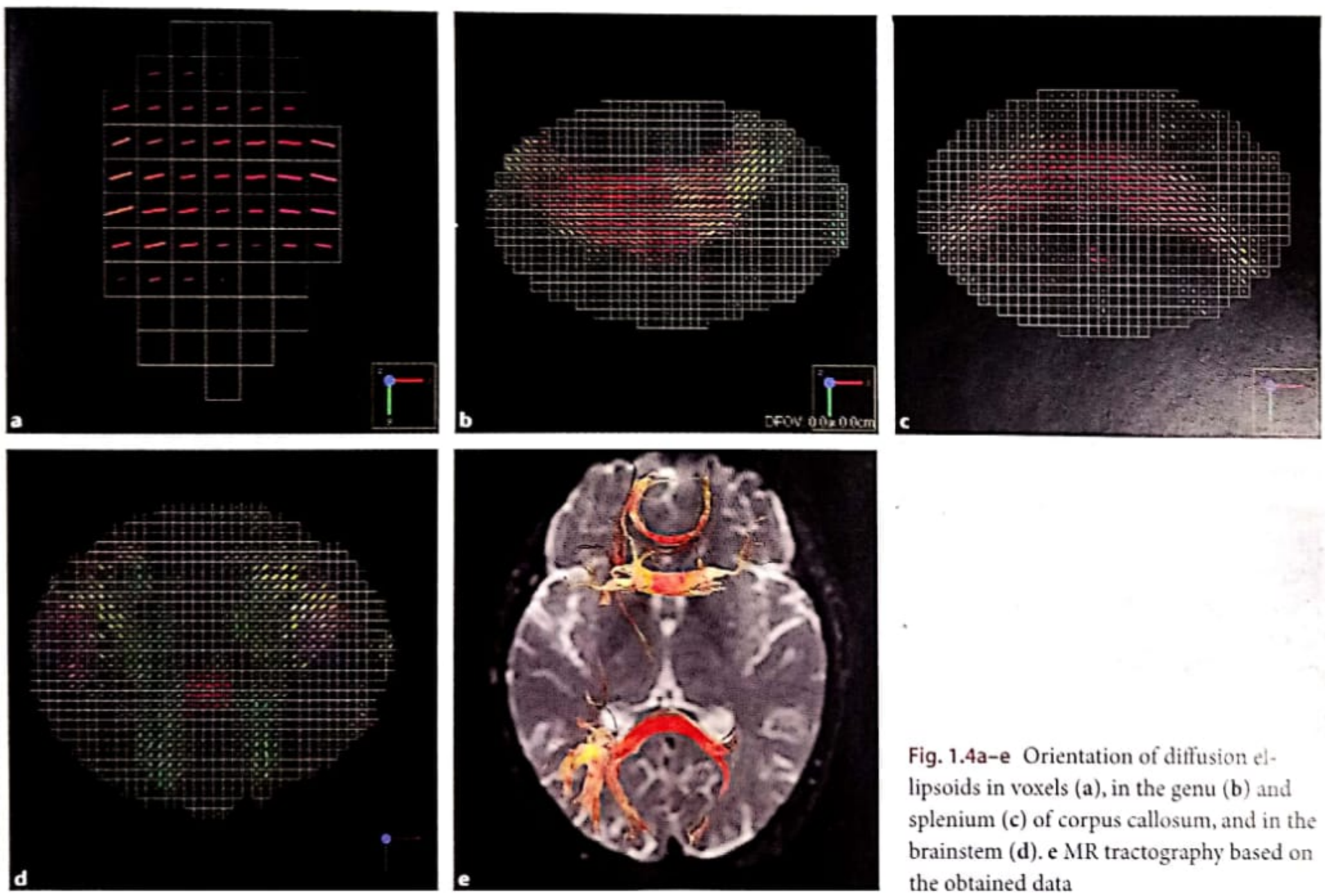

Fig. 1.4a–e Orientation of diffusion ellipsoids in voxels (**a**), in the genu (**b**) and splenium (**c**) of corpus callosum, and in the brainstem (**d**). **e** MR tractography based on the obtained data