diginerve
A Jaypee Initiative
• Video Lectures • Dr. Wise AI Chatbot
• Question Bank • Notes

Exam Preparatory Manual for Undergraduates

Ophthalmology

As per the Revised Competency-based Medical Education Curriculum (NMC)

3rd Edition



JAYPEE BROTHERS

K Mohan Raj

Foreword

Contents

1. Anatomy of the Eye 1
2. Physiology of the Eye 11
3. Neurology of Vision 17
4. Ocular Pharmacology 31
5. Errors of Refraction 38
6. Conjunctiva 55
7. Cornea 73
8. Sclera 99
9. Uvea 105
10. Lens 126
11. Glaucoma 141
12. Vitreous 160
13. Retina 165
14. Intraocular Tumors 197
15. Lids 204
16. Lacrimal Apparatus 218
17. Injuries to the Eye 230
18. Orbit 239
19. Neuro-ophthalmology 251
20. Squint 267
21. Ocular Manifestations of Systemic Diseases 280
22. Community Ophthalmology 285
23. Clinical Examination 295
24. Instruments and Lenses 305
25. Miscellaneous 315

Annexure *329*

Index *331*

JAYPEE BROTHERS

13
CHAPTER

Retina

INTRODUCTION

Retina forms part of the posterior segment which also includes vitreous, choroid, posterior sclera and optic disk.

1. Describe the structure and functions of retina.

Structure of Retina

- Innermost layer of the eye
- Development from neuroectoderm
- Thickness of retina
- Near optic disk – 0.5 mm
- At equator – 0.2 mm
- Anteriorly – 0.1 mm

Layers of the Retina

- Pigment epithelium
- Layer of photoreceptors (layers of rods and cones)
- External limiting membrane (ELM)
- Outer nuclear layer: Consists of nuclei of rods and cones
- Outer plexiform layer: Synapses between axons of bipolar cells, dendrites of ganglion cells and processes of amacrine cells
- Inner nuclear layer: Consists of bipolar cells, horizontal cells, amacrine cells and Muller cells which connect different cells together
- Inner plexiform layer
- Ganglion cell layer
- Nerve fiber layer
- Internal limiting membrane (ILM): Footplates of Muller cells end in the internal limiting membrane.

Muller Cells

Muller cells: Modified astrocytes extend from ILM to ELM.

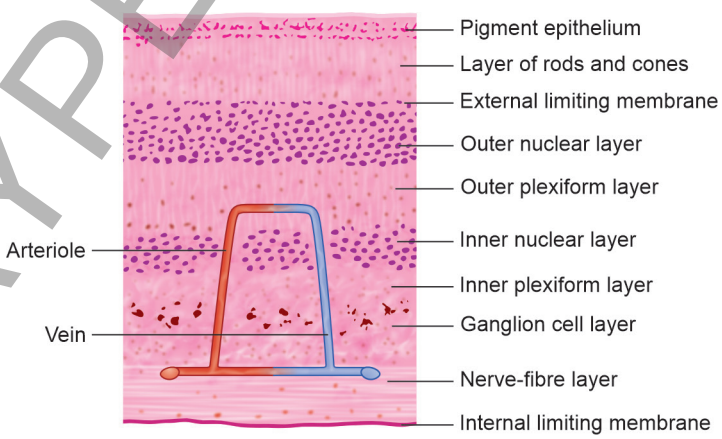

Fig. 13.1: Structure of retina.

JAYPEE BROTHERS

Peripheral Retina

- Extends from macula to ora serrata
- Have a single layer of ganglion cells
- 120 million rods
- 6 million cones of which 50% are in the macula.

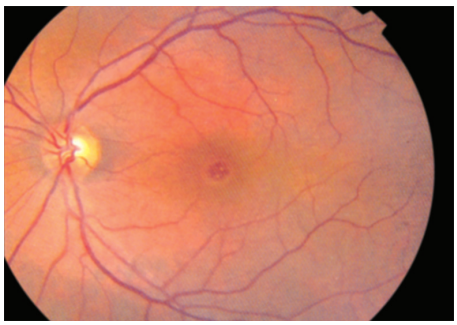

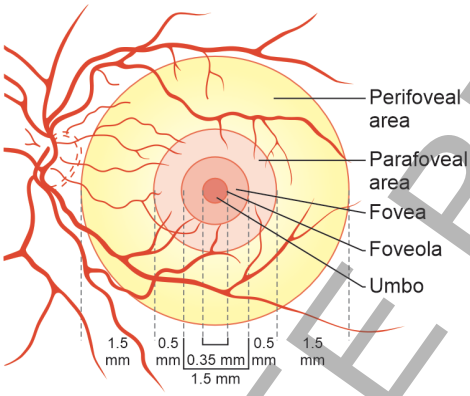

Fig. 13.2: Normal fundus.

Macula

- Outer plexiform layer in the macula is called Henle's fiber layer
- Radial orientation of fibers: Responsible for macular star formation
- Macula: Area of the retina with more than one ganglion cell layer
- Fovea: Central depression of inner retinal surface—avascular zone
- Foveola: Absence of ganglion and other nucleated cells.

Diameters

- Macula – 5.5 mm
- Fovea – 1.5 mm
- Foveola – 350 micrometer
- Umbo – 150 micrometer
- Avascular zone – 450 micrometer
- Ratio of Macula:Fovea:Foveola = 16:5:1.

Blood Supply

- Choriocapillaries supply outer four layers
- Central retinal artery supplies inner six layers.

Venous Drainage

- Outer four layers drained by vortex veins through choriocapillaries
- Inner six layers drained by central retinal vein.

Functions of Retina

- Central part—the macula—cones:
  - Color vision
  - Sharp vision—distant and near
- Peripheral part—mainly of rods:
  - Night vision
  - Dark adaptation
  - Field of vision
- In the outer segment of the retina conversion of light energy to electrical energy takes place
- Pigment epithelium—services and maintains overlying photoreceptors cells
- Functions of retinal pigment epithelium (RPE)
  - Absorbs strong light
  - Actively transports metabolites
  - Forms outer blood-retinal barrier
  - Helps in regeneration of visual pigments.

2. Describe the methods of examination of retina.

- Direct ophthalmoscope
- Indirect ophthalmoscope
- Slit-lamp biomicroscope with special lenses
- Fluorescein angiography
- Indocyanine green angiography
- Ultrasonography.

Direct Ophthalmoscopy

Invented by Babbage–1848
Popularized by Von Helmholtz–1850.

JAYPEE BROTHERS



Fig. 13.3: Direct ophthalmoscope.

Distant Direct Ophthalmoscopy: + 20 D lens in ophthalmoscope at 20–25 cm.

Uses

- To diagnose opacities in media
- To recognize the subluxation of the lens
- To recognize detached retina
- To differentiate between a mole and hole in the iris
  - Portable, battery-operated, self-illuminated, handheld instrument
  - Extent of field seen-from posterior pole to equator
  - Area of visualization increases as the eye is approached
  - Magnification—15 times in emmetrope
  - Less in hypermetrope and more in myopes
  - Real and erect image.

Indirect Ophthalmoscopy

Invented by Nagel in 1864.

Principle

Makes the observed eye myopic irrespective of its refraction by placing strong convex lens (+20 D) in front of the eye:

- Real inverted image is formed
- Lenses used +20 D, +13 D
- +13 D gives 5 times magnification
- +20 D gives 3 times magnification



Fig. 13.4: Indirect ophthalmoscopy.

Advantages

- Large field of view
- Allows examination in hazy media
- Stereoscopic view.

Disadvantage

Image inverted vertically and laterally.

	Direct ophthalmoscope	*Indirect ophthalmoscope*
Magnification	15X	3–5X
Static field of view	10 degrees	46 degrees (with +20 D)
Dynamic field of view	Up to equator	Up to ora serrata
Technique	Easy	Difficult
Illumination	Good	Excellent, fundus can be seen through hazy media
Stereopsis	Absent	Present

Contact Lenses

- Goldman three mirror contact lens
- Panfundoscopic lens
- Nullify the power of the cornea

JAYPEE BROTHERS

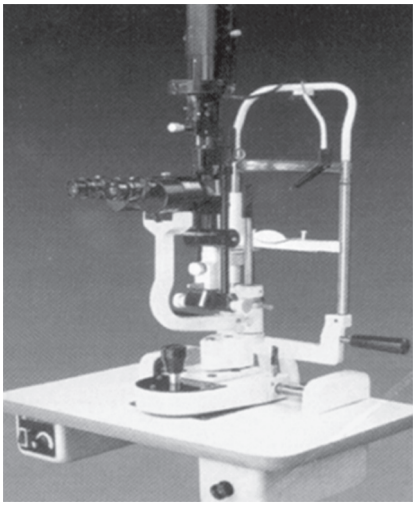

Fig. 13.5: Slit-lamp biomicroscopy with special lenses.

Noncontact Lenses

- Hruby lens –55 D
- +78 D
- +90 D

Goldmann three-mirror Lens

- Three mirrors placed in different inclinations—73°, 67°, 59°
- Central lens for disk and posterior pole:
  - 59° mirror—gonioscopy mirror: Smallest tongue shaped to view the angle of anterior chamber
  - 67° middle sized bigger mirror—to view central retina to mid periphery
  - 73° largest mirror—to view from mid periphery to periphery.

Other Lenses

- Pan fundoscopic lens:
  - Whole retina can be seen
  - High plus lens can be used to give laser burns
- +78 D lens–1.3X + 90 D lens–1.1X
- Image inverted laterally and vertically
- –55 D lens—small field.

Fluorescein Angiography

[Discussed in Miscellaneous chapter]

Indocyanine Green Angiography (ICG)

- 1–2 mL of ICG 25 mg/mL
- Late exposure up to 30–60 minutes post injection is taken
- Absorbs light at 805 nm and emits light at 835 nm (near-infrared).

Advantages of ICG

To visualize:

- Choroidal neovascular membranes
- Choroidal tumors
- Choroidal vasculature.

Ultrasonography

- Ultrasonic frequencies in the range of 10 MHz or 10 million cycles per second are used for ophthalmic diagnosis
- Body scanning probe frequency is only 2.5–5 MHz.

Principle of Ultrasonography

- The transducer transforms electrical energy to sound energy which is directed in the tissues
- Reflected sound waves are received by ceramic plates which convert sound energy into electrical energy.

A scan is time amplitude:

- One dimensional display—horizontal dimension is proportionate to time
- Vertical deflection—denotes position of echo.

B-scan—intensity modulated:

- 2-dimensional display—horizontal dimension is proportional to time and distance
- Vertical echoes—represented as bright intensity modulated dots
- By judging the bright dots and space, it can be interpreted.

3. Describe the investigations of retinal function.

- Electroretinography
- Electrooculogram

JAYPEE BROTHERS

- Dark adaptometry
- Color vision tests
- Methods of retinal nerve fiber layer assessment.

Electroretinography

Measures function of outer retinal layers (activity of rods and cones). ERG detects ganglion cell loss in the retina.

- Records of action potential produced by retina when it is stimulated by light of adequate intensity
- Recording is made between an active electrode in a contact lens placed on the patient's cornea and a reference electrode on the patient's forehead—the potential difference between two electrodes is amplified and deployed.

ERG

- Normal ERG is biphasic
- A wave:
  - Initial negative deflection
  - Arises from photoreceptors

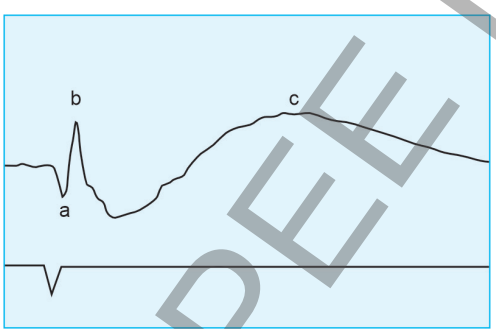

Fig. 13.6: Electroretinography.

- B wave:
  - Positive deflection
  - Elicited by Muller and bipolar cells

Oscillatory potentials: Small wavelets on ascending limb of B wave produced by amacrine cells.

- C wave:
  - Positive wave of RPE seen only in dark adapted eye
  - ERG measures mass retinal response.

Indications

- To diagnose generalized retinal degeneration—retinitis pigmentosa, congenital night blindness
- Amplitude of B wave decreased in anoxic conditions like CRAO and ischemic CRVO.

Electrooculogram (EOG)

- Measures standing potential between electrically +ve cornea and –ve back of eye
- Reflects activity of RPE and photoreceptors:
  - Electrodes are attached to skin near medial and lateral canthi
  - Patient asked to move eyes from side to side
  - When the eyes move, cornea near electrode becomes +ve with respect to other
  - Potential difference between the electrodes amplified and measured.

Uses

- To diagnose Best's disease and carriers:
  - Where ERG is normal but EOG is abnormal. EOG is more sensitive than ERG in diagnosis of retinitis pigmentosa
- To diagnose chloroquine toxicity.

Visual evoked potential (VEP) records electrical signal in response to light stimulus. It measures the integrity of visual pathway and is an objective indicator of optic nerve function.

Dark Adaptometry

- Ability to adapt to decreased illumination is measured
- Useful to diagnose night blindness.

Abnormal in:

- Pigmentary dystrophies of the retina
- Vitamin A deficiency
  - Glaucoma

After 5 minutes of light adaptation, the patient is seated in dark. Spots of increasing luminance are presented until seen by the patient.

JAYPEE BROTHERS

- Dark adaptation curve increases in sensitivity after 5–10 minutes
- Reaches plateau by 20 minutes.

Color Vision Tests

- Lantern test
- Holmgren wool test
- Farnsworth-Munsell 100-hue test
- Ishihara pseudoisochromatic charts
- Nagel anomaloscope.

Methods of Retinal Nerve Fiber Layer (RNFL) Assessment

- Red free filter indirect ophthalmoscope
- Fundus photography of RNFL
- **Newer methods:**
  - GDx vcc—scanning laser polarimetry
  - HRT
    - Heidelberg retinal tomograph
    - Confocal scanning laser ophthalmoscopy
  - Optical coherence tomography (OCT).

GDx vcc

- Measures thickness of RNFL in the peripapillary area
- Resolution up to 5 microns
- Can be used in undilated pupil
- Short test time – 3 minutes
- Used mainly in glaucoma.

HRT

- Analyses 3-dimensional images of optic nerve head and retina
- Pupil dilatation is necessary
- Test time –15 minutes
- Resolution –15 microns.

Optical Coherence Tomography

- Works similar to ultrasound but uses light waves instead of sound waves
- Gives cross image of the retina, adding third dimension viz. depth
- Clear media and pupillary dilation are necessary
- Test time – 15 minutes. Resolution – 10 microns.

Macular Hole with Vitreous Traction

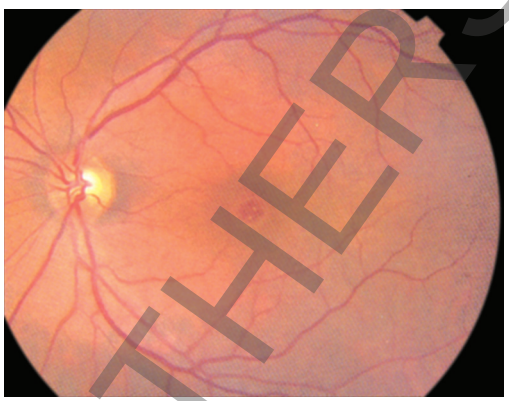

Fig. 13.7: Fundus picture of macular hole.

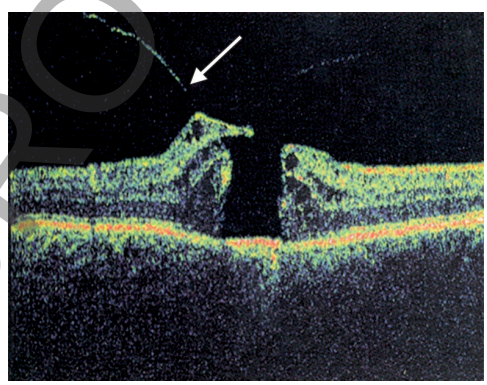

Fig. 13.8: Optical coherence tomography.

Uses

- To assess RNFL thickness in glaucoma
- To diagnose macular diseases such as:
  - Central serous retinopathy
  - Epimacular membrane
  - ARMD and macular hole.

4. Write short notes on retinal hemorrhages.

These are of two types:

i. **Superficial retinal hemorrhages**: Striate or flame shaped because they are situated in the nerve fiber layer. They are bright red and obscure retinal vessels. They are seen in:
   - Hypertensive retinopathy
   - Diabetic retinopathy

JAYPEE BROTHERS

- Central vein occlusion
- Anemia
- Leukemia
- AIDS.

ii. **Deep retinal hemorrhages**: These are rounded because they are situated in the outer plexiform layer. They are deep red and retinal vessels course over the hemorrhage. They are seen in diabetic retinopathy.

5. What are soft exudates (cotton wool spots)?

These are fluffy deposits with feathery edges lying in the nerve fiber layer. They obscure retinal vessels. It is due to ischemia and anoxia of the nerve fiber layer following occlusion of small vessels. Usually, disappear within 6–8 weeks. They are seen in:

- Hypertensive retinopathy
- Toxemia of pregnancy
- Papillitis and papilledema
- Anemia
- Leukemia
- AIDS.

6. What are hard exudates?

These are discrete yellowish-white plaques with a clear-cut margin. These are the result of a leak of plasma from capillaries with the absorption of fluid leaving behind the lipid material in the outer plexiform layer. These last some years. They are seen in:

- Diabetic retinopathy
- Coat's disease
- Circinate retinopathy
- Hypertensive retinopathy.

7. Describe the risk factors, pathogenesis, classification, clinical features, and management of diabetic retinopathy.

Retinal changes occurring due to diabetes mellitus.

Risk Factors

- Duration of diabetes:
  - 50% of patients develop retinopathy after 10 years
  - 70% of patients develop retinopathy after 20 years
  - 90% of patients develop retinopathy after 30 years
- Poor metabolic control
- Pregnancy
- Hypertension
- Nephropathy.

Local Protective Factors

- High myopia
- Chorioretinal scarring

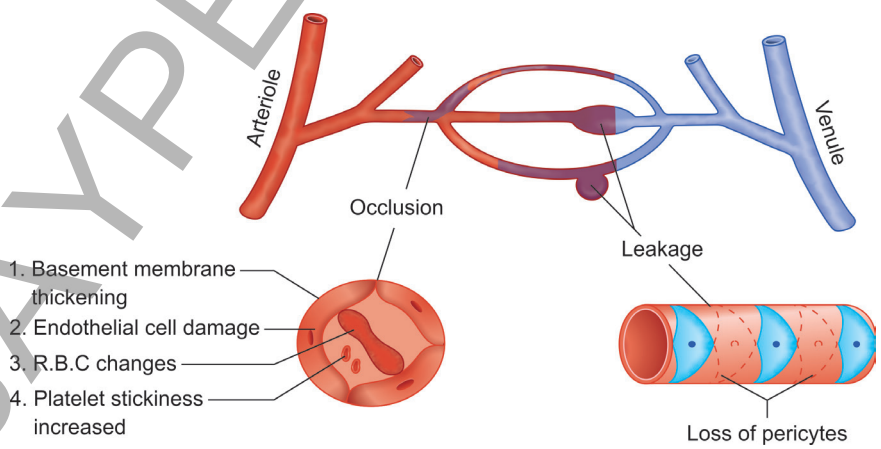

Fig. 13.9: Pathogenesis of diabetic retinopathy (DR).

JAYPEE BROTHERS

- Glaucoma
- Optic atrophy
- Retinitis pigmentosa

It is due to decreased retinal metabolic demand.

Pathogenesis

Microangiopathy

- Two important factors:
  a. Microvascular occlusion
  b. Microvascular leakage.

Microvascular Occlusion

- Capillary changes:
  - Loss of pericytes
  - Thickening of basement membrane
  - Proliferation of endothelial cells
  - Resulting in microaneurysms
- Hematological
  Deformation and aggregation of RBC and platelets resulting in decreased oxygen transport
  - Retinal hypoxia results in:
    - Arteriovenous shunts
    - Intraretinal microvascular abnormalities (IRMA). IRMA-shunts from arterioles to venules.

Neovascularization

- Liberation of vascular endothelial growth factor (VEGF) by the hypoxic retina
- Promotes neovascularization of the retina and optic nerve head
- Consequences of retinal ischemia.

Microvascular Leakage

- Breakdown of inner blood-retinal barrier
- Microaneurysms—weakening of capillary walls
- Increased vascular permeability resulting in focal or diffuse retinal edema—Hard exudates may occur in a circinate pattern.

Classification

- Eva Kohner's
- Early treatment diabetic retinopathy study (ETDRS).

Eva Kohner's Classification

- Background retinopathy
- Preproliferative retinopathy
- Proliferative retinopathy.

ETDRS Classification

- Background or non-proliferative (NPDR): It is characterized by microaneurysms, retinal edema, hard exudates, retinal hemorrhages, venous changes, cotton wool spots and IRMA (intraretinal microvascular abnormalities).
  - Mild
  - Moderate
  - Severe
  - Very severe
- Maculopathy with or without clinically significant macular edema (CSME)
- Proliferative diabetic retinopathy (PDR)
  - Without high-risk characteristics (HRC)
  - With HRC. *Nonproliferative retinopathy*.

Mild

- Few microaneurysms (MA)
  - Retinal hemorrhages
  - Hard exudates
  - Seen in 1 quadrant.

Moderate

Above features are seen in 2 or 3 quadrants.

Severe (Preproliferative Retinopathy)

- 4-2-1 Rule
- Defined as anyone of the following:
  - 4 quadrants of hemorrhages/microaneurysms

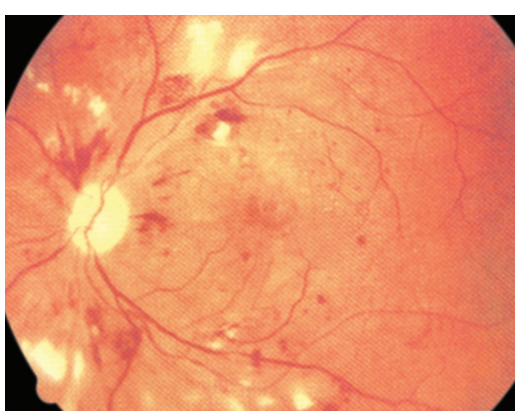

Fig. 13.10: Soft exudates.

JAYPEE BROTHERS

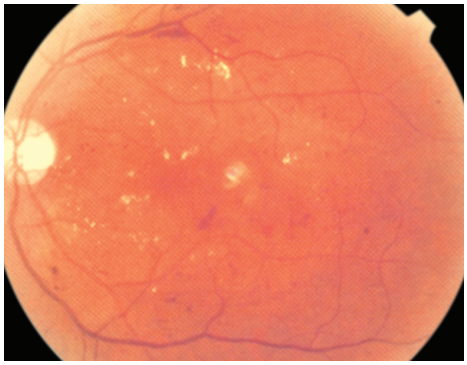

Fig. 13.11: Nonproliferative diabetic retinopathy—microaneurysms (MA) and dot and blot HGS.

- 2 quadrants of venous beading
- 1 quadrant of intraretinal microvascular abnormalities (IRMA).

Very Severe

Defined as 2 or more of the above features.

Proliferative Diabetic Retinopathy

Neovascularization of disk or elsewhere, with or without following three high-risk characteristics:

i. Neovascularization of disk (NVD) >1/4 to 1/3 disk area
ii. Any NVD with vitreous hemorrhage (VH)
iii. Neovascularization elsewhere (NVE) >1/2 disk area with VH.

PDR—High-risk

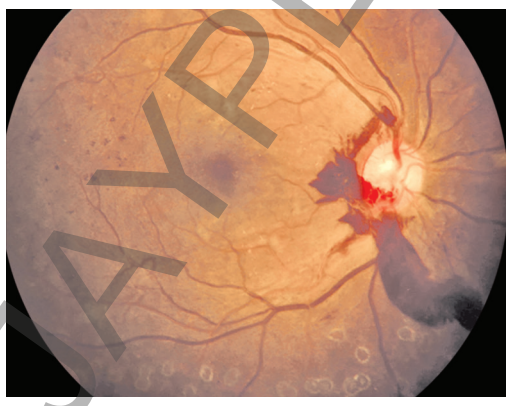

Fig. 13.12: Proliferative diabetic retinopathy—high-risk.

Proliferative DR

- New vessels on the disk (NVD)
- New vessels elsewhere (NVE).

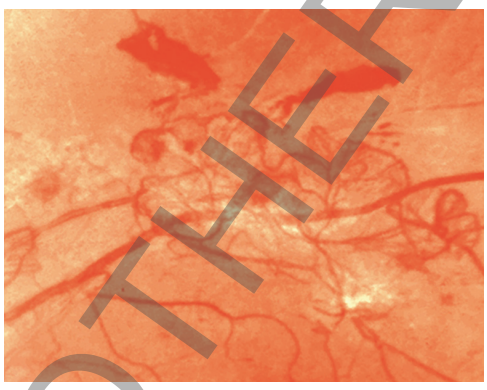

Fig. 13.13: New vessels on the retina with hemorrhages.

Maculopathy

- Clinically significant macular edema (CSME)
- Edema involving the center of the macula
- Seen with SL examination with +90 D lens:
  i. Thickening of the retina within 500 µ of foveal avascular zone (FAZ)
  ii. Hard exudates within 500 µ of FAZ with associated thickening of the adjacent retina
  iii. Zone of retinal thickening 1 disk area or larger any part of it is within 1 DD of the foveal center.

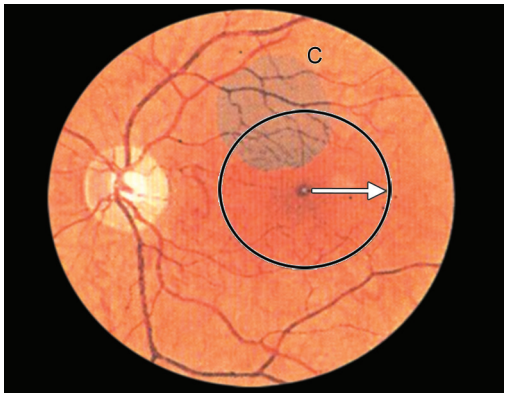

Fig. 13.14: Clinically significant macular edema.

JAYPEE BROTHERS

Three Criteria of Diabetic Macular Edema

Criteria 1

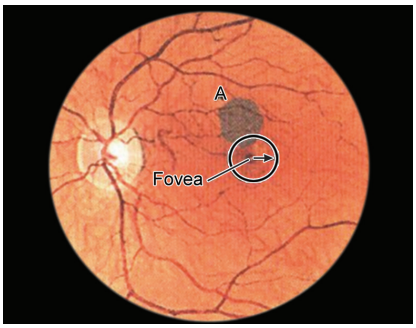

Fig. 13.15: Retinal thickening within 500 μ from the fovea.

Criteria 2

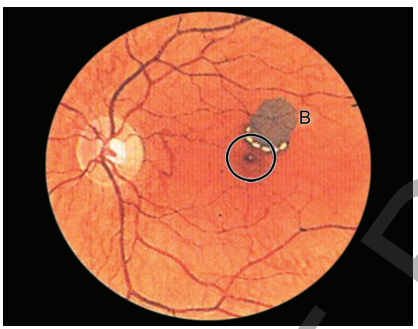

Fig. 13.16: Hard exudates within 500 μ of fovea with adjacent retinal thickening.

Criteria 3

Retinal thickening of >1 DD even if partly within 1 DD of the foveal center.

NPDR–CSME

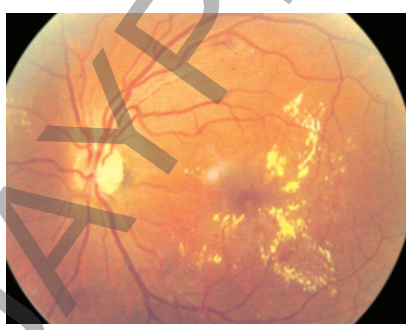

Fig. 13.17: Hard exudates in the macula with clinically significant macular edema in severe nonproliferative diabetic retinopathy.

Advanced Diabetes Eye Disease

- Persistent new vessels
- Tractional retinal detachment
- Neovascular glaucoma.

Advanced

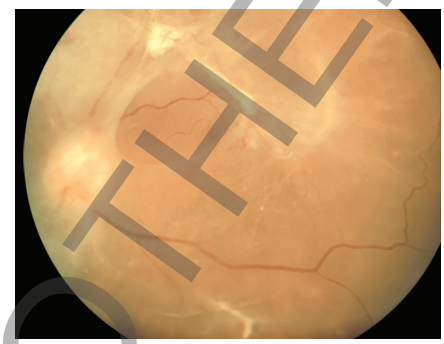

Fig. 13.18: Extensive avascular glial tissue and localized inferior retinal detachment in proliferative diabetic retinopathy.

Causes of Visual Loss

- In NPDR:
  - Macular edema or ischemia
- In PDR:
  - Tractional RD
  - Neovascular glaucoma
  - Vitreous hemorrhage.

Differential Diagnosis

- Hypertensive retinopathy
- Retinal vein occlusion
- Radiation retinopathy
- Ocular ischemic syndrome
- Anemia/leukemia.

Investigations

- Direct and indirect ophthalmoscopy
- Slit-lamp examination with 90 D lens
- Color fundus photography
- Fluorescein angiography
- Optical coherence tomography.

FFA – Indications

- All eyes with maculopathy
- Unexplained visual loss
- Asteroid hyalosis
- Doubtful diagnosis.

JAYPEE BROTHERS

Treatment

- Control of diabetes
- Laser
- Intravitreal injection of triamcinolone
- Surgery
- Low vision aids.

Treatment of DR

Based on several studies:

- Early Treatment Diabetic Retinopathy Study (ETDRS) – Role of focal laser
- Diabetic Retinopathy Study (DRS) – Role of PRP
- Diabetic Retinopathy Vitrectomy Study (DRVS) – Role of pars plana vitrectomy.
- Diabetic Control and Complications Trial (DCCT) – Control of DR in type I diabetes.
- United Kingdom Prospective Diabetes Study (UKPDS) – Control of DR in type II diabetes
- **Early treatment diabetic retinopathy study (ETDRS):**
  - Focal laser decreases vision loss from macular edema by 50%
  - No benefit from aspirin
- **Diabetic retinopathy study (DRS):**
  - Pan retinal photocoagulation (PRP) reduces the incidence of severe vision loss in high- risk PDR by 60%
- **Diabetic retinopathy vitrectomy study (DRVS):**
  - Early vitrectomy of vitreous hemorrhage in type I diabetic is advised
  - Can be deferred in type II diabetic
- **Diabetic control and complication trial (DCCT):**
  - In type I diabetics tight control of blood sugar decreases progression of retinopathy and macular edema
  - HbA1c <8% – reduced risk of retinopathy
  - Rapid normalization and tight control of blood sugar after a period of prolonged hyperglycemia can lead to worsening of retinopathy
- **United Kingdom prospective diabetes study (UKPDS):**
  - Tight control of blood sugar and blood pressure slows progression of retinopathy and development of macular edema in type II diabetic patients.

Control of Diabetes

- DCCT for IDDM
- UKPDS for NIDDM.

Important Studies in DR

- DRS: Role of PRP
- DRVS: Role of PPV (pars plana vitrectomy)
- ETDRS: Role of focal laser- CSME.

For CSME

- Focal laser
  - Argon green is preferred
  - Yellow laser can also be used.

For PDR

- Pan retinal photocoagulation (PRP) – Spot size 500 µ, duration 0.15 sec, number of burns 1,200–1,600, burns of moderate intensity placed ½ to 1 burn apart
- Panretinal photocoagulation
- Criteria – high-risk characteristics in PDR.

Intravitreal Injections

- *Steroids:* IV Triamcinolone/Ozurdex
  - These are first line of treatment for center involving macular edema
- Antivascular endothelial growth factors (anti-VEGF):
  - Bevacizumab (Avastin)
  - Ranibizumab (Lucentis)
  - Aflibercept (Eylea).

Surgical Treatment

- Vitreoretinal surgery
- Pars plana vitrectomy
- Endolaser photocoagulation
- Release of tractional bands
- Removal of subretinal neovascular membrane
- Treatment of retinal detachment (RD).

Surgery: Pars Plana Vitrectomy (PPV)

- Non-clearing vitreous hemorrhage
- Tractional RD affecting fovea

JAYPEE BROTHERS

- Combined RD (with hole and traction)
- Taut posterior hyaloid
- Persistent macular edema
- Vitreomacular traction
- Removal of membranes: Segmentation/delamination
- **Laser:** PRP or tamponade only for breaks.

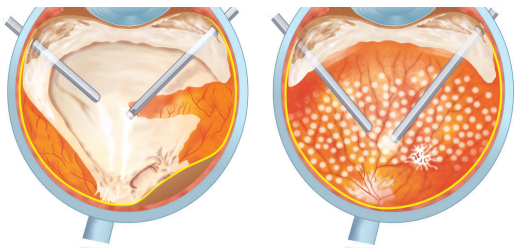

Fig. 13.19: Removal of tractional membrane and endolaser photocoagulation.

Diabetic Retinopathy: Treatment Guidelines

- Background:
  - Control of diabetics
  - Regular review
- Maculopathy:
  - CSME-anti VEGF agents
  - Focal leak
  - Circinate retinopathy—focal photocoagulation
  - Diffuse leak around macula—grid laser
- Pre-proliferative retinopathy—frequent review
- Proliferative retinopathy—PRP
- Advanced diabetic eye disease—vitreoretinal surgery and photocoagulation.

Diabetic Retinopathy Screening: Guidelines by AAO* and AADA**.		
	First examination	***Review***
• Type I diabetic	5 years after onset of diabetes	Every year
• Type II diabetic	At the time of diagnosis	Every year
• During pregnancy women with Diabetic	First trimester	3 Monthly

AAO*: American Academy of Ophthalmologists; AADA**: American Academy of Diabetic Association.

Review of Patients with Diabetic Retinopathy.	
Mild NPDR	12 Months
Moderate NPDR without macular edema	6–12 months
Moderate NPDR with non CSME	4–6 months
NPDR with CSME PDR	3–4 months

8. Discuss the pathogenesis, classification, clinical features and complications of hypertensive retinopathy.

Introduction

Retinal changes occurring due to hypertension.

Predisposing Factors

- Severity of hypertension
- Duration
- Age of patient:
  - In young—narrowing of retinal arterioles due to spasm
  - In aged—depends on pre-existing involutional sclerosis.

Pathogenesis

Results from three changes:

i. Vasoconstriction
ii. Atherosclerotic changes
iii. Increased vascular permeability

Vasoconstriction

- Primary response of retinal arterioles is narrowing:
  - In pure form—seen in young
  - In aged people
- Narrowing modified by rigidity of arterioles from involutional sclerosis.

Atherosclerotic Changes

- Manifests as changes in arteriolar reflex and AV crossing changes
- Thickening of vessel wall due to involutional sclerosis.

Increased Vascular Permeability

- Disruptions of inner blood-retinal barrier due to retinal hypoxia:
  - Narrowing of retinal arteriole
  - Retinal ischemia

JAYPEE BROTHERS

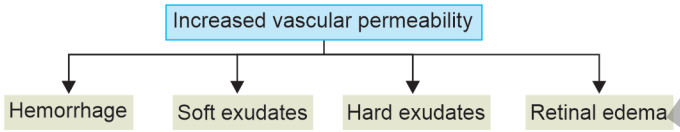

Phases of Retinopathy

- Vasoconstrictive phase
- Sclerotic phase
- Exudative phase
- Complication of sclerotic phase.

Phase: 1 and 2—asymptomatic
3 and 4—vision is affected

Vasoconstrictive Phase

- Focal and diffuse constriction of arteries
- Occurs in 2nd and 3rd order arteries
- Common in young patients.

Sclerotic Phase: Sets in where BP Remains Elevated for Prolonged Period

- Narrowing of arteries
- AV crossing changes
- Sclerosis of vessel walls (copper/silver wiring)
- Vascular tortuosity
- Increased angle of branching of arterioles.

Exudative Phase

- Flame-shaped hemorrhages
- Cotton wool spots
- Hard exudates
  - Macular star
  - Circinate retinopathy.

Complications of Sclerotic Phase

- Central or branch vein occlusion
- Macular edema
- Neovascularization.

Classification

Depends on inter-relationship of arteriosclerotic and hypertensive changes

- Keith-Wagner-Barker
- Scheie.

Keith-Wagner-Barker Classification

Helps in assessing damage to heart, brain and kidneys.

Grades of HR	*Fundus picture*	*Cardiorenal function*
Grade 1 Mild	Mild to moderate narrowing or sclerosis of arteries	Normal
Grade 2 Moderate	Moderate to marked arteriolosclerosis and exaggeration of light reflex. Salus' sign	Satisfactory
Grade 3 High and sustained	Marked retinal arteriolar narrowing and focal constriction cotton wool exudate superficial hemorrhage. Gunn's sign and Bonnet's sign	Evidence of cardiorenal disease
Grade 4 Malignant	Grade 3 plus macular star and disk edema	Marked cardiorenal damage

Scheie's Classification

Mainly based on arteriosclerosis:

- Grade 1:
  - Generalized arteriolar attenuation
  - Broadening of arteriolar light reflex
  - Concealment of vein at AV crossing.
- Grade 2:
  - Severe generalized and focal arteriolar constriction
  - Right angled deflection of veins—Salus' sign
- Grade 3:
  - Copper wiring of arterioles
  - Gunn's sign: Venous tapering on either side of crossing
  - Bonnet's sign: Banking of veins distal to AV crossings

JAYPEE BROTHERS

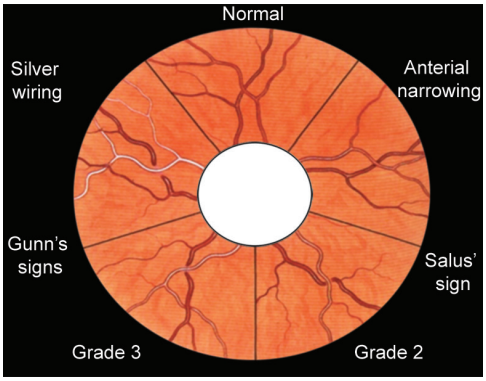

Fig. 13.20: Hypertensive retinopathy.

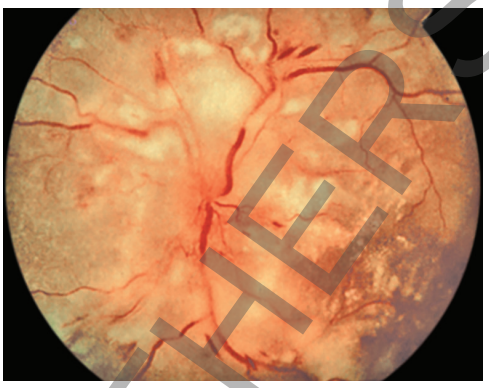

Fig. 13.22: Disk edema.

- Flame-shaped hemorrhages
- Cotton wool spots
- Hard exudates

- Grade 4:
  - All changes in grade III with
  - Silver wiring of arterioles
  - Disk edema

Fundus Picture

- **Retinal changes:**
  - Arterial narrowing
  - Vascular leakage
  - Arteriosclerosis
- **Choroidal changes:**
  - Elschnig's spots
  - Siegrist streaks
  - Exudative RD.

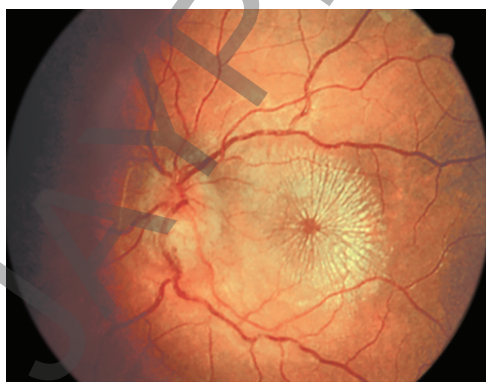

Fig. 13.21: Macular star.

Retinal Changes

- Arterial narrowing:
  - Focal or generalized
  - Obstruction of precapillary arterioles
  - Cotton wool spots
- Vascular leakage:
  - Flame-shaped hemorrhages
  - Retinal edema
  - Macular star
  - Disk edema
- Arteriosclerosis:
  - Thickening of vessel wall
  - Changes at AV crossing.

Grade 1: Generalized arteriolar attenuation,

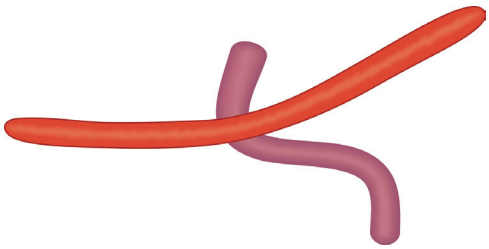

Fig. 13.23: Salus' sign—superficial artery deflects the course of underlying vein.

Grade 2: Broadening of arteriolar light reflex Deflection of vein at AV crossing – Salus' sign.

Salus' sign: Deflection in the course of the vein at arteriovenous crossings.

JAYPEE BROTHERS

Grade 3:

- Copper wiring:
  - Banking of veins distal to AV crossing—Bonnet's sign
  - Tapering of veins on either side of crossings—Gunn's sign.



Fig. 13.24: Silver wiring of arterioles in grade 4 hypertensive retinopathy.

Grade 4:

- Grade 3 changes plus
- Silver wiring of arterioles.

Choroidal Changes

Rare: May occur due to acute hypertensive crisis in young adults.

- **Elschnig's spots:**
  - Focal choroidal infarcts
  - Small black spots surrounded by yellow halos
- **Siegrist's streaks:**
  - Due to fibrinoid necrosis seen in malignant hypertension
  - Seen as flecks arranged linearly along choroidal vessels
- Exudative retinal detachment seen in toxemia of pregnancy.

Complications of Hypertensive Retinopathy (HR)

- Retinal vein occlusion
- Retinal artery occlusion
- Retinal artery macroaneurysm
- Anterior ischemic optic neuropathy (AION)
- Ocular motor nerve palsy
- Aggravation of diabetic retinopathy.

Management of Hypertensive Retinopathy (HR)

Medical control of hypertension essential for good visual function and long-term survival of patients:

- BP to be lowered gradually
- General measures—weight control, sodium restriction, and exercise.

9. Describe the retinopathy of toxemia of pregnancy.

- Occurs in last trimester of pregnancy
- Consists of triad of hypertension, proteinuria and edema—preeclampsia
- Headache, vomiting, convulsion, eclampsia.

Fundus Picture

Three Stages:

i. Stage of angiospasm
ii. Stage of sclerosis of vessels
iii. Stage of retinopathy
  - Retinal changes run parallel with severity of hypertension.

Stage of Angiospasm

- Due to liberation of toxin
- Attenuation of retinal arteriole—starts in nasal periphery
- May become generalized due to spasm.

Stage of Sclerosis

Arteriovenous crossing signs occur:

- Salus' sign
- Gunn's sign
- Bonnet's sign.

Stage of Retinopathy

- Superficial and deep hemorrhages
- Retinal edema
- Exudative retinal detachment.

Complications

- Complete loss of vision
- Loss of life of mother and fetus.

JAYPEE BROTHERS

Treatment

- Prevention—adequate antenatal care
- Control of high BP—rest, sedation and salt restriction
- Diuretics and antihypertensives.

Role of Ophthalmologist

- Diagnosis of early retinopathy
- Advised termination of pregnancy to avoid maternal mortality
- Prognosis—good for life and vision following termination of pregnancy.

10. What are the types of obstruction of retinal vessels?

- **Retinal artery occlusion:**
  - Central retinal artery occlusion
  - Branch retinal artery occlusion
  - Cilioretinal artery occlusion
- **Retinal vein occlusion:**
  - Central retinal vein occlusion (CRVO)
  - Branch retinal vein occlusion (BRVO)
  - Hemi-retinal vein occlusion.

11. Discuss the causes, clinical features, differential diagnosis and treatment of central retinal artery occlusion (CRAO).

Causes of CRAO

- Spasm of vessels
- Atherosclerosis
- Carotid embolism
- Cardiac embolism
- Giant cell arteritis
- Periarteritis.

Spasm of Vessels Occurs in Young

For example: Toxemia of pregnancy and quinine toxicity.

Atherosclerosis Related Thrombosis—80%

- Carotid artery atherosclerosis is the most common cause of CRAO
- Occurs at the level of lamina cribrosa
- Occurs in older age when they have hypertension.

Carotid Embolism

- Most common cause of branch retinal artery occlusion (BRAO).
- Cholesterol embolic (Hollenhorst plaques) located at arteriolar bifurcation—bright refractile golden to yellow orange crystals
- Fibrin-platelet emboli:
  - Dull gray elongated particles fill the lumen
  - Transient ischemic attacks
  - Amaurosis fugax
- Calcific emboli:
  - From atheromatous plaques
  - Often close to disk
  - May causes permanent occlusion of CRA or its branches.

Cardiac Embolism

The ophthalmic artery is the first branch of internal carotid artery. Hence embolic material from the heart and carotid arteries has a fairly direct route to the eye.

- 20% of retinal occlusion
- Calcification
- Vegetation
- Thrombus.

Giant Cell Arteritis

Periarteritis

Connective tissue disorders

Symptoms: Painless sudden loss of vision

Signs: In complete block

- Amaurotic pupil
- Fundus: Attenuation of artery
- Appear extremely thin and thread like
- Veins: Usually normal
- *Cherry-red spot*:
  - Striking cherry-red spot at the macula
  - Retina becomes edematous and milky white
  - Choriocapillaris shine against white background of macula.

JAYPEE BROTHERS

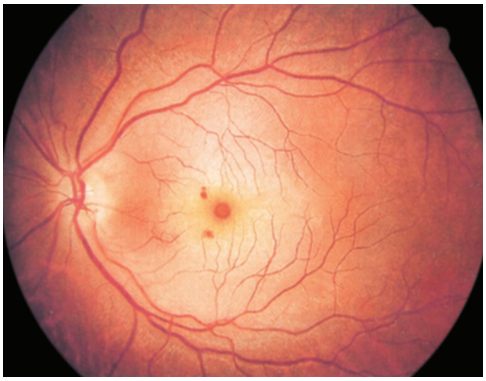

Fig. 13.25: Cherry-red spot.

Partial Occlusion of CRA

- Column of venous blood break into red beads
- Separated by clear interspaces which moves to and fro by gentle pressure on eyeball
  - Cattle truck appearance
- Cattle-track appearance—the arteries show a segmented column of blood with stagnation of blood flow.

Cilioretinal Obstruction

- Cilioretinal artery present in 20% of population
- Arises from posterior ciliary artery circulation
- Supplies macula and papillomacular bundle.

Complications of CRAO

- Optic atrophy
- Rubeosis iridis.

Differential Diagnosis – CRAO

Sudden Painless Loss of Vision

- CRAO and CRVO
- Retinal detachment
- Vitreous hemorrhage
- Methyl alcohol poisoning
- Occipital lobe infarction
- Hysteria and malingering
- AION – nonarteritic type.

Causes of Cherry-red Spot

- CRAO
- Tay-Sachs disease
- Niemann-Pick disease
- Sandhoff's disease
- Gaucher's disease
- Quinine toxicity
- Berlin's edema
- Macular hole.

Treatment of CRAO

Ocular emergency—to be started within 90 minutes.

- Patient to lie flat
- Firm ocular massage—intermittent pressure for 15 minutes
- Sublingual isosorbide dinitrate—for dilatation
- Lowering of IOP—IV acetazolamide 500 mg followed by 20% mannitol
- Inhalation of carbogen (95% oxygen and 5% carbon dioxide mixture)
- Anterior chamber paracentesis
- IV streptokinase 7,50,000 units to disintegrate fibrin emboli along with IV methyl prednisolone 500 mg, to reduce allergy to streptokinase
- Retrobulbar (RB) injection of tolazoline 50 mg to decrease RB resistance to flow.

12. What are the types of retinal vein occlusions?

- Central retinal vein occlusion (CRVO)
- Branch retinal vein occlusion
- Hemiretinal vein occlusion.

13. Discuss the pathogenesis, clinical features, complication, and treatment of central retinal vein occlusion.

Pathogenesis

Atherosclerosis of retinal artery or arteriole important factor in CRVO and BRVO due to sharing of common adventitial sheath.

JAYPEE BROTHERS

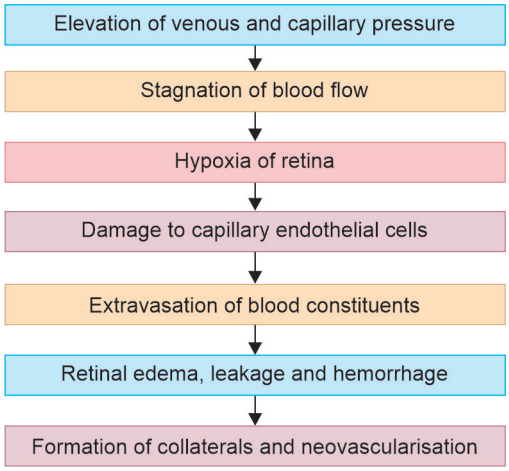

Thickness of artery compresses vein—precipitates CRVO or BRVO.

Risk Factors of CRVO

- Advancing age
- Systemic conditions
  - Hypertension, hyperlipidemia, diabetes
- Raised IOP
  - POAG
  - Ocular hypertension
- Inflammatory diseases
  - Sarcoidosis
  - Behcet's disease
- Hyperviscosity
  - Polycythemia, macroglobulinemia
- Acquired thrombophilic disorders
  - Hyperhomocysteinemia
- Inherited thrombophilic disorders
  - Increased level of clotting factors 7 and 11
  - Deficiencies of anticoagulants.

Types of CRVO

- Nonischemic
- Ischemic.

Features	*Nonischemic CRVO*	*Ischemic CRVO*
Incidence	70%	30%
Vision	>6/60	<6/60
Pupil	Relatively normal	RAPD
Hemorrhages	Dot and blot	Flame shaped
Cotton wool spots	Few	Numerous
Retina	Relatively normal	Edematous retina
Retinal nonperfusion	<10 disk diopters	>10 disk diopters
Risk for neovascularization	Low	High
Prognosis	Good	Bad

Ischemic CRVO—usually occurs in elderly patients with cardiovascular disorder. Fundus examination will reveal markedly enlarged and tortuous retinal veins. Retinal hemorrhages are so extensive, it will present as 'tomato splash' appearance.

Complications

- Iris neovascularization
  - More common than NVD or NVE
- 100th day glaucoma—seen in ischemic variety of central retinal vein occlusion due to new vessels in the angle of AC
- Tractional retinal detachment
- Vitreous hemorrhage
- Macular edema.

Treatment of CRVO

- Treat the underlying cause, manage IOP
- Intravitreal anti-VEGF
- Monthly follow up with gonioscopy during first 6 months after CRVO
- PRP for ischemic CRVO when 2 clock hours of neovascularization iris (NVI) or any angle NV is present.

14. Write short notes on branch retinal vein occlusion.

- Major branch vein occlusion
- Minor branch vein occlusion
- Peripheral branch vein occlusion.

Types of Branch Retinal Vein Occlusion

- Nonischemic
  - <5 DD of capillary nonperfusion

JAYPEE BROTHERS

- Ischemic
  - >5 DD of capillary nonperfusion.

Features of Branch Retinal Vein Occlusion

- Flame-shaped and dot-blot hemorrhages
- Retinal edema
- Cotton wool spots.

Fluorescein Angiogram (FA)

- *Early phase:* Hypofluorescence due to blockage of choroidal fluorescence by hemorrhages
  - *Late phase:* Hyperfluorescence due to leakage.

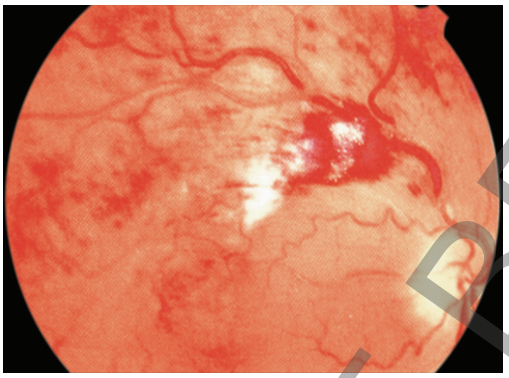

Fig. 13.26: Superotemporal branch retinal vein occlusion.

Prognosis

- Usually good
- Within 6 months, 50% of eyes develop collaterals and vision returns.

Complications

- Chronic macular edema
- Neovascularization:
  - NVD – 10%
  - NVE – 20–30%.

Treatment

- Macular edema and vision <6/12 for 3 months
  - Grid laser photocoagulation
- Neovascularization—scatter laser
  - >5 DD of nonperfusion—PRP.

15. Write short notes on hemiretinal vein occlusion.

- Less common than CRVO or BRVO
- Involves occlusion of superior or inferior branch of CRVO
- Treatment—depends on severity of ischemia
- Similar to ischemic CRVO.

16. Discuss the pathogenesis, clinical features, differential diagnosis, and treatment of retinal detachment (RD).

Definition

Separation of sensory retina from retinal pigment epithelium by subretinal fluid (SRF).

Classification

- Rhegmatogenous
- Nonrhegmatogenous:
  - Tractional
  - Exudative.

Rhegmatogenous RD

- Occurs due to full thickness defect in sensory retina
- SRF from liquefied vitreous enters subretinal space
- Prevalence—1 in 10,000 eyes
- More common in myopia.

Tractional RD

Sensory retina pulled away from RPE by contracting vitreoretinal membrane.

Causes

- Proliferative diabetic retinopathy
- Retinopathy of prematurity
- Sickle-cell retinopathy
- Penetrating posterior segment trauma.

Exudative RD

- Fluid derived from choriocapillaris
- Gain access to subretinal space through damaged RPE.

JAYPEE BROTHERS

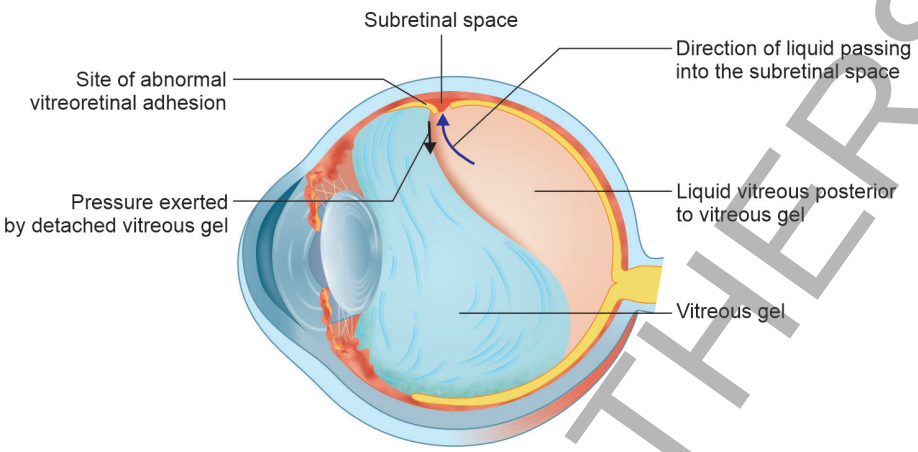

Fig. 13.27: Mechanism of rhegmatogenous retinal detachment.

Causes

- Choroidal tumors
- Exophytic retinoblastoma
- Harada's disease
- Toxemia of pregnancy
- Posterior scleritis
- Subretinal neovascularization.

Pathogenesis

Rhegmatogenous detachment

Underlying mechanism:

- Retinal breaks
- Vitreous traction
- Retinal breaks occur in 5–10% of population
- 70% of breaks are located superiorly between 10 o'clock and 2 o'clock position.

Mechanism of Rhegmatogenous Detachment

- Liquefied vitreous
- Posterior vitreous detachment
- Retinal breaks
- Failure of RPE pump.

Tractional Detachment

- Vitreous traction tears the retina
- Formation of vitreous membrane
- Contraction of fibrous bands
- Bleeding induces fibroblastic proliferation
- Bands pull the retina
- Traction detachment sets in.

Exudative Detachment

- Causes—tumors of retina and inflammatory diseases
- Due to damage to RPE allowing fluid to leak into subretinal space.

Examination Techniques

- Direct ophthalmoscopy
- Indirect ophthalmoscopy
- Goldmann 3 mirror examination
- Slit-lamp examination with +78 D lens or +90 D lens
- B-scan.

Clinical Features

Rhegmatogenous detachment.

Symptoms

- Variable
- Photopsia (seeing flashes of light)
- Metamorphopsia (seeing distorted images)
- Showers of black spots
- Cloudy vision.

Signs

Schaeffer's sign: Slit-lamp examination showing fine pigmented cells or tobacco dusting on anterior face of vitreous or in anterior chamber, with no previous eye disease, trauma, surgery or inflammation.

JAYPEE BROTHERS

Diagnostic of retinal break:

- Detached retina presents as white or gray discoloration with folds, which oscillates on ocular movement.
- Retinal vessels crossing over detached retina look darker



Fig. 13.28: Horseshoe tear.

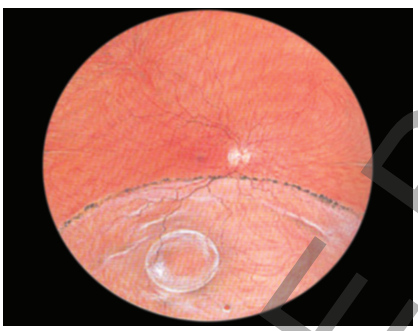

Fig. 13.29: Old retinal detachment.

Peripheral lesions require scleral indentation:

- Breaks will be seen
- Low IOP
- Visual fields—scotoma corresponding to area of detachment
- ERG—subnormal or absent
- B-scan—reveals detachment

Shows marked pallor of the detached retina. There is a subretinal vacuole seen.

Clinical features of exudative detachment

- Detached retina—convex smooth surface
- No retinal break
- Shifting of SRF on head movements
  - *Pathognomonic:* In upward position, sub retinal fluid collects under the inferior retina due to gravity and in supine position, inferior retina flattens and the SRF shifts posteriorly to macula and superior retina.
- Diminution of vision
- Black floaters
- No photopsia
- Fundus
  - Smooth convex gray discoloration
  - No retinal breaks
- Raised IOP if associated with tumors
- Visual fields—scotoma
- Transillumination—negative if due to tumors.

Clinical Features of Tractional Detachment

- Smooth surface, usually taut, and immobile
- Concave towards the front of eye
- Usually limited to posterior fundus
- Breaks are usually absent.
  - To differentiate various types of RD **see Table in Question no. 17**.

Differential diagnosis:

- Senile retinoschisis
- Choroidal detachment.

Senile retinoschisis

Separation at the level of Outer Plexiform Layer (In congenital retinoschisis separation occurs at the nerve fibre layer).

Common in lower temporal, bilateral smooth, thin convex elevation, immobile, and transparent inner retinal layer

- Sheathing of vessels
- No demarcation line
- Absolute field defect.

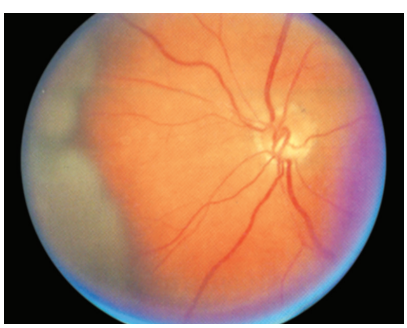

Fig. 13.30: Choroidal detachment.

JAYPEE BROTHERS

Choroidal detachment

Separation between RPE and choroid due to fluid or blood in suprachoroidal space:

- Smooth, brown, dome shaped elevation, and bullous
- Very low IOP
- Ora serrata can be seen with scleral depression

Difference between retinal detachment and choroidal detachment.

	Retinal detachment	*Choroidal detachment*
Color	Pale	Darker/normal color
Dome	Convex corrugated	Convex smooth
Breaks	Present	Absent
Ora serrata	Visible with indentation	Easily visible
Maximal extent	Anterior: Ora serrata Posterior: Unlimited	Anterior: Ciliary body Posterior: Vortex veins

Goals of Treatment

- Identify all retinal breaks
- Close all breaks
- Place scleral buckle to support all retina breaks
- Retinal tears should be flat on buckle.

Treatment of Rhegmatogenous RD

Rhegmatogenous detachment:

- Seal and support the break
- Sealing can be done by cryopexy, photocoagulation or diathermy
- Scleral buckle supports the break by reducing the vitreoretinal traction as well as apposing RPE to the sensory retina
- Retinal detachment with vitreoretinal traction or proliferative vitreoretinopathy require pars plana vitrectomy
- Prophylactic photocoagulation or cryopexy is recommended in high myopia with lattice degeneration or holes in ora serrata.

Treatment

- Scleral buckling
- Drainage of subretinal fluid
- Intravitreal injections
- Pneumatic retinopexy
- Pars plana vitrectomy.

Scleral Buckling

- It is a surgical technique for creating an inward indentation of the sclera
- Explant is the material directly sutured to the sclera to create a buckle.

Types of explants

- Radial explant—placed at right angles to the limbus
- Circumferential explant:
  - Segmental
  - Encircling

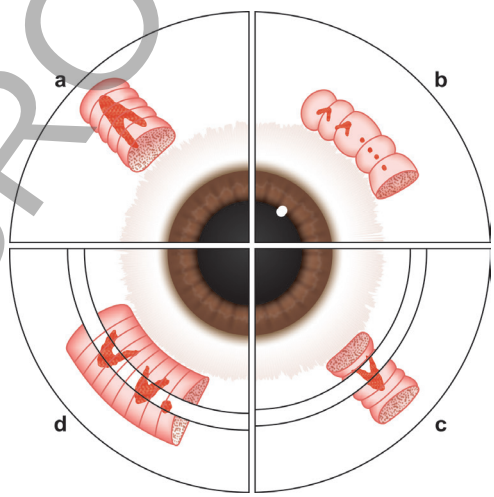

Fig. 13.31: Types of scleral buckling.

- Silicone sponges:
  - Hard and soft
    a. Radial sponge
    b. Circumferential sponge
    c. Encirclement with radial sponge
    d. Encirclement with solid silicone tyre.

Intravitreal Injections

- Air
- Saline
- Expanding gases
- Silicone oil
- Perfluorocarbons.

JAYPEE BROTHERS

Exam Preparatory Manual for Undergraduates

Ophthalmology

Salient Features

- This updated comprehensive manual covers answers for **theory, clinical and viva questions**, along with **multiple choice questions as per the competency-based curriculum**. It has been prepared as per the **latest competency-based NMC guidelines**.
- It facilitates **MBBS students to perform better in the university examination**, with all answers given as per the **expectation of the examiners.** It is a concise book with relevant material explained in a **simplified manner**.
- Numerous **tables, diagrams and flowcharts** have been included for better understanding of the subject. The book is also useful for **optometry students**, while the basics explained are useful for **postgraduate students** as well.
- It provides a **quick reference to the main aspects of Ophthalmology** in an easily reproducible manner, making it useful for **rapid revision and understanding the essential concepts in Ophthalmology**.
- This concise manual will provide **sure success to the students** and facilitate them to **secure high marks in the examination**.

K Mohan Raj did MBBS, DO, and MS in Ophthalmology from a premier institute, namely Madras Medical College at Chennai, Tamil Nadu. He has been teaching Ophthalmology for more than 40 years. He has been Professor for the past 25 years. He has worked in government and private medical colleges. He was awarded various awards for teaching. He was an examiner in various states from National Board of Examination. He was Director and Superintendent of the Regional Institute of Ophthalmology, Government Ophthalmic Hospital, Chennai, Tamil Nadu, India.

JAYPEE BROTHERS

Shelving Recommendation
OPHTHALMOLOGY

ISBN 978-81-6770-818-2

Buy from ejaypee

JAYPEE