aypee.com, for detailed information on obstetrics and gynecology books, visit our website www.ejaypee.com, for detailed information on obstetrics and gynecology books

Companion for Obstetrics & Gynecology Practical Examination

Haresh U Doshi



17th Edition

JAYPEE

JAYPEE BROTHERS

Contents

1. Instruments 1
2. Catheters 33
3. Suture Materials and Needles 39
4. Obstetric Forceps and Vacuum Extractor 47
5. Contraception 58
6. MTP, POCSO Act 83
7. Intravenous Fluids and Administration 92
8. Drugs 99
9. Obstetric Operations 134
10. Gynecological Procedures and Operations 152
11. Bony Pelvis and Fetal Skull 180
12. Obstetric Cases Proforma: Antenatal and Postnatal 190
13. Mechanism of Labor 200
14. Induction of Labor 211
15. Ultrasonography, X-rays, MRI 215
16. Specimens 237
17. Scores, Tests, FIGO Staging, Classifications 251
18. Miscellaneous 263

Course of Practical Exam 272

Index *273*

JAYPEE BROTHERS

CHAPTER

4 Obstetric Forceps and Vacuum Extractor

Obstetric forceps were invented by doctors of Chamberlen family in England during the 17th century. It was kept as a family secret for almost three generations. More than 700 types of forceps have been invented up till now. In last two decades, the incidence of instrumental deliveries has decreased a lot and is still decreasing. Lack of adequate training during residency, fear of complications, and the risk of litigation, along with the rise in the incidence of cesarean sections, are responsible.

TYPES OF FORCEPS

Different types of forceps include short forceps (e.g., Wrigley's, Simpson's short), long forceps (with or without axis traction, e.g., Simpson's long, Das'), rotational forceps (e.g., Kielland, Moolgaoker, Barton) and special forceps (e.g., Hale forceps for cesarean section or Piper's forceps for aftercoming head of breech).

Only **short forceps** are used at present.

Description

All forceps have same fundamental parts. Each has two metal branches called blades articulated by a lock.

Each pair of forceps consists of following parts **(Fig. 4.1)**:

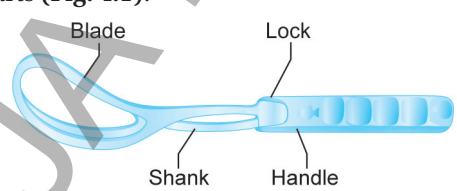

Fig. 4.1: Parts of forceps.

Blades

They are usually fenestrated for better grip on fetal head. Each blade has two curves.

Cephalic Curve

It is the curve on the flat. It fits over the fetal head. Its radius is 11.25 cm in Simpson's long forceps.

Pelvic Curve

It is the curve on the edge. It fits the curve of maternal pelvis. Its radius is 17.5 cm. It may be absent in some short forceps, i.e., Simpson's short forceps.

The blade which lies on the right side of maternal pelvis is called the **right blade** and that which lies on the left side is called the **left blade.** When articulated, the maximum distance between the two blades in standard forceps is 9.0 cm.

Shank

It is the portion between the blade and the lock. It may be parallel or overlapping. It is 6.25 cm long in Simpson's long forceps.

Lock

Usually it is English type, i.e., double slot lock, slot in each blade fitting with each other.

Handle

It is a long metal rod, 12.5 cm long in Simpson's long forceps. It may have finger grips or rests which flare outside or fixation screw for secure grip.

JAYPEE BROTHERS

Forceps with different axis traction devices are **not** used in modern times.

Cephalic curve radius	: 11.25 cm
Pelvic curve radius	: 17.5 cm
Maximum distance between 2 blades	: 9.0 cm
Distance between 2 tips	: 2.5 cm
Shank	: 6.25 cm
Handle	: 12.5 cm
Total length long forceps	: 37.0 cm

Types of Forceps Operation

American College of Obstetricians and Gynecologists classified forceps application as follows:

Outlet Forceps

- Scalp is visible at introitus without separating the labia.
- Fetal skull has reached the pelvic floor.
- Sagittal suture is in the anterior-posterior diameter or in the right or left occiput anterior or posterior position.
- Fetal head is at or on the perineum.
- Rotation does not exceed 45°.
- The station happens to be +3 or more.

Low Forceps

The leading point of the fetal skull is at station +2 or more but not on pelvic floor. Rotation is divided into 45° or less and more than 45° in anterior or posterior positions.

Midforceps

The station is above +2 cm, but the head is engaged. (High forceps were removed from the classification)

Functions of Forceps

- **Traction:** It is the most important function. With each individual traction, average force applied is usually 16–18 kg in weight for primigravida and 12–13 kg for parous patient.
- **Rotation:** Kielland forceps are best for the purpose. Rotational forceps are **not** done in modern obstetrics due to lack of skill and training and high safety of cesarean section.
- **Compression:** Because forceps act as the first type of lever with the fulcrum in the middle, compression even if unintended, is unavoidable. Only enough compression to ensure a safe grip (to prevent slipping) is needed. When correctly applied, only this type of compression is achieved.
- **Flexion:** Pulling in backward direction encourages flexion.

Indications

A. Fetal

1. Suspected or proved fetal compromise (fetal distress)—abnormal fetal heart rate patterns, thick meconium or abnormal fetal blood sampling results.
2. Failure to progress in labor due to fetal causes such as malrotation, deflexion or large size fetus.
3. Prolonged second stage of labor due to fetal causes like malrotation or large size fetus. More than 2 hours in a primigravida and >1 hour in a parous patient is considered as prolonged (1 hour extra is allowed in both if epidural is given for labor analgesia).
4. Delivery of aftercoming head of breech.

B. Maternal

- Prolonged second stage of labor, which may be due to rigid perineum, weak uterine action or pendulous abdomen.
- Inability to bear down due to frank exhaustion, excessive sedation or epidural analgesia.
- To give less strain to mother in certain medical and obstetric disorders (prophylactic forceps):
  - *Obstetric*: **P**regnancy induced hypertension, eclampsia.
  - *Medical*: **V**alvular heart disease, pulmonary tuberculosis and other lung diseases, acute or chronic liver diseases,

JAYPEE BROTHERS

acute or chronic kidney diseases, general debility, anemia, diabetes, etc.

C. Others

- Trial forceps in borderline CPD cases.
- To end successful trial of labor.
- Previous one LSCS—to give less strain to the scar.
- During cesarean section-outlet forceps or its one blade can be used to deliver the head.

Common indications: Fetal distress, prolonged second stage of labor and to give less strain to mother in certain medical and obstetric disorders.

Contraindications

- Incompletely dilated cervix
- Nonengaged head
- Moderate or severe degree contracted pelvis
- Malpresentation-brow, face-mentoposterior
- Contraction ring dystocia
- Pelvic tumors
- Fetal malformations

Pre-requisites

- **The pelvis must be adequate.** There should not be any cephalopelvic disproportion (CPD). Thorough clinical pelvimetry and estimation of fetal weight should be done.
- **Cervix must be fully dilated (10 cm)** and fully effaced in between pains. Forceps in less than fully dilated cervix (1) cause injury to cervix, (2) can produce neurogenic shock, and (3) damage paracervical ligaments.
- **Membranes must be ruptured,** because (1) forceps might slip if applied on intact membranes, (2) sometimes rupture of membranes improves uterine contractions leading to normal delivery, and (3) unruptured membranes when pulled might detach the placenta.
- **Bladder should be empty,** because full bladder: (1) inhibits uterine contractions (2) and may get injured during forceps delivery.
- **Head must be engaged,** preferably deeply engaged.
- **Presentation must be favorable,** i.e., vertex, face mentoanterior and aftercoming head of breech.
- **Position** must be precisely known.
- **Anesthesia must be adequate:**
  - *For outlet forceps*: Minimum perineal infiltration.
  - *For low forceps*: Minimum pudendal block.
  - *For mid forceps (or Kielland)*: Spinal, epidural or general anesthesia is required.
- **Episiotomy** at proper time should be given, although in multipara it is not a must.
- **Baby resuscitation facilities** should be available.
- **Operator must be properly trained** in operative vaginal delivery.

Steps of Operation

- Consent is taken after proper counseling.
- The patient is placed in the lithotomy position, and painting and draping are performed. Anesthesia, perineal infiltration or pudendal block, is given.
- The bladder is evacuated using a simple catheter. A pervaginal examination is conducted to confirm all prerequisites. One vein is kept patent (simple drip or if indicated, oxytocin drip is started).
- The blades are articulated in front of the patient to determine the right and left blades. The blade is lubricated before introduction using a dilute antiseptic solution.
- Left blade is to be introduced first because of peculiarity of English lock (slot in left blade faces anteriorly). It is held in left hand vertically, two fingers or whole of right hand is introduced in the vagina and posterior vaginal wall is depressed. Blade is introduced posteriorly in the hollow of the

JAYPEE BROTHERS

sacrum, pushing it by the thumb of right hand keeping flush contact with fetal head, till the blade becomes almost horizontal, then under guidance of internal fingers the blade is rotated to left side of the maternal pelvis **(Fig. 4.2)**.

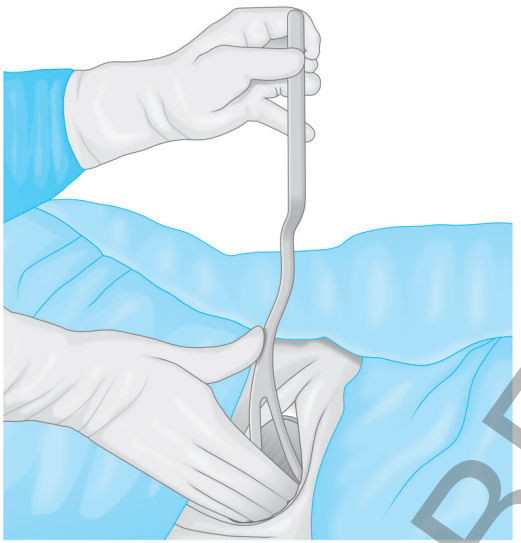

Fig. 4.2: Introduction of left blade.

- Hands are changed and the right blade is introduced by holding it in right hand in the same manner, passing in front of the left blade.
- In the occipito-anterior position after application, the **right blade** remains on **right side of maternal pelvis,** applied on **right parietal bone of fetus** and handle is in **right hand** of the **obstetrician.**
- Blades are slightly depressed if required and then locked, if application is proper there should not be any difficulty in locking.
- Criteria for proper application **(Figs. 4.3 and 4.4)**:
  a. Sagittal suture throughout its length should be perpendicular to the plane of the shanks.
  b. Lowermost part of the head should be within one inch reach from the shank OR the fenestration in advance of the head should not admit more than the tip of one finger.
  c. Posterior fontanelle should not be more than one finger breadth away from the plane of the shank and should be equidistant from the side of the blades.

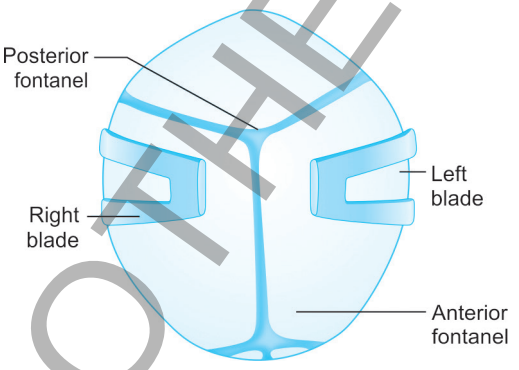

Fig. 4.3: Blades in relation to fetal head.

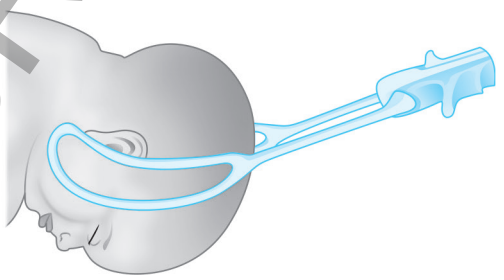

Fig. 4.4: Biparietal, bimalar application.

- **Traction:** It is given applying following principles:
  1. Before starting traction, criteria for proper application should be checked. Easy application and locking usually suggest proper application.
  2. Head is to be extracted slowly, and traction should be applied during and only up to the uterine contraction.
  3. In between the tractions, separate the handles slightly, i.e., relax the blades, without actually unlocking them.
  4. Traction should be applied in the axis of the pelvis. For midforceps and low forceps, traction should first be applied downward and backward, then horizontally downward, followed by

JAYPEE BROTHERS

downward and forward as the occiput fixes under the symphysis pubis, and lastly forward and upward to deliver the head by extension. For the outlet forceps, traction is applied horizontally downward, then downward and forward, and finally forward and upward. In practice, applying traction posterior to handle automatically aligns with the axis of the pelvis. The operator should be in a comfortable position with the forearms fixed slightly below the level of the delivery table. Ideally, only the power of the elbow muscles of one hand should be used. If both hands are used, the flexed elbow should not cross the operator's waistline.

5. Placing of folded towel or finger in between shanks prevents undue compression of fetal head.
   Episiotomy (60° from midline) is given before starting traction or after one or two pulls when perineum gets stretched (In outlet forceps it can be given before introduction of blades).
6. As soon as the head is delivered, blades are removed first right and then left. Upper respiratory passages of the fetus are cleaned out. Suction is not must if liquor is clear.
7. Active management of the third stage of labor is followed.
8. Cervix is explored to check for tears if there is active bleeding.
9. Episiotomy wound is sutured in layers.

Outlet forceps are carried out in labor room, but mid and low forceps deliveries should be done in operation theater.

Complications

Maternal

1. **Injuries:**
   - Birth canal:
     - Extension of episiotomy
     - Vaginal lacerations
     - Perineal tears
     - Paraurethral tears
     - Cervical tears, lacerations, rarely annular detachment
     - Rupture or laceration of lower uterine segment
     - Undue stretching of ligaments leading to prolapse in later life.
   - *Bowel*: Injury to anal sphincter, anal canal or lower rectum, i.e., third- or fourth-degree perineal tear.
   - *Bladder*: **Not common**—they were found with high forceps. But urethral injuries may occur.
   - *Bones*: **Very rare** at present-fracture of coccyx, dislocation of sacrococcygeal joint, injury to symphysis pubis.
2. **Hemorrhage:** External (PPH)— traumatic, atonic or both.
   - *Internal*: Vulva or vaginal hematoma, broad ligament hematoma, intraperitoneal hemorrhage (uncommon).
3. **Infection:** If proper aseptic precautions are not observed, puerperal sepsis including thrombophlebitis of pelvic veins can occur.
4. **Obstetric shock:** Hypovolemic—if there is severe bleeding.
   - Neurogenic—if done on incompletely dilated cervix.

Fetal Complications

- Birth asphyxia—due to compression of brain or intracranial injuries.
- Intracranial hemorrhage—it can be subependymal, subdural or subarachnoid.
- Fetal scalp injuries—lacerations, pressure necrosis.
- Cephalohematoma (blood collection under the periosteum or pericranium).
- Fracture of skull bones (rare—occurs only when excessive force is used).

Trial Forceps

In the case of borderline cephalopelvic disproportion (CPD), forceps are attempted with full preparation in place for LSCS if

JAYPEE BROTHERS

necessary. This is called a "Trial forceps". It is done with normal traction force. If, after three pulls, the head does not descend even slightly, the procedure is abandoned in favor of LSCS. With the "Trial of forceps," many LSCS procedures have been prevented, while traumatic and failed forceps deliveries are also avoided.

Prophylactic Forceps

The concept of prophylactic forceps was introduced by De Lee in 1920. It is always a low forceps delivery, and it is used to shorten the second stage of labor when maternal and fetal complications are anticipated. Common indications are—very painful second stage of labor, heart disease, eclampsia, severe pre-eclampsia, other medical disorders, postcesarean section labor or patient under epidural analgesia.

Failed Forceps

It may be a failure in application or failure in traction. It usually means a vigorous but unsuccessful attempt of delivery by forceps. It is a very traumatic experience for all concerned.

Causes: (1) Undiagnosed occipitoposterior-commonest cause, (2) cervix not fully dilated, (3) constriction ring, (4) Cephalopelvic disproportion, (5) Malpresentation, i.e., brow, and (6) soft tissue obstruction-lower segment fibroid, ovarian tumor.

For failure in application, management consists of removal of the blades and reassessment of the case. Reapplication may be made once if everything is normal, otherwise CS is carried out. For failure in traction, no further attempt should be made and CS is a safer alternative.

Forceps in Abnormal Presentation

Occipito-posterior

Forceps rotation is described later. Here, it means face to pubis forceps delivery. Bladers are applied as routine. Horizontal traction should be applied until the root of the nose is under the symphysis. Then forward pull is given to deliver the vertex and occiput by flexion and finally backward pull will deliver the face by extension. Generous episiotomy is a must.

Face Presentation

Presentation must be mentoanterior with chin completely rotated to the front. Forceps are applied as in vertex anterior position. The handles should be kept somewhat forward so that blades remain in occipito-mental diameter. First downward and backward pull is given; this will extend the face fully till chin comes well below the symphysis pubis. Then handles are lifted upwards and delivery is completed by flexion.

Aftercoming Head of Breech

Long forceps are used. **Piper's forceps** with long shanks having perineal curve ("S" shape) is especially designed for this. Forceps are applied from the ventral aspect of the fetus. At first the child is allowed to hang unsupported so that its head descends until occiput lies up against the back of the symphysis pubis. Assistant should hold the trunk upwards. Forceps are applied as routine—first left blade and then right blade from beneath the trunk. Traction is given first downwards and backwards till the chin appears. Then, it is carried forward and upward to deliver the head by flexion.

Advantages of forceps for aftercoming head of breech: (1) Controlled delivery of head is done, (2) flexion is maintained and (3) traction is directly applied over the fetal head contrary to other manual methods where it is applied via the vertebral column.

It is also the most reliable method, but due to lack of experience and required skill it is not commonly done.

Wrigley's Forceps

It is a simple and delicate instrument invented by Wrigley in 1935. It is a type of short forceps with total length of 27.5 cm. It

JAYPEE BROTHERS

is very light in weight, about one-third the weight of an ordinary long curved forceps. Handles and shank are short. Shank is only 2.5 cm long instead of usual 6.25 cm. Blades have got marked cephalic curve and slight pelvic curve **(Fig. 4.5)**. It is meant to apply on the head low in pelvis. It can be applied under minimum anesthesia with ease. As it is not possible to exert strong traction with it, there are less chances of injury to mother or fetus.



Fig. 4.5: Wrigley's forceps

Kielland Forceps

It is a long rotational forceps with overlapping shanks. It has sliding lock for correction of asynclitism of fetal head. There are **small knobs** (buttons) over the handles. Slight pelvic curve of the blades is on the side of knobs. The blades are 15 cm long, 4 cm broad and slightly thicker than usual forceps with beveled edges **(Fig. 4.6)**. The **blades** are **anterior and posterior** rather than left and right. It is decided by articulating the forceps in front of the patient, keeping knobs on the side of occiput, the blade remaining anterior is anterior blade. The objective of Kielland's forceps was a biparietal application to the fetal head in any position **(Fig. 4.4)**.

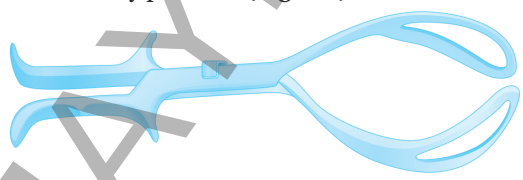

Fig. 4.6: Kielland forceps.

Indications

(1) Deep transverse arrest, (2) Persistent occipito-posterior.

Method

Anterior blade is always introduced first. There are three methods for it.

1. **Wandering method:** Most frequently used. Blade is introduced laterally over the face side or posteriorly in the hollow of sacrum and then wandered over the face side to bring it anteriorly.
2. **Direct method:** Used when head is very low in the pelvis or very small. Blade is introduced directly anteriorly and correctly over the fetal head.
3. **Classical or inversion method:** Obsolete.

In any of the above methods, the posterior blade is applied directly posteriorly.

- Blades are articulated by sliding lock. Asynclitism is corrected.
- Rotation is done in relaxation phase while traction is given during uterine contractions.

Risk

If injudiciously used it can cause injury to cervix, vagina or lower uterine segment.

VACUUM EXTRACTOR (VENTOUSE)

It was introduced by **Malmstrom** in 1954.

Original unit consisted of **suction cups** (made of steel, in 4 sizes 30, 40, 50 and 60 mm diameter with 20 mm depth), **traction chain** (metal chain from the metal plate to traction bar), **traction bar** (handle with lock-pin) connected by rubber tube to **vacuum flask** (glass bottle with a rubber stopper) and vacuum pump **(Fig. 4.7)**.

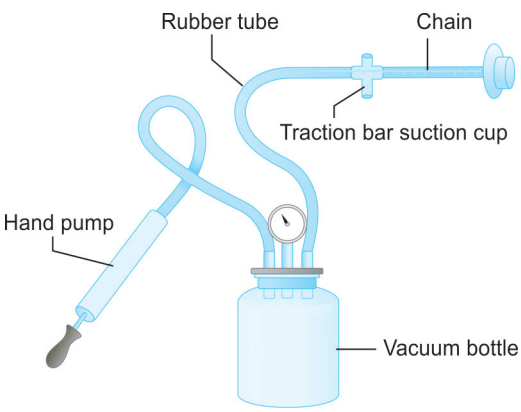

Fig. 4.7: Vacuum extractor.

JAYPEE BROTHERS

Bird's Modifications: Bird modified the original Malmstrom cup by making the traction chain and vacuum tube separate. While traction chain is still kept in the center, vacuum tube is placed eccentrically in Bird's anterior cup (used for occipito-anterior position) **(Fig. 4.8A)**and shifted to the side wall of the cup in Bird's posterior cup (used for occipito-posterior positions) **(Fig. 4.8B)**.

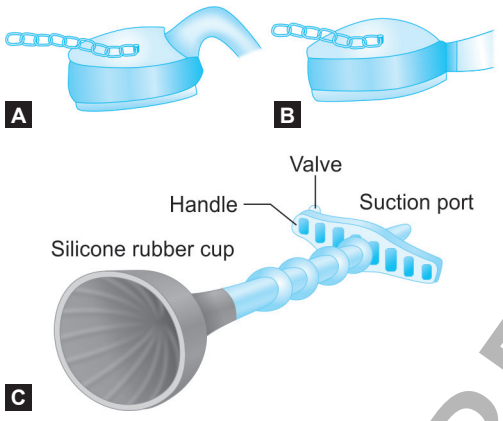

Figs. 4.8A to C: (A) Bird's anterior cup; (B) Bird's posterior cup; (C) Kobayashi silastic cup.

Silastic cup was introduced by Kobayashi in 1973. It is now commonly used instead of metal cups, because flexibility and cone shape further simplifies the use of ventouse. The cup is available in 2 sizes, 60 mm and 65 mm. The cup is attached to about 20 cm long plastic shaft which is perpendicular to the axis of the cup and with the handle at the end **(Fig. 4.8C)**. Silastic cups are reusable after chemical sterilization.

Mityvac vacuum assisted delivery system comprises of hand operated vacuum pump which is a reusable pump and different plastic cups (from 50 to 70 mm diameter), for use in vaginal delivery as well as cesarean section **(Fig. 4.9)**. M style mushroom cup of 50 mm diameter is commonly used. Ideally the cup is disposable.

Kiwi Omni is another complete vacuum delivery system with hand operated pump. There is ease of insertion due to low profile cup, and the flexible stem leads to application over the flexion point of fetal head **(Fig. 4.10)**. Traction force indicator in the system measures the force exerted during traction. Like Mityvac cup it is to be disposed of after single use.

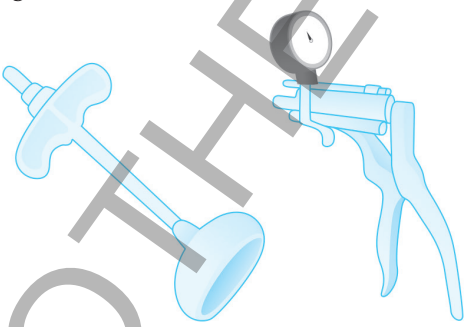

Fig. 4.9: Mityvac vacuum.



Fig. 4.10: Kiwi Omni vacuum delivery system.

Indications

Maternal

- Prolonged second stage of labor due to rigid perineum, frank exhaustion, excessive sedation, epidural analgesia, etc.
- To give less strain to the mother in conditions like PIH, cardiac disease, lung disease, previous LSCS or maternal distress due to any cause.
- To end successful trial of labor.

Fetal

- Prolonged 2nd stage of labor.
- Occipito-posterior position.

JAYPEE BROTHERS

- Fetal distress in 2nd stage of labor (parous patient)
- At cesarean section.

Rarely, it is useful to deliver second baby of twin (high cephalic).

Contraindications

All those described under forceps.

Other contraindications include face presentation, breech presentation (i.e., aftercoming head), prematurity (<34 wks), congenital fetal head anomalies, prior fetal scalp trauma (scalp blood sampling).

Intrauterine death, large caput, general anesthesia and severe fetal distress are the relative contraindications.

Prerequisites

- Same as those for forceps.
- Presence of uterine contractions is helpful but not essential.

Steps of Operation

- Consent is obtained, and the patient is placed in the lithotomy position with aseptic precautions. The bladder is emptied.
- Local anesthesia (L/A), i.e., perineal infiltration or pudendal block, is administered depending on the station of the fetal head.
- Per-vaginal examination is performed.
- 6 to 6.5 cm silastic cups are used.
- Vacuum equipment is prechecked for leaks.
- Cup is introduced inside the vagina after depressing the perineum. Cup should be applied as near the occiput as possible, to maintain flexion.
- Before creating the vacuum, ensure that the cervical lip or vaginal wall is not included in the cup. A vacuum of 0.2 kg/cm is created slowly over 2 minutes initially. After confirming correct application, the vacuum is rapidly increased to the required level of 0.8 kg/cm.

- **Application distance**: As defined by Bird, the distance between the leading edge of the cup and the anterior fontanelle is called the application distance. For **flexing** application, it should be >3 cm.
- Also, the center of the cup should overlie the flexion point. **Flexion point** (or **pivotal point**) lies 6 cm from anterior fontanelle on sagittal suture **(Fig. 4.12)**.
- Both the above points imply the same thing.

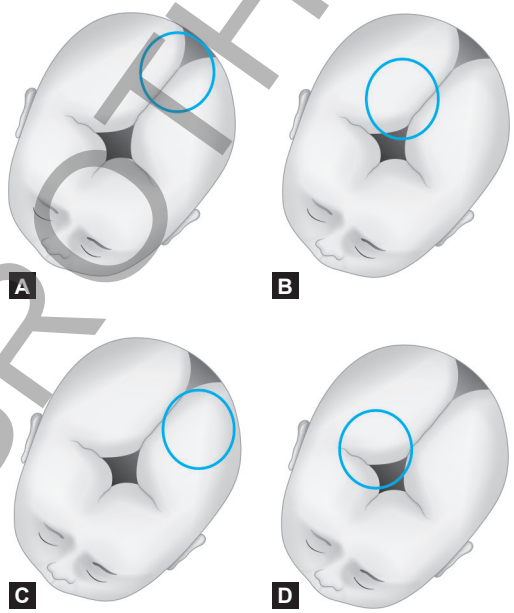

Figs. 4.11A to D: (A) Flexing median; (B) Deflexing median; (C) Flexing peramedian; (D) Deflexing paramedian.

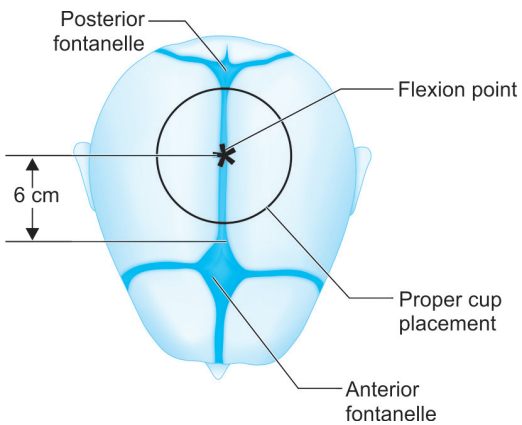

Fig. 4.12: Flexion point.

JAYPEE BROTHERS

Principles of Traction

- Before starting, ensure sufficient pressure is created. Check again that maternal soft tissues are not included in the cup.
- Traction is given during uterine contractions only. There is no difference in outcome whether traction is maintained between contractions or not.
- Traction should be applied perpendicular to the cup and also in the pelvic axis to get maximum advantage. It is difficult to practice both simultaneously, so a 10° off-center traction may be given. More than 10° direction will lead to leakage of vacuum and slipping of cup.
- With the left forefinger and thumb, the cup (upper part) is pressed backward over the fetal head during traction.
- Episiotomy is given when the head is bulging the perineum.
- Safety rules as suggested by Bird should be observed:
  - Head should be delivered in not more than three pulls. With first pull, head and not just the scalp must begin to move. By second pull the head must be on the pelvic floor. The head must be completely or almost completely delivered by the third pull.
  - The cup should not be applied more than twice in one patient.
  - Application delivery interval should not exceed 20 minutes (except in dead fetus).

Complications

If correctly performed, they are minimal.

Maternal

They are comparable to spontaneous vaginal delivery. Injury to cervix, vagina or perineum may happen, if incorrectly used.

Fetal

- Laceration, abrasion or necrosis of scalp
- Cephalohematoma
- Intracranial hemorrhage
- Subaponeurotic hemorrhage (subgaleal hematoma)
- Hyperbilirubinemia
- Alopecia
- Retinal or subconjunctival hemorrhage
- Depressed fractures of skull.

Advantages of Vacuum Extractor Over Forceps

- Easy to use
- Much less increase in intracranial pressure during traction
- Does not interfere with internal rotation of head (autorotation)
- No trauma to maternal soft tissues if correctly applied
- Minimum anesthesia is required
- Safety factor, because at some pressure (20 kg) vacuum will break and cup will pop off.
- Ability to rotate fetal head without the instrument impinging upon the maternal soft tissues.

As per recent Cochrane database of systematic review (2021) which included 31 studies involving 5754 women, forceps may be more likely to achieve vaginal birth and have lower rates of fetal trauma, but at a greater risk of perineal trauma and higher pain relief requirements compared with vacuum cups. Rigid vacuum cups may be more likely to achieve a vaginal birth than soft cups but with more fetal trauma.

Failure

Failure rate varies from 4 to 27% in different studies reported.

Causes of Failure

- **Faults in the instrument:** Leak in the instrument, vacuum pump not working properly, loose traction chain.
- **Faults in the technique:** Wrong size of the cup, deflexing and paramedian application, wrong direction of pull, pulling too hard or too less, vacuum pressure too low, cervix or vaginal walls trapped in the cup. If the center of the cup is situated more than

JAYPEE BROTHERS

1 cm to either side of the sagittal suture, the application is described as paramedian. **Deflexing** and **paramedian** application leads to failure **(Figs. 4.11A to D)**.

- **Adverse obstetric factors:** Disproportion, severely deflexed head, presentation, very large caput.
- If advancement is not evident after two pulls stop the procedure and re-evaluate the case.
- If cervix or vagina is included, hissing leak will be heard when traction is applied.
- Artificial caput produced by vacuum is called **Chignon**.
- Sequential delivery (first apply vacuum and then forceps) is not advocated due to bad results.

Odon Device

It is a new device which was developed by Jorge Odon from Argentina for instrumental vaginal delivery. It is permitted for clinical trial by WHO. It is a low-cost device and claimed to be safer and easier to apply than forceps or vacuum. It consists of a plastic sleeve that is inflated around the baby's head and used to gently pull it out **(Fig. 4.13)**. Initial clinical pilot study showed it feasible for clinical use. No adverse maternal or fetal outcomes were observed at 6 weeks follow-up. Randomized control trials for its safety and efficacy are required before its clinical use.

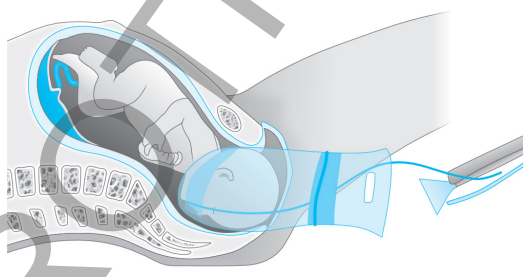

Fig. 4.13: Odon device.

VIVA-VOCE QUESTIONS

1. What are the main differences between **outlet forceps**, **low forceps**, and **midforceps**, and how do these differences affect their clinical indications?
2. How do **forceps** and **vacuum extractor** compare in terms of complications for both the mother and fetus, and why is the vacuum extractor considered less traumatic for the maternal soft tissues?
3. Discuss the role of **rotational forceps**, such as **Kielland's forceps**, in managing cases of **persistent occipito-posterior position** and the potential risks associated with their use.
4. What are the prerequisites for using **forceps** during delivery, and why is it essential that the **cervix** be fully dilated before their application?
5. Explain the steps involved in **vacuum extraction** and the importance of ensuring correct **cup application distance**?
6. What are the **contraindications** for using a **vacuum extractor** during delivery, and how do these contraindications affect decision-making in high-risk obstetric cases?
7. How does **episiotomy** relate to the use of **forceps** during delivery, and when is it typically performed in the process?
8. What are the **maternal complications** that may arise from the use of **forceps**, and how can these complications be minimized during the procedure?
9. Discuss the concept of **prophylactic forceps** and provide examples of maternal and fetal conditions where this approach is considered beneficial.
10. What is the purpose of the **Odon device**, and how does it compare to traditional methods like **forceps** and **vacuum extraction** in terms of safety and ease of application?

JAYPEE BROTHERS

for detailed information on obstetrics and gynecology books, visit our website www.ejaypee.com, for detailed information on obstetrics and gynecology books, visit our w

Companion for Obstetrics & Gynecology Practical Examination

The book covers the ObGyn subject in a comprehensive yet concise manner. The book is a ready reckoner for both undergraduate and postgraduate students. It has been used by students for the last 40 years. It has proved an excellent companion for students facing practical viva tables. All the topics are described point by point in a simplified manner, avoiding unnecessary elaboration. The book is an excellent exam booster for the students.

Haresh U Doshi is an eminent teacher for more than 35 years. He passed his MD (Gynecology) and PhD from BJ Medical College, Ahmedabad, Gujarat, India. Currently, he is Professor and Head of the Department of ObGyn at Gujarat Cancer Society Medical College, Ahmedabad. Over the years, he has been involved in many undergraduate and postgraduate teaching courses across the country. He was Chairperson of Practical Obstetric Committee of FOGSI from 2004 to 2008, President of Ahmedabad ObGyn Society 2003, President of State Organization of ObGyn 2004, Vice President of FOGSI 2019, and ICOG Governing Council Member 2021–2025.

He is a teacher of teachers and doctor of doctors. He has authored 3 books, 5 booklets, and 25 book chapters and published 35 scientific papers in national and international journals.

This book is the essence of his vast experience, wisdom, and strong academics.

JAYPEE BROTHERS

Buy from ejaypee

JAYPEE BROTHERS

Shelving Recommendation
OBSTETRICS & GYNECOLOGY

ISBN 978-81-6770-819-9

9 788167 708199