website www.ejaypee.com, for detailed information on dental books, visit our website www.ejaypee.com, for detailed information on dental books, visit our website www.ejaypee.com

3rd Edition

TEXTBOOK OF ORAL EMBRYOLOGY & HISTOLOGY



Dr. Wise
Innovative & Genius
AI Chatbot
access code inside

B Sivapathasundharam

Forewords
Dinesh K Daftary
Kannan Ranganathan

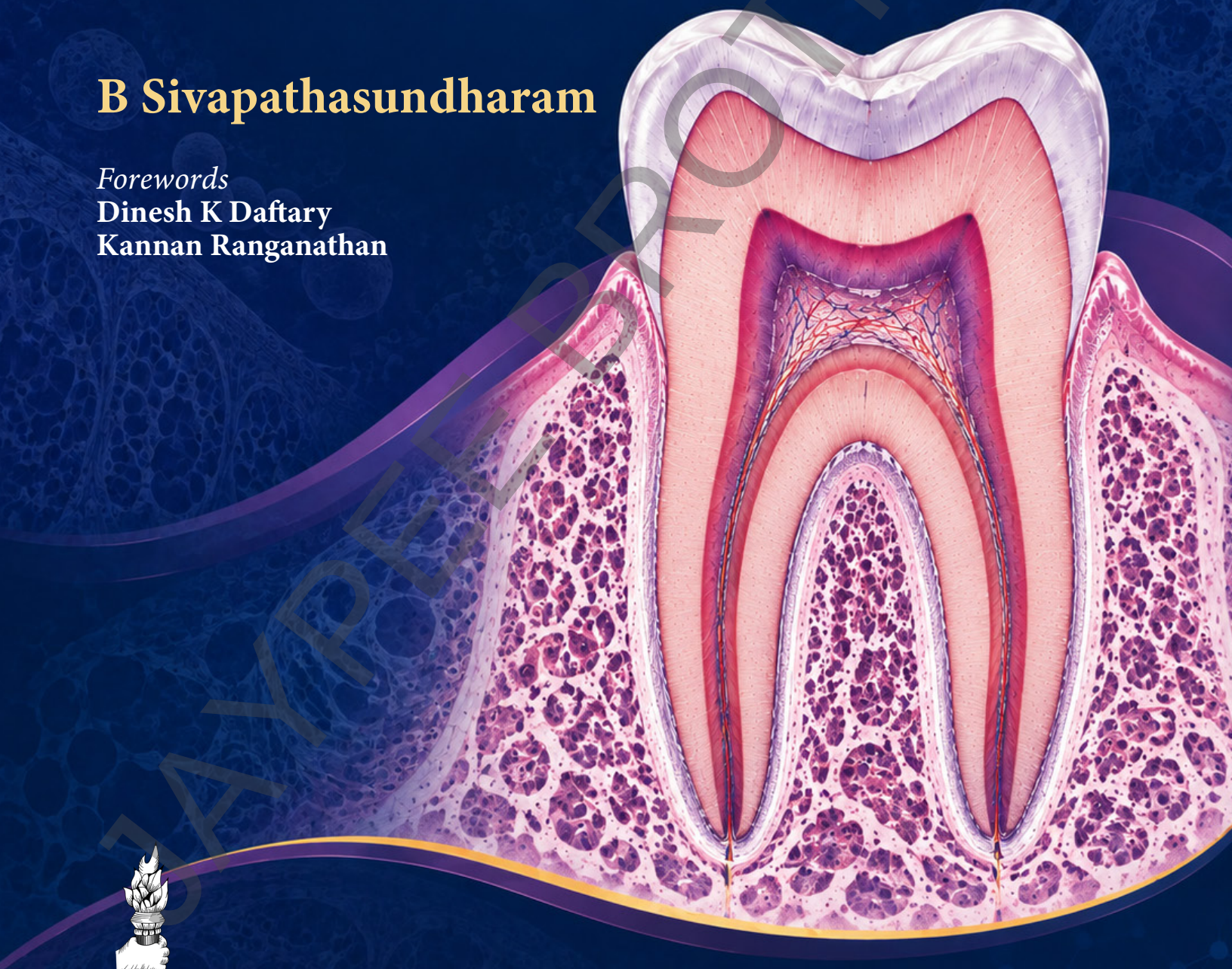

JAYPEE BROTHERS

JAYPEE

Contents

SECTION 1: Introduction and Oral Embryology

1. **Overview of Oral Tissues** 3
   B Sivapathasundharam
   - Overview of Oral Tissues *4*
   - Hard Tissues of the Oral Cavity *5*
   - Soft Tissues of the Oral Cavity *6*
   - Maxillary Sinus *7*
   - Temporomandibular Joint *7*
   - Eruption and Shedding *8*
   - Methods of Studying Oral Tissues at Microscopic Level *8*
   - Molecular Biology in Oral Tissue Development *9*
   - Advances in Early Embryo Imaging *9*
   - Cell Signaling *9*
2. **General Embryology** 13
   B Sivapathasundharam
   - Fertilization *13*
   - Cleavage *14*
   - Formation of Bilaminar Germ Disk *14*
   - Prochordal Plate and Trilaminar Germ Disk Formation *16*
   - Formation of Neural Crest Cells *17*
   - Folding of the Embryo *18*
   - Development of Branchial Arches *19*
   - Fate of Pharyngeal Clefts *19*
3. **Development of Face, Palate and Tongue** 23
   B Sivapathasundharam, Manoj Prabhakar
   - Development of Face *23*
   - Development of Pharyngeal Arches *24*
   - Development of Palate *26*
   - Development of Tongue *28*
   - Clinical Considerations *29*
4. **Development of Tooth** 34
   B Sivapathasundharam, Logeswari Jayamani
   - Dental Lamina *35*
   - Vestibular Lamina *36*
   - Tooth Development *37*
   - Apposition and Hard Tissue Formation *46*
   - Root Formation *46*
   - Clinical Considerations *47*

SECTION 2: Histology of Dental Structures

5. **Enamel** 57
   Mandana Darafsh Donoghue, B Sivapathasundharam, RJ Vijayashree
   - Physical Properties *58*
   - Chemical Composition *58*
   - Structure of Enamel *59*
   - Hypomineralized Structures of Enamel *64*
   - Surface Structures of Enamel *66*
   - Amelogenesis *67*
   - Age Changes *74*
   - Clinical Considerations *75*
   - Forensic Significance of Dental Enamel *77*
6. **Dentin** 82
   B Sivapathasundharam
   - Physical Properties *82*
   - Chemical Composition *84*
   - Histology of Dentin *84*
   - Structural Patterns of Dentin *88*
   - Dentin Sensitivity *94*
   - Dentinogenesis *94*
   - Clinical Considerations *97*
7. **Pulp** 102
   B Sivapathasundharam
   - Structure of Pulp *104*
   - Cells of the Pulp *107*
   - Intercellular Substance *109*
   - Functions of Pulp *111*
   - Development of Pulp *112*
   - Age Changes *113*
   - Clinical Considerations *114*
8. **Cementum** 119
   Punnya V Angadi, B Sivapathasundharam
   - Physical Properties *120*
   - Chemical Composition *121*
   - Cells of Cementum *122*
   - Fibers of Cementum *124*
   - Structure and Classification of Cementum *124*
   - Cementogenesis *126*
   - Cementoid *130*

JAYPEE BROTHERS

- ❖ Incremental Lines of Cementum *130*
- ❖ Hyaline Layer of Hopewell–Smith *131*
- ❖ Cementodentinal Junction *131*
- ❖ Cementoenamel Junction *131*
- ❖ Functions of Cementum *133*
- ❖ Age Changes *133*
- ❖ Clinical Considerations *133*

9. Periodontal Ligament 139
Anil Sukumaran, B Sivapathasundharam, Paavai Ilango
- ❖ Development of Periodontium *140*
- ❖ Structure of Periodontium *142*
- ❖ Periodontal Fibers *146*
- ❖ Interstitial Tissue *150*
- ❖ Ground Substance *151*
- ❖ Functions of the Periodontal Ligament *152*
- ❖ Age Changes *153*
- ❖ Clinical Considerations *153*

10. Alveolar Bone 159
B Sivapathasundharam
- ❖ Physical Properties *160*
- ❖ Chemical Composition *160*
- ❖ Classification of Bones *160*
- ❖ Formation of Bone *165*
- ❖ Cells of the Bone *169*
- ❖ Bone Remodeling *174*
- ❖ Alveolar Bone *175*
- ❖ Development of Maxilla and Mandible *176*
- ❖ Development of Alveolar Process *179*
- ❖ Structure of Alveolar Bone *180*
- ❖ Remodeling of Alveolar Bone *182*
- ❖ Age Changes *182*
- ❖ Clinical Considerations *182*

SECTION 3: Tooth Eruption and Shedding

11. Tooth Eruption 191
B Sivapathasundharam, Logeswari Jayamani
- ❖ Eruption *193*
- ❖ Pattern of Tooth Movement *194*
- ❖ Histology of Tooth Movement *196*
- ❖ Theories of Tooth Eruption *198*
- ❖ Clinical Considerations *200*

12. Shedding 204
B Sivapathasundharam
- ❖ Order of Shedding *205*
- ❖ Mechanism of Shedding *207*
- ❖ Histology of Shedding *207*
- ❖ Clinical Considerations *210*

SECTION 4: Histology of Orofacial Structures

13. Oral Mucous Membrane 215
B Sivapathasundharam, Gnanambigai K
- ❖ Functions of Oral Mucous Membrane *216*
- ❖ Boundaries of the Oral Cavity *216*
- ❖ Clinical Appearance and Regional Variations *217*
- ❖ Classification of Oral Mucosa *218*
- ❖ Components of the Oral Mucosa *219*
- ❖ Oral Immune System *235*
- ❖ Masticatory Mucosa *235*
- ❖ Lining Mucosa *244*
- ❖ Specialized Mucosa *247*
- ❖ Development of the Oral Mucosa *251*
- ❖ Age Changes *252*
- ❖ Clinical Considerations *252*

14. Salivary Glands 261
Pratibha Ramani, Einstein A, B Sivapathasundharam
- ❖ Glands *261*
- ❖ Classification of Glands *261*
- ❖ Salivary Glands *265*
- ❖ Classification of Salivary Glands *265*
- ❖ Development of Salivary Gland *266*
- ❖ Histology of Salivary Glands *269*
- ❖ Myoepithelial Cells (Basket Cells) *271*
- ❖ Other Cells *274*
- ❖ Ductal System *274*
- ❖ Connective Tissue Component of the Gland *276*
- ❖ Formation and Secretion of Saliva *276*
- ❖ Ductal Modification of Saliva *276*
- ❖ Composition of Saliva *277*
- ❖ Properties of Saliva *277*
- ❖ Functions of Saliva *278*
- ❖ Major Salivary Glands *278*
- ❖ Minor Salivary Glands *280*
- ❖ Tubarial Glands—The New Salivary Gland Organs *280*
- ❖ Clinical Considerations *280*
- ❖ Acknowledgments *281*

15. Temporomandibular Joint 285
B Sivapathasundharam, Gururaj N
- ❖ Development of Temporomandibular Joint *287*
- ❖ Gross Anatomy and Microscopic Structure *288*
- ❖ Blood Supply *293*
- ❖ Nerve Supply *293*
- ❖ Functions of Temporomandibular Joint *294*
- ❖ Clinical Considerations *294*

16. Maxillary Sinus 299
B Sivapathasundharam, Logeswari Jayamani, Govind Rajkumar
- ❖ Anatomy of Maxillary Sinus *299*
- ❖ Development of Maxillary Sinus *301*
- ❖ Blood Supply and Nerve Supply *303*
- ❖ Microscopic Features *304*
- ❖ Functions *305*
- ❖ Clinical Considerations *305*

17. Lymphatics of Orofacial Region 310
B Sivapathasundharam, Doddabasavaiah Basavapur Nandini
- ❖ Lymphatic Organs *310*

JAYPEE BROTHERS

- Development of Lymphatic System *312*
- Lymph *312*
- Structure of Lymphatic System *312*
- Lymph Circulation *316*
- Lymphatics of the Head and Neck *316*
- Clinical Considerations *317*

SECTION 5: Miscellaneous

18. Age Changes in Oral Tissues 325
Einstein T Bertin A, B Sivapathasundharam
- Theories of Aging *325*
- The Cell Biology of Aging *326*
- Effects of Aging on the Human Body *328*
- Effects of Aging on the Oral and Perioral Structures *328*
- Effect of Aging on the Dental Tissues *330*
- Forensic Implications of Age-related Changes of the Dental Tissues *333*

19. Stem Cells 337
Shankaranarayanan S, B Sivapathasundharam, Protyusha Guha Biswas, Manimaran K
- Stem Cell Niche *338*
- History of Stem Cells *338*
- Classification of Stem Cells *338*
- Mechanism of Action of Stem Cells *340*
- Application of Stem Cells in Regenerative Medicine *340*
- Dental Stem Cells *341*
- Isolation of Dental Pulp Stem Cells *343*
- Applications of Dpscs in Regenerative Dentistry *344*

20 Evolution of Jaws and Teeth 350
Mahesh Verma, Priya Kumar, B Sivapathasundharam
- Agnathan to Gnathostome Transition *350*
- Hominid Jaw Evolution *352*
- Jaw Suspension *355*
- Theories of Evolution of Human Dentition *355*
- Theories of Cuspal Origin *357*
- Evolution of Periodontium *358*
- Trends in Evolution *358*

21. Fundamentals of Histopathological Techniques 362
B Sivapathasundharam, Kavitha B, RJ Vijayashree
- Types of Preparation *363*
- Soft Tissue Processing *363*
- Tissue Sectioning *367*
- Electron Microscopy *371*
- Advanced Optical Imaging Techniques *371*
- Frozen Sections *373*
- Hard Tissue Processing *373*
- Exfoliative Cytology *376*
- Digital Pathology *376*

22. Histochemistry of Oral Tissues 380
Preethi Murali, B Sivapathasundharam
- Oral Tissues and Their Chemical Composition *381*
- Epithelial Tissue and Derivatives *381*
- Connective Tissue *381*
- Cells and Fibers *382*
- Specific Histochemical Methods *383*
- Immunohistochemistry *384*
- Histochemistry of Oral Hard Tissues *385*
- Histochemistry of Oral Soft Tissues *385*
- Advanced Techniques *387*
- Clinical Considerations *389*

Appendices

1. Oral Tissues: A Brief Description 395
RJ Vijayashree, Manoj Prabhakar, Sabarinath B, B Sivapathasundharam
- Comparison of Hard Tissues *395*
- Comparison of Hard Tissue-forming Cells *396*
- Classification of Cementum *396*
- Comparison of Oral Mucosa *397*
- Comparison of Papillae of the Tongue *397*
- Comparison of Major Salivary Glands *398*
- Comparison of Serous and Mucous Acini *398*
- Summary of Molecular Interplay in Tooth Development *398*
- Timeline of Tooth Eruption *399*
- Differences Between Deciduous and Permanent Dentition *399*
- Effects of Aging on Oral and Circumoral Tissues *399*
- Abbreviations and Expansions *400*
- Glossary *401*

2. Histologic Diagrams 416
B Sivapathasundharam, RJ Vijayashree
- Bud Stage of Tooth Development *416*
- Cap Stage of Tooth Development *416*
- Early Bell Stage of Tooth Development *417*
- Advance Bell Stage of Tooth Development *417*
- Hertwig's Epithelial Root Sheath *418*
- Cross Section of Enamel Rods *418*
- Cross Section of Enamel Rods-fish Scale Pattern *418*
- Enamel Rods Exhibiting Tortuous Pattern *419*
- Incremental Lines of Retzius *419*
- Enamel Lamellae *420*
- Enamel Spindles *420*
- Enamel Tufts *420*
- Hunter-Schreger Bands *421*
- Cross Section of Dentinal Tubules *421*
- Interglobular Dentin *422*
- Terminal Branching of Odontoblastic Processes *422*

JAYPEE BROTHERS

- Dead Tracts *422*
- Tomes' Granular Layer *423*
- Cellular Cementum *424*
- Acellular Cementum *424*
- Cellular Cementum in Decalcified and H&E Stained Section *424*
- Cementoenamel Junction-butt Type *425*
- Cementoenamel Junction-gap Type *425*
- Cementoenamel Junction-overlapping Type *425*
- Dental Pulp *426*
- Free False Pulp Stones *426*
- Lamellar Bone *426*
- Woven Bone *427*
- Pseudostratified Ciliated Columnar Epithelial Lining of the Maxillary Sinus *427*
- Keratinized Mucosa *427*
- Nonkeratinized Mucosa *428*
- Filiform Papillae of the Tongue *428*
- Fungiform Papillae of the Tongue *428*
- Circumvallate Papillae of the Tongue *429*
- Dentogingival Junction *429*
- Periodontal Fiber Groups *430*
- Serous Salivary Gland *430*
- Mucous Salivary Gland *430*
- Mixed Salivary Gland *431*
- Salivary Gland Duct *431*

Index *433*

JAYPEE BROTHERS

CHAPTER 3

Development of Face, Palate and Tongue

B Sivapathasundharam, Manoj Prabhakar

CHAPTER OUTLINE

- Development of Face
- Development of Pharyngeal Arches
- Development of Palate
- Development of Tongue
- Clinical Considerations

Learning Objectives

After completing this chapter, the learner will be able to:

- ❒ Describe the chronological events involved in the embryological development of the face, palate and oral cavity.
- ❒ Explain the facial prominences and pharyngeal arches contributing to facial formation.
- ❒ Explain the role of neural crest cells, growth factors, and molecular signaling pathways in facial development.
- ❒ Outline the stages in the development of the primary and secondary palate.
- ❒ Describe the mechanisms involved in elevation, fusion, and ossification of the palatal shelves.
- ❒ Explain the embryological development of the tongue.
- ❒ Recognize common anomalies of the face, palate, and tongue and explain their embryological basis.
- ❒ Appreciate the clinical relevance of disturbances in normal facial, palatal, and tongue development.

INTRODUCTION

The face, palate, and tongue are vital craniofacial structures that develop through a highly coordinated sequence of embryological events involving cellular proliferation, migration, and differentiation. Their development begins early in intrauterine life and is primarily governed by the growth and fusion of facial prominences and pharyngeal arches. Any disturbance in these events may lead to a wide spectrum of congenital anomalies with functional, aesthetic, and clinical implications.

DEVELOPMENT OF FACE

- ❖ Development of face begins soon after the folding of the embryo during the *4th week of intrauterine life* with the development of forebrain and prochordal plate mesoderm.
- ❖ The prochordal plate acts as an organizer for the development of face.
- ❖ The neural crest cell migration and its inductive influence in the mesenchyme also play a major role.
- ❖ After the formation of the head fold, the primitive oral cavity, which is also called *stomodeum* or *stomatodeum*, is bound by the head bulge above and cardiac bulge below. These two bulgings represent the developing brain cranially and pericardium caudally.
- ❖ The primitive oral cavity is separated from the foregut by buccopharyngeal membrane posteriorly **(Figure 3.1)**.
- ❖ The cranial mesoderm proliferates in the midline to form a downward projection, superior to the stomodeum known as *frontonasal process*, which gives rise to forehead and later contributes to the formation of bridge of nose and part of palate known as premaxilla.
- ❖ Pharyngeal arches that are formed on the lateral and ventral surfaces of foregut, also lie in close vicinity to the stomodeum, with the first arch lying on either side.

Cranial neural crest cells continue to be recognized as key contributors to the development of the face and oral cavity. Advances in multi-omics and single-cell technologies have highlighted how their gene expression patterns and epigenetic regulation control cell fate, migration, proliferation, and differentiation processes that are essential for normal morphogenesis and the diversity of facial forms.

JAYPEE BROTHERS

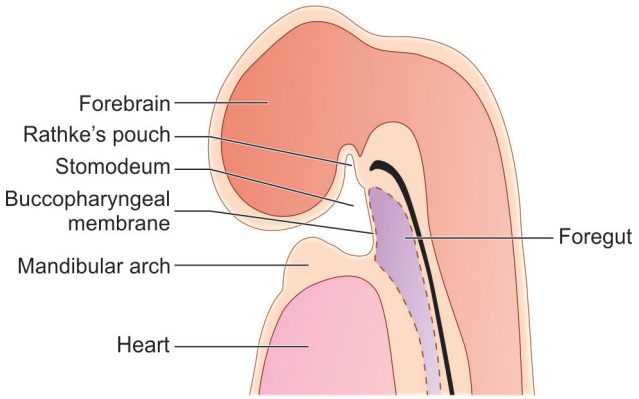

Figure 3.1: Folded embryo with primitive oral cavity bounded above by the head bulge and below by the cardiac bulge.

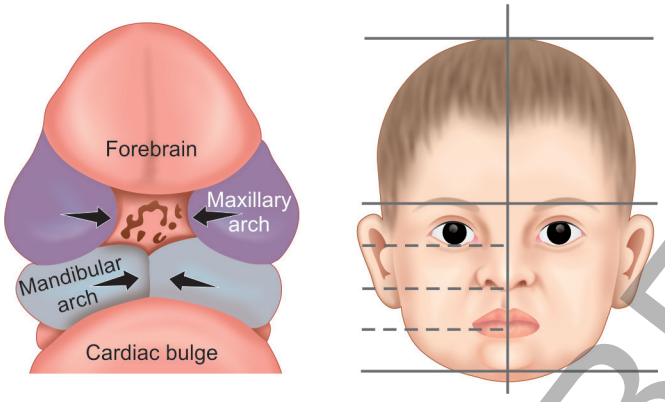

Figure 3.2: Development of face from facial prominences.

Flowchart 3.1: Development of face.

4th week of intrauterine life
↓
Prochordal plate—main organizer
↓
Formation of head fold—two bulgings represent developing brain
↓
Separation of primitive oral cavity
↓
Formation of frontonasal process by proliferation of cranial mesoderm
↓
Frontonasal process gives rise to forehead, contributes to the formation of bridge of nose and premaxilla
↓
Between 4th and 10th week of intrauterine life—five facial prominences: One frontonasal, two maxillary, two mandibular prominences
↓
Elimination of furrow
↓
Actual fusion occurs in the development of palate
↓
Stomatodeum: Unpaired frontonasal process from above
Paired first pharyngeal arch
↓
Formation of two maxillary and mandibular processes
↓
Contributes majorly to the development of face

Between *4th and 10th week of intrauterine life*, five facial prominences namely one frontonasal, two maxillary, and two mandibular prominences appear to form the face **(Figure 3.2)**. These prominences or processes grow further and fuse to form facial structures. These facial processes are swellings of mesenchyme with furrows in between; hence, the union involves elimination of furrow rather than fusion. Actual fusion occurs in certain instances, as in development of palate. These structures surrounding the stomodeum namely, the unpaired frontonasal process from above, which later gives rise to medial nasal and lateral nasal processes, and paired first pharyngeal arch giving rise to two maxillary and mandibular processes on each side, contributes majorly to the development of face **(Flowchart 3.1)**.

Growth factors including Shh (Sonic hedgehog) secreted by the prochordal plate, induce the development of forebrain, which in turn signals the cranial mesoderm to induce the growth of the frontonasal prominence. Other growth factors like fibroblast growth factors *(FGFs)*, bone morphogenetic proteins *(BMPs)*, and Wnt signaling molecules regulate epithelial–mesenchymal interactions essential for the development of face. The homeobox containing transcription factor Msx-1 also play a crucial role in facial development.

Bilateral localized horseshoe-shaped ectodermal thickenings of the frontonasal process induced by the forebrain appear just above the stomodeum on either side of the midline. These thickenings are called as nasal placodes. They sink at the center to form nasal pits, which are continuous with the stomodeum. The edges of the pits are raised, with the medial side called as medial nasal process and the lateral side as lateral nasal process. Similar thickening of the ectoderm appears lateral and cranial to nasal placodes. These are called as lens placodes, which lead to the formation of eye **(Figure 3.3)**.

DEVELOPMENT OF PHARYNGEAL ARCHES (FIGURES 3.4A TO C)

- Pharyngeal arches are the mesodermal thickenings present at the cranial most part of the foregut.
- The first pharyngeal arch, the mandibular arch, gives rise to two processes namely *maxillary process* and *mandibular process*.
- The maxillary process grows medially and fuses with lateral nasal process first and medial nasal process next, to form the upper lip. This fusion is not restricted to the lip alone and includes the fusion of medial angle of the developing eye. This is initially marked by a linear depression called nasolacrimal furrow, which later, buried deeper to form the nasolacrimal duct.

JAYPEE BROTHERS

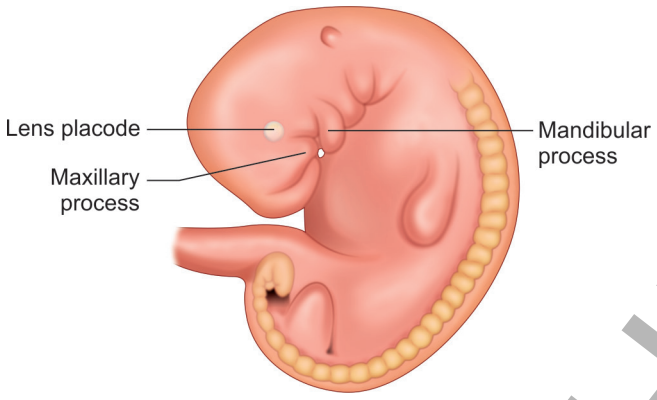

Figure 3.3: The lens placode in the lateral aspect of the developing head.

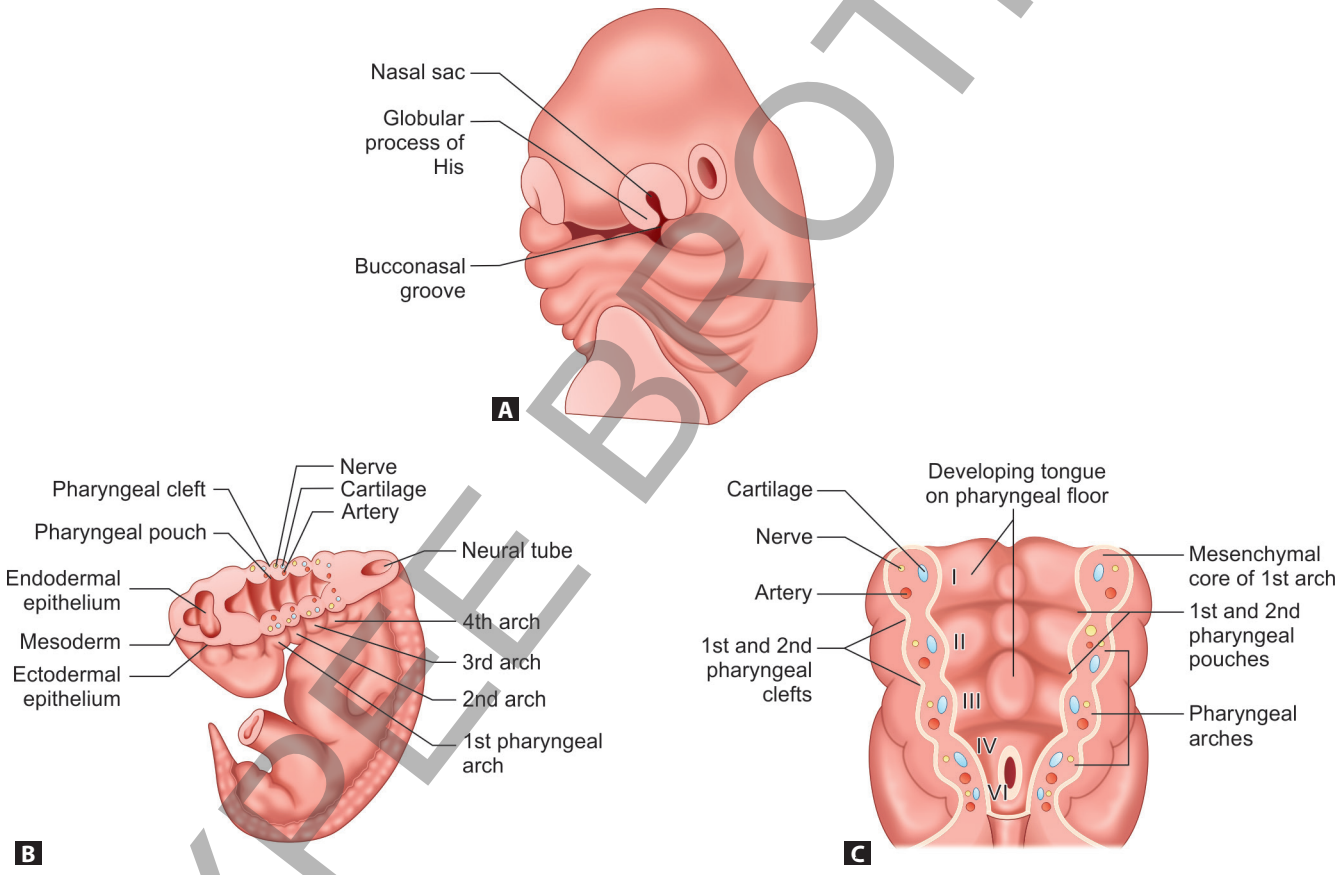

Figures 3.4A to C: Pharyngeal arches.

- The medial and lateral nasal processes fuse together to separate the nasal pit from the stomodeum. The nasal pits at this stage are called external nares.
- The mesoderm and ectoderm of the lateral part of upper lip is derived from maxillary process; whereas the mesoderm of the median portion of the upper lip, called *philtrum*, is derived from lower most portion of the enlarged medial nasal process, which is otherwise called as *globular process of His*.
- The ectoderm of the maxillary process grows over the mesoderm and meets the ectoderm of the contralateral maxillary process in the midline, the reason for which the entire upper lip to get innervated by the maxillary nerves.
- The mandibular process on either side grows toward each other and fuses at the center to form the lower jaw and lower lip. The maxillary and mandibular processes later fuse with each other to form the cheek, making the mouth opening smaller **(Figure 3.5)**.

JAYPEE BROTHERS

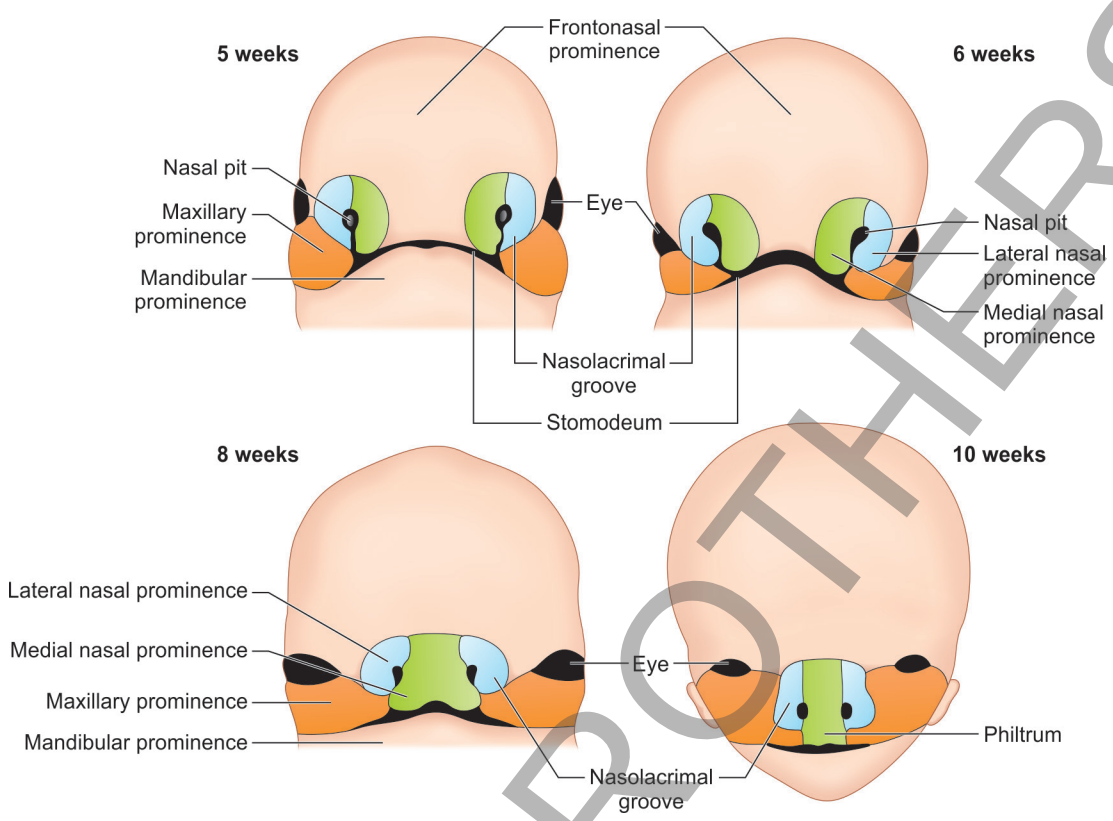

Figure 3.5: Development of face.

DEVELOPMENT OF PALATE

- Development of palate starts at about *5th week of gestation*.
- Initially there is a common oronasal cavity, which is occupied entirely by the developing tongue.
- The nasal cavity is separated from the oral cavity, after the formation of palate.
- Palate develops from two components, namely primary palate (also known as *primitive palate*) and *secondary palate* **(Figures 3.6A and B)**.
- The primitive palate is formed from the frontonasal process and secondary palate from the palatine shelves of the maxillary process on either side.
- The maxillary process of the mandibular arch, apart from forming the upper lip, extends posteriorly and medially on either side of the stomodeum to form the palatal process or the palatine shelves.
- These palatine shelves of the maxillary process are positioned vertically on either side of the developing tongue **(Figures 3.7A to D)**.
- As the mandible grows, the developing tongue is moved forward and downward, which allows the palatine shelves to snap up horizontally (elevate) to form the secondary palate. The fusion occurs at the midline by merging of the ectomesenchyme. This actual fusion includes series of molecular, mechanical, and morphological events.

Formation of permanent palate therefore occurs by the fusion of palatal components. The palatal processes on either side will fuse with the primitive palate in a Y-shaped manner, at its posterior end. The medial portion of two palatal processes in turn fuses with each other horizontally to form the secondary palate. Further, it also fuses with the free lower border of the nasal septum, separating the two nasal cavities in the midline and from the oral cavity inferiorly. The anterior and mid part of the palate undergoes intramembranous ossification and forms the hard palate, while the posterior part does not ossify and is made up of muscles which forms the soft palate **(Flowchart 3.2)**.

The epithelium overlying the palatine process, initially thins down due to cessation of cell division and apoptosis (programmed cell death). Thinned epithelium later breaks into islands. Soon these epithelial islands interact with ectomesenchyme and transform into cells resembling fibroblasts.

This interaction and transition of the epithelial cells into mesenchymal cells is known as *epithelial–mesenchymal transition*. This is mediated by the production of extracellular surface substances like transforming growth factor-beta 3 (TGF-β3), fibroblast growth factor (FGF) signaling, and increase in cyclic adenosine monophosphate (cAMP) for the cessation of cell division.

JAYPEE BROTHERS

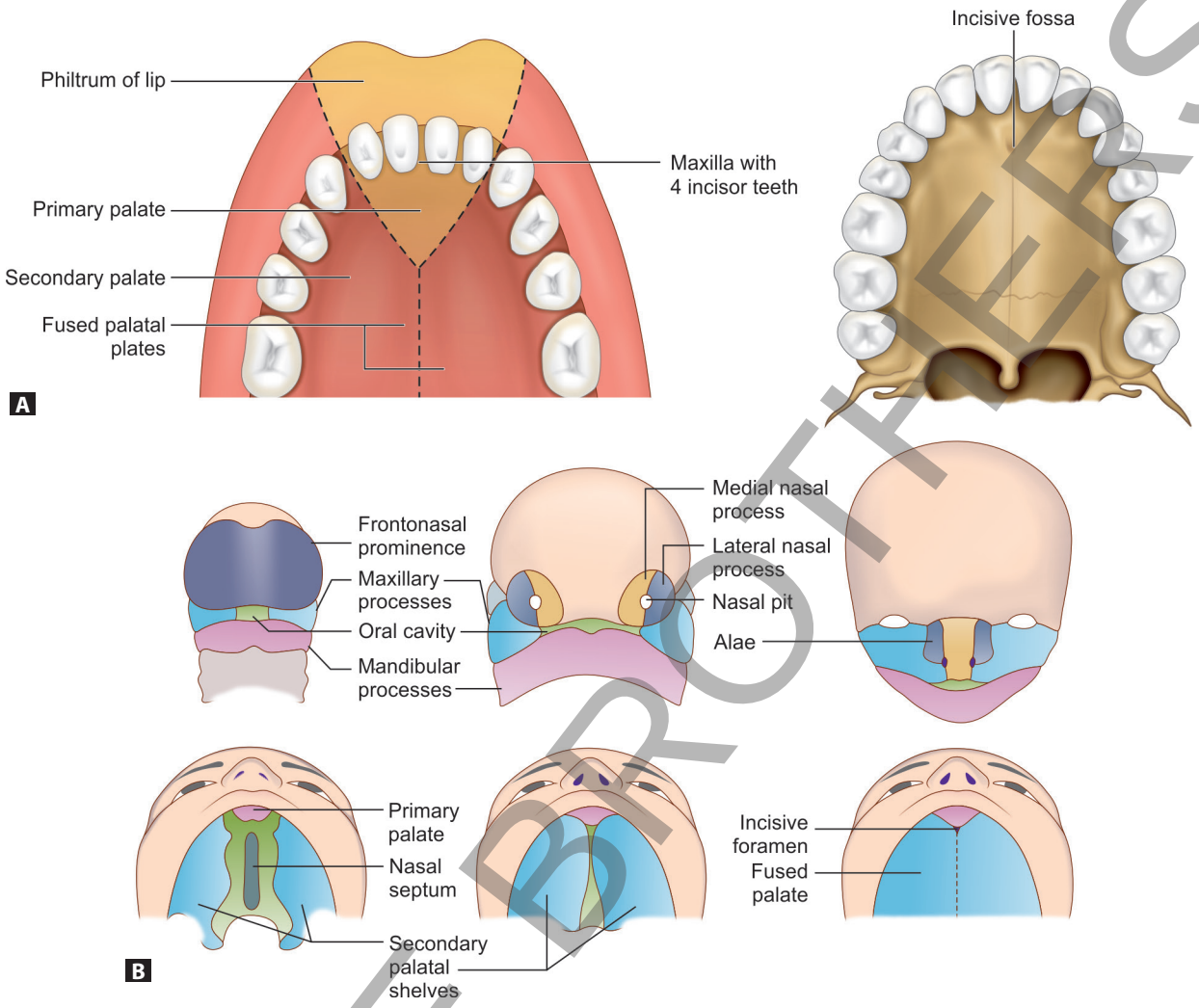

Figures 3.6A and B: (A) Primary and secondary palate; (B) Fusion of two palatine shelves to the primary palate.

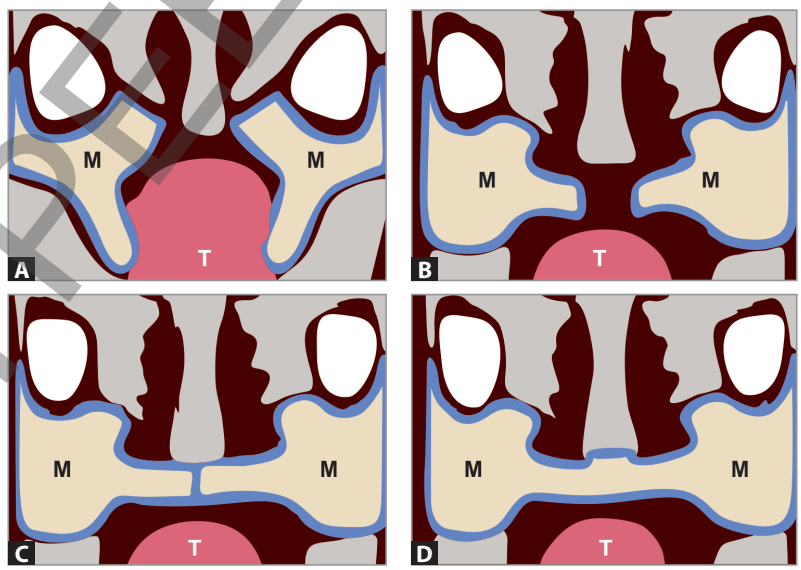

Figures 3.7A to D: (A) Common oronasal cavity occupied by the developing tongue (T); (B) Horizontal snap-up of the palatine shelves from the vertical position due to the mandibular growth and descendance of the tongue; (C) Palatine shelves and nasal septum growing toward each other and fusing; (D) Oral cavity is separated from the nasal cavity by the palate (M—maxillary process).

JAYPEE BROTHERS

Flowchart 3.2: Development of palate.

- Development starts in the 5th week of gestation
- Separation of nasal cavity from oral cavity after the formation of palate
- Development of palate starts with two components: Primary palate and secondary palate
- Primary palate by frontonasal process and secondary palate by palatine shelves of the maxillary processes
- Formation of palatine shelves
- Palatine shelves positioned vertically on either side of the developing tongue
- Growth of mandible (tongue moves downward and forward)
- Shelf elevation of palatine shelves and fusion in midline with primary palate and nasal septum
- Final differentiation by anterior 2/3rd ossifies and make **hard palate** and posterior 1/3rd which is nonossified make **soft palate**

Factors which facilitate the elevation of palatine shelves include differential growth of the palatine shelves, hydrostatic forces exerted by hyaluronic acid and other glycosaminoglycans (GAG), compressive forces from maxillary processes, downward movement of tongue, and urge in mouth opening.

Palate morphogenesis is governed by several key signaling pathways, including Sonic Hedgehog (Shh), Wnt, TGF-β, FGF, and BMP, which act in coordination with transcription factors to control palatal shelf growth, elevation, adhesion, and subsequent fusion.

DEVELOPMENT OF TONGUE

- The tongue is a muscular organ, which helps with mastication, deglutition, and speech.
- It is divided into two parts, namely anterior two-thirds (oral part) and posterior one-third (pharyngeal part), which is marked by a "V"-shaped faint groove called sulcus terminalis **(Figures 3.8A and B)**.
- Tongue develops at the same time as the palate develops, around 4th week of intrauterine life from the floor of the oral cavity.
- The pharyngeal arches contribute to the formation of anterior and posterior parts of the tongue. The anterior part of the tongue develops from three swellings derived from the first pharyngeal arch: two lateral lingual swellings arising from its medial aspect and a midline swelling known as the *tuberculum impar*.

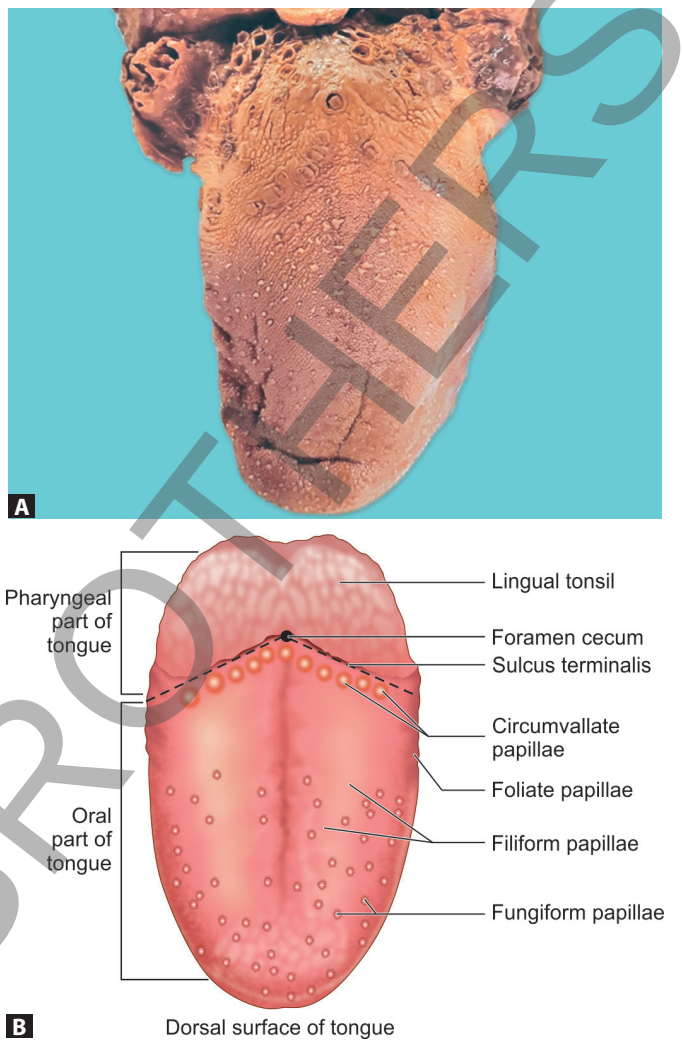

Figures 3.8A and B: Anatomy of the dorsal portion of the tongue.

- The major portion of the anterior part of the tongue is thus formed by the fusion of two lateral lingual swellings, while the remaining portion is contributed by the tuberculum impar **(Figure 3.9A)**.
- Downward proliferation of the epithelium is noticed immediately behind the tuberculum impar, which contributes to the development of thyroid gland and is called *thyroglossal duct*. This region is marked by a depression called *foramen cecum*.
- At about 5th to 6th week, another midline swelling called hypobranchial eminence *(copula of His)* develops in relation to second, third and fourth arches, which have a cranial part and a caudal part. The cranial part, which is related to second and third arches is called *copula*, while the caudal part is related to the fourth arch.
- Copula forms the posterior part of the tongue and at this instance the mesoderm of the third arch overgrows the second arch to fuse with the first arch.
- The third arch endoderm thus forms the posterior part of the tongue, while the posterior most part is developed

JAYPEE BROTHERS

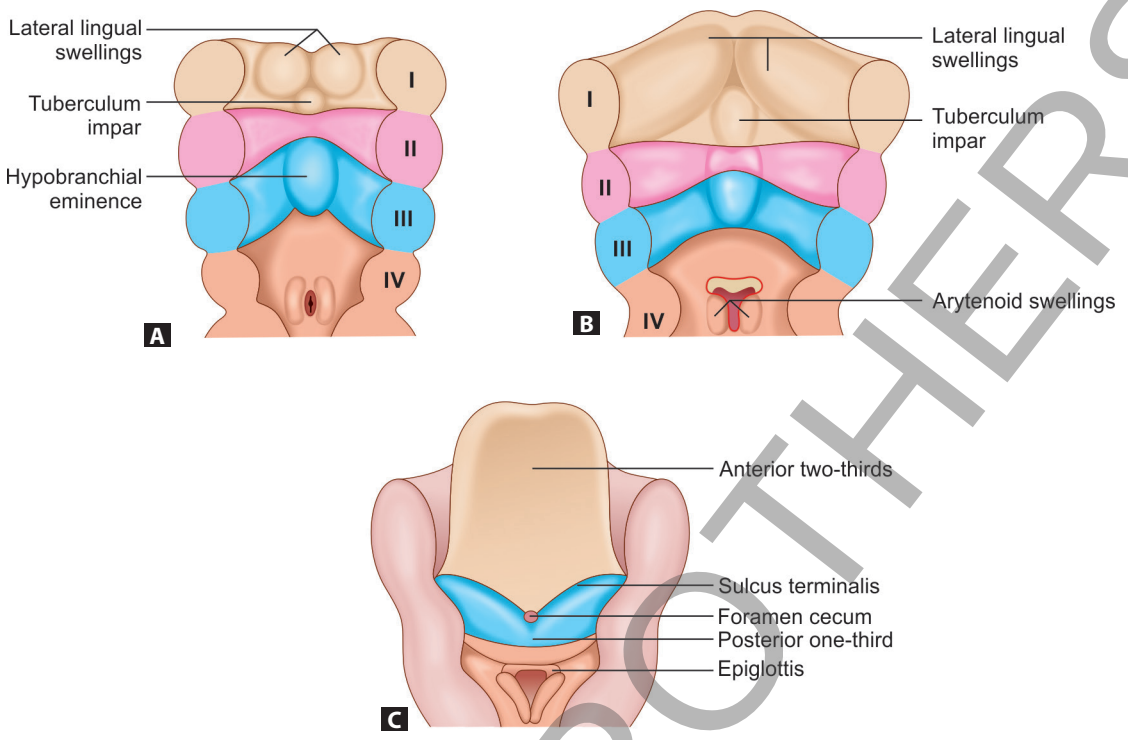

Figures 3.9A to C: (A) Three swellings from first arch giving rise to anterior tongue; (B) Fusion of two lateral lingual swellings and tuberculum impar to form the anterior portion of the tongue; (C) Overgrowth of hypobranchial eminence from the third arch to form the posterior portion of the tongue.

from the fourth arch. The mesenchymal contribution of the second arch in the development of the tongue is almost nil **(Figures 3.9B and C) (Flowchart 3.3).**

Innervation of tongue differs for anterior and posterior part as it involves multiple pharyngeal arches during development. The anterior part of the tongue is supplied by the lingual nerve and chorda tympani nerve. Lingual nerve is the branch of trigeminal nerve, which in turn is a nerve of first arch, while chorda tympani is the branch of facial nerve, which in turn is a pretrematic nerve of the first arch. The posterior one-third of the tongue is supplied by the nerve of third arch, the glossopharyngeal nerve and the posterior most part of the tongue is supplied by the superior laryngeal nerve, the nerve of the fourth arch. Taste buds, which are the specialized structures, are seen in relation to the terminal branches of the nerve fibers. The muscles of the tongue are developed from occipital myotomes and are supplied by the hypoglossal nerve.

The genetic and molecular signaling mechanisms governing tongue development are largely parallel to those involved in the formation of the face and palate. Along with the growth factors responsible for facial development, neurotrophic factors play a key role in taste bud differentiation, while myogenic regulatory factors control the differentiation of tongue musculature derived from the occipital myotomes.

Flowchart 3.3: Development of tongue.

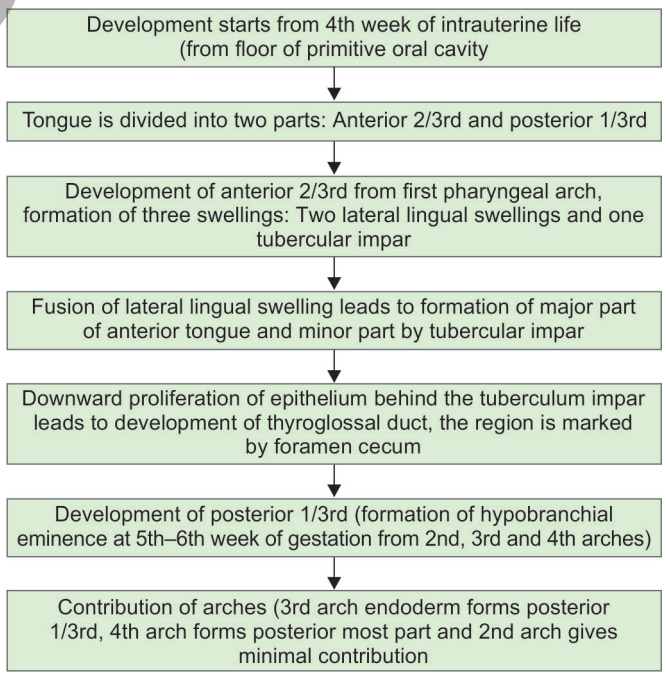

CLINICAL CONSIDERATIONS

Development of face is a complex process, involving cellular proliferation, migration, interaction, differentiation, and

JAYPEE BROTHERS



Figures 3.10A to D: (A) Incomplete or cleft lip; (B) Unilateral cleft lip and palate; (C) Bilateral cleft lip and palate; (D) Cleft palate.
(*Courtesy:* Dr Manikandhan R, Meenakshi Ammal Dental College, Chennai, India).

organization. Disturbances in any of these events may result in developmental anomalies. These disturbances may be caused by environmental or genetic factors and may range from absence to deficiency and rarely an increase in size of the specific tissue or organ.

As formation of the face involves fusion of various components/processes, any defect in failure or incomplete fusion may result in developmental anomalies particularly clefts. Several deformities associated with defective fusion have been reported; however, the frequent ones are given here:

- Failure of fusion of facial prominences, results in various cleft anomalies in the face including *cleft lip and cleft palate* **(Figures 3.10A to D)**.
- *Clefts* are common in the upper lip, which results from the failure in fusion of maxillary process with the medial nasal process and can be unilateral or bilateral (hare lips). Cleft of the lower lip occurs due to the failure in fusion of mandibular process at the midline and is very rare.
- Like cleft lip, cleft palate may form due to defective fusion of palatal components. It can be unilateral or bilateral, complete or incomplete, restricted to hard palate or extend to involve the soft palate.
- *Oblique facial cleft* results from the nonfusion of maxillary and lateral nasal processes. This cleft runs from medial canthus of the eye to the angle of the mouth, with the absence of nasolacrimal duct.
- *Horizontal facial cleft* results from incomplete fusion of maxillary and mandibular processes of the first arch; the milder form of which results in macrostomia (increased mouth opening).
- Genetically related anomalies like *Treacher Collins syndrome* or *mandibulofacial dysostosis* can occur when there is defect in the development of entire first arch on any one or both sides.
- *Developmental deformity of tongue* may be due to failure or incomplete fusion of two lateral lingual swellings resulting in median lingual cleft or cleft tongue. Other developmental anomalies include *macroglossia* (large-sized tongue), *microglossia* (small-sized tongue), and *ankyloglossia* (the apical portion attached to the floor of the mouth) **(Box 3.1)**.

Box 3.1: Clinical considerations

- Cleft anomalies in the face—due to failure of fusion of facial prominences (cleft lip and cleft palate).
- Oblique facial cleft—due to nonfusion of maxillary and lateral nasal process.
- Horizontal facial cleft—due to incomplete fusion of maxillary and mandibular processes of the first arch.
- Genetically related anomalies—Treacher Collins syndrome or mandibulofacial dysostosis.
- Developmental deformity of tongue—due to failure or incomplete fusion of two lateral lingual swellings causes cleft tongue.
- Macroglossia—large sized tongue.
- Microglossia—small sized tongue.
- Ankyloglossia—apical portion attached to the floor of the mouth.

ESSENTIAL HIGHLIGHTS OF DEVELOPMENT OF FACE, PALATE AND TONGUE

- Buccopharyngeal membrane separates the primitive oral cavity from foregut.
- Face is formed majorly by frontonasal process, two maxillary and two mandibular processes.
- First pharyngeal arch gives rise to maxillary and mandibular process on each side.
- Maxillary process fuses with the lateral and medial nasal process to form the upper lip.
- Nasal placode and lens placode are ectodermal thickenings seen on the frontonasal process.
- Initially there is a common oronasal cavity, occupied entirely by the developing tongue.

JAYPEE BROTHERS

- Palate separates the nasal cavity from the oral cavity.
- Hard palate is formed by both primary and secondary palate.
- Secondary palate is formed by the fusion of two palatal processes of maxilla.
- Soft palate does not ossify and is formed by muscles.
- Tongue develops from the first, second, third and fourth pharyngeal arches, however, the mesenchymal contribution of the second arch in tongue development is almost nil.
- Anterior part of the tongue is formed by the fusion of two lateral swellings and tuberculum impar.
- The posterior part of the tongue is developed from hypobranchial eminence.
- Anterior two-thirds and posterior one third of the tongue is demarcated by 'V'-shaped faint groove called sulcus terminalis.
- Muscles of the tongue are developed from occipital myotomes.
- Failure in fusion of maxillary process with the medial nasal process results in the formation of cleft lip.



SELF-ASSESSMENT KIT

Practice Questions

1. Explain the development of face.
2. Detail the events involved in the development of palate.
3. Briefly explain about the formation of tongue.
4. Write a short note on cleft lip and cleft palate.
5. Describe the developmental anomalies of tongue.



MULTIPLE CHOICE QUESTIONS

Simple Recall Questions

1. In the developing embryo, the stomodeum (also known as the stomatodeum) is the anatomical precursor to which of the following structures?
a. Pharyngeal part of oral cavity
b. Primitive oral cavity
c. Anterior part of the oral cavity
d. Fully developed oral cavity

2. During embryonic development, the primitive oral cavity is separated from the foregut by which structure?
a. Nasal placode
b. Palatal process of maxilla
c. Buccopharyngeal membrane
d. Soft palate

3. The maxillary and mandibular processes, which are responsible for forming the majority of the middle and lower face, are derived from which of the following embryonic structures?
a. First arch
b. Second arch
c. Third arch
d. Fourth arch

4. Face develops from:
a. Frontonasal process
b. Maxillary process
c. Mandibular process
d. All the above

5. During the development of the face, the maxillary process merges with the lateral nasal process and subsequently with the medial nasal process. Successful fusion at these sites is essential for the formation of which of the following structure?
a. Philtrum
b. Upper lip
c. Base of the nose
d. None of the above

6. The primitive palate is formed from:
a. Lateral nasal process
b. Mandibular process
c. Maxillary process
d. Frontonasal process

7. Secondary palate is formed by the:
a. Fusion of primitive palate to nasal septum
b. Fusion of palatine shelves of maxillary process
c. Downward growth of tongue
d. Fusion of mandibular processes

8. Primary palate and secondary palate fuse to form:
a. Anterior part of the hard palate
b. Posterior part of the hard palate
c. Soft palate
d. Both a and b

JAYPEE BROTHERS

9. Which part of the palate does not ossify?
a. Primary palate
b. Secondary palate
c. Midline of palatine shelves
d. Soft palate

10. During a clinical examination of the oral cavity, a student identifies a V-shaped groove on the dorsal surface of the tongue that separates the anterior two-thirds (body) from the posterior one-third (base). This landmark, which also represents the site of the embryonic foramen cecum, is known as the:
a. Sulcus terminalis
b. Tuberculum impar
c. Epiglottis
d. Thyroglossal duct

11. Fusion of two lateral swellings and tuberculum impar forms:
a. Posterior most part of the tongue
b. Anterior part of the tongue
c. Epiglottis
d. None of the above

12. The posterior part of tongue is formed from
a. First arch
b. Fifth arch
c. Hypobranchial eminence
d. Tuberculum impar

13. Which of the following arches contributes very minimally to the tongue development?
a. First arch
b. Second arch
c. Third arch
d. Fourth arch

14. Which is the nerve of the first arch?
a. Facial nerve
b. Trigeminal nerve
c. Glossopharyngeal nerve
d. Hypoglossal nerve

15. Anterior part of the tongue is innervated by
a. Lingual nerve
b. Glossopharyngeal nerve
c. Vagus
d. Mental nerve

16. Hypobranchial eminence is otherwise called as:
a. Tuberculum impar
b. Copula of His
c. Lateral swelling
d. Median swelling

17. A newborn presents with a cleft palate. Upon further investigation, it is determined that the condition resulted from a failure in the fusion of the two palatal shelves. Which of the following developmental defects is most likely responsible for this condition?
a. Unilateral cleft palate
b. Bilateral cleft palate
c. Midline cleft
d. Clefts of the soft palate

18. A newborn presents with difficulty in moving the tip of the tongue, and it appears attached to the floor of the mouth at the apex. This condition is called:
a. Microglossia
b. Macroglossia
c. Aglossia
d. Ankyloglossia

19. Failure of fusion of maxillary process and lateral nasal process leads to the formation of:
a. Cleft lip
b. Oblique facial cleft
c. Cleft of the lower lip
d. Cleft palate

20. Failure or incomplete fusion of two lateral lingual swellings result in:
a. Cleft tongue
b. Bifid uvula
c. Ankyloglossia
d. Microglossia

Case-based Questions

21. A child presents with a cleft lip and palate, where there is an abnormality in the fusion of the facial prominences during development. Which of the following clefts is caused by the failure of fusion between the maxillary and lateral nasal processes?
a. Oblique facial cleft
b. Horizontal facial cleft
c. Cleft lip
d. Cleft palate

22. A newborn is diagnosed with a unilateral cleft lip. During the clinical examination, the dental student recalls that this condition arises due to a failure in the fusion of specific embryonic processes. Based on the developmental timeline, which processes failed to unite?
a. Two mandibular processes at the midline
b. Maxillary process and lateral nasal process
c. Maxillary process and medial nasal process
d. Lateral nasal process and medial nasal process

Combined Response Questions

23. A newborn presents with a failure of the nasal and oral cavities to separate, diagnosed as a failure of secondary palate formation. Concerning the normal embryological origin and development of the secondary palate, which of the following statements are correct?
1. It is derived from the palatine shelves, which are internal projections of the maxillary processes.
2. Development involves the elevation of these shelves from a vertical position to a horizontal position above the tongue.

JAYPEE BROTHERS

3. The definitive secondary palate is formed by the fusion of these shelves in the midline.
4. It includes the premaxillary portion of the maxilla containing the four incisor teeth.

Options:

a. 1, 2, and 3 are correct
b. 1 and 3 are correct
c. 2 and 4 are correct
d. 4 only is correct

24. During a clinical evaluation, a developmental anomaly is localized specifically to the anterior two-thirds of the tongue, while the posterior one-third appears normal. Concerning the embryonic structures responsible for the formation of the affected region, which of the following statements are correct?

1. The affected region is primarily derived from the first pharyngeal arch.
2. The anomaly involves the failure or abnormal growth of the lateral lingual swellings.
3. The tuberculum impar contributes to the midline of the affected area but is often overgrown.
4. The defect involves derivatives of the third and fourth pharyngeal arches, specifically the hypobranchial eminence.

Options:

a. 1, 2, and 3 are correct
b. 1 and 3 are correct
c. 2 and 4 are correct
d. 4 only is correct

ANSWERS

1. b	2. c	3. a	4. d	5. b	6. d	7. b	8. d	9. d	10. a	11. b	12. c	13. b	14. b	15. a
16. b	17. c	18. d	19. b	20. a	21. a	22. c	23. a	24. a						

Bibliography

Scan the QR code for Bibliography.

JAYPEE BROTHERS

for detailed information on dental books, visit our website www.ejaypee.com, for detailed information on dental books, visit our website www.ejaypee.com, for detailed information on d

TEXTBOOK OF
ORAL EMBRYOLOGY & HISTOLOGY

Salient Features

- A comprehensive foundation of general embryology with clear concepts and clinical relevance.
- Covers recent advances in the development of oral and paraoral tissues to keep readers updated with evolving science.
- Richly illustrated with descriptive photomicrographs, schematic diagrams and easy-to-follow flowcharts for better visualization and understanding.
- Includes a dedicated chapter on stem cells and their emerging role in tissue development and regeneration.
- Essential Highlights at the end of each chapter for quick revision and exam-focused learning.
- Extensive collection of MCQs and practice questions to reinforce concepts and support self-assessment.
- A separate section featuring histologic diagrams for practical understanding and microscopic identification.
- Enriched with expert contributions from eminent academicians from India and across the globe.



B Sivapathasundharam MDS (Oral Pathology) FIAOMP FISDR FIAFO is Professor, Department of Dental Surgery and Pro Vice-Chancellor, Sri Venkateswaraa University, Redhills, Chennai, Tamil Nadu, India. A distinguished academician with over 36 years of teaching and clinical experience, he completed his BDS (1986) and MDS (1989) from the Government Dental College and Hospital, Chennai, affiliated to the University of Madras.

He has held several key academic and administrative positions, including Principal of Priyadarshini Dental College and Hospital and Principal, Professor and Head, Department of Oral Pathology at Meenakshi Ammal Dental College, Chennai. He has also served as Registrar (Academic) and Pro Vice-Chancellor at Meenakshi Academy of Higher Education and Research (MAHER), Chennai.

Dr Sivapathasundharam has contributed extensively to dental literature, with over 200 scientific publications in reputed journals. He has served as Editor/Editor-in-Chief of several leading journals, including the Indian Journal of Dental Research, Journal of Oral and Maxillofacial Pathology, Journal of Education and Ethics in Dentistry, and Journal of Forensic Dental Sciences. He was the adaptation editor for five consecutive editions of Shafer's Textbook of Oral Pathology and is the editor of the Manual of Salivary Gland Diseases.

He is a recipient of several prestigious awards, including the ISDR Founder President Award, Best Researcher Award, and Best Teacher Award from MAHER. He was conferred the Lifetime Achievement Award by the Indian Association of Oral and Maxillofacial Pathology (IAOMP) in 2025 and currently serves as its President-Elect.

JAYPEE BROTHERS

Shelving Recommendation
DENTISTRY

ISBN 978-81-6799-979-5

Buy from ejaypee

JAYPEE BROTHERS