Textbook of Dental and Oral Anatomy, Physiology and Occlusion

With Multiple Choice Questions

Satish Chandra
Shaleen Chandra
Sourabh Chandra

Foreword by
RK Bali
Anil Kohli

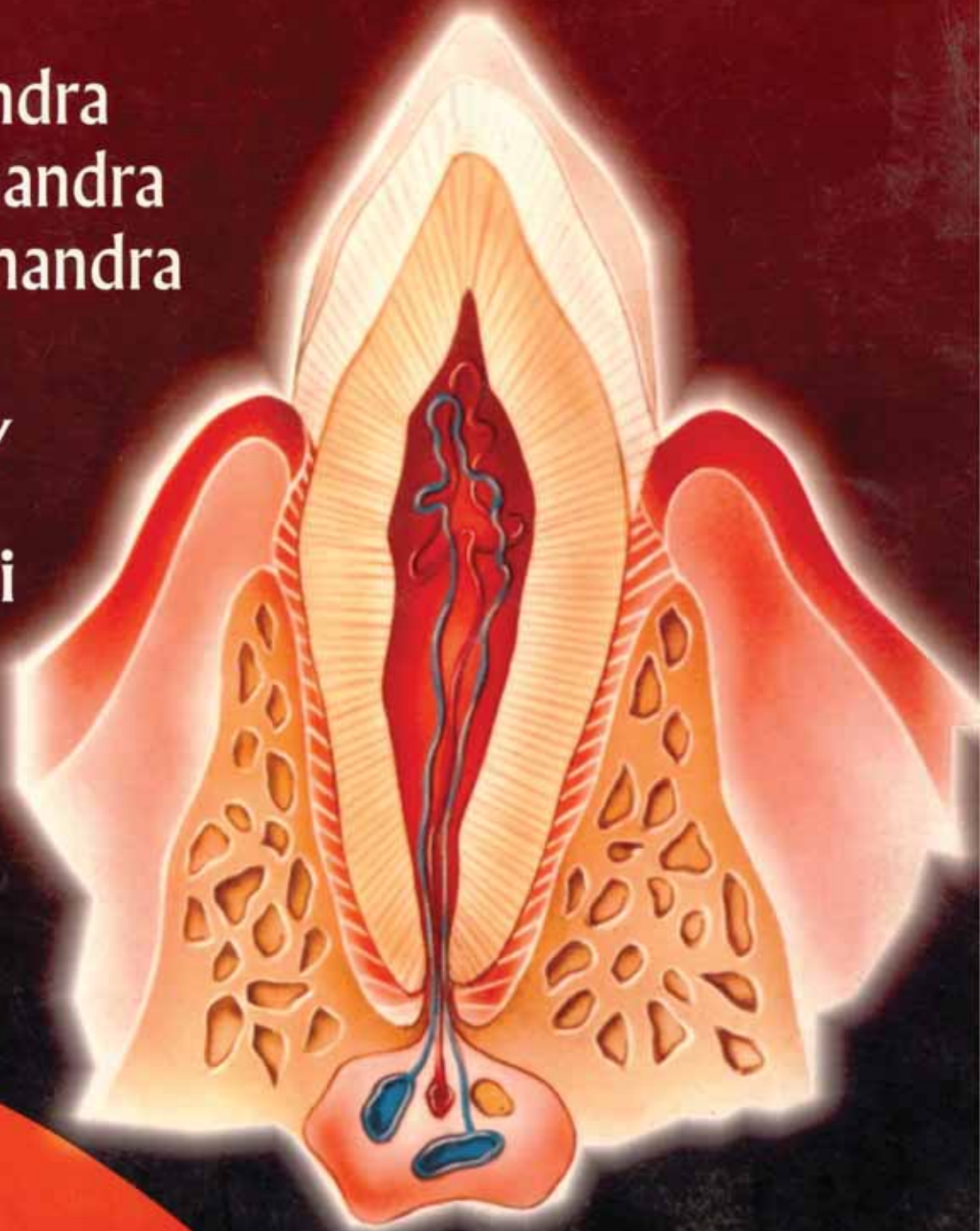

JAYPEE

Contents

1. Introduction 1-12
Nomenclature and Differences in Teeth 1
Important Descriptive Landmarks on the Tooth Surface 1
Structure of Tooth 5
Life Cycle of a Tooth—The Crown and Root 6
Dental Tissues 7
Junctions of Tooth Tissues 10
Anatomic and Clinical Crown 10
Oral Physiology and Importance of its Study 11
Organization of the Functions of the Oral Cavity 11

2. Oral Examination 13-25
Introduction 13
Normal Anatomy of the Oral Cavity 13
Intraoral Examination 15
Surface Anatomy and Location of Structures that can be Palpated Extraorally 24

3. Dental Anthropology (Comparative Study of Dentition) 26-35
Introduction 26
Evolution of the Jaws 26
Dentition in Vertebrates 27
Dentition of Primates 31

4. Development and Eruption of Teeth 36-47
Introduction 36
Development 36
Eruption 38

5. Tooth and Surface Identification 48-55
Introduction 48
Nomenclature and Tooth Identification Systems 48
Different Surfaces of the Teeth 52
Line Angles and Point Angles 55

6. Drawing and Carving of Teeth 56-62
Introduction 56
Method of Measurement of Teeth 56
Drawing an Individual Tooth 59
Carving an Individual Tooth 60

7. Deciduous (Primary) Teeth 63-87
Introduction 63
Importance of Deciduous Dentition 63
Difference between Deciduous and Permanent Dentition 64
Occlusion of Deciduous Teeth 86

JAYPEE BROTHERS

8. Physiology of Dentition 88-93
Introduction 88
Alignment and Contacts 88
Interproximal Form 88
Root Form 89
Occlusal and Dental Arch Compensating Curvatures 89
Tooth Form and Jaw Movements 91
Concept of Crown Outline 92

9. Physiologic Form of Teeth in Relation to Functions and Periodontium 94-106
Introduction 94
Proximal Contact Areas 94
Interproximal Spaces 97
Embrasures (Spillways) 98
Facial and Lingual Contours of the Crowns. 102
The Cervical Lines on Mesial and Distal Surfaces (Cemento-Enamel Junction) 104
The Height of Epithelial Attachment 104

10. Permanent Maxillary Incisors 107-118
Introduction 107
Functions 107
Morphology and General Outline of Maxillary Central Incisors 107
Characteristics of All Incisors 108
Arch Characteristics 111
Description of Permanent Maxillary Central Incisors 111
Description of Permanent Maxillary Lateral Incisors 115

11. Permanent Mandibular Incisors 119-126
Introduction 119
Mandibular Central Incisors 119
Mandibular Lateral Incisors 123
Variations in Mandibular Incisors 126

12 Permanent Canines 127-136
Introduction 127
Functions 127
General Characteristics of Canines of Both the Arches 128
Maxillary Canines 128
Mandibular Canines 132
Variations 136

13. Maxillary Premolars 137-147
Introduction 137
Functions 137
Comparison of Morphology of Premolars to Anterior Teeth 137
Common Characteristics of All Premolars 138
Maxillary First Premolar 141
Maxillary Second Premolar 143
Distinguishing Features Between First and Second Maxillary Premolars 147
Distinguishing Features and Similarities Between Right and Left Maxillary First and Second Premolars 147
Variations 147

14. Mandibular Premolars 148-159
Introduction 148
Mandibular First Premolar 148
Mandibular Second Premolar 153

JAYPEE BROTHERS

15. Permanent Maxillary Molars 160-171
General Description 160
Maxillary First Molar 161
Maxillary Second Molar 166
Maxillary Third Molar 169

16. Permanent Mandibular Molars 172-183
Introduction 172
Mandibular First Molar 172
Mandibular Second Molar 177
Mandibular Third Molar 181

17. Pulp Cavities of the Teeth 184-208
Introduction 184
Pulp Cavities of Maxillary Teeth 186
Pulp Cavities of Mandibular Teeth 193

18. Basic Concept of Occlusion and Malocclusion 209-231
Introduction 209
Development of Occlusion 209
Dental Arch Form 212
Compensating Occlusal Curvatures and Planes of Dental Arches 212
Jaw Relationships—The Relationship of the Mandible to the Maxillae 213
Angulation of Individual Teeth and Root Shape in Relation to Various Planes 215
Shape of Incisal and Occlusal Thirds of Teeth To Suit the Various Functions 217
In Centric Occlusion—Facial and Lingual Relations of Individual Tooth to its Antagonists in the Opposite Arch 218
In Centric Occlusion—Occlusal Contacts and Intercuspal Relationships of Individual Tooth of one Arch to that of Opposite Arch 220
During the Various Mandibular Positions and Movements Occlusal Contacts and Intercusp Relations of all the Teeth 225
Neurobehavioral Aspects of Occlusion/Stomatognathic System 227
Occlusal Stability 229
Guidance of Occlusion 229
Vertical Dimension 229
Oral Motor Behavior 230
Types of Malocclusion 230

19. Dento-osseous Structures 232-245
Maxillae 232
Maxillary Sinus 239
Mandible 242

20. Temporomandibular Joints and Their Functions 246-256
Introduction 246
Anatomy of the Temporomandibular Joint 246
Development of the Temporomandibular Joint 248
Ligaments 249
Blood Supply and Nerve Supply 249
Muscle Functioning of Temporomandibular Joint 250
Normal Movements Within the Temporomandibular Joint 252
Act of Chewing 254

21. Oral Physiology of Dental Pain 257-261
Oral Physiology 257
Pulpal Pain 258
Mechanoreceptors 259
Kinesthesia 260
Thermal Receptors 260

JAYPEE BROTHERS

22. Special Oral Functions 262-271
Salivary Secretion 262
Mastication 264
Taste 266
Swallowing 270
Speech 271

Multiple Choice Questions 273

Index 291

JAYPEE BROTHERS

CHAPTER 4

Development and Eruption of Teeth

INTRODUCTION

The timely initiation of development of the teeth and their eruption into the oral cavity is very important for healthy dentition. This knowledge is also useful in forensics, odontology, archaeology, demography and paleontology. Eruption is the process by which the tooth moves within the jaw bones, comes out into the oral cavity and comes up to the occlusal contact and maintains its clinical position.

1. During infancy the dental age is estimated by the following.
   a. Number of teeth present in the oral cavity.
   b. Stages of eruption of teeth.
   c. The formation of crowns and roots of the teeth at each chronological age.
2. During the period of mixed dentition, it is assessed on the basis of
   a. Erupted teeth present.
   b. The amount of resorption of the roots of the deciduous (primary) teeth
   c. The amount of development and presence of the permanent teeth.

Therefore, the calcification and emergence of a tooth, along with root formation and tooth eruption play an important role in determining the dental age. All the developmental stages which are not visible in oral cavity can be visualized on radiographs.

DEVELOPMENT

The tooth development is least affected by environmental factors like nutrition, endocrinopathies, etc. hence the dentition may be considered to be the single best physiological indicator of chronological age in juveniles. This indicates that dental age can reflect more accurate assessment of physiologic age comparable to age based on skeletal development, weight or height.

The dental age assessed by radiographs on the basis of tooth formation and calcification is more reliable than the chronologies of tooth eruption. Tooth eruption occurs in a single episode whereas tooth formation and calcification can be divided into different stages, which continuously cover the development of tooth. Tooth eruption can be altered by severe malnutrition, oral jaw bone diseases, caries, tooth loss, etc. thus further influencing the dental age assessment.

STANDARDS OF TOOTH GENERATION

Various landmarks in the generation of dentition are based on the studies of dissected prenatal anatomic material and from radiographic imaging of the teeth of the same subjects over long periods (longitudinal data). These are also confirmed by the results on different subjects of different ages seen once (cross-sectional data). From such studies both descriptive information and chronological data are obtained. It is quite difficult to define ideal standards of tooth generation from such isolated studies which are based on different variables and many different statistical methods. Most of the studies which are based on dental development have been carried out on the European and American populations. The results may not be very precisely correct for other populations of the world. In other populations, there are sporadic studies.

CHRONOLOGIES OF DENTITION

In the literature, various chronologies have been described for standards of normal growth from sporadic studies based on different variables. Many different statistical methods have been suggested but none can be considered ideal.

The chronology of dentition suggested by Logan W, and Kronfeld RJ (1933), has been shown in Table 4-1. It has been revised from time to time to include other chronologies suggested by Kronfeld (1935), Kronfeld and Schour (1939), Schour and Massler (1940), Lysell et al (1962), Nomata (1964), Kraus and Jordan (1965) and Lunt and Law (1974).

JAYPEE BROTHERS

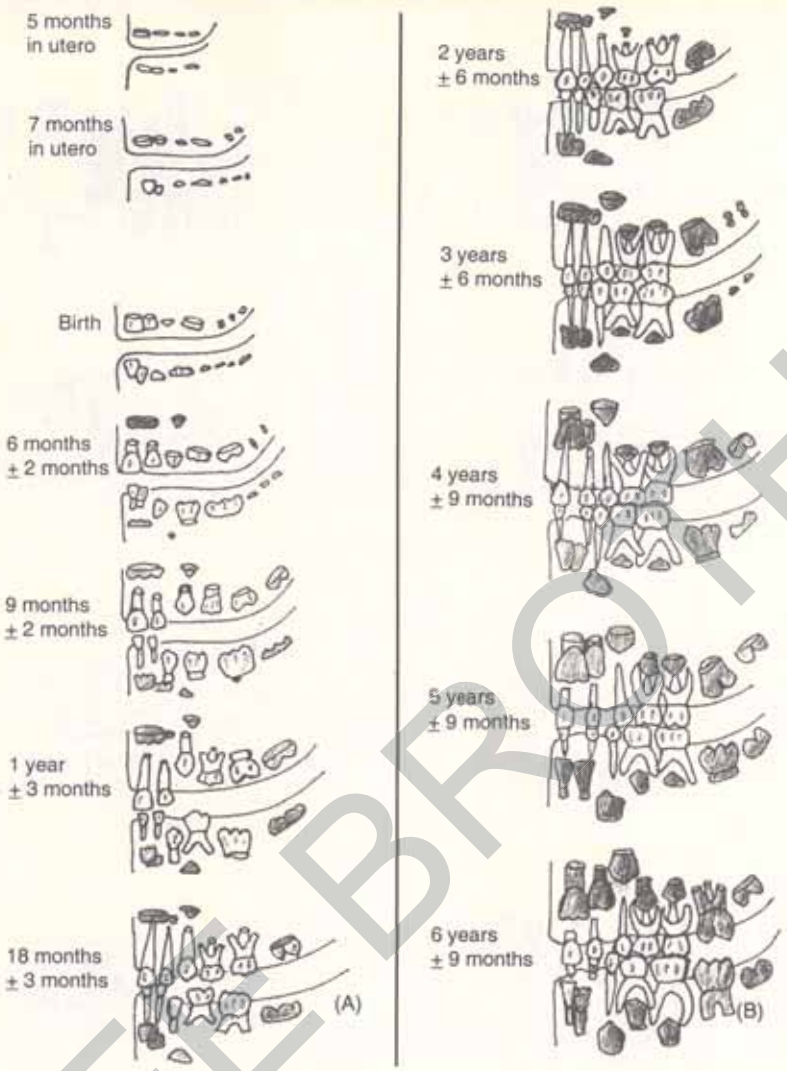

Figs 4.1A and B: Facial view of development of deciduous dentition. Deciduous teeth are light in color and permanent teeth are dark in color (A) Infancy (B) Early childhood.

Revisions have been made to modify the calcification schedule (by Kraus and Jordan), 1965; Lunt and Law, 1974 and for lateral incisor by Nomata, 1964) and eruption schedule (by Lysell et al, 1962) in the chronology by Logan and Krenfeld in the light of recent studies by Smith (1991).

The cumulative distributive functions or probit analysis appears to be the best method of determining the age of attainment and have been used by several investigators.

The illustrations of the development of the dentition (Figs 4.1 and 4.2) should not be used as ideal standards of normal development. They may be used for informing to patients general aspects of development for precise guidance of clinical procedures and age prediction.

The formation of tooth can be divided into three main stages for studies in radiographs—Initial Calcification, Crown completion and root completion. The tooth formation has been divided into eleven stages by Nolla (1952), into thirteen stages by Gleiser and Hunt (1955) and into fourteen stages (6 for crown and 8 for root) by Moorrees et al (1963). Moorrees et al provided normative data for the development of mandibular canines.

JAYPEE BROTHERS

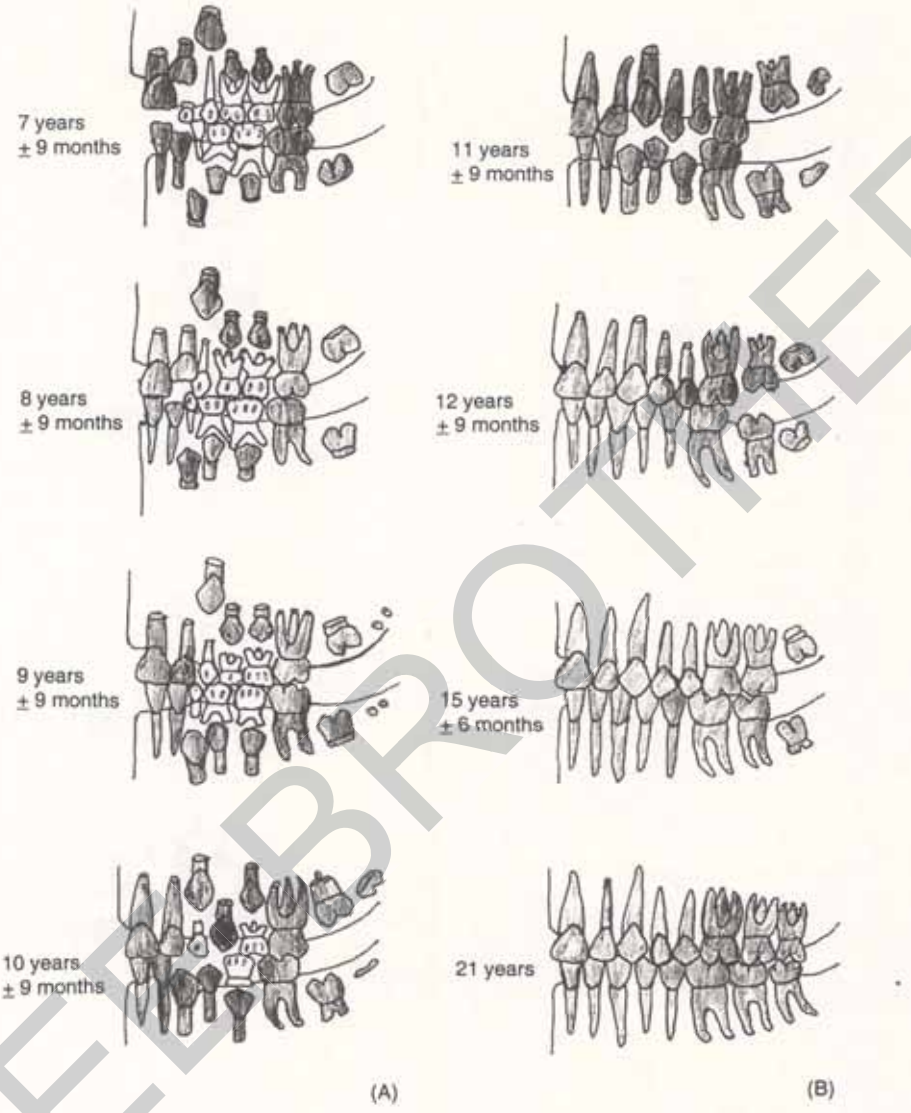

Figs 4.2A and B: Facial view of development of permanent dentition. Permanent teeth are darker in color and deciduous teeth are light in color (A) Late childhood (B) Adolescence.

ERUPTION

THE DECIDUOUS DENTITION

The enamel of the crowns of all deciduous teeth begins to calcify between 3 to 4 months *in utero* (12 and 16 weeks) and completes calcification at about 11 months (Table 4.1). For mandibular teeth, the completion of deciduous roots takes place 14 months after emergence in oral cavity. For maxillary teeth, it takes place approximately 15 months after emergence. All deciduous teeth erupt at about 6 to 30 months of postnatal life and the time taken for the deciduous (primary) dentition for completion is from 2 to 3 years (Fig 4.1), starting from the initial calcification of the deciduous central incisor to the completion of the roots of the deciduous second molar (Table 4.1). However, each permanent tooth takes 8 to 14 years to complete if the third molar is also taken into account (Figs 4.2 to 4.4). Normally at birth no tooth is present in the oral cavity. Sometimes mandibular incisors may be present in newborn infants. These teeth are called natal teeth. In different races and ethnic groups there is considerable variation in eruption dates.

JAYPEE BROTHERS

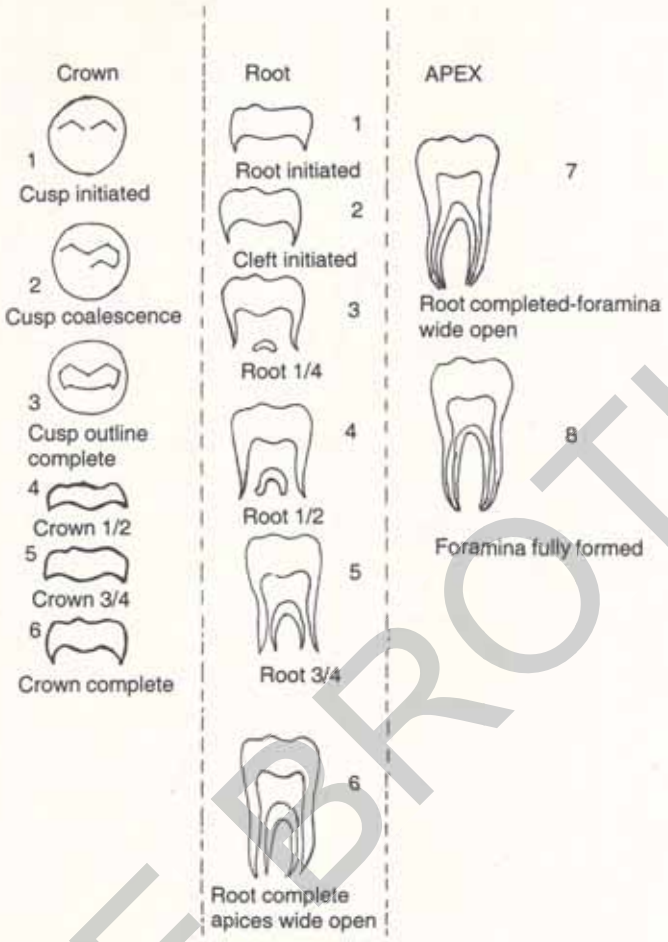

Fig. 4.3: Various stages (6 for crown and 8 for root) of tooth formation in permanent dentition (facial view).

The root formation begins immediately after the enamel completion and gradually the tooth starts to move occlusally in the oral cavity. This tooth movement is called eruption, in which the crown of the tooth emerges into the oral cavity until it comes and remains in occlusion with teeth present in the opposite jaw. The incisal or occlusal wear is also compensated by the passive eruption of the tooth. Various studies on different world populations have shown that the differences in tooth standards exist. Tooth formation, tooth morphology and eruption are highly affected by heritage and the other physiologic parameters like height, sex and skeletal maturation.

The eruption or emergence of deciduous mandibular central incisors occurs at a mean age of 5 months (Table 4.1). In Tables 4.1 and 4.2 values for eruption are given as the mean age and a range of variations

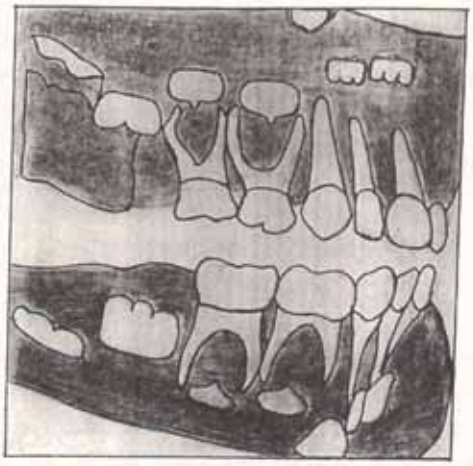

Fig. 4.4: Dentition showing the erupted deciduous teeth and partially developed crowns of the permanent teeth at the age of about two years (seen after removing buccal plate of maxilla and mandible)—Facial view.

JAYPEE BROTHERS

Table 4.1: Chronology of deciduous teeth

Primary tooth	*First evidence of calcification (weeks in utero)*	*Amount of enamel formed at birth*	*Enamel completion (months after birth)*	*Eruption (mean age in months)*	*Root completion (yrs)*
Maxillary					
Central Incisor	14 (12 to 16)	Five-sixths	1 ½	10 (8 to 12)	1 ½
Lateral Incisor	16 (15 to 16 ½)	Two-thirds	2 ½	11 (9 to 13)	2
Canine	17 (15 to 18)	One-third	9	19 (16 to 22)	3 ¼
First Molar	15 ½ (14 ½ to 17)	Cusps united, occlusal surface completely calcified plus a half to three-fourths crown height	6	16 (13 to 19) -Boys (14 to 19) - Girls	2 ½
Second Molar	19 (16 to 23 ½)	Cusps united, Occlusal surface incompletely calcified tissue covers a fifth to a fourth crown height	11	29 (24 to 33)	3
Mandibular					
Central Incisor	14 (13 to 16) weeks *in utero*	Three-fifths	2 ½	8 (6 to 10)	1 ½
Lateral Incisor	16 (15 to 17) weeks *in utero*	Three-fifths	3	13 (10 to 16)	1 ½
Canine	17 (16 to 18) weeks *in utero*	One-third	9	20 (17 to 23)	3 ¼
First Molar	15 ½ (14 ½ to 17) weeks *in utero*	Cusps united, occlusal surface completely calcified	5 ½	16 (14 to 18)	2 ¼
Second molar	18 (17 to 19 ½) weeks *in utero*	Cusps united, occlusal surface incompletely calcified	10	27 (23 to 31) - Boys (24 to 30) – Girls	3

based on plus or minus one standard deviation, after rounding all values to the nearest month. The eruption of these teeth is followed one to two months later by the maxillary central incisors at a mean age of about 8 months, and then by the mandibular lateral incisors at a mean age of 11 months.

Occasionally all four mandibular incisors erupt before the eruption of any of the maxillary teeth. In boys over all eruption is earlier by few weeks. Lunt and Law (1974) have observed that the maxillary first molars often tend to erupt earlier than the mandibular first molars in the deciduous dentition.

JAYPEE BROTHERS

The deciduous mandibular canine erupts at a mean age of 20 months and the deciduous maxillary canines at 19 months of age (Table 4.1).

The deciduous second mandibular molar erupts at a mean age of 27 months and the deciduous second maxillary molar erupts at a mean age of 29 months (Table 4.1) (Fig. 4.1).

The predominant sequence of eruption of the deciduous teeth in the individual jaw is central incisor (A), lateral incisor (B), first molar (D), canine (C), and second molar (E) as depicted in Table 4.1. Variations in that order may be due to reversals of central and lateral incisors, first molar and lateral incisor, or eruption of two teeth at the same time. Jaw reversals in eruption of canines and first molars have been found to be important in increasing the variety of sequences when differences according to jaws are considered.

The completed primary dentition may show evidence of bruxing wear, especially of the anterior teeth. Spacing of teeth may be beneficial for the subsequent eruption of permanent teeth. The premature loss of deciduous teeth because of caries, reflects a lack of knowledge as to the course of the disease and establishes a negative attitude about preventing dental caries in the adult dentition

Sometimes laymen fail to understand the importance of deciduous dentition thinking that they are only temporary. However, the deciduous dentition may be in use from 2 years of age until about 8 years of age, for about 6 years in all. Some teeth are in use from 8 months to 12 years of age. Thus, the deciduous teeth are in use during most important period of the first few years of greatest and most important physical and mental development. Proper maintenance of these teeth will assure better tooth relationships and health long after the shedding of deciduous teeth.

Insufficient space, early loss of deciduous teeth, over retention of deciduous teeth, congenital absence of teeth, and dental anomalies are important factors in the initiation and development of an abnormal occlusion. Early loss of deciduous teeth due to dental neglect is likely to cause loss of arch length resulting in crowding of the permanent dentition. At about 6 years of age, the transition from deciduous to permanent dentition begins with the eruption of the first permanent molars. The early shedding of deciduous teeth may result in early eruption of the permanent teeth.

THE PERMANENT DENTITION

Schour and Massler (1940) have described the initiation of the formation of permanent dentition taking place in three steps. The initiation of the formation of the central and lateral incisors, canines and first molars takes place during the first year in the first step. During the age group of 2 to 4 years, in the second step the initiation of formation of premolars and second molars takes place. The initiation of formation of third molar occurs in third step, at the age of about 5 to 7 years distal to the second molar.

The first molars are the first teeth of permanent dentition to emerge through the gingiva, although this period varies in different groups of population. Because eruption occurs at approximately 6 years of age the teeth are often called" 6 years molars" They begin to calcify at about the time of birth (Table 4.2). These teeth emerge distal to the deciduous second molar and are larger than any of the deciduous teeth (Figs 4.5 to 4.7).

The second permanent tooth to emerge into the oral cavity is the central incisor. Eruption time occurs quite close to that of the first molar, i.e. tooth erupts between 6 to 7 years (Table 4.2). Usually the mandibular central incisor erupts before the maxillary central incisor. It may erupt simultaneously or even before the mandibular first molar. The maxillary central incisor may erupt along with the mandibular lateral incisor.

Before the permanent central incisor erupts the deciduous central incisor must be exfoliated. This takes place by the resorption of deciduous roots. Pressure is exerted by the permanent tooth bud on the roots of deciduous teeth which are subsequently almost fully resorbed. The deciduous crown has lost its anchorage, becomes loose and is eventually lost. During this period the permanent successor tooth has moved occlusally, so that it is at the point of eruption and is in proper position to succeed its predecessor.

Lingual to the roots of deciduous incisors are the follicles of the developing incisors and canines (Figs 4.8 A to G and 4.9). The developing premolars which are to erupt in place of deciduous molars are within the bifurcation of primary molar roots (Fig. 4.10). The permanent incisors, canines and premolars are called succedaneous teeth, since they take the place of their deciduous predecessors. However, failure of the deciduous roots to resorb may bring about prolonged retention of the deciduous tooth (Figs 4.11and 4.12).

JAYPEE BROTHERS

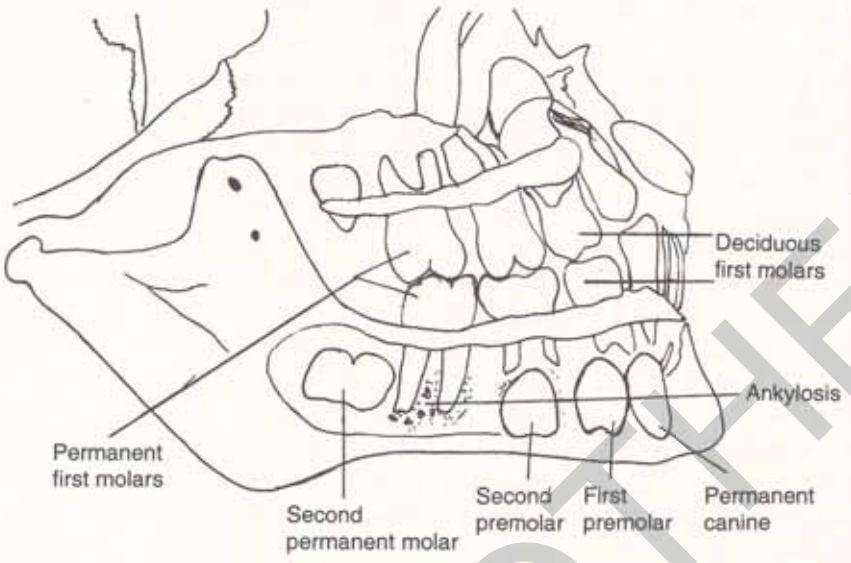

Fig. 4.5: Mixed dentition present in a dried skull of 7 years old child. The outer cortical plate is cut to show the developing permanent teeth.

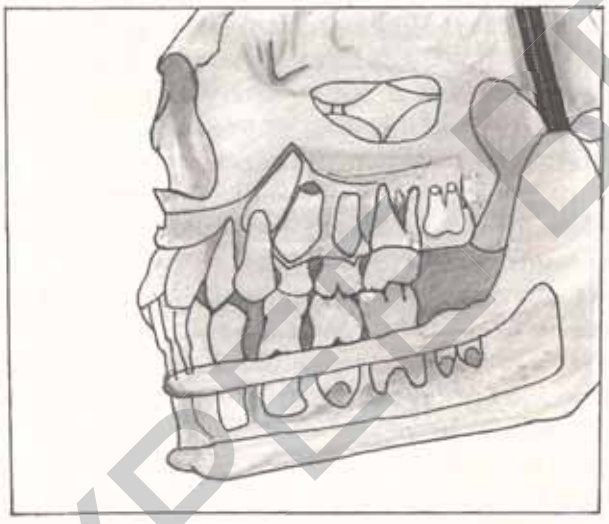

Fig. 4.6: Left side of the lower part of dried skull of a child aged 9 years. The amount of resorption of the roots of the deciduous maxillary molars which has taken place and the relation of the developing premolars above them are visible. The roots of the first permanent molars have been completed. The open pulp canals from apical end in the developing teeth are visible.

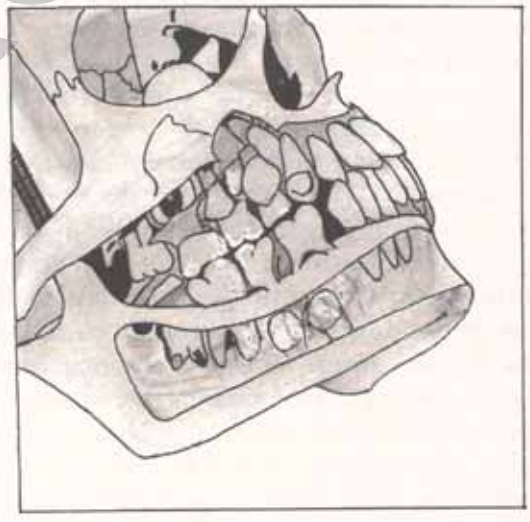

Fig. 4.7: Right side of the lower part of dried skull of a child aged 10 years. The placement of the permanent maxillary canine and premolar and the position and stage of development of the maxillary second permanent molar are visible. The developing roots of the mandibular second permanent molar are also visible.

After the central incisors, mandibular lateral incisors erupt very soon sometimes simultaneously. Next in chronological order erupt the maxillary central incisors. The maxillary lateral incisors erupt after about a year (Table 4.2 and Fig. 4.2). The first premolars follow the maxillary laterals in sequence at the age of 10 to 11 years. The mandibular canines often appear at the same time or a little later. After one year the second premolars erupt and the maxillary canines follow. The second molars erupt at the age of about 12 years, they are posterior to the first molars and are also called "12 years molars".

JAYPEE BROTHERS

Table 4.2: Chronology of permanent dentition

Tooth	*First evidence of calcification*	*Enamel completed*	*Eruption*	*Root Completed*
Maxillary				
Central incisor	3 to 4 months	4 to 5 years	7 to 8 years	10 years
Lateral incisor	1 year	4 to 5 years	8 to 9 years	11 years
Canine	4 to 5 months	6 to 7 years	11 to 12 years	13 to 15 years
First premolar	1½ to 2 years	5 to 6 years	10 to 11 years	12 to 13 years
Second premolar	2 to 2 ½ years	6 to 7 years	10 to 12 years	12 to 14 years
First molar	At birth	2 ½ to 3 years	6 to 7 years	9 to 10 years
Second molar	2 ½ to 3 years	7 to 8 years	12 to 13 years	14 to 16 years
Third molar	7 to 9 years	12 to 16 years	17 to 21 years	18 to 25 years
Mandibular				
Central incisor	3 to 4 months	4 to 5 years	6 to 7 years	9 years
Lateral incisor	3 to 4 months	4 to 5 years	7 to 8 years	10 years
Canine	4 to 5 months	6 to 7 years	9 to 10 years	12 to 14 years
First premolar	1½ to 2 years	5 to 6 years	10 to 12 years	12 to 13 years
Second premolar	2 ¼ to 2 ½ years	6 to 7 years	11 to 12 years	13 to 14 years
First premolar	At birth	2 ½ to 3 years	6 to 7 years	9 to 10 years
Second molar	2 ½ to 3 years	7 to 8 years	11 to 13 years	14 to 15 years
Third molar	8 to 10 years	12 to 16 years	17 to 21 years	18 to 25 years

The third molars usually erupt at the age of 17 to 25 years. Occasionally it may erupt even after the age of 25 years or may not erupt at all. A good amount of jaw growth is needed after the age of 12 years to create space for these teeth. Usually third molars are subject to many anomalies and variations in space. Lack of sufficient development of jaw for accommodation of third molars may create problems of impacted third molars.

Sometimes, root resorption does not follow the routine procedure, with the result that the permanent tooth cannot emerge or is kept out of its usual place. Failure of deciduous roots to resorb may bring about prolonged retention of the tooth.

The average time taken by permanent teeth to emerge into the oral cavity after the completion of calcification of crown is 3.7 years, with a time range of 2.7 years for the lower anterior teeth to 4.7 years for the lower posterior teeth. Generally, tooth eruption occurs a few months earlier in females than in males and the mandibular teeth tend to erupt earlier than their maxillary counterparts except the premolars.

The roots of permanent teeth are usually completely formed in about 2.5 to 4 years, after the crowns have become visible in the oral cavity. In Table 4.2, the figures below root completed indicate the age at which the root apex is completed. The root tip or apex is the last part to develop. On an average, the completion of root formation occurs 2.6 years after eruption of the tooth, ranging from 2.4 years (for the lower anterior teeth) to 2.8 years (for the lower posterior teeth).

In clinical practice, knowledge of eruption schedule is very important. The children and their parents should be adequately and correctly guided concerning the normal eruption time for the teeth. For 28 permanent teeth, except third molars a variation of 12 to 24 months (early or late) of the expected eruption time (given in Table 4.2) is considered normal. For deciduous teeth, the variation of 4 to 8 months is considered normal. The actual position of a tooth which has not erupted on the expected time, particularly when it is considerably overdue, can be determined by dental radiographs. This much delay does not require any active and direct nutritional supplements or treatment.

The tooth crowns show evidence of having developed from four or more lobes which are the primary centers of formation. Lines of demarcation are present on dentin and not on enamel to show this development. Signs called developmental grooves are found on the surfaces of the crowns and roots.

The incisors develop from four lobes-three facial lobes (forming three mamelons) and one lingual lobe (forming the cingulum). Most canines and premolars develop from four (or five) lobes - three facial lobes

JAYPEE BROTHERS

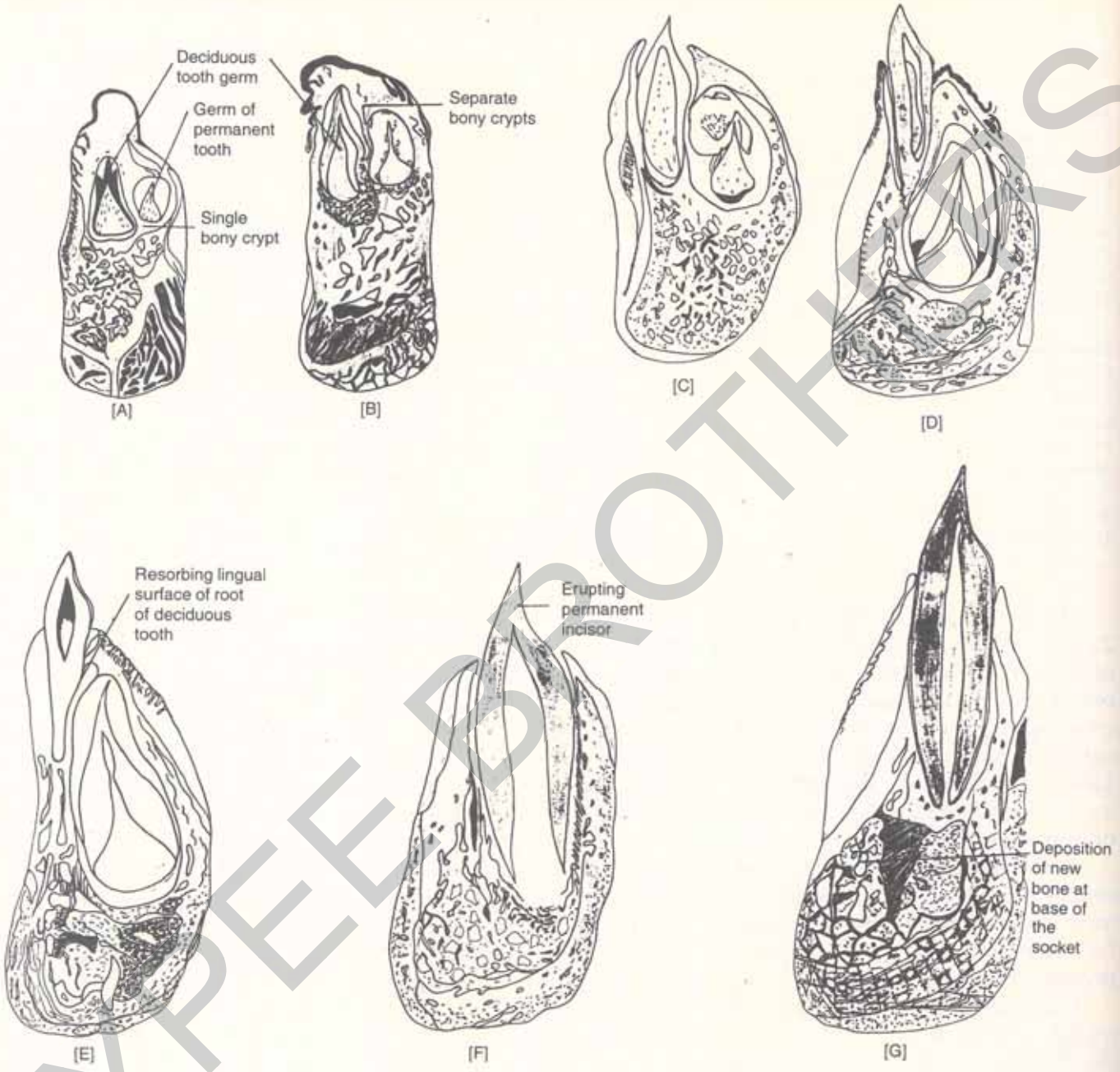

Figs 4.8 A to G: Labiolingual sections of mandible through central incisors. (A) At birth, (B) At the age of four months, (C) Ten months, (D) twenty five months, (E) fifty five months, (F) Seventy five months, and (G) One hundred ten months.

that form the cusps, the three subtle longitudinal ridges separated by two depressions and one (or two) lingual lobes that form the cingulum on canines and lingual cusps on premolars. Mandibular first premolar develop from four lobes. Mandibular second premolar develop from five lobes, three buccal and two lingual. The mandibular first molar develops from five lobes—three buccal and two lingual (Fig. 4.13). Only some maxillary third molars develop from as few as three lobes. Some anomalies, for example, the peg-shaped maxillary lateral incisors and supernumerary teeth develop because of less than three lobes. On the tooth surface, the fusion of lobes is evidenced by the developmental grooves.

JAYPEE BROTHERS

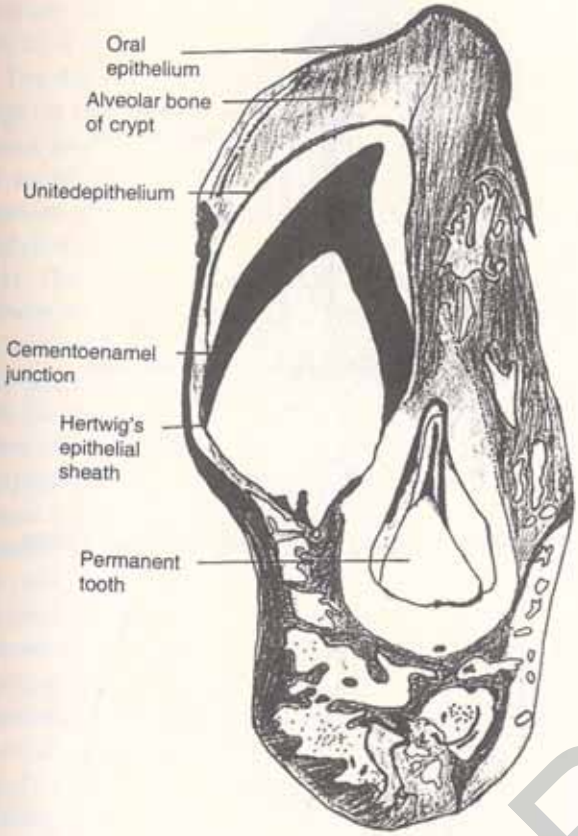

Fig. 4.9: Unerupted deciduous canine and its permanent successor located lingually and apically to it, in a section (Buccolingual) of mandible at the age of six months.

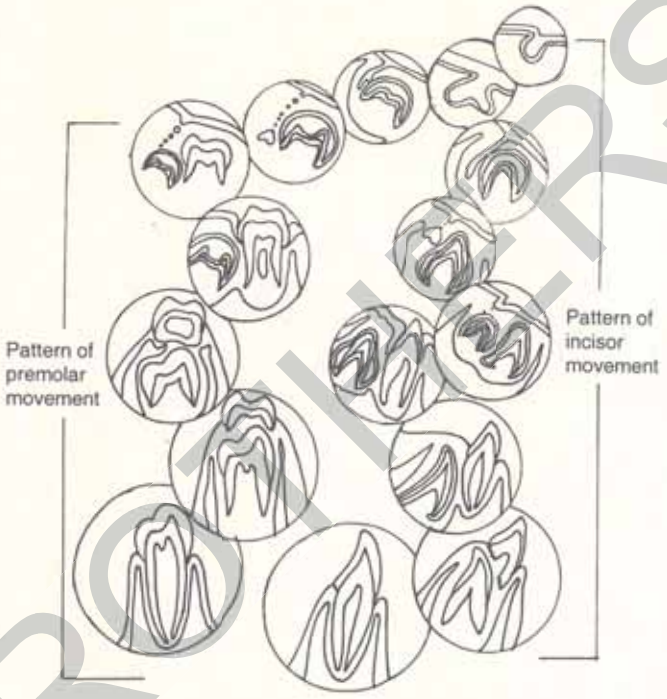

Fig. 4.11: Summary of physiologic tooth movements—pre-eruptive and eruptive, along with pattern of tooth resorption. The left stream shows pattern of premolar movement whereas the right stream shows pattern of incisor movement.

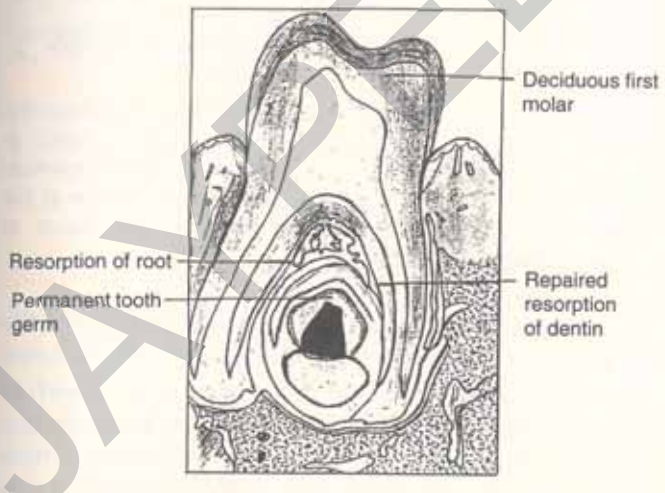

Fig. 4.10: Deciduous first molar showing germ of permanent first premolar between its roots at the age of about two years (seen after removing buccal plate of mandible).

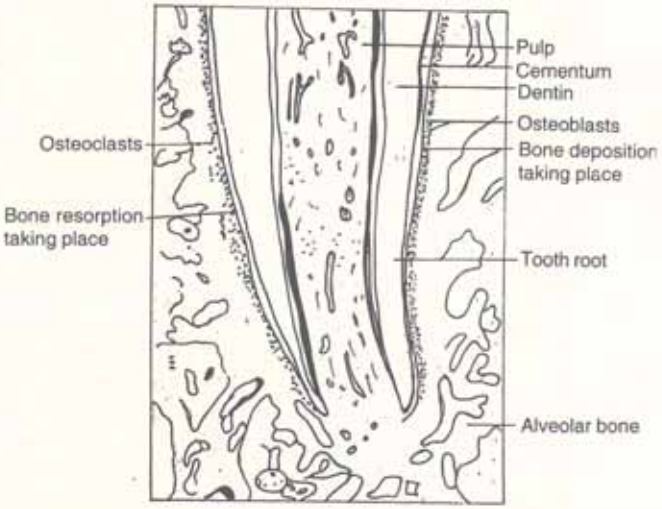

Fig. 4.12: Bone remodeling within the crypt wall during physiologic tooth movement. At right, osteoblasts are present for bone deposition and are seen as a continuous row of minute spots. At left, osteoclasts are present for bone resorption and are seen as dark dots.

JAYPEE BROTHERS

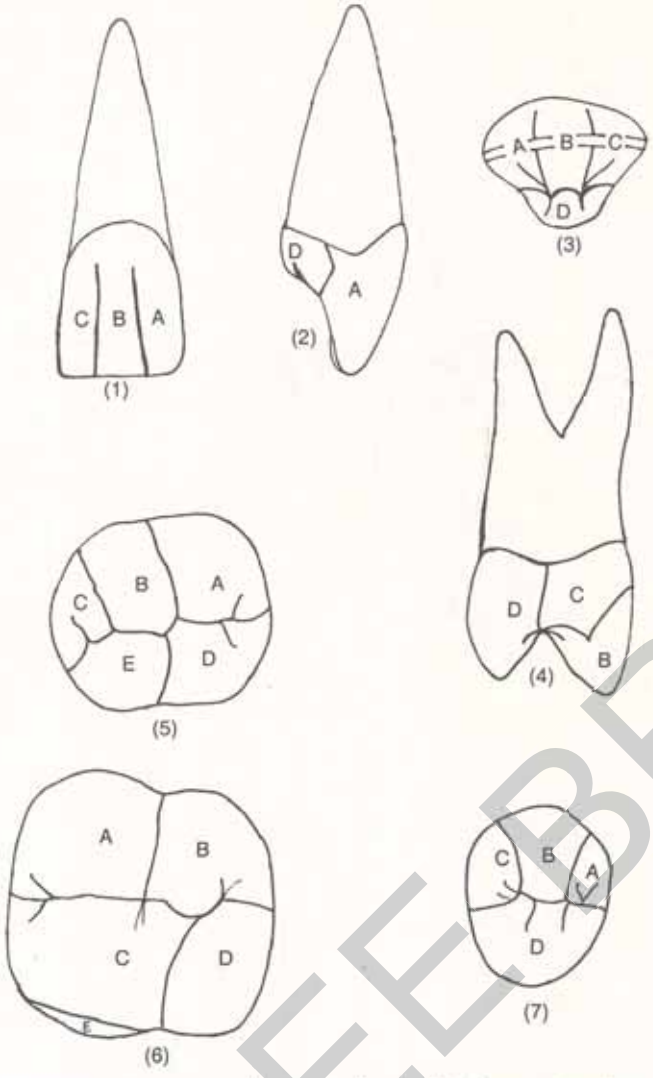

Fig. 4.13: Lobes or primary anatomic divisions on teeth are shown on different surfaces: (1) (2) (3) Maxillary central incisor, like all anterior teeth has four lobes (ABCD). The lingual lobe (D) is present beneath the cingulum and is seen in the mesial view (2) and in the incisal view (3). Mamelons, whenever present are an indication of the three labial lobes on incisors. (4) and (7) depicts the mesial and occlusal view of the maxillary first premolar respectively. The marginal ridge and developmental grooves indicate the divisions between the facial and lingual lobes.(5) Three buccal (ABC) and two lingual (CD) lobes are present on the mandibular first molar. (6) Three large lobes (ABC) and one small lobe (D) are seen on the maxillary first molar. Whenever the cusp of carabelli (E) is present, it is part of the large mesiolingual lobe. Major developmental grooves are present on posterior teeth, which separate these divisions.

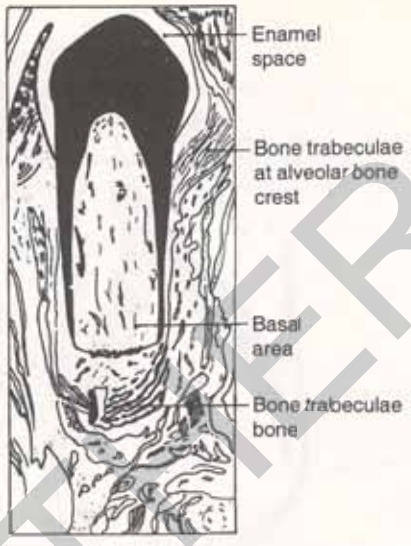

Fig. 4.14: Erupting mandibular deciduous canine.

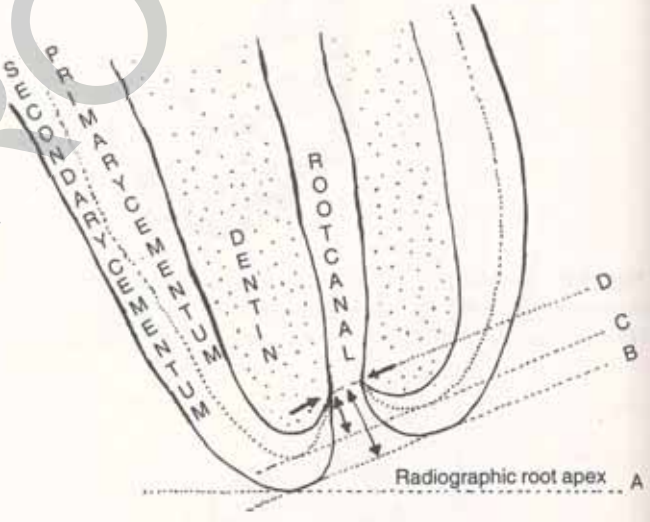

Fig. 4.15: Magnified view of root apex of mandibular central incisor at the age of 60 years. (A) The level at which in radiograph the root will appear. (B) Level of tip of cementum at the age of 60 years. (C) Level of tip of cementum at the age of 20 years. (D) Narrowest point of root canal at cementoenamel junction.

After the completion of the crown portion of the tooth, the root begins to form. Initially, cementum forms the covering of the root at the cervix of the crown in the form of a thin layer. The demarcating line between the crown and root is known as the cervical line, which forms the junction of enamel and cementum. It is a

JAYPEE BROTHERS

thin line depression and also called as cementoenamel junction because in most of the teeth, cementum of root and enamel of the crown meet at this place.

The development of the tooth occurs within a bony crypt in the jaw bone. After the completion of the crown and the formation of half of the root length, the tooth erupts into the oral cavity. Further development of the root is an active factor in pushing the tooth towards the final position in the oral cavity (Fig. 4.14). The cementum forms the outermost covering of the root. The root formation is half finished when the tooth emerges. Finally the root is completed. The eruption continues until it comes in proper occlusion with its antagonist in the opposing jaw. This is called active eruption. After this, eruption may continue to compensate for attrition and to accommodate itself to new conditions. In the root portion, the formation of cementum continues after the root is completed at the root apex and the tooth is in use. This is to compensate the attrition of teeth due to use. This cementum formation keeps the tooth in occlusion by pushing the tooth occlusally. This is called 'passive eruption'. Formation of root dentin and cementum continues after the tooth is in use. The blood and nerve supply to the tooth remain in the pulp cavity and the opening of the pulp cavity at the apex is constricted. The opening is called the apical foramen. The pulp keeps its tissue- forming function, in that it may form secondary dentin to protect itself. The secondary dentin produced in the pulp chamber is as a result of any stimulation like caries or excessive wear. The pulp cavity becomes smaller and constricted with age. Sometimes, the pulp chamber within the crown is completely obliterated and in rare instances the entire pulp cavity has been found filled with secondary deposit. With the formation of the apex of the root by cementum, the tooth is completely formed. However, this process continues very slowly throughout the life of the tooth.

In (Fig. 4.15) the cementodentinal junction at D is the narrowest of the root canal. Manipulation at this point meets with greatest resistance, like during condensation of root canal filling procedures. With continued cementum deposition apex increases (from C to B), similarly the distance of the radiographic apex (A) from the most constricted area (D).

The dental pulp is a connective-tissue organ containing a number of structures, among which are arteries, veins, nerves and a lymphatic system. The formation of dentin is the primary function of the pulp. In a newly erupted tooth the pulp space is large and it becomes smaller with age. The deciduous teeth and young permanent teeth have relatively larger pulp space. The teeth of children and young people are more sensitive to thermal changes and dental operative procedures than the teeth of older people.

BIBLIOGRAPHY

1. Kraus BS, Jordan RE: The Human Dentition before Birth. Philadelphia: Lea and Febiger, 107, 109, and 127, 1965.
2. Lysell L, Magnusson B, Thilander B: Time and order of eruption of the primary teeth. A longitudinal study. Odontol. Revy 13:217, 1962.
3. Woelfel and Scheid: Dental Anatomy—Its Relevance to Dentistry fifth edition 1999.

JAYPEE BROTHERS

Textbook of
Dental and Oral Anatomy, Physiology and Occlusion

With Multiple Choice Questions

REASONS TO PURCHASE THIS BOOK

- Excellent and comprehensive coverage.
- To make distinguishing the teeth, easy and simple, comparative tables have been given.
- Text spread over 22 chapters covering the latest syllabi of Dental Council of India and Indian and Foreign Universities.
- Text has been made very simple and easy to understand with sufficient number of labelled figures.
- Students, teachers and practitioners all will find this book very useful.
- Authored by very renowned experienced teachers, researchers and clinicians.
- Very useful for competitive examinations as it contains 250 MCQs covering all the relevant topics.
- Attractively low priced.

81-8061-230-9

JAYPEE BROTHERS
MEDICAL PUBLISHERS (P) LTD.
www.jaypeebrothers.com