# Implantology Made Easy

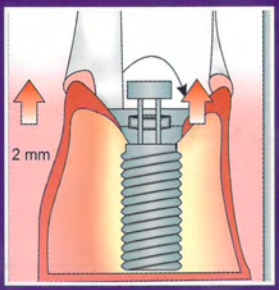








TP Chaturvedi

JAYPEE



# Contents


1. Introduction, History and Uses of Implants ..... 1
2. Types of Implants ..... 9
3. Implant Osseointegration ..... 29
4. Implant Biomaterials ..... 37
5. Case Selection ..... 57
6. Implant Placement in Patients having Systemic Disorders ..... 67
7. Examination and Treatment Planning ..... 83
8. Surgery ..... 105
9. Prosthodontic Procedure: Single Tooth Implant ..... 133
10. Prosthodontic Procedure: Partial Replacement Case ..... 149
11. Prosthodontic Procedure: Edentulous Case ..... 161
12. Implant Placement in Advanced Cases and Other Applications ..... 175
13. Implants Longevity ..... 197
14. Occlusal Consideration for Implant Supported Prosthesis ..... 207
15. Orthodontic Microimplant ..... 219
16. Complications of Dental Implants ..... 233


JAYPEE BROTHERS

**17. Maintenance of Dental Implants ..... *243***

**18. The Future ..... *251***

**19. Literature Revisited ..... *257***

***Implants Glossary* ..... *289***

***Bibliography* ..... *293***

*Index* ..... *321*

JAYPEE BROTHERS

CHAPTER

11

# Prosthodontic Procedure: Edentulous Case

JAYPEE BROTHERS

Restoration of one or both edentulous jaws with prosthesis stabilized by dental implants is appropriate in two situations.

- First and more commonly, when a conventional complete denture is found to be unsuccessful.
- Second situation, is the desirability of promoting the retention of alveolar bone and avoiding resorption and future atrophy of edentulous jaw.

In the restoration of complete dental arch by means of implants, two options are available to the practitioner, namely:

1. Fixed-implant retained prosthesis.
2. Implant-supported overdenture.

## FIXED-IMPLANT RETAINED PROSTHESIS

Followings factors are determining factor to decide complete implant-stabilized fixed prosthesis(es) as influencing factors;

- Number of implants: Adequate quality/volume of bone for minimum 5-6 implants in the maxilla and 4 implants in the mandible
- Total retention and stability of prosthesis
- Reduced volume/mucosal coverage improving tolerance
- Optimal masticatory function
- Where resorption has created inadequate height and width to the jaw, autogenous grafting may be used in the form of an inlay or onlay
- Cantilevering limits occlusal table
- Risks destabilizing an opposing complete denture,
- More difficult to clean and achieve good oral hygiene.

JAYPEE BROTHERS

- Presence of periodontally compromised natural teeth may compromise implant support
- Initials casts greater than overdenture.

A fixed prosthesis may be choosen to oppose an intact or partially dentate arch of natural teeth. If entire length of the occlusion is to be restored either sufficient bone must exist above the maxillary antrum or inferior dental canal to accommodate implants at least 6-7 mm length and 5-6 mm diameter. If not, then an auxillary surgical procedure must be considered, e.g. a maxillary sinus lift, in order to create an increased volume of bone. A fixed mandibular prosthesis occupying a reduced prosthetic space may be provided to oppose a complete maxillary denture, if upper foundation offers good support and retention. As for occlusion is concerned, loads should be spread widely, avoiding local high concentration. Optimizes the number and position of implants with heavy loads, provide biteguards for night wear. Canine guidance should be avoided. Modified acrylic resin material for artificial teeth or composite veneering most commonly used (porcelain teeth may be used for overdentures).

## IMPLANT-SUPPORTED OVERDENTURE

This procedure is mainly determined by the number of implants present and need for flange. Following are influencing factors (Figs 11.1A and B):

- Number of Implants for overdenture in maxilla-4 implants and mandible-2 implants
- Enhanced stability and retention by anchorage from implants in a resorbed jaw

JAYPEE BROTHERS




**Figs 11.1A and B:** (A) OPG view of implant supported denture (B) Artificial denture on implants

- Improved resistance permitting improved tooth positions in the dental arch
- Facial support provided by denture flange
- Occlusal table may oppose an intact natural arch
- Complete denture occlusion favors stability of an opposing denture having limited support from the jaw
- Easy cleaning for oral hygiene
- Higher maintenance requirements.

Completed dentures may be successfully stabilized by a limited number of implants sited in the edentulous jaw. A sufficient volume of bone for implantation is usually present in the canine eminence and anterior to antrum in the maxilla and canine/first premolar area of mandible (although the central incisor site may also be available). Generally, standard implants of approximately 4 mm diameter and at least 10 mm length are considered adequate to sustain load in the maxilla, whereas even 7 mm is a sufficient length to engage the more dense basal bone of the anterior mandible. The longer the implant, the better

JAYPEE BROTHERS

are the prospects for osseointegration and the reaction to loading. Essential features for planning an implant-supported complete denture are to be maintained. Occlusion relation against natural arch should to avoid canine guidance, and against complete denture should be balanced occlusion.

*Prosthodontic stages for a full arch restoration is as follows:*

- Primary impression for special tray
- Secondary impression with an open-tray technique and impression copings
- Verification of the cast if multiple implants are used
- Jaw registration, which is most likely to require an occlusal rim
- Wax try-in
- Metal try-in for framework
- Wax and metal try-in or metal/porcelain try-in
- Finish.

With a complete arch restoration much of the planning of tooth position equates to the standard prosthetic techniques for complete dentures. Assessment of the occlusal vertical dimension, occlusal plane, tooth position, centerline, smile line and retruded contact position (RCP) are all important to the success of the case.

## Abutment Selection for Complete Fixed-Implant Prosthesis

*Premachined*

**Standard abutments:**

- Appropriate for oil rig design, typically in mandible

JAYPEE BROTHERS

- Aesthetics not significant
- Minimum of 4 mm spacing between each one
- Easy to clean.

**Wide platform abutments:**

- Meet criteria for standard abutments
- Enhance loading potential in molar areas of jaws.

**Multi-unit abutments:**

- Alternative to standard abutment
- Appropriate for optimal emergence profile from good ridges forms, e.g. maxilla.
- Facilitate sitting of cylinder component in the 'prosthetic envelope'.

**Angulated abutment:**

- Necessary where long axis of implant body and tooth crown are divergent, e.g. Class II div 2 incisor pattern
- Compensate for differences in implant/posterior arch alignment
- Avoid perforating buccal/labial tooth face with a channel for access to the prosthesis screw.

*Customized*

Individually fabricated by casting onto a gold alloy abutment post, milling a precision abutment (clinic/laboratory)/CAD/CAM produced by scanning, milling/spark erosion of a titanium block.

- Optimize emergence profile of the unit
- Optimize superstructure form in relation to the restored arch.

JAYPEE BROTHERS

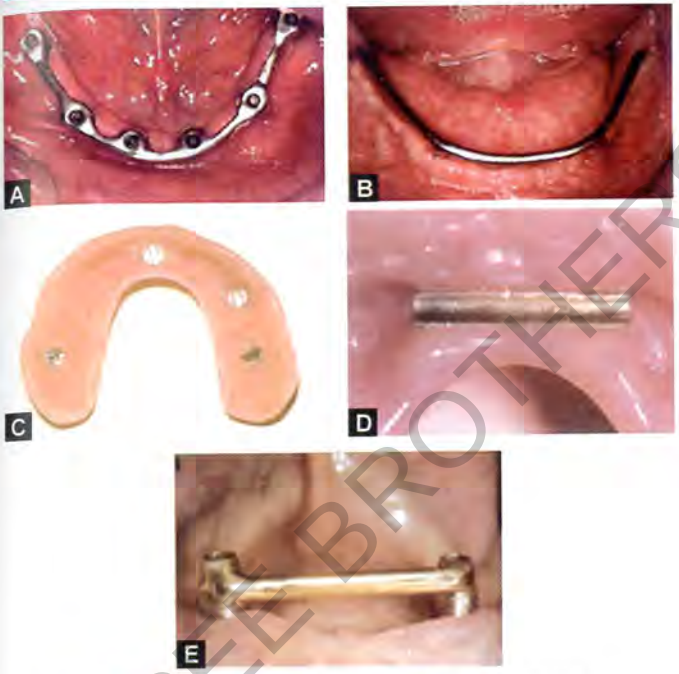


**Figs 11.2A to E:** Different attachment of overdenture

*Overdenture* can be retained in the following ways (Figs 11.2A to E):

- Bar and clip
- Ball attachment
- Magnets.

Tissue bar constructed for removable prosthesis, sometimes attachment can be placed distal to last attachment.

A bar and clip design is the most popular, as it gives the patient confidence with minimal maintenance. Ball attachments are simple and

JAYPEE BROTHERS

allow the patient to clean effectively. It is suggested that the ball abutments be used in the mandible and not in the maxilla. Magnets have certain advantages, but are less commonly used, as they are bulky in design and may corrode in clinical service (Figs 11.3A to H - Case report).







JAYPEE BROTHERS










JAYPEE BROTHERS







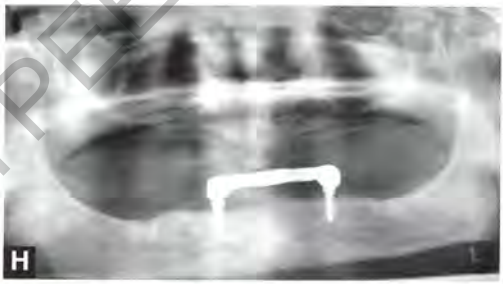


JAYPEE BROTHERS

**Figs 11.3A to H:** (A) Pre-implantation extraoral view (B) Pre-implantation intraoral view showing atrophic mandibular ridge (C) Implant placed in premental region (D) Cast metal bar placed over implants (E) Mandibular denture maximally extended to reduce stresses over implants (F) Patient wearing implant supported overdenture (G) Pre-implantation panaromic radiograph (H) Post-implantation panaromic radiograph

In case of overdenture, abutment is attached to the denture base by certain attachments. In ball and ring type of attachment ball like head of the implant is protruded in the oral cavity (male part) and inserted into a socket housing on the tissue surface of denture, called "o" ring (female part). In a bar attachment bar is fabricated on 2 or 4 implants inserted in the jaw and a clip is housed in the tissue surface of the denture, which fits on this bar which ultimately improves retention and stability of the denture.

## LABORATORY CONSIDERATIONS

The clinician's responsibility is to provide work of the highest possible quality. This should be mirrored in the dental laboratory with accurate and skilled manipulation of materials. Communications and good relationship between clinicians and dental technicians reduce the chance of errors. Ultimately, the responsibility for the finished prosthesis lies with the clinicians.

Laboratory stages will be familiar to most readers as:

- Production of working cast
- Selection of component and design
- Wax-up to full contour
- Casting of metal superstructure
- Veneering with porcelain, acrylic or composite.

Dental materials are constantly evolving to enhance clinical performance and appearance. All porcelain restorations have been introduced for single tooth restorations. A strengthened core is cast or milled to fit the fixture head or implant abutment.

JAYPEE BROTHERS

Surface abutment is then fired to produce the desired contour and shade.

## CAD/CAM

Computer aided design/computer aided manufacture (CAD/CAM) has recently been developed for use in implantology. Various procedures have been employed utilizing laser scanning, sparked erosion and milling techniques. In this way a single abutment or frameworks can be produced.

## SUMMARY (PARTIAL AND COMPLETE PROSTHESIS)

Healing period of 4-6 months is allowed before loading the implant with final restoration. Progressive loading should be given by initial placement of transitional prosthesis of acrylic material, with no occlusal contact. After rigid fixation of the implant the acrylic transitional prosthesis should be given occlusal contact. Subsequently, it mut be followed by permanent restoration.

The permanent restorations can be made of:

a. Gold/Gold alloys
b. Metal ceramic crown
c. Ni-Cr alloys

Resinous occlusal surfaces are preferred to prevent traumatic shock-type forces from affecting the health and longevity of the osseointegrated interface.

In complete edentulous patient, initially provisional denture should be provided which had been relieved in the regions of the implants for 3 months. Implants loaded, placing resilient material between the implant and the denture. Patient should be recalled for follow-up:

JAYPEE BROTHERS

- Ideal surgical implant placement allows the use of standard components and impression procedures
- Fixture level impressions and use of custom abutments, as is standard practice with some implant systems allow restoration of difficult cases
- Cemented implant crowns and superstructures give the best appearance occlusally, whereas screw retained prosthesis allow easier maintenance
- Temporary prostheses give the clinicians and the patient the opportunity to assess the appearance and function prior to completing the laboratory prescription.

JAYPEE BROTHERS

# Implantology Made Easy

Dental implants are fastest growing method of treatment of dentistry today. The implant system currently available are diverse. Implant manufacturers have developed individualized designs for their implants, and they are continually altering marketing strategies to highlight the feature of each implant. They themselves describe from case selection to completion of implant placement and prosthetic treatment procedures.

Objective of present book is to give some basic information related to implants right from its inception to use in dentistry in proper way. The author has tried to incorporate basic relevant and important features of implants applicable to every system of implant placement. Whole book is divided into 19 chapters and glossary as well as references. The book is well planned to give proper information right from material sciences related to implant to final treatment with implants and prosthesis. In recent years orthodontic microimplant is also very commonly used in orthodontics, book also contains one special chapter on it. In whole book colour diagrams are given in proper way to understand implants in better ways. Recent advancement of implant beyond dental use is described in brief. The author has tried to give one special chapter 'Literature Revisited' to give an insight into development that is taking place in implantology from early time to till date.

After completion of graduation and postgraduation in dentistry, **TP Chaturvedi** is doing PhD in Dental material sciences and especially doing research in implants materials as well as other dental materials. He is fully involved in implants subjects with postgraduate students in the faculty of Dental Sciences, Institute of Medical Sciences, BHU, Varanasi.

**Available at all medical book stores**
**or buy directly from Jaypee Brothers through online shopping at www.jaypeebrothers.com**

**or call + 91-11-32558559**

**JAYPEE BROTHERS**
**Medical Publishers (P) Ltd.**
**www.jaypeebrothers.com**

ISBN 81-8448-160-8

9 788184 481600