Volume 3

Kadasne's Textbook of ANATOMY

(Clinically Oriented)
Head, Neck, Face & Brain

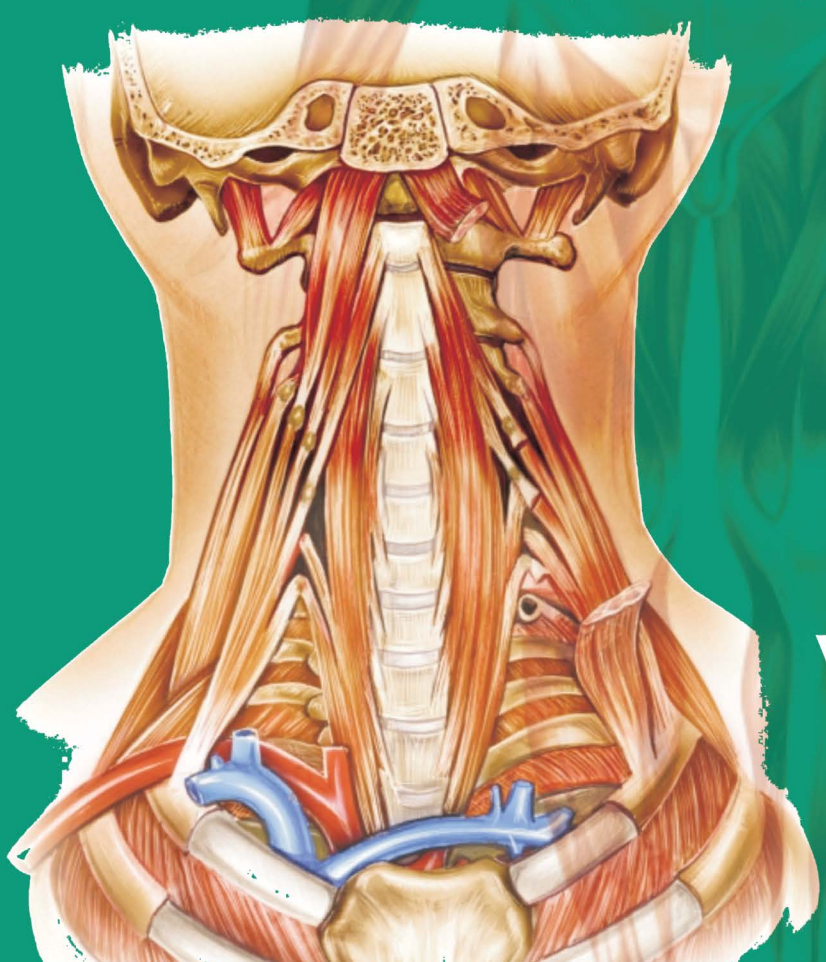

DK Kadasne

Foreword
Vedprakash Mishra

JAYPEE

CONTENTS

Osteology of Head, Neck and the Face 723
Pterygopalatine Fossa 730
Cervical Vertebrae 736
Mandible 739
Maxilla 741
Cranial Cavity 744
Posterior Cranial Fossa 748
Cervical Fascia 755
Cervical Plexus 761
Posterior Triangle 765
Sternomastoid Muscle 774
Front of the Neck 777
Anterior Triangles of the Neck 782
Carotid Triangle 783
Scalenus Anterior Muscle 792
Median Region of the Front of the Neck 794
Scalp and Temple 796
Muscles of the Face 805
Back of the Neck and Head 808
Branches of Occipital Artery 812
Ligamentum Nuchae 813
Suboccipital Triangle 814
Suboccipital Muscles 816
Deeper Consideration of the Face 817
Parotid Region 823
Temporal and Infratemporal Regions 830
Temporomandibular Joint 839
Mandibular Nerve 843
Maxillary Nerve 846
Eyelids, Lacrimal Apparatus and External Nose 855
Lacrimal Apparatus 857
Cranial Cavity 860
Orbit 879
Eyeball 892
Deep Part of the Neck 899
Thoracic Duct 913
Common Carotid Artery 915
Internal Jugular Vein 917
External Carotid Artery 921
Cranial Nerve 924
Hypoglossal Nerve 929
Sympathetic Trunk 931
Phrenic Nerve 934

JAYPEE BROTHERS

Prevertebral Region 936
Joints of Neck 937
Mouth 939
The Tongue 941
Pharynx 947
Tonsil 954
Palate 956
Larynx 959
External Nose 969
Nasal Cavity 973
Nasal Septum 976
Pterygopalatine Ganglion 979
External Ear 980
Middle Ear 985
Auditory Tube 991
Internal Ear 993
Facial Nerve 996
Nuclei of Some of the Cranial Nerves 1002
Structure and Development of Tooth 1003
Nuclear Components of Cranial Nerves 1007
Brain 1009
Medulla 1012
Internal Structure of the Medulla 1013
Pons 1016
Midbrain 1017
Cerebellum 1022
Superolateral Surface of the Cerebral Hemisphere 1025
Inferior Surface of the Cerebral Hemisphere 1028
Medial Surface of the Cerebral Hemisphere 1030
Thalamus 1032
Hypothalamus 1035
Subthalamus 1036
Metathalamus 1037
Epithalamus 1038
Third Ventricle 1039
Fourth Ventricle 1041
Lateral Ventricles of the Cerebral Hemispheres 1043
Limbic System 1046
Basal Ganglia 1048
Olfactory Nerve 1050
Blood Supply of Brain 1053
Venous Drainage of the Brain 1057
Reticular Formation 1059
White Matter of the Cerebrum 1061
Surface Marking of Head, Neck and Face 1067
Clinical Pictures 1069
Multiple Choice Questions *1075*
Index ..... *i-v*

JAYPEE BROTHERS

OSTEOLOGY OF HEAD, NECK AND THE FACE

Norma Frontalis (Figure 1):

Forehead is formed by the frontal bone. Frontal eminences are placed above the orbital openings. Orbital openings are quadrilateral on either side of the external nasal apurture. Below and between the orbital openings is the anterior nasal aperture. It is piriform in shape and presents an anterior nasal spine lower down where maxillae meet. Nasal opening is bounded by the maxillae and nasal bones. Nasal bones join the frontal bone above and meet the nasal bone of the opposite side. Meeting of the frontal and nasal bones is known as the nasion. Above the nasion is the smooth raised area known as the glabella. Running on either sides of glabella are the superciliary arches. They are situated above the medial part of the superior margin of orbital opening. Above and lateral to the super cilliary arches are the frontal eminences.

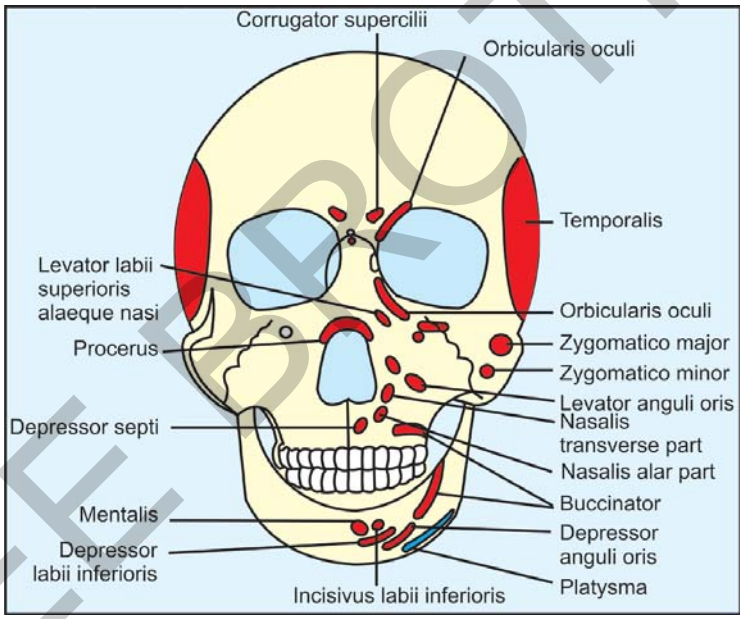

Figure 1 Showing norma frontalis

Zygomatic arch is formed by the zygomatic process of the temporal bone and the temporal process of the zygomatic bone. Frontozygomatic suture is at the lateral border of the orbit. It can be palpated with a finger. It is an important landmark for surface marking of the middle meningeal artery. Superior margin of the orbital opening presents a notch or a foramen at the junction of its lateral 2/3rd and the medial 1/3rd. It is known as the supraorbital notch or foramen. Supraorbital vessels and the nerves pass through it. Lateral border of the opening of orbit is formed by the zygomatic bone below and the zygomatic process of the frontal bone above. Inferior border of the orbital opening is formed by the maxilla medially and zygomatic bone laterally. Infraorbital opening is placed half a centimeter below the lower margin of the orbit. It gives passage to the infraorbital vessels and the nerves. Medial margin is formed by lacrimal crest of the maxilla and the lacrimal bone. Nasal bones form the upper limit of the nasal aperture. They are notched or may present small foramina at the lower margins, is for the external nasal nerve. Please remember that the tip of nose is supplied by the external nasal nerve and

JAYPEE BROTHERS

when pressed it feels firm. Alveolar margin contains sockets for the eight teeth on the each half.

Incisive fossa lies above the incisors. Canine eminence lies over the canine while the canine fossa is lateral and the incisive medial to the canine eminence (Figures 2 and 3).

Figure 2
Showing detail of canine eminence

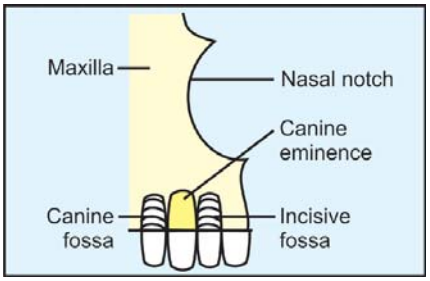

Figure 3
Showing landmarks in front of the symphysis menti

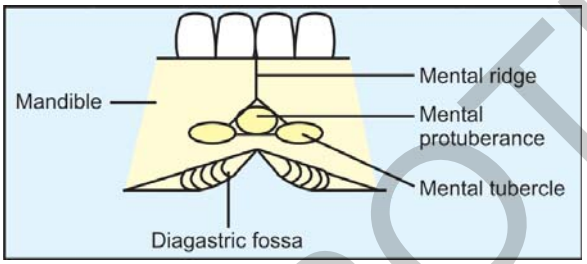

Muscles of the face arise from the bones and are inserted into the skin. They are not covered by the deep fascia thus making them more expressive for the sake of facial expressions.

Medial aspects of the supercilliary arch gives origin to the corrugator supercilliary muscle. Nasal process of the frontal bone and the frontal process of the maxilla give origin to the orbital part of orbicularis oculi. Between these two, the medial palpable ligament is attached to the frontal process of the maxilla.

Procerus muscle is attached to the nasal bones in the midline. Lavator labii superioris arises from the maxilla between the inferior margin of orbit and infraorbital foramen. Zygomaticus major and the minor arise from the body of the zygomatic bone, major being lateral.

Norma Verticalis (Figure 4):

It is ovoid in shape and its maximum width is near the occipital pole. It presents frontal bone anteriorly separated from the two parietal bones by the coronal suture. Parietal bones articulate in the midline through the sagittal suture. Occipital bone articulates with the parietal bones through lambdoidal suture. Meeting point of the coronal and sagittal suture is known as bregma. At birth it is occupied by a diamond shaped fibrous membrane. It is known as anterior fontanellae. It closes at the age of one and half year. Lambda is situated at the meeting point of the sagittal and the lambdoidal sutures. It is occupied by a triangular fibrous membrane known as the posterior fontanellae. Parietal eminences are placed postero-laterally. Emissary parietal foramen is situated by the side of the sagittal suture 3.5 cm in front of the lambda. It gives passage to the emissary vein which drains into the superior sagittal sinus.

Norma Lateralis (Figures 5 and 6):

It is formed by nine bones, namely the frontal, parietal, occipital, zygomatic, sphenoidal, temporal, nasal, maxilla and the mandible. Out of these frontal, sphenoidal, occipital and the maxilla are single bones placed near the midline. Prominently this view presents zygomatic arch, external acoustic

JAYPEE BROTHERS

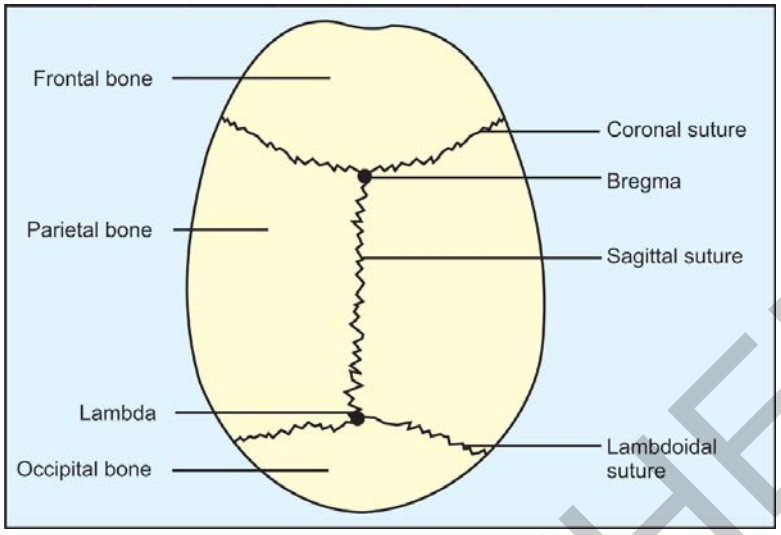

Figure 4
Showing norma verticalis

meatus and the mastoid process. Above the zygomatic arch lies the temporal fossa. It is bounded by the superior and the inferior temporal lines above, the frontal crest anteriorly and the supramastoid crest posteriorly.

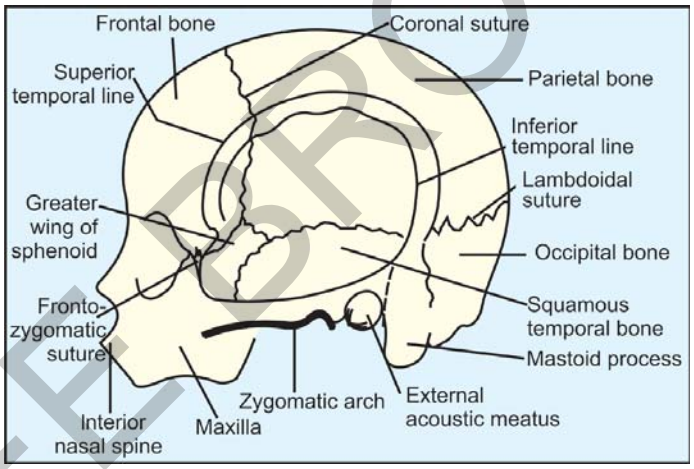

Figure 5
Showing bones taking part in norma lateralis

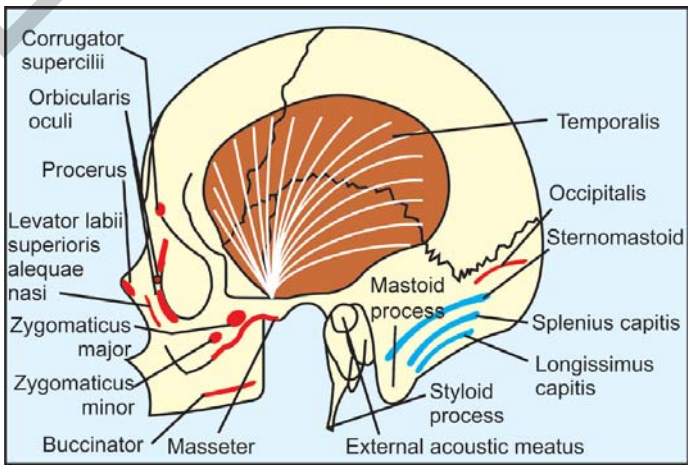

Figure 6
Showing norma lateralis

JAYPEE BROTHERS

The Floor of the Superficial Temporal Fossa (Figure 7):

The floor of the superficial temporal fossa is formed by the four bones namely, the frontal, parietal, greater wing of sphenoid and the squamous part of the temporal. They are united by the H shaped suture located at the anteroinferior angle of the parietal bone. Meeting point of the four bones is marked by circular area. It is known as the pterion. It is an important surface landmark for the surface marking of the anterior division of the middle meningeal artery. It is marked at a point 4 cm above the zygomatic arch and 3.5 cm behind the frontozygomatic suture. It marks the axial position of the stem of lateral sulcus (Sylvian sulcus). It is also called as the Sylvian Point.

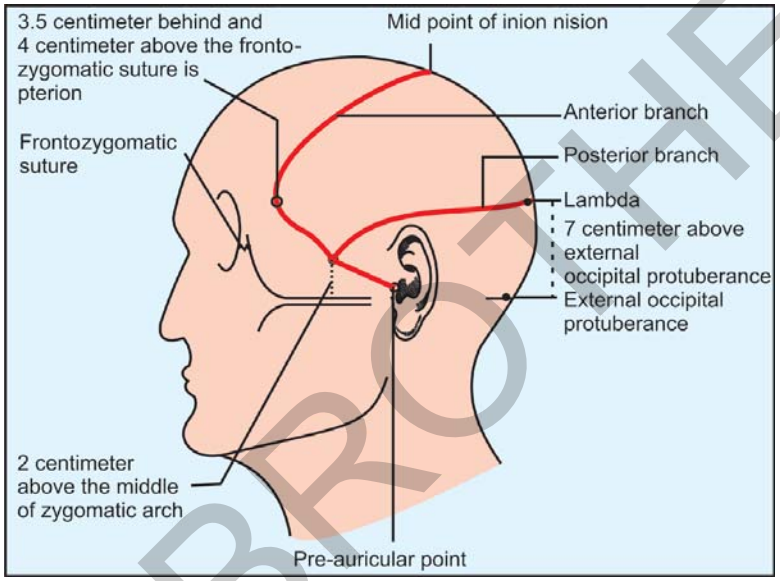

Figure 7
Showing surface marking of middle meningeal artery

Temporal surface of the zygomatic bone, part of the greater wing of the sphenoid, part of the frontal bone form the anterior limit of the temporal fossa. All these structures separate the temporal fossa from the orbit. Anterior part presents zygomatico-temporal foramen which transmits zygomatic nerve. Temporal fossa communicates with infratemporal fossa through the gap between the zygomatic arch and the lateral wall of the cranium. The tendon of temporalis, deep temporal vessels and nerves pass through it. The tendon of temporalis comes down, while the deep temporal vessels and nerves go up. Zygomatic arch can be palpated between the cheek and the temple. It is formed by the temporal process of the zygomatic bone and the zygomatic process of the temporal. The suture between the two is obliquely placed (zygomatico-temporal suture). Upper border of the zygomatic arch gives attachment for the superficial layer of the temporal fascia. Its medial surface and the lower border give origin to the masseter muscle. Deep layer of the temporal fascia merges with the fascia on the medial aspect of the masseter. Zygomatic process of temporal bone divides into two roots posteriorly near the temporal bone. Anterior root turns medially to form the tubercle of the root of the zygoma and the anterior boundary of the mandibular fossa as an articular eminence. Posterior root runs posteriorly, lateral to the mandibular fossa and joins the supramastoid crest (Figure 8).

Postglenoid tubercle is the part of the posterior root of the zygoma. It lies behind the mandibular fossa (Figure 8).

JAYPEE BROTHERS

External Acoustic Meatus (Figure 8): External Acoustic Meatus lies posteroinferior to the posterior root of the zygomatic arch. Posterosuperior margin of the meatus is formed by the squamous part of the temporal bone and the anteroinferior margin is formed by the tympanic plate.

Anterosuperiorly is the squamotympanic suture and posteriorly is the tympanomastoid suture, which presents canaliculus for the auricular branch of the vagus. (Nerve of Arnold).

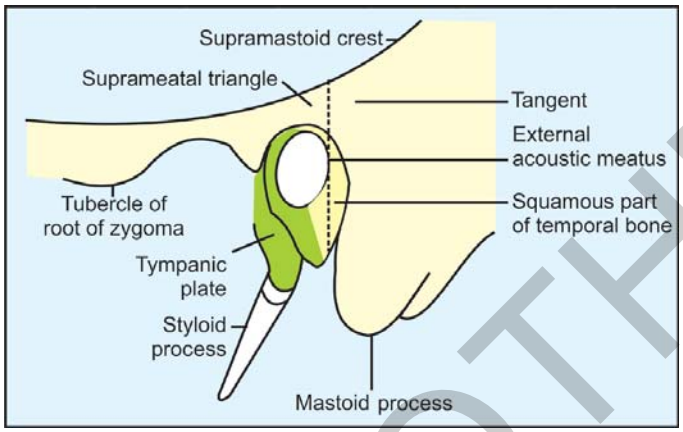

Figure 8 Showing external acoustic meatus with supra meatus triangle tympanic plate and styloid process

Suprameatal Triangle (Figure 8): It is situated posterosuperior to the external acoustic meatus. It is bounded above by the supramastoid crest, anteriorly the margin of the external acoustic meatus and posteriorly by the tangent drawn from the posterior margin of the meatus. It may present a spine known as suprameatal spine. Suprameatal triangle is known as the MacEwen triangle. It is the surface landmark for the tympanic antrum (Mastoid Antrum).

Mastoid Process: It is the bony projection situated behind the external acoustic meatus. It can be palpated under the lobule of the ear. It has two sutures namely, i.e.

1. Parietomastoid
2. Occipitomastoid.

Parietomastoid suture is situated at the posteroinferior parietal angle and the occipitomastoid suture in between the posterior border of the mastoid and the occipital bone. These two sutures meet the lambdoidal suture, at the point known as asterion.

Mastoid foramen is situated near the posterior border of the mastoid process. It transmits emissary vein from the sigmoid sinus and the small dural branch of the occipital artery. Asterion is the site for the postero-lateral fontanelle. Mastoid process develops in the second year of life. At birth absence of mastoid process leaves the facial nerves unprotected. Although the mastoid process develops in the second year of life, the mastoid air cells develop at the age of six years. At times mastoid process has no air cells and is called the acellular mastoid.

Styloid Process: Styloid process like a thick pointed needle attached to the base of the skull. It runs downwards forwards and medially. Its tip goes upto the posterior border of the ramus of mandible. Its length varies from few mm to few centimeters (about 2.5 cm). It is attached to the lesser cornu of the hyoid bone by the stylohyoid ligament. Stylomastoid foramen lies posterior to its base. Tympanic plate forms the sheath around the base of the styloid process.

StyAlgia (Eagles Syndrome): Long styloid reaching tonsillar fossa can cause pain in the tonsillar region which increases during swallowing. The pain is referred to the neck and

JAYPEE BROTHERS

the ear of the same side. The process can be palpated transorally at the site of the tonsillar fossa with the finger. The long styloid process can be seen in a radiograph. Ossified stylohyoid ligament may be seen in few cases.

Infratemporal Fossa (Figures 9A and B): Infratemporal fossa is situated below the level of the zygomatic arch under the skull. It communicates with the temporal fossa through the gap between the zygomatic arch and the infratemporal crest of the greater wing of sphenoid.

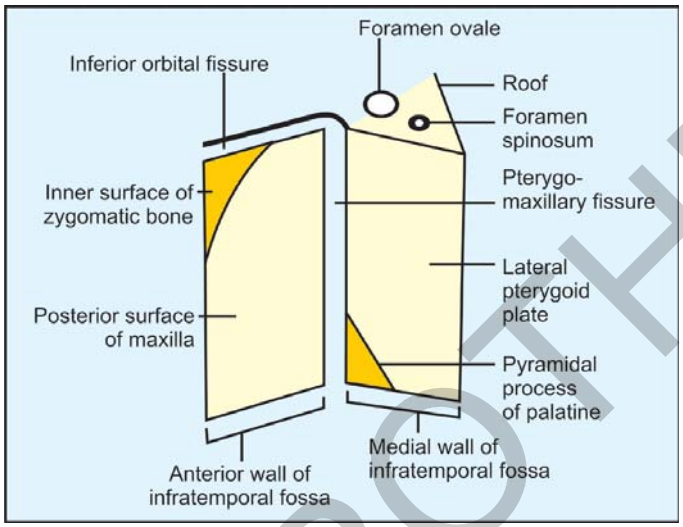

Figure 9A Showing anterior and medial walls of the infratemporal fossa. Note: foramen ovale spinosum in the roof

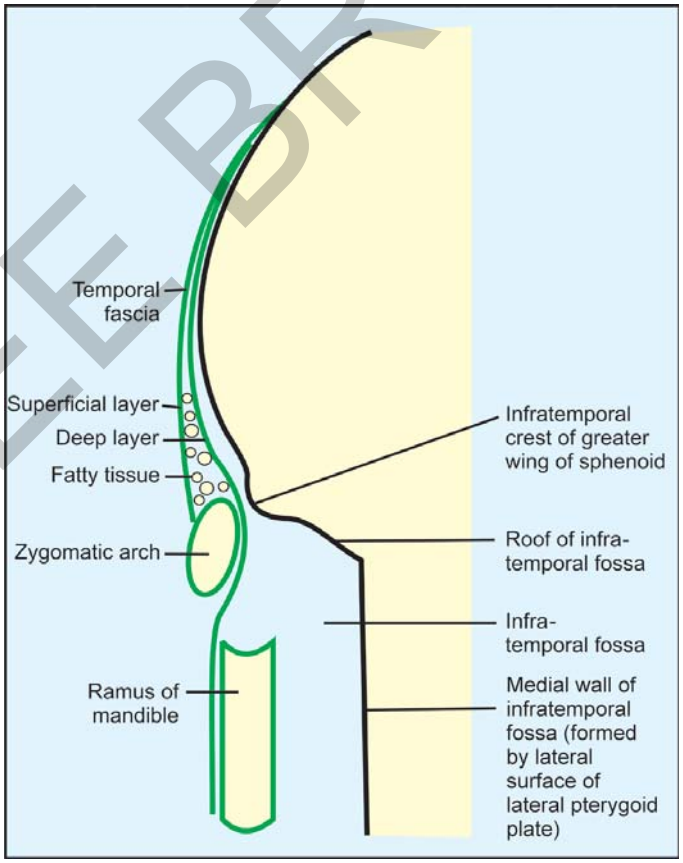

Figure 9B Showing temporal fascia and the infra-temporal fossa

Medial Wall: It is formed by the lateral pterygoid plate and the pyramidal process of palatine.

JAYPEE BROTHERS

Roof : Roof is formed by the infratemporal surface of the greater wing of sphenoid and partly by the squamous part of the temporal bone. It presents two foramina: (1) foramen ovale and (2) foramen spinosum.

Foramen ovale transmits the mandibular, lesser superficial petrosal nerves, accessory meningeal artery (MLA). Foramen spinosum gives passage to the middle meningeal artery and the nervous spinosus.

Anterior Wall: Anterior wall is formed by the posterior surface of the maxilla and the medial surface of the zygomatic bone.

Lateral Wall: Lateral wall is formed by the ramus of the mandible.

Infratemporal fossa has no floor and is without the posterior wall:

Communications: It communicates with the pterygopalatine fossa through the pterygomaxillary fissure which lies between its medial and the anterior walls of the infratemporal fossa. It also communicates with the orbit through the infraorbital fissure which lies between the roof and the anterior wall of the fossa.

Pterygomaxillary Fissure: It lies betwen the lateral pterygoid plate and the maxilla (Figure 9A). Maxillary artery enters the pterygopalatine fossa through the pterygomaxillary fissure.

JAYPEE BROTHERS

Kadasne's Textbook of
ANATOMY
(Clinically Oriented)
Head, Neck, Face & Brain

DK Kadasne was born on 22nd April 1932 at Wani in district of Yeotmal, Maharashtra, India. He obtained his MBBS and MS degrees in Anatomy from the Government Medical College, Nagpur. During his pre-clinical days he was a merit scholar. He worked in Government Medical College, Nagpur as Lecturer and Reader of Anatomy. His crowded lecture hall is the proof of his able and excellent teachership. In the United Kingdom he worked under Professor GJ Romanes in Medical School at Edinburgh.

He did his FRCS in general surgery from the Royal College of Surgeons at Edinburgh in 1968. He is also a Fellow of the International College of Surgeons of the USA (FICS). He was appointed as Professor designate of Anatomy in the BJ Medical College, Pune; however, he preferred to join as Civil Surgeon and had his successful tenure in four districts of Maharashtra including Nagpur.

In the Mayo General Hospital and Indira Gandhi Medical College, Nagpur he was in-charge of a surgical unit and was a guide for MS (Surgery) under Nagpur University. After retirement, he joined Pandit Jawaharlal Nehru Medical College at Sawangi, Wardha and worked as a visiting professor of anatomy for the period of ten years. Recently, he has been conferred the title of Emeritus Professor of Anatomy at Datta Meghe Institute of Medical Sciences, Sawangi, Wardha (a Deemed University). He is a qualified anatomist and practising surgeon which is in itself a rare combination for authorship of the book on anatomy with clinical applications.

Available at all medical book stores
or buy directly from Jaypee Brothers through online shopping
at www.jaypeebrothers.com

or call + 91-11-32558559

JAYPEE BROTHERS
Medical Publishers (P) Ltd.
www.jaypeebrothers.com

ISBN 81-8448-457-7
9 788184 484571