Essentials of Pediatric Dentistry



Kanchan Harikishan Asnani

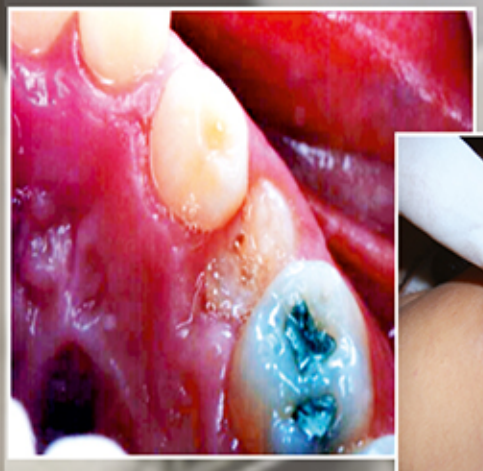







JAYPEE

Contents

PART-1

FUNDAMENTALS OF PEDIATRIC DENTISTRY

1. The Practical Importance of Pediatric Dentistry 3
2. Pain Reaction Control : Sedation 15
3. Antimicrobials in Pediatric Dentistry 19
4. Dental Public Health Issues in Pediatric Dentistry 22

PART-2

PRIMARY DENTITION YEARS: THREE TO SIX YEARS

5. General Topics to be Considered 27
6. Child Psychology 38
7. Examination, Diagnosis and Treatment Planning 48
8. Prevention of Dental Diseases 53
9. Restorative Dentistry for the Primary Dentition 65
10. Pulp Therapy for the Primary Dentition. 88
11. Periodontal Problems in Children and Adolescents 101
12. Space Maintenance in the Primary Dentition 111

13. Oral Habits 125
14. Local Anesthesia and Oral Surgery in Children 138

PART-3

TRANSITIONAL YEARS : SIX TO TWELVE YEARS

15. Pit and Fissure Sealants and Conservative Adhesive Restoration 149
16. Managing Traumatic Injuries in the Young Permanent Dentition 156
17. Treatment Planning and Management of Orthodontic Problems 170
18. Behavior Management 192
19. Care of Special Child (Handicapped Child) 202

PART-4

ADOLESCENCE

20. Aesthetic Restorative Dentistry for the Adolescence 225
21. Sports Dentistry and Mouth Protection 239

Index 241

Part 3

Transitional Years: Six to Twelve Years

15. *Pit and Fissure Sealants and Conservative Adhesive Restoration*
16. *Managing Traumatic Injuries in the Young Permanent Dentition*
17. *Treatment Planning and Management of Orthodontic Problems*
18. *Behavior Management*
19. *Care of Special Child (Handicapped Child)*





Chapter 15

Pit and Fissure Sealants and Conservative Adhesive Restoration

INTRODUCTION

Pit and fissure caries represent approximately 90 percent of the total caries experience in childhood and adolescence. The development of pit and fissure caries occurs not only in 6-14 years old children but also in adolescents and young adults.

With the introduction of sealants, a clinical approach to prevention of caries in pit and fissure became available.

With innovative applications of the acid-etch technique, tooth surfaces with isolated involvement of pits and fissures may also benefit from the conservation of the tooth structure afforded by conservative adhesive resin restorations.

With the use of both fluoride releasing sealant and glass ionomer-based material which acts as a fluoride reservoirs for adjacent enamel and dentin, provide enhanced caries resistance for sound enamel and dentinal caries.

To make significant gains in caries reduction in the child, adolescent and adult population in the near future, it is necessary for the dental professional to educate and inform the general public, parents, physicians, underwriters of dental care plans and funding agencies about the cost-effectiveness and caries-preventive benefits of sealants and preventive restorations.

With the widespread use of the acid-etch technique, it may be possible to provide the majority of children, adolescents and adults with a caries-free-dentition.

MORPHOLOGY OF SURFACES WITH PITS AND FISSURES

The two main types of pits and fissures are:

i. *Shallow; wide V-shaped fissures* that tend to be self-cleansing and somewhat caries resistant.
ii. *Deep, narrow I-shaped fissure* that are quite constricted and may resemble a bottleneck in

JAYPEE BROTHERS

that the fissure may have an extremely narrow slit-like opening with a larger base as it extends towards dentino-enamel junction. These caries-susceptible, I-shaped fissures may also have a number of different branches extending towards or into a underlying dentin.

- *Reason for Early Development of Caries in Pits and Fissures*
  i. The fissure provide a protected niche for plaque accumulation.
  ii. The rapidity with which dental caries occurs in pits and fissures is most likely related to the fact that the depth of the fissure is in close proximity to the dentinoenamel junction and the underlying dentin; which is highly susceptible to caries.
- The morphology of occlusal surfaces varies from one tooth to the next and from individual-to-individual. But in general; the "Typical" premolar has a prominent primary fissure with usually three or four pits.

  In typical molar as many as 10 separate pits may be present in primary, secondary and supplemental fissures.

HISTOPATHOLOGY OF CARIES IN PITS AND FISSURES

- The inclines forming the walls of the fissures are affected first by caries process.
- The first histologic evidence of lesion formation occurs at the orifice of the fissure and is usually represented by the two independent bilateral lesions in the enamel composing the opposing cuspal inclines.
- As the lesion progresses, the depth of the fissure walls becomes involved and coalescence of the two independent lesions into a single, contiguous lesion occurs at the base of fissure.
- The enamel at base of the fissure is affected to a greater degree than that of cuspal inclines, and lesion spreads laterally along the enamel adjacent to the depth of the fissure and readily towards dentinoenamel junction.
- Once the caries process involves the dentin; it leads to eventual cavitation of the fissure owing to loss of mineral and structural support from the adjacent affected enamel and dentin, resulting in a clinically detectable lesion.

Historical Attempts in Prevention of Pits and Fissure Caries

- In 1924, "Thaddeus Hyatt", advocated "prophylactic restoration"; This procedure consisted of preparing a conservative class I cavity that included all pits and fissures at risk for caries development and then placing amalgam restoration.

Rationale of Prophylactic Restoration:

- An otherwise caries-free surface was that the procedure prevented further insult to the pulp from caries.
- Decreased loss of tooth structure.
- Required less time for restoration when the tooth eventually succumbed to caries.
- *A conservative approach by Bodecker in 1929*: Initially; cleaning of pits and fissure is performed with the use of explorer and flowing a thin mix of oxyphosphate cement into the fissure in an attempt to "seal" the fissures.
- *Prophylactic Odontomy by Bodecker*: The mechanical eradication of fissures is done in order to transform deep, retentive fissures into a easily cleansable ones.

JAYPEE BROTHERS

These techniques were employed until the use of sealants became prevalent.

DIAGNOSIS OF PIT AND FISSURE CARIES

Clinical Examination

Caries is present when the explorer catches or resists removal after insertion into pit or fissure with moderate to firm pressure and when this is accompanied by one or more of following signs of caries—

a. Softness at the base of the area.
b. Opacity or loss of normal translucency adjacent to pit or fissure as evidence of undermining or demineralization.
c. Softened enamel adjacent to the pit or fissure that can be scraped away with the explorer.

Radiographic Examination

Evaluation of pit and fissure caries on occlusal surfaces has been found to be of minimal diagnostic value especially evaluating enamel caries and superficial dentinal caries.

Currently, there are a number of techniques to aid the dentist in diagnosis of pits and fissure caries—

- Radiography—Conventional, xeroradiographic, digital
- Fiberoptic transillumination/infrared laser
- Caries detecting dye
- Light-induced fluorescence
- Ultrasonic imaging
- Electrical resistance
- A promising ancillary diagnostic device.

Electronic caries detector (having sensitive and very specific detecting explorer).

ALTERNATIVES OF PIT AND FISSURE TREATMENT

Dental practitioner can consider following alternatives:

- Observation only
- Sealant placement
- Conservative adhesive restoration
- Conservative restorations
  - Glass-ionomer-resin conservative restoration
  - Glass-ionomer conservative restoration
  - Sealant amalgam conservative restoration
- Amalgam, glass ionomer, glass-ionomer-resin or posterior composite restorations.

INDICATIONS FOR PIT AND FISSURE SEALANT PLACEMENT

- Deep, retentive pits and fissures, which may cause wedging or catching of an explorer.
- Stained pits and fissures with minimal appearance of decalcification or opacification.
- Pit and fissure caries or restoration of pits and fissures in other primary or permanent teeth.
- No radiographic or clinical evidence of interproximal caries in need of restoration on teeth to be sealed.
- Use of other preventive treatment such as systemic or topical fluoride therapy; to inhibit interproximal caries formation.
- Possibility of adequate isolation from salivary contamination.

CONTRAINDICATIONS TO SEALANT PLACEMENT

- Well-coalesced, self-cleansing pits and fissures.
- Radiographic or clinical evidence of interproximal caries in need of restoration.

JAYPEE BROTHERS

- Presence of many interproximal lesions or restorations and no preventive treatment to inhibit interproximal caries could be given.
- Tooth partially erupted and no possibility of adequate isolation from salivary contamination.

  Also the presence of an operculum over the distal marginal ridge is associated with loss of sealant material.
- Life expectancy of primary teeth is limited.
- For dentinal caries consider preventive restoration, conventional restoration.

CLINICAL TECHNIQUE : SEALANT APPLICATION

Step 1: *Isolation of tooth surface from salivary contamination*— Ideally a rubber dam isolation is preferred; but also cotton roll isolation with adequate suctioning to remove saliva from the operating field is also acceptable.

Step 2: *Cleaning the tooth surface*:

- Prophylaxis of the tooth surface is carried out in several ways—
- Using a pumice slurry applied with a rubber cup or pointed bristle brush.
- Using a air-polishing device with an air-powder abrasive (sodium bi-carbonate slurry) system; later neutralize this slurry with phosphoric acid for 5-10 sec.
- Using simply a tooth brush prophylaxis with toothpaste or pumice followed by copious water rinsing to prepare the pits and fissures.
- Trace the pits and fissures with a sharp, fine-pointed explorer to remove any cleansing material lodged within the pits and fissures.
- Once the tooth surface has been thoroughly cleansed, rinse and air dry the surface.

Step 3: *Acid-etch tooth surface*—The efforts of acid-etching on enamel were studied by buonocore in 1955.

Before explaining clinical application of Acid-Etch Technique the Scientific Basis for the Acid-Etch Technique must be understood

Acid-etching of surface enamel has been shown to produce a certain degree of porosity.

A sound enamel etched with phosphoric acid is affected at three levels microscopically they are:

- A narrow zone of enamel is removed by etching. By this way plaque, surface and subsurface organic pellicles are effectively dissolved.
- The other zone after narrow zone is etched zone is a fully reacted zone in which inert mineral crystals in the surface enamel are also removed, resulting in a more reactive surface, an increased surface areas, and a reduced surface tension that allows resin to wet the etched enamel more readily.

Etched Zone is Approx 10 mm in Depth

- The next zone is qualitative porous zone which is approx 20 mm in depth. The name of this zone itself explains that porosities which are created by the etching process is easily distinguished qualitatively from adjacent sound enamel.
- The final zone is quantitative porous zone; this zone extends into enamel for an additional 20 mm.

JAYPEE BROTHERS

As its name suggests it has relatively small porosities created by etching process that may be identified by quantitative methods using polarised light microscopy.

The resin material penetrates in these created porosities by various zones.

After gaining knowledge about various zones of enamel it is essential to know about various etching patterns.

Three characteristic etching patterns occurs following exposure of sound enamel to phosphoric acid

Type I etching pattern: In this prism cores are lost but the prism peripheries remains.

Type II etching pattern: In this prism core are relatively intact but prism peripheries are lost.

Type III etching pattern: Enamel shows a generalised surface roughening and porosity with an areas with no exposure of prism cores or peripheries.

These three etching patterns are found adjacent to one another.

Clinical Applications of Acid-Etch Technique

- Etching agent is applied over tooth surface with a fine brush, a cotton pledget or a minisponge using a recommended exposure time—
  For permanent teeth—Exposure time is 15 sec.
  For primary teeth—Exposure time is 15-30 sec.
  Fluorosed teeth require an additional exposure time.
- Gently rub the etchant applicator over the tooth surface; while rubbing periodically of fresh etchant is added; but while rubbing prevent spillage of etchant in interproximal areas (which may lead to irritation of gingiva in interproximal areas); in this regards a gel material is preferred to have controlled etching gently rubbing the etchant with including 2 to 3 mm of the cuspal inclines and reaching into any buccal or lingual pits and grooves that are present.

Step 4: *Rinse and dry-etched tooth surface*

- Rinse the etched tooth surface with an air-water spray for 30 seconds. This will remove the etching agent and reaction products from etched enamel surface.
- Dry the tooth surface for at least 15 seconds with uncontaminated compressed air. The dried, etched enamel should have a frosted-white appearance. If the enamel does not have this appearance; repeat the etching step.
- If etched and dried tooth surface is contaminated at this stage reisolate the teeth, rinse the entire tooth surface, dry thoroughly and repeat the etching process.

Step 5: *Apply sealant to etched tooth surface*

- Sealant material is allowed to flow in all etched pits and fissures; with mandibular teeth; sealant is applied at the distal aspect and allow it to flow at the mesial aspect and with maxillary teeth sealant is applied at mesial aspect and is allowed to flow distally. To allow sealant material to flow helps in preventing the incorporation of air in material.
- A thin layer of sealant is carried using a fine brush, or applicator to the cuspal inclines to seal secondary and

JAYPEE BROTHERS

supplemental fissures; and flow the sealant material into buccal or lingual pits and grooves.

- With photo activated sealants the setting reaction is initiated by exposing the sealant to visible light and usually requires 10 to 20 seconds for complete setting.

Step 6: *Explore the sealed tooth surface*

Explore the entire tooth surface for pits and fissures that may not have been sealed and for voids in the material.

If deficiencies are present, apply additional sealant material.

Step 7: *Evaluate the occlusion of sealed tooth surface*

- Evaluate the occlusion of sealed tooth surface to determine whether excessive sealant material is present and must be removed, allowing proper interdigitation.
- Evaluate the interproximal regions for inadvertent sealant placement by performing tactile examination with an explorer and passing dental floss between the contact regions.

Step 8: *Periodically reevaluate and reapply sealant as necessary*

- During routine recall examination, it is necessary to reevaluate the sealed tooth surface for loss of sealant material; and or caries development.
- If reapplying of sealant is necessary: the steps involved in reapplying sealant material to an existing sealant are identical to those used for initial placement.

FLUORIDE: RELEASING SEALANTS

- Fluoride-releasing sealant material composed of modified urethane-BIS-GMA resin.
- A reduction of approximately 60 percent of secondary caries formation occurs with use of the fluoride-releasing sealant compared with conventional sealant material.
- The fluoride released from the sealant material apparently becomes incorporated into the adjacent enamel and provides an increased level of caries resistance.
- It is possible to increase the fluoride load within a resin-based material, this may result in substantial increasein fluoride-release in the local environment and may reduce the effect of cariogenic challenge.
- Incorporation of organic fluorides in resin materials also enhances fluoride release while maintaining the physical properties of resin material.

Organic Fluorides that may be Incorporated into Polymer Matrix of Dental Material Includes

- Acrylic amine-hydrogen fluorides salt.
- Methacrylol fluoride-methyl methacrylate.
- *t*-butylaminoethyl methacrylate hydrogen fluoride.
- Tetrabutylammonium tetrafluoroborate.

CONSERVATIVE ADHESIVE RESTORATIONS

- Recently, additional types of conservative adhesive restorations have been introduced to deal with more extensive caries in isolated pits and fissures that require restoration of the prepared cavities with dental materials of greater strength.
- A well-accepted clinical procedure used for restoring isolated pits and fissures and simultaneously preventing caries in the remaining unaffected pits and fissures was originally

JAYPEE BROTHERS

designated the "preventive resin restoration" and uses acid-etch technique.

This restorative technique is been renamed "Conservative adhesive resin restoration".

A conservative adhesive resin restoration require the same steps as those used for sealant placement except that caries are removed from isolated pits and fissures.

Step 1: *Isolate tooth surface from salivary contamination*: Isolate tooth surface as described in pit and fissure sealant placement technique.

Step 2: *Remove caries from isolated pits and fissures*

- Removal of caries from isolated pit and fissure is accomplished by inverted cone- shaped, round or pear-shaped bur in a high-speed handpiece.
- Caries should be removed making no attempts to incorporate retention into the preparation.
- The size of the bur and the resulting cavity preparation will be dictated by the amount of caries present.

Step 3: *Cleanse tooth surface*: Perform tooth prophylaxis followed by rinsing and drying.

Step 4: *Place cavity base or lining material*: If cavity is deep leading to exposure of dentin; calcium hydroxide or glass ionomer base should be placed prior to acid etching.

Step 5: *Acid-etch tooth surface*: Etch, rinse and dry tooth surface similar to described previously with pit and fissure sealant placement technique.

Step *6:* *Place resin and sealant material*

- Place a thin layer of resin bonding agent or dentinal bonding agent in the prepared cavity.
- Next; place composite resin over the bonding agent. If it is chemical cured; allow time for complete setting reaction to occur; and or expose light cured material to the visible light source to initiate the setting reaction.
- Next, apply sealant material over the restored area and the adjacent intact etched pit and fissures.

Carry the sealant material up the cuspal inclines for 2 to 3 mm and into buccal-lingual grooves and pits; provide adequate time for sealant setting reaction.

Step 7: *Explore the sealed and restored tooth surface*: Explore the sealed and restored surface as described previously and add sealant material in deficiencies if any.

Step 8: *Evaluate the occlusion of sealed and restored tooth surface*

- Evaluate the occlusion of the sealed and restored tooth surface to determine presence of any occlusal interferences if any.
- Evaluate the interproximal regions for inadvertent resin placement by using explorer and dental floss.

Step 9: *Periodically reevaluate the conservative adhesive restoration, repair and reapply sealant as necessary*: During routine recall visits and examination it is necessary to reevaluate the sealed and restored tooth surface for—

- Loss of sealing material if any.
- Development of any carious lesion in already restored area.

Repair of the restored regions and reapplication of sealant material may be necessary periodically.

JAYPEE BROTHERS

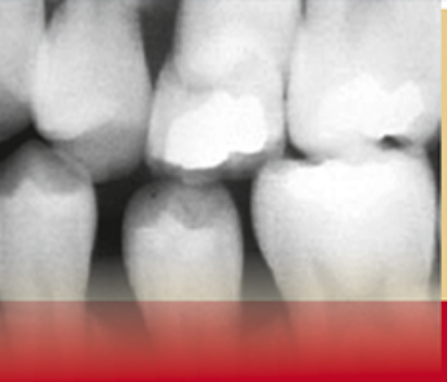

Essentials of Pediatric Dentistry

The *Essentials of Pediatric Dentistry* is a learning textbook intended to serve the needs of undergraduates especially final year BDS students to get integrated concepts with a better elaboration. Clarity, simplicity and condensing of various restorative procedures in a descriptive manner and style of steps has been the prime objective while writing this book. The organization of Units and chapters within the units serve as the format of dealing various procedures to be undertaken in children with different age groups with the special concern towards the practical importance of the subject itself. This in turn would serve as the programmed guide for the readers. The basic text has been written in an attempt to make our understanding of pediatric dentistry accessible to the undergraduate students and general practitioners.

Kanchan Harikishan Asnani



She is a dental surgeon, who completed her graduation from College of Dental Science and Hospital (RAO) Indore affiliated to DAVV University, Indore. During her academic career, she secured first position in final BDS examination. She has basic interest in pediatric branch of dentistry and so she initiated condensing her literature research and experiences gained in private practice into her textbook *Essentials of Pediatric Dentistry.* Currently, she is into private practice in Indore, India.

Available at all medical book stores
or buy directly from Jaypee Brothers through online shopping
at www.jaypeebrothers.com

or call + 91-11-32558559

JAYPEE BROTHERS
Medical Publishers (P) Ltd.
www.jaypeebrothers.com

ISBN 978-81-8448-742-8