A Concise Book on Pathology



Vasanthi Kasinathan

JAYPEE

Contents

1. Cell Injury and Cell Adaptation 1
2. Inflammation 11
3. Repair and Regeneration 29
4. Hemodynamic Derangements 43
5. Neoplasia 68
6. Infectious Diseases 80
7. Amyloidosis 96
8. Deficiency Diseases 99
9. Blood Formation and Blood Elements 104
10. Cardiovascular System 156
11. Respiratory System 175
12. Gastrointestinal Tract 192
13. Urinary Tract 203
14. Bones and Joints and Muscular System Disease 209
15. Diseases of Oropharyngeal Tissues, Jaws and Teeth 225
16. Central Nervous System 255

Index 263

CHAPTER

4 Hemodynamic Derangements

The cellular compartments of the body depend on the fluid circulation and blood supply. If there is any imbalance, it causes life-threatening conditions.

Fluid imbalance and any interruption in the blood supply lead to the following conditions:

1. Edema
2. Hyperemia/congestion
3. Hemorrhage
4. Thrombosis
5. Embolism
6. Infarction
7. Shock.

EDEMA

This term is defined as accumulation of excess fluid in the intracellular (intestitial) spaces or body cavities.

It is classified into generalized and localized edema according to the site of anatomical location:

Generalized edema (anasarca) means the fluid collection all over the body cavities causes diffuse swelling of the subcutaneous tissues.

Localized edema—Collection of fluid in the peritoneal cavity—Ascites, in the pleural cavity—Hydrothorax, in the pericardial cavity—Hydropericardium.

The edema fluid may be exudate or transudate (Table 4.1).

JAYPEE BROTHERS

Table 4.1: Comparison of exudate with transudate

	Exudate	*Transudate*
Total protein content	High as in plasma	Less than 10 g/l
Distribution of proteins	As in plasma	Albumin is present
Fibrinogen	Present. It clots spontaneously	Not present. No tendency for coagulation
Specific gravity	High more than 1.020	Low less than 1.012
Cells	Plenty of inflammatory cells	Few cells are present Mesothelial cells are seen

According to the cause (etiology) the edema is classified as follows:

Localized Edema

- Acute inflammatory edema
- Hypersensitivity (allergic edema)
- Edema due to venous obstruction
- Lymphatic edema.

Generalized Edema

- Cardiac edema
- Pulmonary edema
- Renal edema
- Famine edema (nutritional edema)
- Protein losing enteropathy
- Hepatic edema
- Edema due to adrenal hormones
- Myxedema
- Pregnancy
- Unexplained edema.

Causes for Edema

1. Increased hydrostatic pressure
   a. Impaired venous return
   b. Arteriolar dilatation

JAYPEE BROTHERS

2. Reduced oncotic pressure of plasma—Hypoproteinemia
3. Sodium retention
4. Lymphatic obstruction.

Pathogenesis

Imbalance between the production of interstitial fluid and its return to blood through either reabsorption or lymphatic obstruction or lymphatic drainage will result in edema.

Pulmonary Edema

Pulmonary edema, a common clinical and pathologic condition, is defined as increased water within the lung.

Pathogenesis of Pulmonary Edema
There is a balance between hydrostatic forces which tend to make fluid pass out from the capillaries to the interstitium and alveoli due to oncotic forces, which draw fluid into the capillary had from the capillary and oncotic pressure on the venous side. In hydrostatic edema the hydrostatic forces dominate and the fluid is forced into the interstitium of the lung and alveolar spaces. When epithelial cells are lost and fluid flow freely into alveolar space. When there is endothelial damage, the barrier function of the capillary wall is also impaired.

Causes of Pulmonary Edema

- Heart failure
- Withdrawal of effusions
- Cerebral damage
- Infections
- Toxic irritants
- Oxygen toxicity
- Aspiration pneumonia
- Drowning and near drowning
- Circulating toxicity
- Radiation pneumonia
- Uremia
- Adult respiratory distress syndrome (ARDS)

JAYPEE BROTHERS

Morphology

Pulmonary edema accumulates as a transudate. Lungs become heavy and alveolar spaces are filled with transudate. Histologically, the alveoli are filled with coagulum of edema fluid. The alveolar wall then becomes normal. There is inflammatory cells within the alveoli.

Clinical Significance

Dyspnea, abnormal breath sounds (rales) are produced. In severe pulmonary edema, it is life-threatening with basal rales and severe respiratory difficulty.

Renal Edema

Causes

- Acute glomerulonephritis
- Nephrotic syndrome
- Chronic glomerulonephritis.

Morphology

Edema is pitting edema clinically. Finger pressure over edematous subcutaneous tissue will displace the interstitial fluid from the dermal subcutaneous connective tissue to leave pitted depressions.

Renal edema is identified by edema of the face particularly of the eyelids (periorbital edema).

Cardiac Edema

In cardiac failure the edema is in the dependent portions of the body-dependent edema. When the patient is ambulatory fluid collects first in the lower extremities particularly over the dorsal aspects of feet and anklets.

JAYPEE BROTHERS

Cerebral Edema

In hypertensive and encephalitis patients the cerebral edema is commonly seen. In this case brain is heavier than normal. Sulci are narrowed, gyre are swollen and flattened, pressing against the skull. Cut section show soft and gelatinous white matter and widened gray matter. Ventricles are compressed histologically. Loose appearance of white and gray matter is seen. Swelling of the neuronal cells are present.

Clinical Significance

Increased intracranial pressure resulting in headache, projectile vomiting and convulsive seizures. Herniation of the brainstem or cerebellar tonsils into the foramen magnum may precipitate death.

HYPEREMIA / CONGESTION

Increased blood volume in an affected tissue or part is called hyperemia. Hyperemia is also called active hyperemia which is due to arteriolar and arterial dilatation. This is brought about by sympathetic neurogenic mechanisms or the release of vasoactive substances, e.g. blushing.

Congestion or Passive Hyperemia

Congestion or passive hyperemia results from impaired venous drainage and causes an intensified blue-red coloration in the affected parts and leads to an increase of deoxygenated hemoglobin in the blood cyanosis.

Morphology

Organs affected are lungs, liver and spleen.

Lungs

In cases of rheumatic mitral stenosis which causes reduced left ventricular output.

JAYPEE BROTHERS

Grossly: Lungs are edematous filled with blood.

Cut section: Shows airspaces are filled with a frothy liquid—blood mixed with air.

Microscopically: Dilated alveolar capillaries are seen.

Rupture of distended capillaries cause minute intraalveolar hemorrhages and phagocytosing of breakdown red cell debris leads to hemosiderin lead macrophage (heart failure cells) in the alveolar septa are thickened. The edematous fibrotic and along with hemosiderin pigmentation forms brown induration of the lung.

Liver

Causes: Right sided heart failure, obstruction of inferior vena cava or hepatic vein.

Gross: Liver is enlarged bloodly and congested.

Cut Sectzion: Nutmeg appearance, shows red-blue areas of congestion alternating with uncongested areas (Fig. 4.1).

Microscopically: Area of central hemorrhagic necrosis surrounded by fatty areas due to hypoxia, fibrotic thickening of central veins is seen. Extension of this fibrous tissue into the surrounding lobule creates cardiac sclerosis or cardiac cirrhosis.

Spleen

Causes: Ischemia, chronic cardiac failure.

Grossly: Spleen is enlarged, congested, bloody.

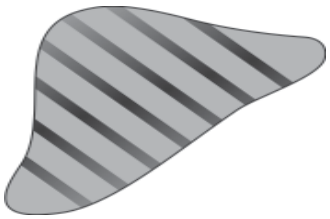

Fig. 4.1: Nutmeg liver

JAYPEE BROTHERS

Cut Section: Shows woozing out from the sinuses.

Microscopically: Capsule and trabeculae are thickened. Red pulp shows the congested arterioles containing blood. White pulp shows atrophied lymph follicle.

In longstanding cases fibrous thickening and hemosiderin deposits within the edematous, congested sinusoidal walls from siderofibrotic nodules. The calcification occurs in these areas forming Gamna-Gandy bodies.

HEMORRHAGE

Rupture or laceration in the organs lead to hematoma. When blood escapes into the serous cavity and referred as hemothorax, hemopericardium or hemoperitoneum. Smaller hemorrhages occur in the skin, mucous membranes and serosal surfaces are known as petechiae or purpura.

Causes

- Trauma.
- Diseases that attack the blood vessel primarily or secondarily.
- Hemorrhagic disorders, scurvy.

Clinical Significance

Hemorrhage depends on the blood loss, its rate of escape and site of hemorrhage. In larger rapid blood loss cause hemorrhagic shock. Hemorrhage into the blood leads to death.

THROMBOSIS

Formation of a clotted mass of blood within the noninterrupted cardiovascular system is termed as thrombosis and the mass is known as thrombus. Blood clot is formed by formed elements of blood due to the activation of blood coagulation cascade.

Thrombus is formed in the living tissue only. It differs from the postmortem clot.

JAYPEE BROTHERS

Antemortem clot (Thrombus)	*Postmortem clot*
1. Clot is formed elements of blood and interaction of blood vessel wall	Clot is formed by the elements only
2. Endothelial injury is the cause of thrombus	No endothelial injury
3. Clot is reddish brown in color, firmly attached to the blood vessel wall	Clot is jelly like, yellowish having chicken fat appearance. No attachment to the vessel wall
4. Clot is not able to remove from the blood vessel	Clot is easily removable
5. Lines of Zahn is seen	No lines of Zahn
6. Clot is formed in the living body	Clot is formed after death

Pathogenesis of Thrombus—Thrombogenesis

This is influenced by three factors which are known as Virchow's triad of thrombogenesis. The three major influences predispose to thrombosis (Fig. 4.2).

1. Injury to the endothelium.
2. Alterations in the normal blood flow.
3. Alteration in the blood (hypercoagulability).

Endothelial Injury

Endothelial injury is important in the formation of thrombi in the heart and arteries.

Causes and sites for endothelial injury:

a. In the left ventricle at the site of myocardial infarction
b. On ulcerated atherosclerotic plaques
c. Diabetics
d. Inflammatory valve disease patients (Prosthetic valves)
e. Cigarette smoking
f. Endotoxin of bacteria
g. Immunologic injuries
h. Radiation injury

JAYPEE BROTHERS

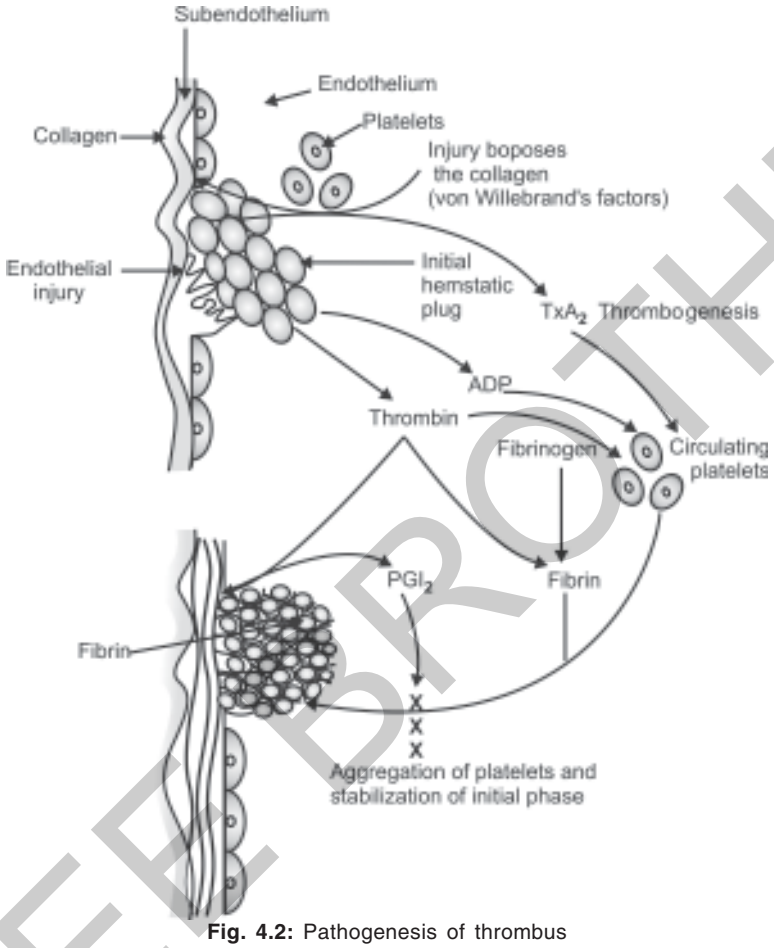

Fig. 4.2: Pathogenesis of thrombus

Alterations in the Blood Flow

Turbulent flow contribute to the development of arterial and cardiac thrombi.

Stasis contributes to venous thrombosis.

Stasis and turbulent flow has four dimensions in the formation of thrombus:

1. They disrupt the laminar flow and using the platelet into contact with the endothelium.
2. They prevent the dilution by the fresh flow of blood and hepatic clearance of the activated coagulation factors.

JAYPEE BROTHERS

3. They retard the inflow of inhibitors of clotting factors and permit the thrombi to form.
4. Turbulent flow damage the endothelium and reduce the local release of prostacyclin and tissue plasminogen activator.

Alteration in the Blood (Hypercoagulability States)

a. Deficiency of antithrombin III or protein C.
b. Nephrotic syndrome.
c. Following severe trauma or burns.
d. Disseminated cancers.
e. During late pregnancy and following delivery.

Formation of Thrombus

Following endothelial injury and alteration in blood flow exposes the subendothelial collagen and von Willebrand factor is released. The platelet adhere to the site and then aggregate. ADP and thromboxane A2 are released and along with locally generated thrombin, which recruit additional platelet, causing the mass to enlarge. The growing platelet thrombus is stabilized by fibrin along with other elements of blood. The release of prostacyclin (PGI_2) by endothelial cells regulates the process by inhibiting platelet aggregation.

Stages in the Formation of Thrombus

There are five stages:
1. Primary platelet thrombus
2. Corallin thrombus
3. Occluding thrombus
4. Consecutive clot
5. Propagated clot.

1. Initial endothelial damage, adhere the platelet to the vessel wall aggregate to form a *platelet thrombus* (Fig. 4.3).

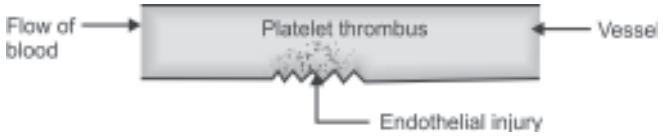

Fig. 4.3: Platelet thrombus

JAYPEE BROTHERS

2. Fibrin deposition along with red and white blood cells and thrombin formation on primary platelet thrombus take the upstanding laminate growing across the stream. They bent in the direction of blood flow by the force of stream. The laminae anastomose to form an intricate structure which resembles coral—*corallin thrombus*. The elevated platelet ridges are called the *lines of Zahn*. This is best seen in aorta (Fig. 4.4).



Fig. 4.4: Line of Zahn (arrow)

3. Thrombus progressively occludes the lumen of the vein, and due to the stasis of blood flow, there is formation of more thrombus which occludes the lumen, *occluding thrombus*, and trails away from the corallin thrombus in the direction of blood flow (Fig. 4.5).



Fig. 4.5: Corallin thrombus

4. After occlusion of vessel, the blood stops and the stationary column of blood beyond the occluding thrombus clots to form consecutive clots which extends up to the entrance of the venous tributary. At this point the edge of the clot become endothelialized and spreads.
5. *With thrombus formation at each entering tributary:* The clot which reaches to the entrance of the venous tributary leads to the formation of another platelet and corallin thrombus, and occludes the ostium of tributary consecutive clot then up to the ostium of next venous tributary. Eventually a long *propagated clot* is produced that is well-anchored at each successive ostium (Fig. 4.6).

JAYPEE BROTHERS

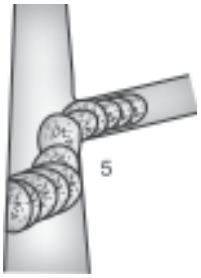

Fig. 4.6: Propagated clot

5. *Clotting enmasses in an extensive length of vein:* Sometimes the column of blood above the consecutive clot is so stagnant, due to the stasis of circulation that it clots en masses, forming one long cord of clotted blood, anchored only at the original site of clotted blood, anchored only at the original site of thrombus formation. This length of clots retracts, and lies loose in the vessel except at this point of anchorage, which may retract and forms pulmonary embolus. This type of propagation is particularly dangerous to life.

Morphology

Sites of Thrombi

Thrombi can occur anywhere in the circulatory system. According to the site the thrombi are divided into 3 types:

1. Mural thrombi
2. Arterial thrombi
3. Venous thrombi (Thrombophlebitis)

Macroscopically the thrombi are reddish brown in color, which is firmly attached to the blood vessel wall. Lines of Zahn, alternating layers of red cells and plasma with pale platelet areas.

- *Mural thrombi*: Occur in more capacious lumina of the heart chambers and aorta.
- *Arterial thrombi*: Arterial thrombi are occlusive and present in descending order of frequency—coronary, cerebral and fermoral arteries.

JAYPEE BROTHERS

- *Venous thrombi*: Venous thrombi are also known as phlebothrombosis (Thrombophlebitis) and occur in descending order of frequency – calveins, femoral, popliteal and iliac veins. These venous thrombi occurring in deep veins of lower limbs (90%) cause embolization.

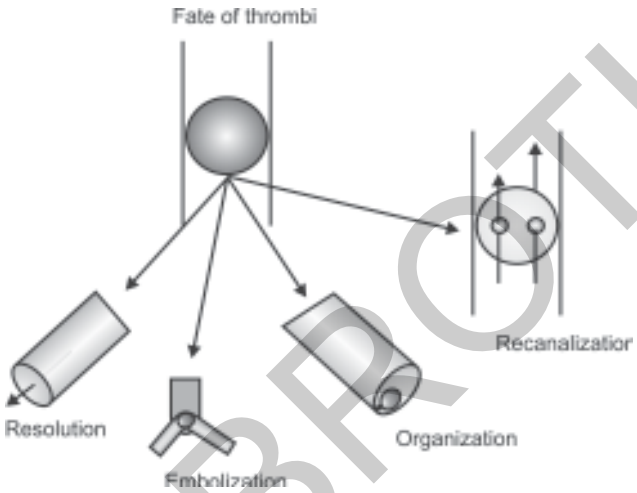

Fig. 4.7: Fate of thrombi

Fate of Thrombi (Fig. 4.7)

1. Resolution
2. Embolization
3. Organized and incorporated into the wall
4. Organized and recanalized.

Resolution: Completely resolved by the fibrinolytic activity.

Embolization: Occur in the lungs. The thrombi arising in calf veins propagated and more up to the left ventricle, reach the pulmonary artery to embolies in the pulmonary artery bifurcation.

Organized and incorporated into the wall: Thrombi get organized by formed elements of blood, neutrophils phagocytose the fibrin and allows the calcium salts which get trapped into the vessel wall.

JAYPEE BROTHERS

A Concise Book on Pathology

Salient Features

- An exam-oriented book
- Presents the text in lucid and concise manner
- Covers all the aspects of pathology
- Provides specific and to-the-point answers to the questions asked in the examination
- Useful for the students preparing for paramedical and dental courses.

JAYPEE BROTHERS

Available at all medical book stores
or buy directly from Jaypee Brothers through online shopping
at www.jaypeebrothers.com

or call + 91-11-32558559

JAYPEE BROTHERS
Medical Publishers (P) Ltd.
www.jaypeebrothers.com

ISBN 978-81-8448-756-5