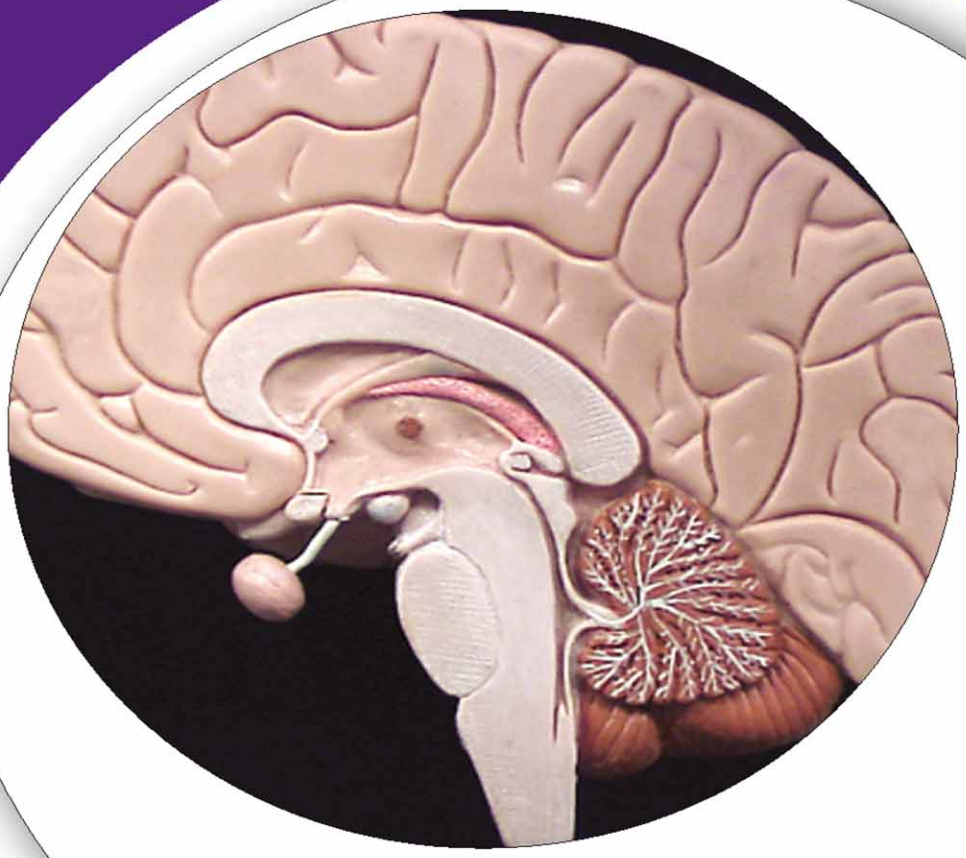

Differential Diagnosis in NEUROLOGY

Rajendra B Kenkre

JAYPEE

Contents.....

1. **Peripheral Neuropathy** ____*1*
2. **Radiculopathy** ___*74*
3. **Disease of Muscle and the Muscle Endplate** ___*82*
4. **Diseases of Anterior Horn Cell** _ *125*
5. **Spinal Cord** _ *136*
6. **Cerebellum** _ *186*
7. **The Extrapyramidal System** _ *200*
8. **The Cerebral Hemispheres** _ *228*
9. **Cranial Nerves** _ *253*
10. **The Autonomic Nervous System** _ *278*
11. **Cerebrovascular Diseases** _ *285*
12. **Epilepsy** _ *316*
13. **Headache** _ *340*
14. **Dementia** _ *348*
15. **The Brainstem** _ *376*

Index _____

2 Radiculopathy

UPPER EXTREMITIES

It is essential to delineate as to whether the clinical picture is that of single nerve lesion or root lesion. Sensory symptoms may be unreliable markers, for instance root lesion may give rise to paresthesias like tingling numbness exactly similar to that of the peripheral nerve lesion.

Exception to the generality is the rule in the following situations root lesions:

- C5: Pain occurs over the shoulder and into the lateral arm; it does not extend below the elbow.
- C6: Deep aching pain in the biceps muscle spreads down to the lateral forearm, involving thumb and index finger on both palmar and dorsal aspects.
- C7: Deep aching pain in the triceps muscle radiating mainly into the middle, index and ring fingers.
- C8: Root pain: It occurs below the olecranon – radiating to the little and ring fingers.
- T1: Root pain, deep aching pain at the shoulder joint and axilla, radiating down the medial side of the arm up to the olecranon.

JAYPEE BROTHERS

Differentiation of Sensory Symptoms Root/peripheral Nerves

Three main nerves which are considered include the following:

1. *Radial nerve:* Detectable sensory loss in radial nerve lesion is limited only to slight tingling over the dorsal aspect of the thumb and index finger.
2. *Median nerve:* In median nerve lesion at the wrist, the pain besides involving lateral palm thumb, index, middle and ring fingers spreads to the forearm and occasionally to the shoulder.
3. *Ulnar nerve:* In practice, the pain and sensory disturbance besides involving skin crease at the wrist front and back of the little finger and medial half of the ring finger also spreads to the ulnar border of the forearm and this may mimic C8 root lesion.

Evaluation of Motor Function in the Arm

The first-seven cervical nerves and their corresponding vertebral bodies are shown in Figure 2.1.

C5 root lesion: Weakening of shoulder abduction.

C6 root lesion: Weakness of elbow flexion due to weakness of biceps and brachioradialis.

C7 root lesion: Weakness of shoulder adduction and extension of elbow and weakness of wrist flexion. Radial nerve lesion, on the other hand does not affect shoulder adduction or wrist flexion.

C8 root lesion: This causes weakness of long extensors and flexors of the fingers and in some instances weakness of small muscles of the hands.

JAYPEE BROTHERS

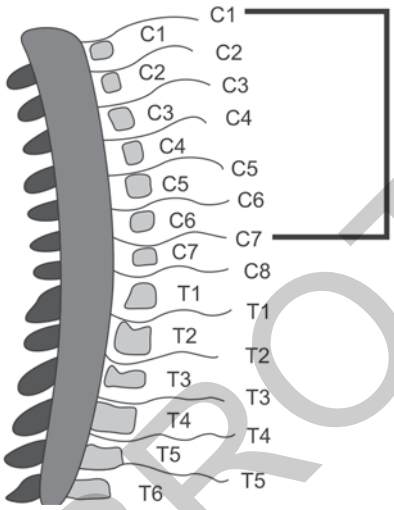

Fig. 2.1: The first-seven cervical nerves and their corresponding vertebral bodies

T1 root lesion: This causes weakness and wasting of all the intrinsic muscles of the hand. Among. 2 - 3% of patients, all hand muscles are supplied by ulnar nerve.

Clinical Syndrome

A few clinical syndromes associated with injury to the brachial plexus (Figure 2.2) are described below:

Erb-Duchenne Type Paralysis

- It occurs due to the avulsion of C5-C6 roots.
- This can happen during forceps delivery or motor cycle accidents.
- It can result in the loss of adduction at the shoulder and loss of flexion at the elbow.

JAYPEE BROTHERS

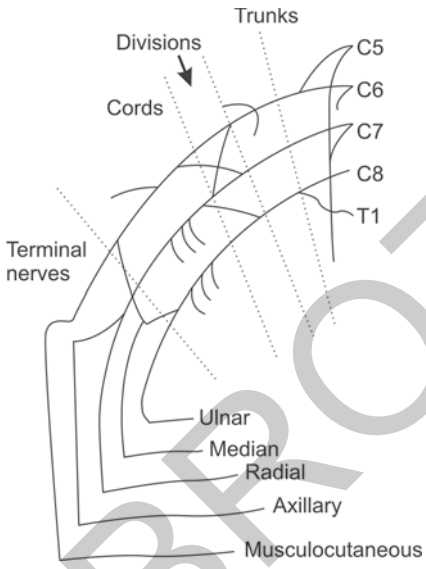

Fig. 2.2: Brachial plexus

Klumpke's Paralysis

It occurs due to avulsion of T1 and C8 roots usually, seen in injuries due to falls.

Root lesions due to cervical spondylosis

- C5, C6 roots are most affected.
- Biceps and supinator jerks depressed or absent some cases all three reflexes may be absent.

Acute Cervical Disc Lesion

- Severe root pain with radicular root pain.

JAYPEE BROTHERS

Brachial Neuritis

- Typically excruciatingly severe pain over C5/C6/C7 dermatomes.
- Wasting and weakness of C5/C6/C7.
- There may be weakness of sternomastoid and trapezius.

Cervical Rib Syndrome

It occurs when accessory or the first rib is displaced upwards by distortion of the thorax, which could be associated with scoliosis, or thoracoplasty.

Sometimes could occur as an autosomal recessive disorder with malformation of the shoulder joint.

Symptoms

Neural

There is deep aching pain in the axilla and down the ulnar border of the arm, often extending into the hand, in the territory of C8-T1.

Principal affect is seen on abductor pollicis brevis. Nevertheless, it is important to note that pain mainly occurs in the ulnar deviated fingers and weakness and wasting is in the median innervated abductor pollicis brevis.

Vascular Syndrome

This occurs due to high cervical rib displacing axillary artery upwards.

There may be stenosis of the artery with poststenotic dilatation.

Clot may form in the poststenotic part of the artery and emboli may pass down to the brachial artery giving rise to ischemic changes akin to Raynaud's phenomena in the fingers.

JAYPEE BROTHERS

Investigations

- EMG
  - Denervation of abductor pollicis brevis.
  - Normal median nerve action potential at the wrist.
- MRI
- Angiography.

NEUROPHYSIOLOGICAL AIDS

All neurologists should have detailed knowledge of electrophysiological techniques and their interpretation to assess a patient with peripheral nervous disease, which may be at the anterior horn, peripheral nerve or muscle. This would also help in providing sensible differential diagnosis in situations such as root lesion and peripheral nerve lesions. Certain terms need to be mentioned here for clarity.

Denervation: If the nerve supply to a muscle is damaged by disease of the ventral horn cell, nerve root or peripheral nerve, the muscle is denervated and EMG findings are denoted as **chronic partial denervation**.

Motor unit: Comprises of ventral horn cell, its axon and the group of muscle fibers.

Reinnervation

Sometimes, when a ventral horn cell or its neuron is damaged, certain muscle fibers cease to function and the surviving neurons branch out and take over the adjacent denervated muscle fiber activity. This is expressed in the EMG as **spontaneous electrical activity** as denervated muscle fibers are innervated.

JAYPEE BROTHERS

On insertion of the needle in the muscle – insertional activity increases, that is injured potentials are prolonged and sometimes continue as burst of decreasing frequency, amplitude and pseudomyoclonic run.

Fibrillation Potentials

These are brief alterations in the amplitude of the action potential (50 - 200 μv). If prolonged and monophasic – positive sharp waves.

When the resting activity has been observed, the patient contracts the muscle gently, the inserted needle in the muscle is steadied, and individual motor units are studied.

Normal motor unit produces bi or triphasic potential up to 2 mv in proximal muscle and 5 mv in distal hand and foot muscles.

Giant unit polyphasic potentials vary from 5-10 mv up to 15 mv. The patient then contracts the muscle against resistance; the activity is continuous as the new units contract and rest. Obliteration of baseline sweep is called interference pattern. In a denervated pattern, gaps appear in the pattern. The surviving units are large and polyphasic, these are identical. This is known as reduction in the interference pattern and indicates denervation (chronic partial denervation), which may be due to involvement of anterior horn cell or peripheral nerves.

Nerve Conduction Studies

Muscle and nerve are the two things on which nerve conduction studies are based.

One stimulates the two end-points, one close to the muscle and the other at a higher point.

JAYPEE BROTHERS

The time taken for the stimulus to travel from that nearest to muscle is known as distal latency, which in fact is time taken for the stimulus to travel from the nerve to end plate muscle and the delay which occurs at the end plate before contraction is elicited.

The nerve is then stimulated at higher point and conduction velocity is measured which is in meters per second and denotes the time taken by the impulse to travel down the length of the nerve.

Most peripheral nerves have standard velocity time commonly in the upper limbs, median and ulnar and in the lower limb, peroneal and tibial nerves.

At some points of injury to a peripheral nerve such as ulnar nerve at the elbow and peroneal nerve at the fibula, there may not be correct assessment of slowed conduction. In such a situation, we study action of quantitative muscle action potentials. Graded shocks are applied to the nerve at the wrist and ankle and muscle action potentials are measured, a few points below elbow and fibula and then above the elbow or popliteal fossa. It is the reduction from 10% at 1st mentioned points to 40% at the second mentioned points, which is diagnostic of damage to the nerve above the stimulus.

JAYPEE BROTHERS

Differential Diagnosis in NEUROLOGY

Salient Features

- A unique book on diagnoses of neurological disorders
- Presents the text in a simplified manner
- Throws light on clear understanding of the subject
- Deals with various diseases of CNS from neuro-anatomical and neurophysiological view points
- Useful for undergraduate and postgraduate students and teachers of Neurology

Available at all medical book stores
or buy directly from Jaypee Brothers through online shopping
at www.jaypeebrothers.com

or call + 91-11-32558559

JAYPEE BROTHERS
Medical Publishers (P) Ltd.
www.jaypeebrothers.com

ISBN 978-81-8448-947-7