Non-Descent Vaginal Hysterectomy Made Easy®

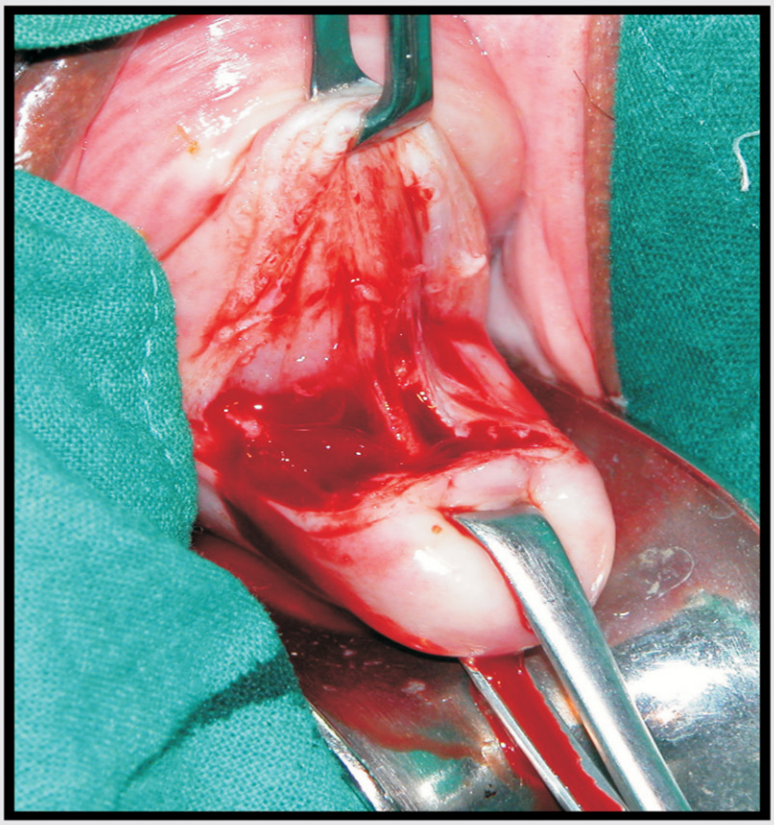

Sudhir R Shah
Beena N Trivedi
Dipal D Solanki

Foreword
Rohit V Bhatt



With Interactive CD ROM

JAYPEE

2nd Edition

Contents

Section 1: Surgical Techniques in Glaucoma

1. Surgical Management of Congenital and Developmental Glaucomas 1
   Ahmad K Khalil (Egypt)
2. Aniridia Rings: Surgery for Advanced Congenital Glaucoma 11
   Ahmad K Khalil (Egypt)
3. Primary Infantile Glaucoma 16
   Maria Da Leiz Freitas (Portugal)
4. Pediatric Glaucomas 29
   Nicola Freeman (South Africa)
5. New Investigations in Glaucoma 33
   Tanuj Dada, Shibal Bhartiya, Sujith Vengayil (India)
6. Management of Open Angle Glaucoma 53
   Mordechai Goldenfeld, Shlomo Melamed (Israel)
7. Management of Primary Angle-Closure Glaucoma (PACG) 67
   G Marchini, M Marraffa, R Morbio, P Ceruti (Italy)
8. Management of Angle-Closure Glaucoma 79
   Boris Malyugin (Russia)
9. Traumatic Angle Recession Glaucoma—An Overview 84
   Cyres K Mehta, Keiki R Mehta (India)
10. Management of Pigmentary Glaucoma and Pseudoexfoliation Syndrome 88
    Ashok Garg (India)
11. Phacoemulsification Combined with Trabeculectomy: Single Site 96
    Tanuj Dada, Shibal Bhartiya (India)
12. Two-site Phacotrabeculectomy 102
    Tanuj Dada, Shibal Bhartiya (India)
13. Bimanual Microincision Cataract Surgery Combined with Trabeculectomy 107
    Tanuj Dada, Shibal Bhartiya (India)
14. Combined Cataract and Ahmed Glaucoma Valve Surgery 114
    Tanuj Dada, Shibal Bhartiya (India)
15. Malignant Glaucoma 119
    V Velayutham (India)
16. Glaucoma Tube Shunts 124
    Cotlear Daniel, Mordechai Goldenfeld, Shlomo Melamed (Israel)
17. Express Shunt as Alternative Drainage Glaucoma Surgery 133
    Shui H Lee (Canada)

18. Update on Shunt Surgery for Refractory Glaucoma 136
Jes Mortensen (Sweden)

19. Viscocanalostomy 143
Roberto G Carassa (Italy)

20. Modern Glaucoma Surgery 148
Jes Mortensen (Sweden)

21. Laser Sclerotomy 155
Amar Agarwal, Sunita Agarwal, Ashok Garg (India)

22. An Update on Deep Sclerectomy with Collagen Implant 158
Sylvain Roy, André Mermoud (Switzerland)

23. Trabeculotome-Guided Deep Sclerectomy 162
Ahmed Mostafa Abdelrahman (Egypt)

24. Post Penetrating Keratoplasty Glaucoma 166
Tanuj Dada, Sunil Choudhary, Anita Panda (India)

25. Glaucoma Implants in the Treatment of Pediatric Glaucoma 176
Peter WT de Waard (Netherlands)

26. Managing Aphakic Glaucoma in Children with AGV Valves 180
Keiki R Mehta, Cyres K Mehta (India)

27. Glaucoma Implants 186
Roberto G Carassa (Italy)

28. Laser Procedures in Glaucoma 190
Tanuj Dada, Shibal Bhartiya, Shalini Mohan (India)

29. CO_2 Laser Assisted Deep Sclerectomy 199
Ehud I Assia (Israel)

30. Update on Selective Laser Trabeculoplasty 203
Madhu Nagar (UK)

31. Trabecular Meshwork Ablation as an Alternative to Invasive Glaucoma Surgery 210
Mona Pache, Jens Funk (Germany)

32. Recent Advances in Drainage Implant Surgery 215
Keiki R Mehta, Cyres K Mehta (India)

33. New Minimally Invasive, Deep Sclerotomie ab Interno Surgical Procedure for Glaucoma 223
Bojan Pajic, Brigitte Pajic-Eggspuehler (Switzerland)

34 Combined Phacoemulsification and Deep Sclerectomy with T-Flux® 231
Pascal Rozot (France)

35. Sutureless Trabeculectomy – A Step Forward in Reducing Postoperative Astigmatism 235
CS Dhull, Sumit Sachdeva (India)

36. Phaco-Deep Sclerectomy Combined Surgical Treatment of Cataract and Open Angle Glaucoma 239
Boris Malyugin (Russia)

37. Refractive Surgery and Glaucoma 261
José I Belda, Gonzalo Muñoz, Juan José Pérez-Santonja, Javier Benitez del Castillo
Jorge L Alió (Spain)

Section 2: Recent Advances and Innovations in Glaucoma Surgery

38. Anterior Segment Lymphatics and Glaucoma Surgery 269
Daljit Singh, Kiranjit Singh (India)

39. Titanium-Sapphire Laser Trabeculoplasty (TiSLT) 276
Shlomo Melamed, Mordechai Goldenfeld (Israel)

40. Milling Trabeculoplasty: A New Technique for Non-penetrating Glaucoma Surgery 279
José L Rodriguez-Prats, Jorge L Alió, Ahmed Galal (Spain)

41. Transconjunctival Transciliary Filtration 289
Daljit Singh (India)

42. Glaucoma Surgery with Fugo Plasma Blade 294
Daljit Singh, Kiranjit Singh (India)

43. Trabecular Bypass Surgery 304
Gabor B Scharioth (Germany), Randy Craven (USA)

44. From Deep Sclerectomy to Canaloplasty: Re-establishing the Natural Outflow 308
Gabor B Scharioth (Germany)

45. Suprachoroidal Shunts: New Surgical Approach in Glaucoma 318
Gabriel Simon (Spain)

46. Minimally Penetrating Glaucoma Surgery Using Microtubes 332
Sylvain Roy, André Mermoud (Switzerland)

47. Open Angle Filter Surgery For Glaucoma: Deep Sclerocanalostomy (DSC)—New Technique 337
Jerome Bovet (Switzerland)

48. Pars Plana AGV Implantation 344
Tanuj Dada, Shibal Bhartiya (India)

49. Intraocular Bevacizumab (Avastin®) for Rubeosis Iridis 350
João J Nassaralla (Brazil)

50. Gold Micro Shunt 355
Mordechai Goldenfeld, Shlomo Melamed (Israel)

51. Evolution of Glaucoma Surgery 361
Kumar J Doctor, Pooja Deshmukh (India)

52. Solid-state UV Laser for Minimally Invasive Glaucoma Surgery 382
JT Lin (Taiwan), Vivek Kadambi (India)

53. An Update on Prostanoid Drugs in Glaucoma Therapy 385
Miguel A Teus, Esther Arranz-Marques (Spain)

54. Primary Phacoemulsification Combined with Drainage Angle Viscodissection in the Management of Chronic Narrow-Angle/Angle-Closure Glaucoma (CNAG/CACG) and Coexistent Cataract 394
P Cikatricis, TKJ Chan (UK)

Index 399

Chapter 2

Aniridia Rings: Surgery for Advanced Congenital Glaucoma

Ahmad K Khalil (Egypt)

A child presented at the age of 9 with uncontrolled high intraocular pressure, complicated cataract, partial aniridia (Fig. 1), with a visual acuity of finger count at 30 cm. Owing to the complicated nature of the condition, a staged approach was planned. Trabeculotomy was done first to control the high IOP. Six months after persistent pressure control, cataract surgery with implantation of specially designed aniridia rings to cover the aniridic part, followed by implantation of 3-piece acrylic intraocular lens.

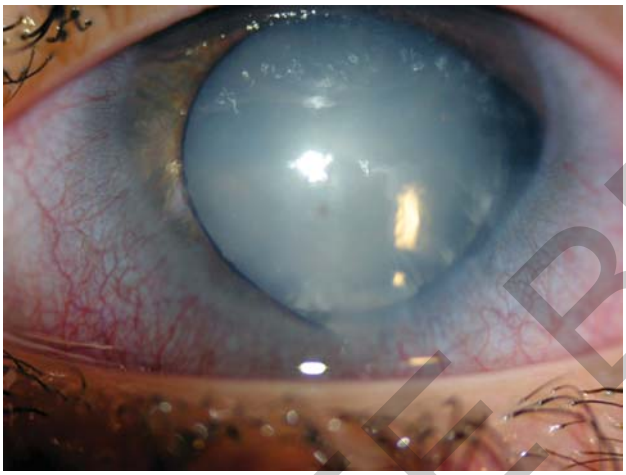

Fig. 1

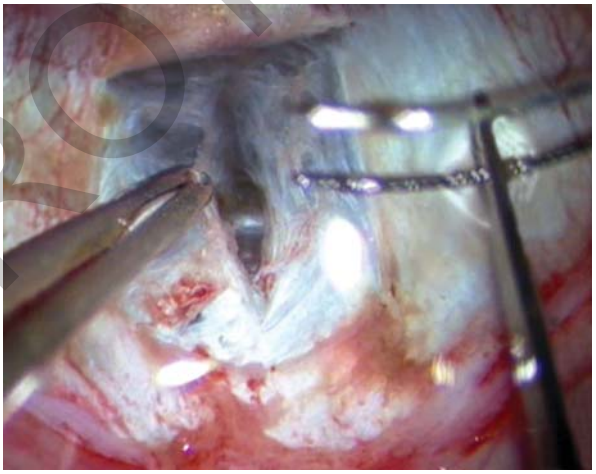

Fig. 2

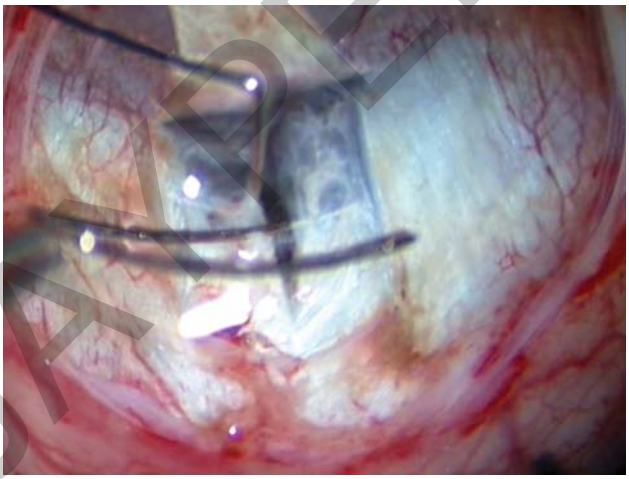

Fig. 3

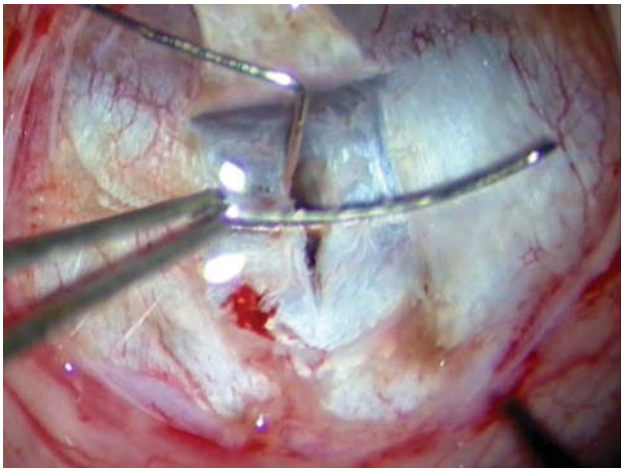

Fig. 4

Figs 2 to 4: Left and right trabeculotomy probes are being inserted through the incised edge of the canal of Schlemm

JAYPEE BROTHERS

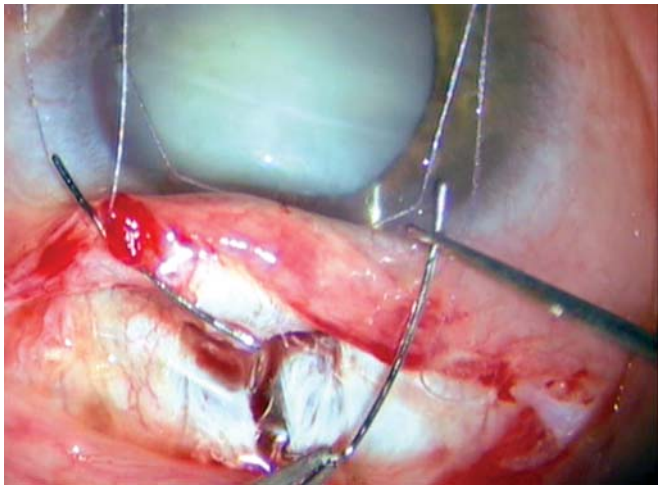
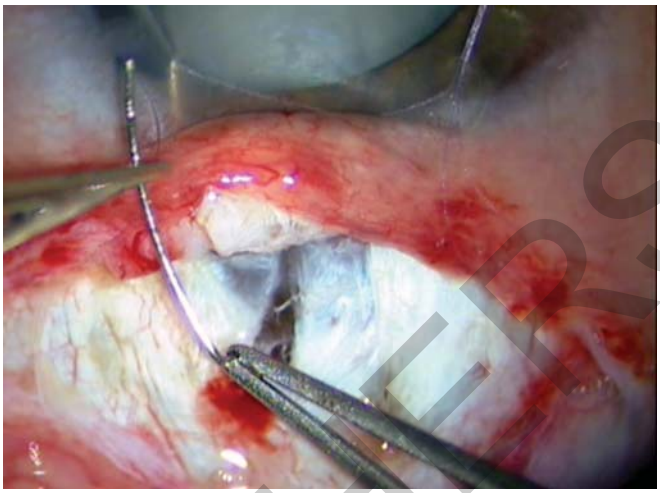

Figs 5 and 6: Probes are rotated inwards into the anterior chamber and gently withdrawn out to avoid injury to the lens capsule

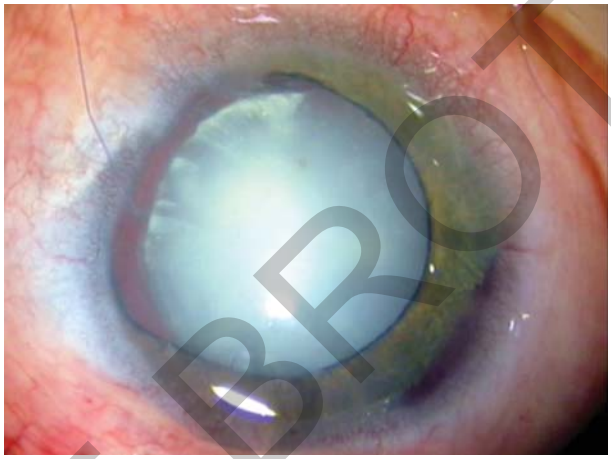

Fig. 7: This is what I call beautiful hyphema; a gentle tinge of hyphema at the trabeculotomy site confirming severing the trabecular meshwork in this area

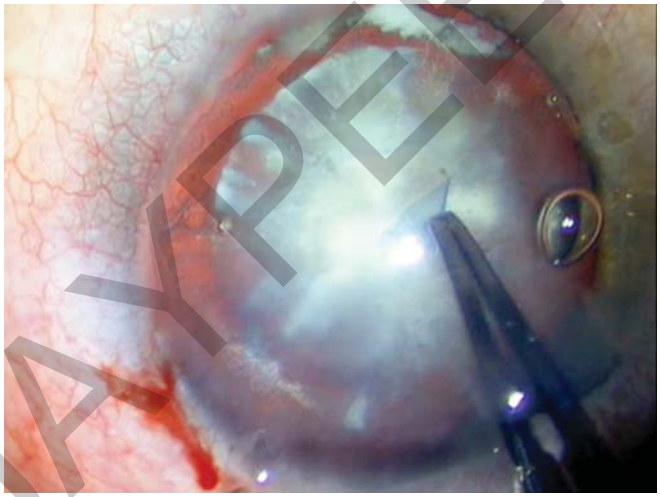
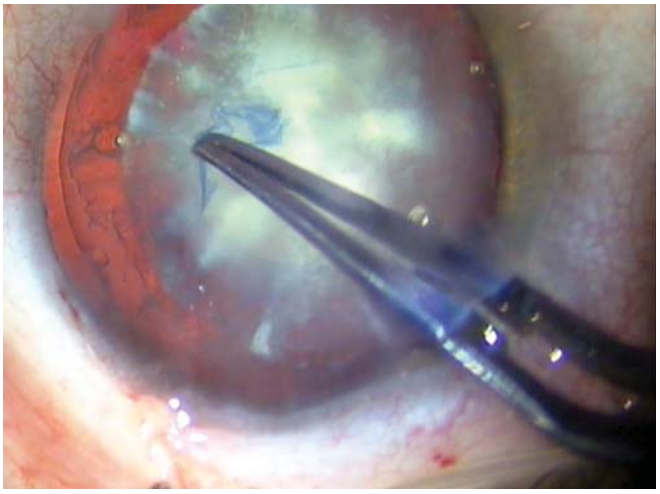

Figs 8 and 9: Six months later with stable control of the IOP, cataract removal was carried out. Here a tough capsulotomy is being performed. Capsular stain is useful not only for proper visualization of the anterior capsule in this white cataract, but also in decreasing the elasticity of the capsule in this young eye, and hence making the capsulotomy path more predictable

JAYPEE BROTHERS

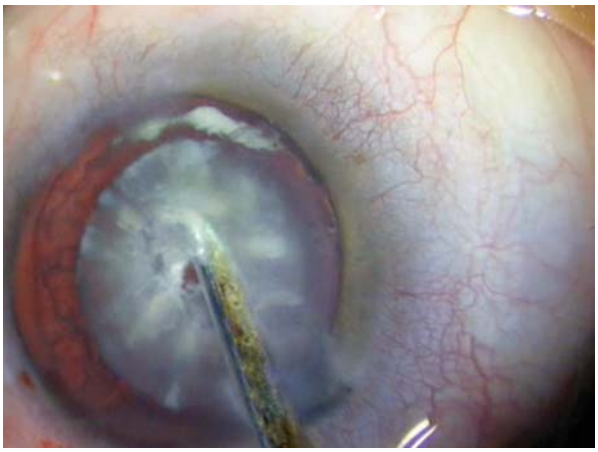

Figs 10: Simple irrigation aspiration was not easily attainable because of the complicated nature of the cataract

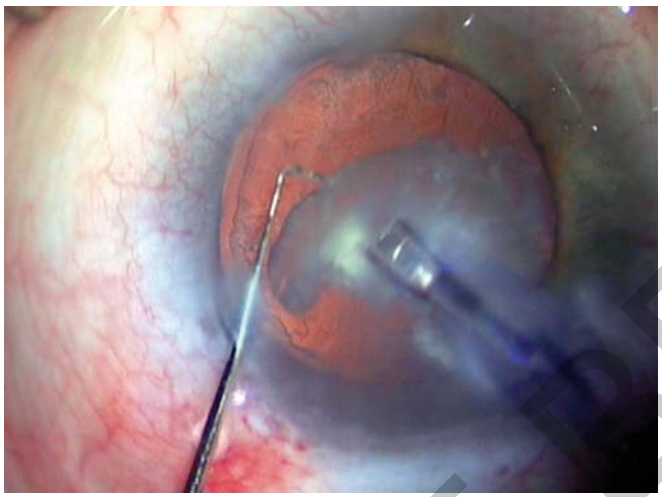

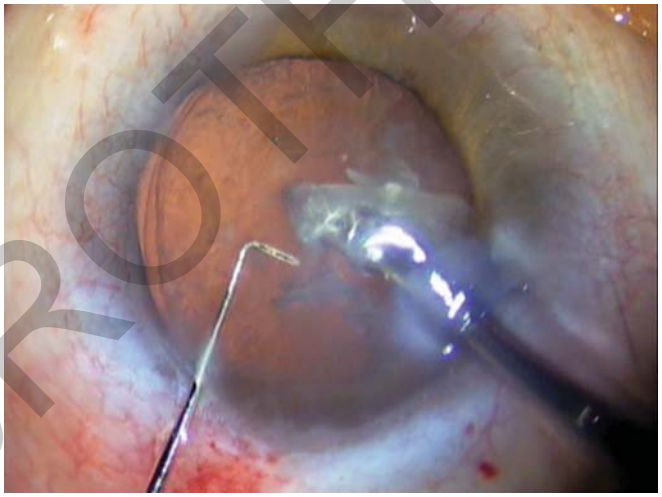

Figs 11 and 12: Soft nucleus is easily removed by phacoemulsification

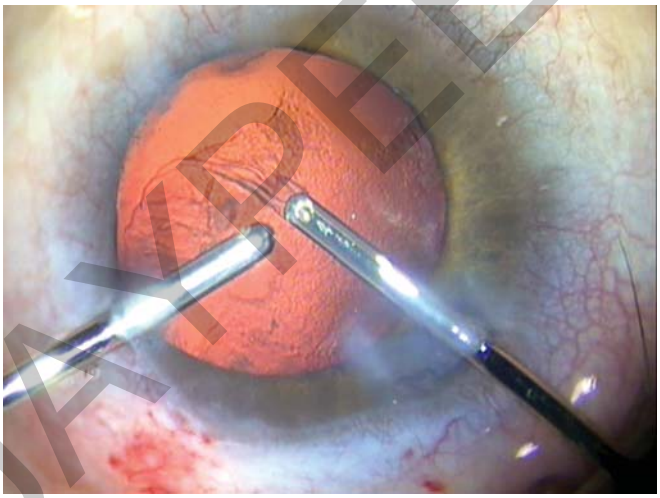

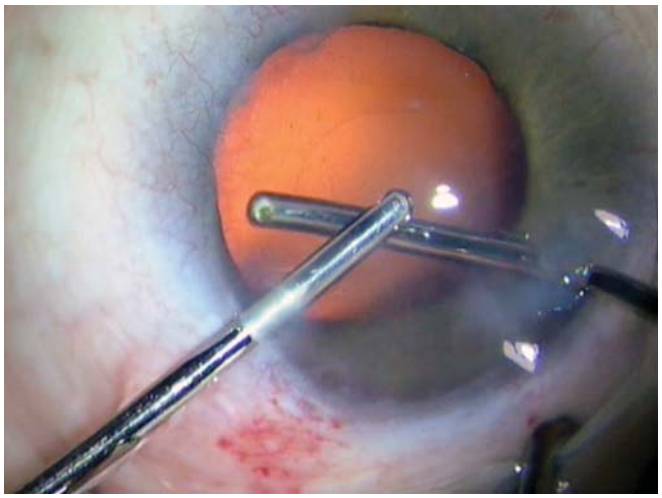

Figs 13 and 14: Bimanual irrigation aspiration is carried out, paying special attention for anterior capsule polishing to lessen the incidence of capsular opacification

JAYPEE BROTHERS

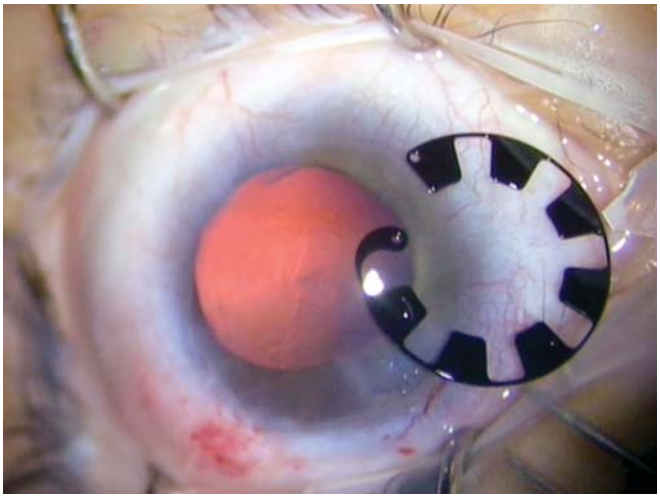

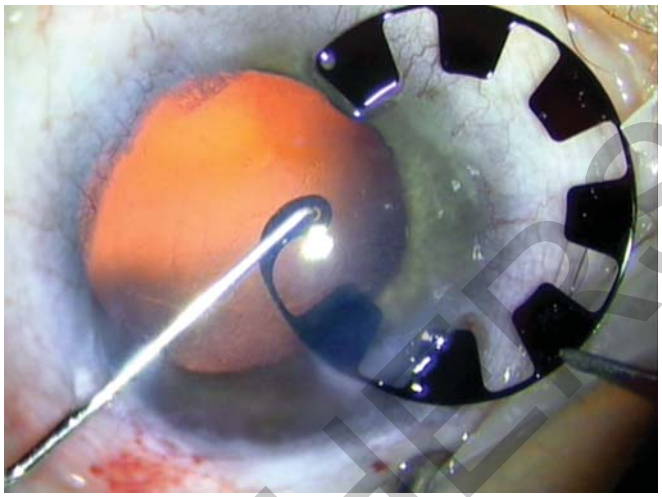

Figs 15 and 16: Two interdigitating aniridia rings made of stained PMMA are introduced in the capsular fornix. When the second ring is inserted, the pigmented segments cover the spaces between the pigmented segments of the first ring. There are several forms of these aniridia rings, which are used according to the aniridia pattern

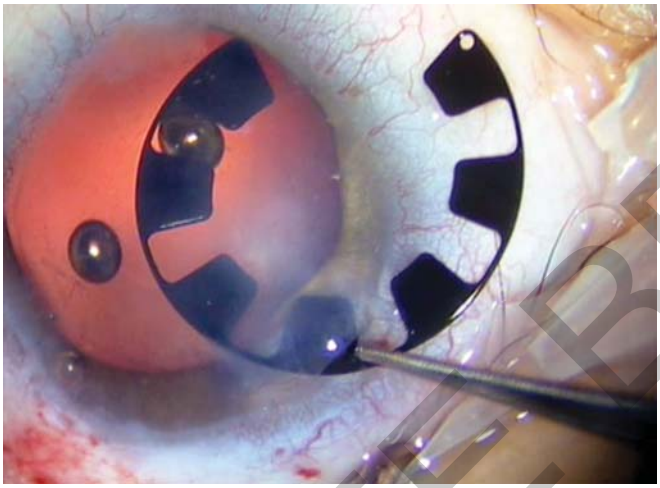

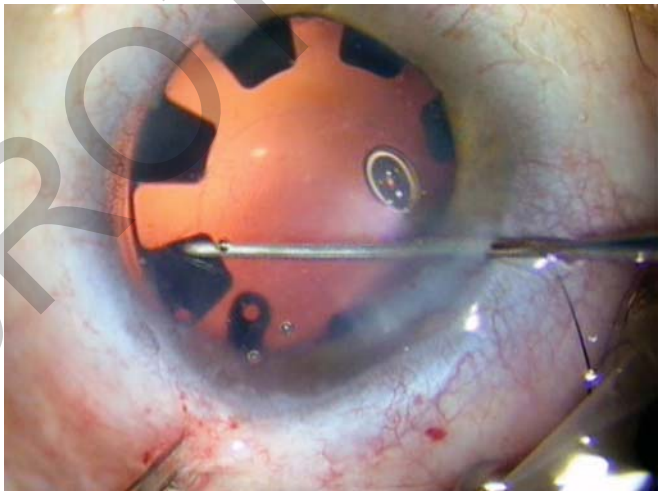

Figs 17 and 18: The first ring is nicely secured in the capsular sulcus

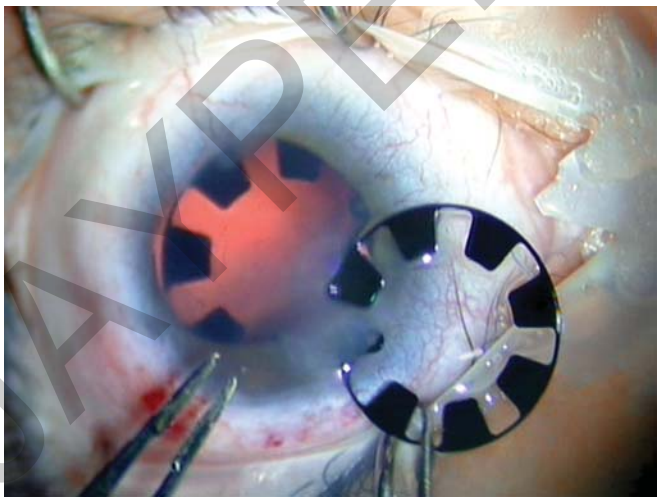

Fig. 19

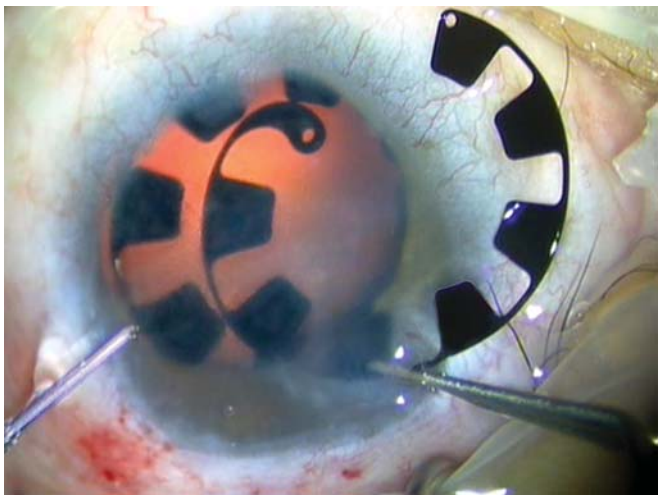

Fig. 20

JAYPEE BROTHERS

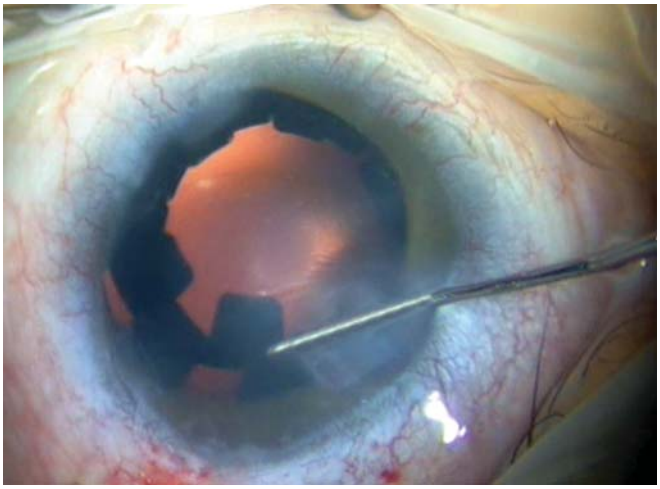

Fig. 21

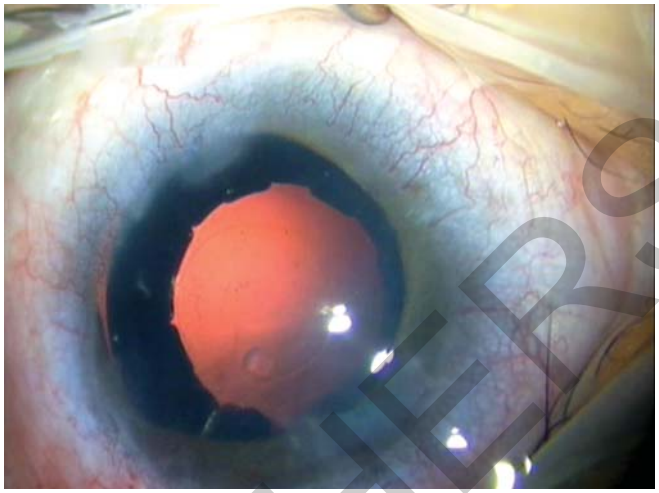

Fig. 22

Figs 19 to 22: The second ring is inserted and dialed to adjust the ring segments to form a complete iris ring

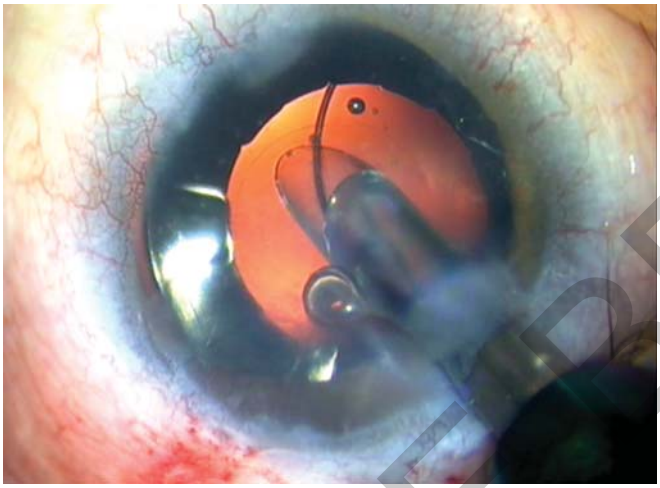

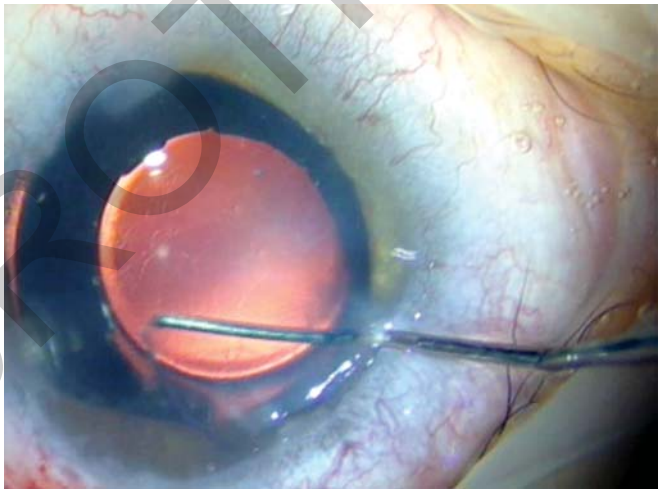

Figs 23 and 24: A 3-piece acrylic intraocular lens is implanted in the bag behind the artificial iris

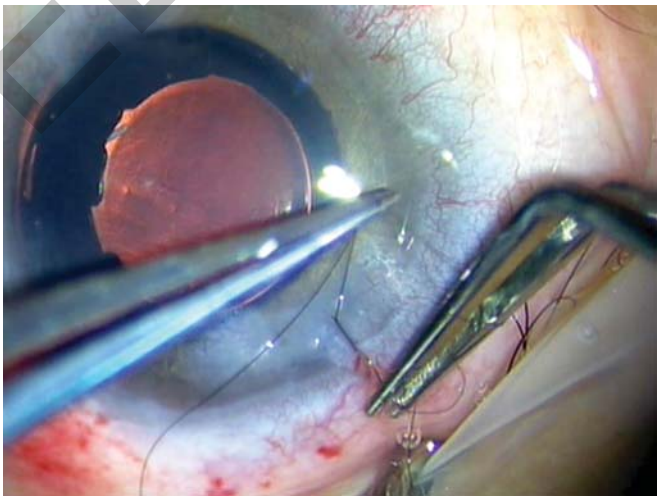

Fig. 25: Cataract wounds secured more and more by one 10/0 suture

JAYPEE BROTHERS

Non-Descent Vaginal Hysterectomy Made Easy®



Sudhir R Shah

At present working as Head of Obstetrics and Gynecology Department at Dasha Srimali Hospital, Rajkot, Gujarat. He did his postgraduate residency at VS Hospital Ahmedabad under the guidance of Dr RM Nadkarni who was an institute as far as vaginal surgery is concerned. After doing MD, he joined Government Medical College Baroda as an Assistant Professor of Obs/Gyn from 1980 to 1983. Since 1983, he is at Rajkot as a Head of Gynecology Department. He became Fellow of Indian College of Obstetrics and Gynecology in 1990. He has written a book on "Prasuti Margdarshan" in Gujarati language for the benefit of patients. He is doing non-descent vaginal hysterectomy for last 8 years and have done more than 500 NDVH with different indications. He has invented SRS short straight needle for the easy ligation of pedicles in NDVH.

Beena N Trivedi

At present working as a senior Gynecologist in Obstetrics and Gynecology Department at Dasha Srimali Hospital, Rajkot, Gujarat. She did her MD Government Medical College, Jamnagar, Gujarat in the year 1992. She has presented many papers, taken part in seminars, panel discussion at various conferences.

Dipal D Solanki

At present working as a Gynecologist in Obstetrics and Gynecology Department at Dasha Srimali Hospital, Rajkot, Gujarat. She did her MD at Government Medical College Jamnagar, Gujarat in the year 1998. She was Assistant Professor in same college up to June 2001.

Available at all medical book stores
or buy directly from Jaypee Brothers through online shopping at www.jaypeebrothers.com

or call + 91-11-32558559

JAYPEE BROTHERS
Medical Publishers (P) Ltd.
www.jaypeebrothers.com

ISBN 978-81-8448-957-6