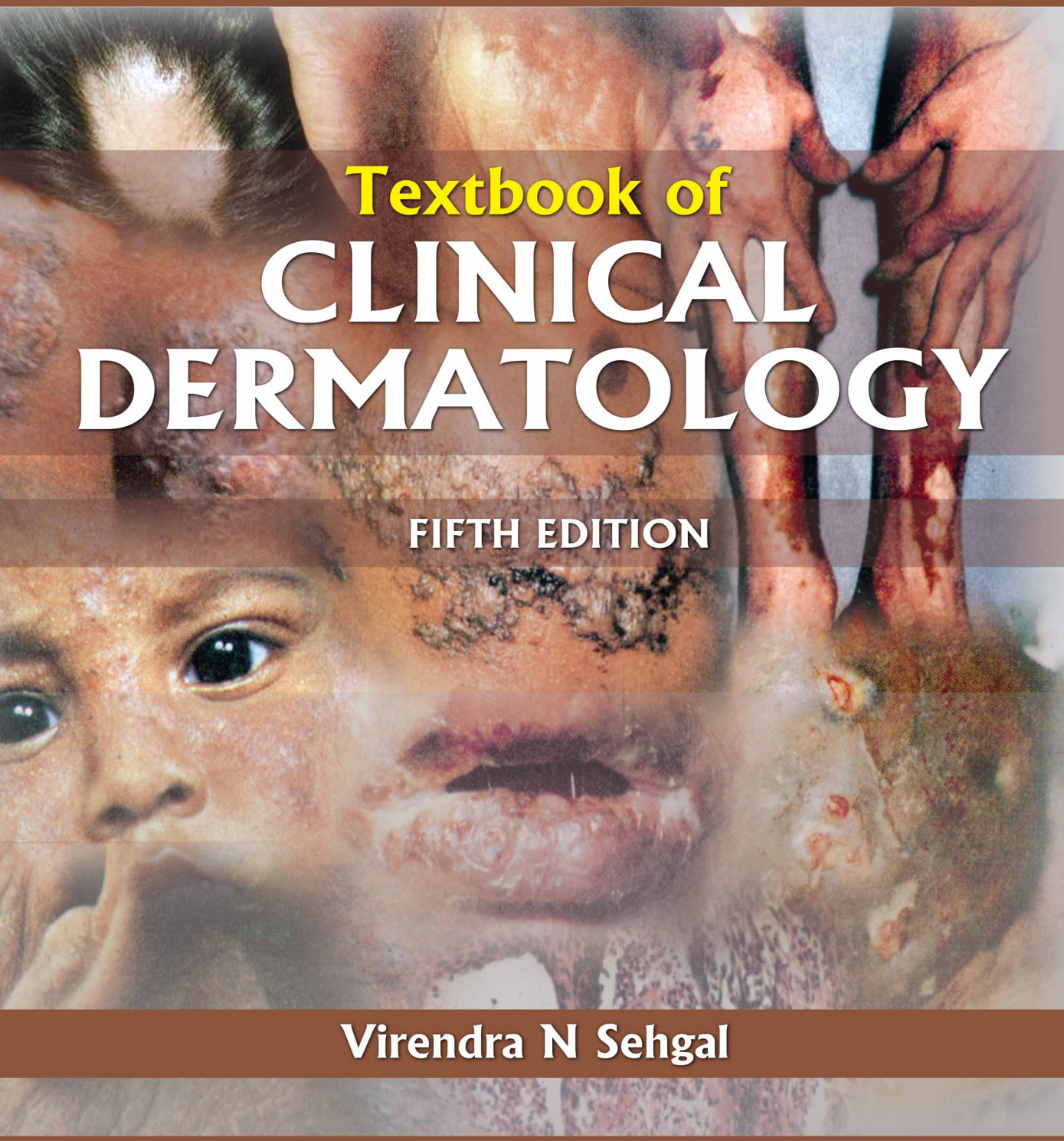

Textbook of CLINICAL DERMATOLOGY

FIFTH EDITION

Virendra N Sehgal

JAYPEE

Contents

1. Drug Reactions 1
2. Acne and Acneiform Dermatoses 12
3. Seborrhea 17
4. Rosacea 21
5. Eczema/Dermatitis 24
6. Erythroderma/Exfoliative Dermatitis 28
7. Atopic Dermatitis 31
8. Stasis Dermatitis 35
9. Hand Dermatitis 38
10. Lichen Simplex Chronicus 42
11. Pyodermas 45
12. Scabies and Pediculosis 50
13. Tinea (Dermatomycosis) 55
14. Tinea Versicolor 64
15. Candidiasis 66
16. Deep Mycotic Infection 70
17. Cutaneous Tuberculosis 75
18. Herpes Simplex 85
19. Herpes Zoster 90
20. Warts 93
21. Molluscum Contagiosum 98
22. Urticaria 100
23. Pityriasis Rosea 105
24. Vitiligo 107
25. Pemphigus 111
26. Pemphigoid 118
27. Dermatitis Herpetiformis 122
28. Lichen Planus 127
29. Lichen Nitidus 133
30. Psoriasis 135
31. Pityriasis Rubra Pilaris 149
32. Lupus Erythematosus 152
33. Scleroderma 162
34. Photodermatoses 172
35. Epidermolysis Bullosa 181
36. Ichthyoses 186
37. Neurocutaneous Syndromes 191
38. Acquired Immunodeficiency Syndrome 194
39. Mastocytosis 209

40. Amyloidosis 211
41. Porphyria 213
42. Miliaria 219
43. Squamous Cell Carcinoma 221
44. Basal Cell Carcinoma 225
45. Malignant Melanoma 227
46. Cutaneous T Cell Lymphoma 231
47. Acrodermatitis Enteropathica 234
48. Exanthems 235
49. Chickenpox 237
50. Skin Structure 239
51. Glossary of Clinical and Histopathological Terms 246
52. Alopecia Areata 251
53. Alopecia Androgenetica 256
54. Cicatricial Alopecia 262
55. Leprosy 270
56. Localized Scleroderma/Morphea 280
57. Polyarteritis Nodosa 285
58. Paraneoplastic Pemphigus/Paraneoplastic Autoimmune Multiorgan Syndrome 288
59. Pigmented Purpuric Dermatoses 291
60. Psoriasiform Dermatoses 295
61. Sexually Transmitted Diseases: Syndromic (Symptomatic) Approach 300
62. Miscellaneous Dermatoses 313

Index *343*

3 Chapter

Seborrhea

Seborrhea is a disorder characterized by erythema and yellowish, greasy scales, distributed over the sebaceous sites. It forms a part component of seborrheic diathesis that includes oily skin, acne, rosacea, seborrhea, seborrheic dermatitis, and labile personality. Both the sexes are affected, however, it is more prevalent in males. It tends to affect adolescents and adults. It is rare before puberty and reaches its peak between 18 and 40 years, when the activity of the sebaceous glands is maximum. The seborrheic dermatitis of infancy is an expression of seborrhea, due to the activity of sebaceous glands under the influence of maternal hormones.

The etiology of seborrheic dermatitis is unknown, although it is presumed that:

- Increased secretion and retention of sebum on the skin may act as an irritant and alter the epidermal function following percutaneous absorption. In some cases, however, the sebum production may be normal or reduced. Qualitative abnormalities in the composition of sebum have also been found
- *Pityrosporum ovale* colonizes the scaly epidermis and induces inflammation
- It may be associated with parkinsonism. Treatment with levodopa reduces seborrhea in addition to ameliorating the symptoms of Parkinson's disease
- Seborrhea may be a manifestation of zinc deficiency syndrome
- Severe form of seborrheic dermatitis is a frequent cutaneous manifestation of acquired immunodeficiency syndrome (AIDS).

CLINICAL FEATURES

It presents as inflammatory, erythematous scaly eruption, the margins of which may be well-defined or indistinct. The scales are yellow in color and greasy in consistency. The disease has a centrocorporeal distribution tending to localize in areas with high density of sebaceous glands, namely the scalp, forehead, eyebrows, paranasal folds, and retroauricular areas. On the trunk it involves the parasternal, interscapular, superior intergluteal folds, and pubic region. Seborrheic dermatitis has the following morphological variants, namely:

Infantile Seborrheic Dermatitis

- Cradle cap
- Seborrheic dermatitis
- Leiner's disease
- Acne neonatorum.

Seborrheic Dermatitis of Adults

- *Scalp seborrheic dermatitis*
  - Pityriasis sicca/seborrhea capitis/dandruff
  - Inflammatory seborrheic dermatitis of the scalp.

JAYPEE BROTHERS

- *Facial seborrheic dermatitis*
  - Pityriasis oleosa/oily skin
  - Marginal blepharitis
  - Acne vulgaris
  - Rosacea
  - Nasolabial seborrheic dermatitis
  - Seborrheic dermatitis of the beard.
- *Otitis externa*
- *Intertriginous/flexural seborrheic dermatitis*
- *Truncal seborrheic dermatitis*
  - Petaloid seborrheic dermatitis of the chest
  - Pityriasiform/erythematosquamous seborrheic dermatitis
  - Follicular seborrheic dermatitis of the back
- *Exfoliative dermatitis secondary to seborrheic dermatitis.*

Seborrheic dermatitis in the neonates may manifest as cradle cap. It begins in 3rd/4th week of life and presents as erythematous, adherent, waxy scaling of the scalp. It clears spontaneously by 8 to 12 months. The neonate may also develop circumscribed, yellow red, scaly plaques over the trunk, diaper area, and flexural folds. The scales are greasy and greyish white/yellow. Acne neonatorum is another expression. These manifestations of seborrheic dermatitis in infancy are due to the transplacental transfer of maternal androgens to the newborn which stimulate the sebaceous glands. The lesions subside once the maternal androgens are metabolized. Leiner's disease is due to defect in the fifth component of the complement. It presents as seborrheic dermatitis which progresses to erythroderma. Severe pyogenic infections, diarrhea, and failure to thrive are its other features. It may prove fatal.

Adult seborrheic dermatitis may begin as noninflammatory, greasy desquamation over the scalp. It is composed of desiccated sebum which is greyish white, and greasy. It may progress to inflammatory dermatitis. Perifollicular redness and scaling extends to form plaques which may remain discrete or coalesce to involve the entire scalp. It may extend beyond the frontal hairline. Both sides of pinna, the preauricular region, and the sides of the neck may also be involved. There is usually erythema, greasy scales, and crusts. Otitis externa may be its accompaniment. Facial seborrheic dermatitis may be preceded by an oily complexion, 'seborrhea oleosa'. It may progress to erythema, and scaling which involves the 'rosaceous' area. It is accompanied by episodic flushing. Telangiectasia may also develop. Acneiform papules, pustules, and cysts may appear. Rhinophyma may be an associated feature in men. The beard area may be affected and the lesions are similar to those found over the scalp. However, pustulation of the beard follicles may be prominent. Seborrheic blepharitis is an erythematous, scaly, granular inflammation of the lid margins and cilia. On the trunk, seborrheic dermatitis may manifest as either petaloid or pityriasiform dermatitis. The petaloid pattern is seen in men on the front of the chest and interscapular region. It begins as small, yellowish red, follicular papules covered with greasy scales. Extension and confluence of follicular papules give rise to figurate or circinate lesions like petals of a flower. The pityriasiform type present as oval, papulosquamous eruption resembling pityriasis rosea. The lesions, however, are more extensive than pityriasis rosea, involving the neck up to the hair margin. The flexural type of seborrheic dermatitis involves the axillae, groins, anogenital and submammary regions, and umbilicus. The lesions resemble intertrigo and present

JAYPEE BROTHERS

as diffuse, sharply marginated erythema, and greasy scaling. Crusted fissures may develop. Sweating and secondary infection predispose to a weeping dermatitis.

DIAGNOSIS

The diagnosis of seborrheic dermatitis is clinical. However, it needs to be differentiated from the following disorders which may simulate it closely.

Psoriasis: Psoriasis of the scalp may simulate seborrheic dermatitis. However, the lesions are wellcircumscribed, erythematous plaques covered with silvery, greyish white, micaceous scales.

Infective dermatitis secondary to pediculosis: The scalp should be screened for the lice and the nits.

Flexural ringworm and candidiasis: They can be excluded by microscopical examination of the scrapings from the advancing margin of the lesion for the fungus.

Pityriasis rosea: This is characterized by 'herald' patch. The lesions are oval, maculosquamous and disposed with their long axis along the lines of body cleavage.

Drug eruptions: Methyldopa, chlorpromazine, and cimetidine may produce cutaneous eruptions that mimic seborrhea. However, the history of drug intake is contributory.

TREATMENT

Seborrheic dermatitis is responsive to topical steroids. One percent hydrocortisone is usually potent enough to provide symptomatic improvement. Seborrheic dermatitis of the scalp responds to tar shampoos, 2.5 percent selenium sulfide, or 2 percent cetrimide shampoo. Systemic ketoconazole improves seborrheic dermatitis; however, it recurs when the drug is stopped.

Table 3.1: Seborrhea treatment

Diseases	*Treatment*	*Status*
Seborrheic dermatitis of the scalp	1. 2.5 percent selenium sulfide shampoo (Selsun), 2 to 3 times a week. 2. 1 percent zinc pyrithione shampoo. 3. Tar shampoo. 4. Topical application of steroid lotions on the scalp. • Flucinolone acetonide lotion (Flucort scalp lotion) • Betamethosone valerate lotion (Betnovate scalp lotion)	• Inhibits mitotic activity • Kills *Pityrosporum ovale* • Possesses antimicrobial effect • Inhibits epidermal proliferation • Useful in inflammatory and severe seborrheic dermatitis
Seborrheic dermatitis of the trunk and face	1. 1 percent hydrocortisone cream or ointment (Wycort). 2. Pragmatar cream containing 3 percent salicylic acid, 4 percent acetyl alcohol coal tar distillate. 3. 2 percent sulfur in calamine lotion. 4. 200 mg of ketoconazole daily.	• Suppresses seborrheic dermatitis Potential toxicity limits its use
Seborrheic blepharitis	1. Topical application of 10 percent sulfacetamide (Albuceol). 2. Topical application of 10 percent sulfacetamide + 0.2 percent prednisolone + 0.12 percent phenylephrine suspension.	• Monitor intraocular tension.

JAYPEE BROTHERS

Also the potential side effects of this drug make it unsuitable for long-term therapy (Table 3.1).

RECOMMENDED READING

1. Bergbrant IM, Faergemann J. The role of *Pityrosporum ovale* in seborrheic dermatitis. *Semin Dermatol* 1990;9:262-268.
2. Geen CA, Farr PM, Shuster S. Treatment of seborrheic dermatitis with ketoconazole II: Response of seborreic dermatitis of the face, scalp, and trunk to topical ketoconazole. *Br J Dermatol* 1987;116: 217-221.
3. Kligman AM, Leyden JJ. Seborrheic dermatitis. *Semin Dermatol* 1983;2:57-59.

JAYPEE BROTHERS

Textbook of

CLINICAL DERMATOLOGY

Virendra N Sehgal



One of the foremost medical scientists in the field of dermatology/venereology/leprosy, is well known for his exquisite research contributions. He has over 375 original research papers published in leading peer review national and international journals with high citation index and impact factor. He has established a school in the field of cutaneous tuberculosis, histoid leprosy, reaction in leprosy, leprosy in children, and classification of leprosy. He has authored many books, which are being studied at undergraduate and postgraduate levels. Deservingly, he was honored with Ambadyrs, Fulfords and Glaxo Orations, besides JALMA Trust Fund Oration award, Indian Council of Medical Research, Dr BC Roy National Fund award and IMA Dr RK Menda Memorial Oration award. Prof Dr KC Kandhari Foundation award was presented to him on 36th National Conference of Indian Association of Dermatologists, Venereologists and Leprologists (IADVL) in the year 2008. He is also a recipient of Life Time Achievement award of Indian Association of Leprologists (IAL) 2009.

His incessant, meritorious and academic contributions have created a place of pride for him in the literature of the specialty. He has several books to his credit ever since 1978 like:

1. Sexually Transmitted Diseases (Venereal Diseases)
2. Clinical Leprosy
3. Donovanosis (*Granuloma Inguinale*)
4. Histoid Leprosy
5. Diagnosis and Treatment of Common Skin Diseases
6. Dermatologic Surgery Made Easy

M/s Jaypee Brothers Medical Publishers (P) Ltd., New Delhi, India has a unique privilege to be associated with the publications of these books.

Available at all medical book stores
or buy directly from Jaypee Brothers through online shopping
at www.jaypeebrothers.com

or call + 91-11-32558559

JAYPEE BROTHERS
Medical Publishers (P) Ltd.
www.jaypeebrothers.com

ISBN 978-81-8448-985-9