Clinical Methods in Obstetrics & Gynecology

SECOND EDITION

PN Nobis



Foreword
Bharati Barooah

JAYPEE

Contents

Chapter 1: Female Genital Organs **1**
External Reproductive Organs 1
Vaginal Opening 2
Embryological Development 7
Lymphatic Drainage 10

Chapter 2: Menstruation, Ovulation, Fertilization and Implantation **15**
Menstrual Cycle 15

Chapter 3: The Fetus **24**
Fetal Circulation 26

Chapter 4: Development of Placenta **29**
Fetal Membranes 31
Umbilical Cord 34
Amniotic Fluid 35

Chapter 5: Types of Pelvis **36**
Gynecoid 36
Android 36
Anthropoid 37
Platypelloid 37

Chapter 6: Congenital Malformation of Female Genital Tract **39**
Congenital Anomalies of Vulva 39
Vagina 39
Failure of Canalization of the Müllerian Cords 41

Chapter 7: History Taking **43**
Gynecology 51

Chapter 8: Physical Examination **53**
General Appearance 54
Attitude 54
Gait 54

Nutrition 54
Height and Weight 54
Pulse 55
Systemic Examination 57
Obstetric Examination 59
First Grip: Fundal Grip (Grip-I) 62
Second Grip: Lateral Grip (Grip-II) 63
Third Grip: Pawlik's Grip (Grip-III) 63
Fourth Grip: Pelvic Grip (Grip-IV) 64
Auscultation of Fetal Heart 65
Vaginal Examination 66
Gynecological Examination 68

Chapter 9: Diagnosis of Pregnancy **76**
Symptoms of Pregnancy 76
Signs of Pregnancy 77
Ultrasonography 79
Summary of Symptoms and Signs of Pregnancy 81

Chapter 10: Examination and Observation in Labor **83**
Onset of Labor 83
Dilatation of Cervix 85
False Labor 85
Stages of Labor 85
Graph 87
Duration of Labor 89
History of Treatment Received Outside 89
Examination of the Patient 89
Obstetric Examination 89
Vaginal Examination 90
Diagnosis of Labor 96
Partogram 99
Clinical Examination 102

Chapter 11: Pelvic Assessment **105**
Cephalopelvic Disproportion 108

Chapter 12: Examination of Placenta and Lying in Period **110**
Examination of Placenta 111
Lying in Period 111
Lochia 113
Pulse and Temperature 113
Height of the Fundus 113

Examination of Lochia 114
Breast 115
Bladder Function 115
Examination of Vulva and Perineum 116
Postnatal Examination 116
General Health 116
General Examination 117
Systemic Examination 117
Pelvic Examination 117
Bimanual Examination 118

Chapter 13: Assessment of Fetal Well Being **119**
Fetal Movement in Intrauterine Life 119
Factors Affecting Intrauterine Fetal Activity 119
Clinical Assessment 121
Cardiotocography 123
Biparietal Diameter 125
Abdominal Circumference 125
Fetal Biophysical Profile 125
Electronic Fetal Monitoring 126
Non-stress Test 126
Contraction Stress Test 127
Amniocentesis 127
Assessment of Lung Maturity 127
Foam Stability Test (Shake Test) 127
Amniotic Fluid Bilirubin 127
Risk of Amniocentesis 128
Intrapartum Monitoring 128
Danger of Electronic Fetal Heart Monitoring and Fetal Scalp Blood Sampling 131

Chapter 14: The Newborn Immediately After Birth **132**
Basic Care of Newborn at Birth 132
Apgar Score 132
Palpation 134
Reflex 135

Chapter 15: Abnormal Presentation and Position **137**
Occipitoposterior Position 138
Face Presentation 142
Brow Presentation 144
Breech Presentation 145

Shoulder Presentation (Transverse Lie) 148
Compound Presentation 151

Chapter 16: Multiple Pregnancy **153**
Incidence 153
Placentation 153
Complications 154
Predisposing Factors 154
Diagnosis 155
Ultrasonography 155
Examination of Placenta 157

Chapter 17: Intrauterine Growth Restrictions **159**
Etiology 159
Diagnosis 160
Ultrasonography 161

Chapter 18: Intrauterine Fetal Death **162**
Causes 162
Diagnosis 163
Radiological Signs of Fetal Death 164
Ultrasonographic Signs 165

Chapter 19: Identification of High-Risk Pregnancy **166**
The Risk Factors and their Possible Effects 166
Physical Examination 168

Chapter 20: Examination of Lump Abdomen **170**
Investigation 172
Differential Diagnosis 173

Chapter 21: Menstrual Abnormality **176**
Examination of the Patient 178
Investigations 179

Chapter 22: Menopausal Problems **184**
Symptoms 184
Postmenopausal Bleeding 185

Chapter 23: Excessive Vaginal Discharge **187**
Bacterial Vaginosis 187

Chapter 24: Infertility **189**
History Taking 189
Age 189
Laboratory Investigations 191
Semen Analysis 193

Chapter 25: Genital Prolapse **195**
Cystocele 195
Rectocele 195
Uterine Prolapse 195
Enterocele 195
Classification 197
Symptoms 198
Examination of the Patient 199
Other Conditions which may Mimic Genital Prolapse 201

Chapter 26: Fibromyoma of Uterus **202**
Secondary Changes 203
Presenting Symptoms 205
On Examination 206

Chapter 27: Abnormalities of Urinary System **209**
Frequency of Micturition 209
Symptoms 209
Urinary Incontinence 209

Chapter 28: Pruritus Vulvae **213**
Dermatological Conditions 213

Chapter 29: Carcinoma Vulva **215**
Symptoms 215
On Examination 215
Staging 216

Chapter 30: Carcinoma Cervix **217**
Preinvasive Carcinoma of Cervix 217
Degree of Dysplasia/Cervical Intraepithelial Neoplasia 218
History 218
Invasive Carcinoma Cervix 220
Symptoms 220
On Examination 220
Differential Diagnosis 221

Investigations 222
Staging 222

Chapter 31: Examination of a Patient with Acute Abdomen **226**

Acute Abdomen During Pregnancy 226
Renal Causes 227
Obstetrical Causes 227
Diagnosis 229
Torsion of Ovarian Tumor 229
Uterine Fibromyoma 230
Gynecological Conditions 230
Endometriosis 232
History Taking 232
Chief Complaints 233
Physical Examination 233
Laparoscopy 234

Chapter 32: Investigative Procedures **235**

Examination of Blood 235
Investigations 235
Examination of Urine 236
Colposcopy 238
Cervical Biopsy 239
Other Diagnostic Procedures in Gynecology 240

Chapter 33: Radiology and Ultrasonography in Obstetrics and Gynecology **242**

Radiology 242
Hysterosalpingography 242
Ultrasonography in Obstetrics and Gynecology 243
Cervical Incompetence 248
USG in Gynecology 249
Computed Tomography 252
Magnetic Resonance Imaging 252

Index 253

chapter

3 The Fetus

Development of the fetus is described in three phases. The first 2 weeks from conception is termed as zygote or ovular period. From 3–8 weeks it is embryonic period and from 8th week till term is fetal period. For clinical purposes the period of gestation is calculated from the first day of last menstrual period. Embryologist uses the date of ovulation for the same calculation. Students should remember this point while going through this chapter.

During the second month of development the age of the embryo is expressed as crown-rump length (CRL) in millimeters. CRL is measured from the vertex of the skull to the mid-point between the apices of the buttocks. During the 2nd month there is increase in size of the head and formation of the limbs, face, ears, nose and eyes. The ectodermal layer of the trilaminar disc of the embryo gives rise to central nervous system, peripheral nervous system, sensory epithelium of ear, nose and eye, skin, hairs, nail, pituitary gland, mammary and sweat glands, etc. From the mesodermal layer develop muscle tissue, cartilage, bones and subcutaneous tissue. Mesoderm also gives rise to vascular system, urogenital system, spleen, cortex of the suprarenal glands. The endoderm gives rise to epithelial lining of the gastrointestinal tract, respiratory tract, urinary bladder, thyroid and parathyroid glands, liver and pancreas. Organogenesis is completed by the end of 8th week of gestation.

Fetal period is from 9th week to birth: This period of fetal development is marked by maturation of tissues and organs and rapid growth of the body. There is rapid increase in length of the fetus upto 20th week of gestation and weight increases during the last two months.

Fetal development during 8th to 12th week: During this period the face of the fetus becomes more human like. Limbs reach their relative length in comparison with the body. Primary ossification centers appear in long bones and skull; external genitalia develops and loops of intestine withdrawn into the abdominal cavity. By end of 3rd month reflex activities appear.

During 12th to 20th week: The fetus lengthens rapidly and there is little increase in weight. Lanugo hairs appear, head hairs are also visible. During the 5th month movement of the fetus is felt by the mother.

During 21st to 28th week: The skin of the fetus is red in color and wrinkled due to lack of subcutaneous connective tissue. Most of the organs are able to function. Some sounds are heard.

JAYPEE BROTHERS

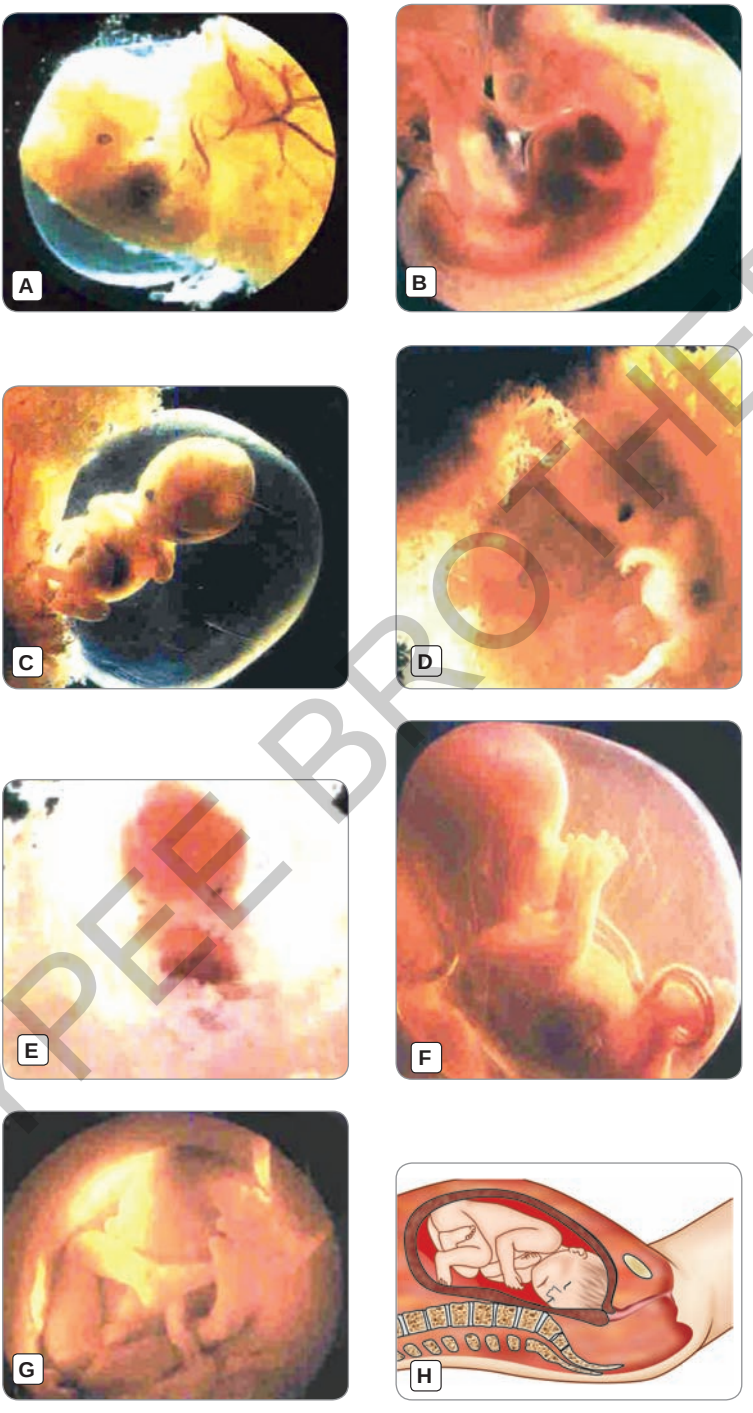

Figs 1A to H: Fetus at different stages of development. (A) Four weeks; (B) Six weeks; (C) Eight weeks; (D) Ten weeks; (E) Twelve weeks; (F) Sixteen weeks; (G) Thirty-two weeks and (H) Term fetus

JAYPEE BROTHERS

During 29th to 32nd week: Subcutaneous fat appear and the fetus starts to store fat and iron. Lanugo hairs disappear from face. Skin becomes pale.

During 33rd to 36th week: Fetus becomes round due to increased subcutaneous fat. At the end of 9th month the skull has the largest circumference. Nails reach the tip of the fingers. Planter creases are visible. Sexual characters are well-developed with testes in the scrotum.

At 40 weeks: The nails usually project beyond the fingers. The skin is pink. Lanugo hairs disappears except over the shoulders. Meconium is present in whole length of intestine. Testecles are in scrotum. Lower end of the femur begins to ossify. Length and weight of the fetus varies.

Length of fetus in different period of gestation:

9–12 weeks : 5–8 cm
17–20 weeks : 15–19 cm
25–28 weeks : 24–27 cm
29–32 weeks : 28–30 cm
33–36 weeks : 31–34 cm
37–38 weeks : 35–36 cm

❒ FETAL CIRCULATION

Fetal circulation functions in such a way that maximizes the delivery of more highly oxygenated blood to the upper body and brain, less highly oxygenated blood to the lower body and very low blood flow to the non-functional lungs.

The umbilical vein carrying oxygenated blood (about 80%) from the placenta enters the portal system of the fetus. A portion of the blood pass through the liver, then to the inferior vena cava. The majority of the blood bypass the liver through the ductus venosus and enters the inferior vena cava. Inferior vena cava also receives unsaturated venous blood (25% saturated) from the lower limbs. Blood entering into the heart through the inferior vena cava is about 70% oxygenated. About one-third of blood from inferior vena cava preferentially pass across the foramen ovale to left atrium. In left atrium this blood mixes with the small amount of blood from the pulmonary vein. From left atrium blood flows to the left ventricle and then to the ascending aorta.

Branches from proximal aorta supply the brain and upper part of the body with highly oxygenated (65%) blood. Blood entering the right atrium via the inferior vena cava mixes with blood from superior vena cava (25% saturated). Blood from right ventricle (55% saturated) enters the aorta via ductus arteriosus. The descending aorta supplies the lower body (about 60% saturated).

Changes After Birth

Something important happens within the baby after birth. Baby takes respiration immediately after birth, which inflates the lungs. Following inflation blood

JAYPEE BROTHERS

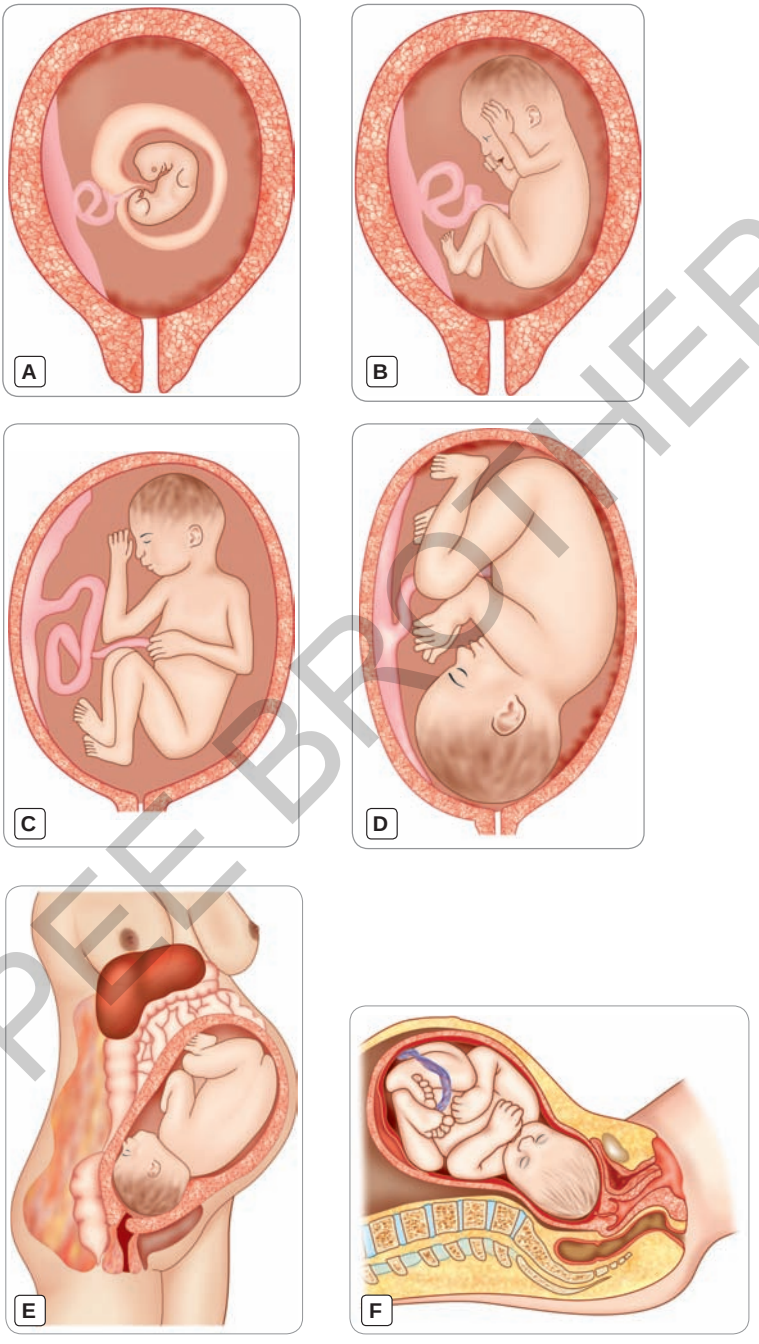

Figs 2A to F: Fetus inside uterus in different periods of gestation. (A) Six weeks; (B) Eight weeks; (C) Twelve weeks; (D) Twenty eight weeks; (E) Thirty-six weeks and (F) Full term fetus

JAYPEE BROTHERS

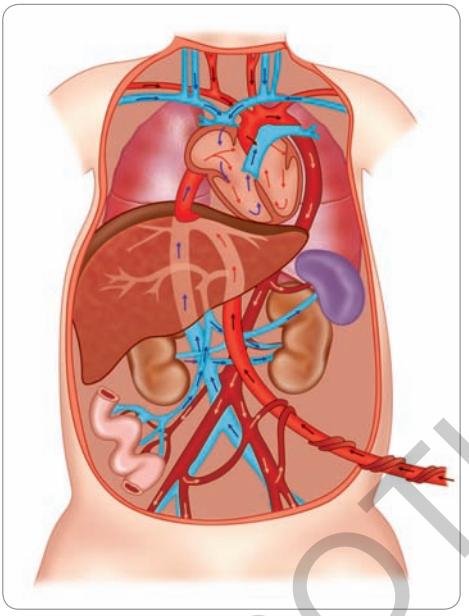

Fig. 3: Fetal circulation

rush to the lungs through the pulmonary arteries. As a result ductus arteriosus closes down and obliterates. Placental circulation stops and umbilical vein and ductus venosus collapse and then obliterate. The umbilical arteries (hypogastric arteries) no more carry blood and collapse. In adult these can be recognized as obliterated hypogastric arteries.

Oxygenated blood return from lungs to left atrium and then to left ventricle. This oxygenated blood is supplied to the whole body by the aorta. Blood from atriums enters the ventricles of both sides. No more blood from the right atrium enters the left atrium through the foramen ovale and the foramen closes down. Complete anatomical closure of foramen ovale takes few months.

JAYPEE BROTHERS

Clinical Methods in
Obstetrics & Gynecology

This is the second edition of the previous book titled "Clinical Methods in Obstetrics". In this edition gynecological portion is added and the name of the book is changed to *Clinical Methods in Obstetrics and Gynecology*. Few more chapters of obstetrics are added and the previous chapters are reviewed and elaborated. This book covers all the important aspects of obstetrics and gynecology. Basic anatomy and physiology have been discussed before starting the clinical aspect. Much importance is given on the art of history taking, which is essential for any student of medicine. Clinical examinations in normal and abnormal pregnancy, and in different gynecological disorders are described.



PN Nobis MBBS MD (OBG) is a renowned teacher of obstetrics and gynecology over the years. Presently, he is a Senior Consultant, Department of Obstetrics and Gynecology, International Hospital, Guwahati, Assam, India. He graduated from Assam Medical College, Dibrugarh, Assam, in 1974 and worked in different capacities in the medical colleges of Assam and retired voluntarily as Professor and Head, Department of Obstetrics and Gynecology, Silchar Medical College, Assam. He had several publications and has already published two books of Obstetrics and Gynecology one of which is in vernacular, meant for the midwives.

Shelving
Recommendation
**OBSTETRICS &
GYNECOLOGY**

ISBN 978-81-8448-989-7

**Available at all medical book stores
or buy directly from Jaypee Brothers through online shopping
at www.jaypeebrothers.com**

**JAYPEE BROTHERS
Medical Publishers (P) Ltd.
www.jaypeebrothers.com**