SUMMITT'S FUNDAMENTALS OF OPERATIVE DENTISTRY

A Contemporary Approach, Fourth Edition Indian Edition

Edited by
Thomas J. Hilton, DMD, MS
Jack L. Ferracane, PhD
James C. Broome, DDS, MS

Illustrations by
José dos Santos, Jr, DDS, PhD

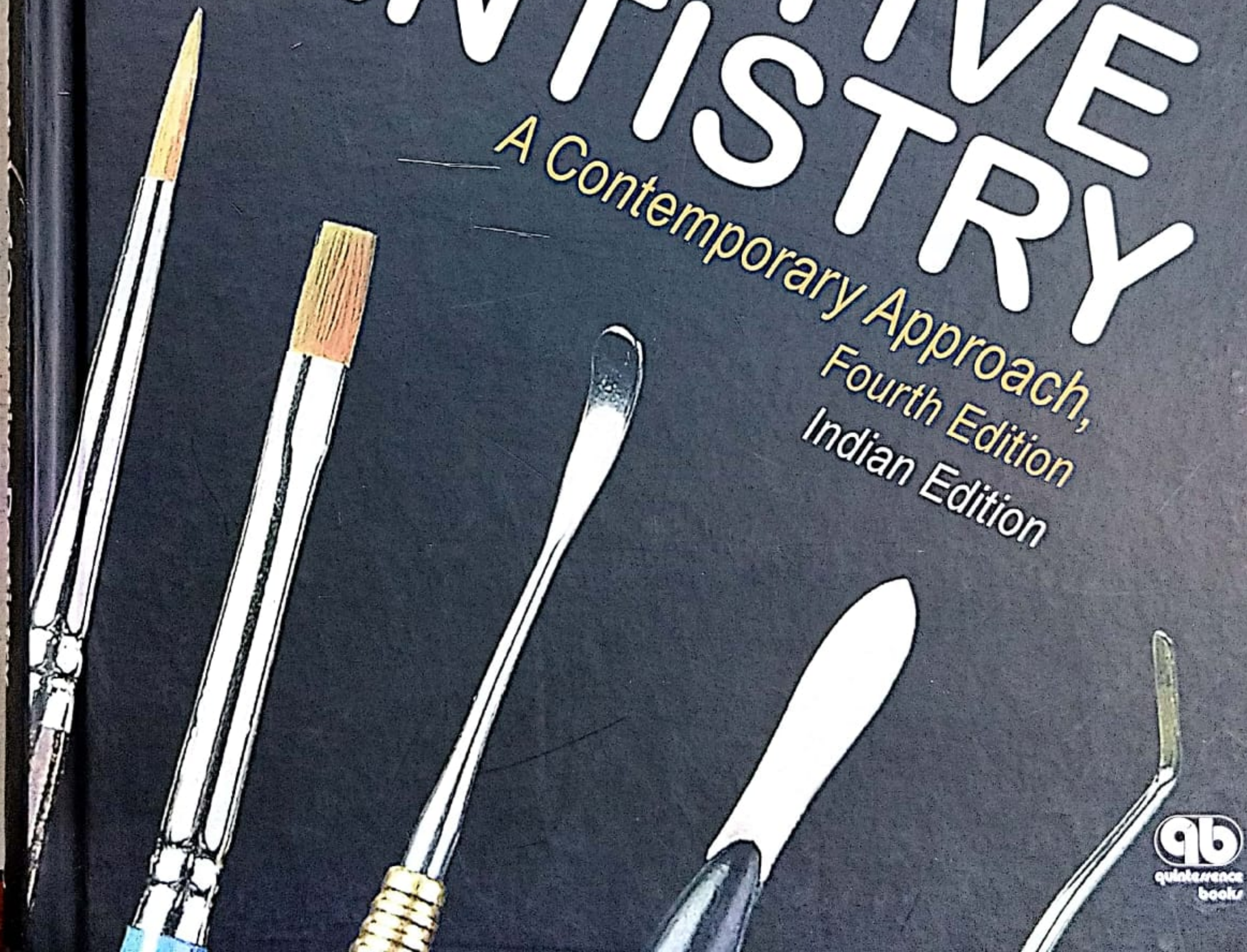

quintessence books

Contents

In Memoriam *v*
Preface *viii*
Contributors *x*

1 Biologic Considerations *1*
Terry J. Fruits, Sharukh S. Khajotia, and Jerry W. Nicholson

2 Patient Evaluation and Problem-Oriented Treatment Planning *37*
William F. Rose, Jr, Carl W. Haveman, and Richard D. Davis

3 Esthetic Considerations in Diagnosis and Treatment Planning *68*
J. William Robbins

4 Color and Shade Matching *79*
Rade D. Paravina

5 Caries Management: Diagnosis and Treatment Strategies *93*
Bennett T. Amaechi, J. Peter van Amerongen, Cor van Loveren, and Edwina A. M. Kidd

6 Pulpal Considerations *131*
Thomas J. Hilton and James B. Summitt

7 Nomenclature and Instrumentation *154*
James B. Summitt

8 Field Isolation *183*
James B. Summitt

9 Adhesion to Enamel and Dentin *207*
Lorenzo Breschi, Jack L. Ferracane, Milena Cadenaro, Annalisa Mazzoni, and Thomas J. Hilton

10 **Direct Anterior Restorations** *249*
Marcos A. Vargas, Cathia Bergeron, David F. Murchison, Joost Roeters, and Daniel C. N. Chan

11 **Direct Posterior Esthetic Restorations** *279*
Thomas J. Hilton and James C. Broome

12 **Amalgam Restorations** *324*
J. D. Overton, James B. Summitt, and John W. Osborne

13 **Diagnosis and Treatment of Root Caries** *369*
Bruce A. Matis, Carlos González-Cabezas, and Michael A. Cochran

14 **Fluoride-Releasing Materials** *380*
Deniz Cakir-Ustun, Nathaniel C. Lawson, and John O. Burgess

15 **Class 5 Restorations** *397*
J. D. Overton, Thomas J. Hilton, Mark L. LittleStar, and Clifford B. Starr

16 **Natural Tooth Bleaching** *414*
Van B. Haywood, Juliana da Costa, and Thomas G. Berry

17 **Porcelain Veneers** *448*
Jeffrey S. Rouse and J. William Robbins

18 **Anterior Ceramic Crowns** *474*
Jeffrey S. Rouse

19 **Esthetic Inlays and Onlays** *501*
Dennis J. Fasbinder, Gisele Neiva, and J. William Robbins

20 **Cast Gold Restorations** *524*
Patrice P. Fan, Richard Stevenson, and Thomas G. Berry

21 **Restoration of Endodontically Treated Teeth** *557*
James C. Broome and J. William Robbins

Index *585*

CHAPTER 1

Biologic Considerations

Terry J. Fruits
Sharukh S. Khajotia
Jerry W. Nicholson

Success in clinical dentistry requires a thorough understanding of the anatomical and biologic nature of the tooth, with its components of enamel, dentin, pulp, and cementum, as well as the supporting tissues of bone and gingiva (Fig 1-1; see also Fig 1-9a). Dentistry that violates the physical, chemical, and biologic parameters of tooth tissues can lead to premature restoration failure, compromised coronal integrity, recurrent caries, patient discomfort, or even pulpal necrosis. The principles, materials, and techniques that constitute operative dentistry are effective only when utilized within a framework based on these biologic parameters. This chapter presents a morphologic and histologic review of tooth tissues with emphasis on their clinical significance for the practice of restorative dentistry.

Enamel

Enamel provides the shape and hard, durable outer surface of teeth, which protects the underlying dentin and pulp (see Fig 1-9a). Both color and form contribute to the esthetic appearance of enamel. Much of the art of restorative dentistry comes from efforts to simulate the color, texture, translucency, and contours of enamel with synthetic dental materials, such as resin composite or porcelain. Nevertheless, the lifelong preservation of the patient's own enamel is one of the defining goals of the discipline of operative dentistry. Although enamel is capable of lifelong service, its crystalline mineral makeup and rigidity, exposed to an oral environment of occlusal, chemical, and bacterial challenges, make it vulnerable to acid demineralization, attrition (wear), and fracture (Fig 1-2). Mature enamel is unique compared with other tissues because, besides alterations in its mineral content, repair or replacement can only be accomplished through dental therapy.

Permeability

At maturity, enamel is 96% inorganic hydroxyapatite mineral by weight and more than 86% hydroxyapatite mineral by volume. Enamel also contains a small volume of organic matrix, as well as 4% to 12% by volume water, which is contained in the intercrystalline spaces and in a network of micropores opening to the external surface.[1] These microchannels form a dynamic connection between the oral cavity and the pulpal interstitial space and dentinal tubule fluids.[2] Various fluids, ions, and low–molecular weight substances, whether deleterious, physiologic, or therapeutic, can diffuse through the semipermeable enamel. Therefore, the dynamics of acid demineralization, reprecipitation or remineralization, fluoride uptake, and vital bleaching therapy are not limited to the surface but are active in three dimensions.[3–6] When teeth become dehydrated, as from nocturnal mouth breathing or rubber dam isolation for dental treatment, the empty micropores make the enamel appear chalky and lighter in color (Fig 1-3). The condition is reversible with return to the "wet" oral environment. There is some evidence that the permeability of the enamel decreases with age and may be affected by various dental procedures, such as tooth whitening, acid etching, or the physical removal of the outermost layer of enamel.[7–9]

Lifelong exposure of semipermeable enamel to the ingress of elements from the oral environment into the mineral structure of the tooth results in coloration intensity and resistance to demineralization. The yellowing of older teeth may be attributed to thinning or increased translucency of enamel, accumulation of trace elements in the enamel structure, and perhaps the sclerosis of mature dentin. This yellowing may be treated conservatively with at-home or in-office bleaching. The enamel remineralization process benefits from the incorporation of fluoride from water

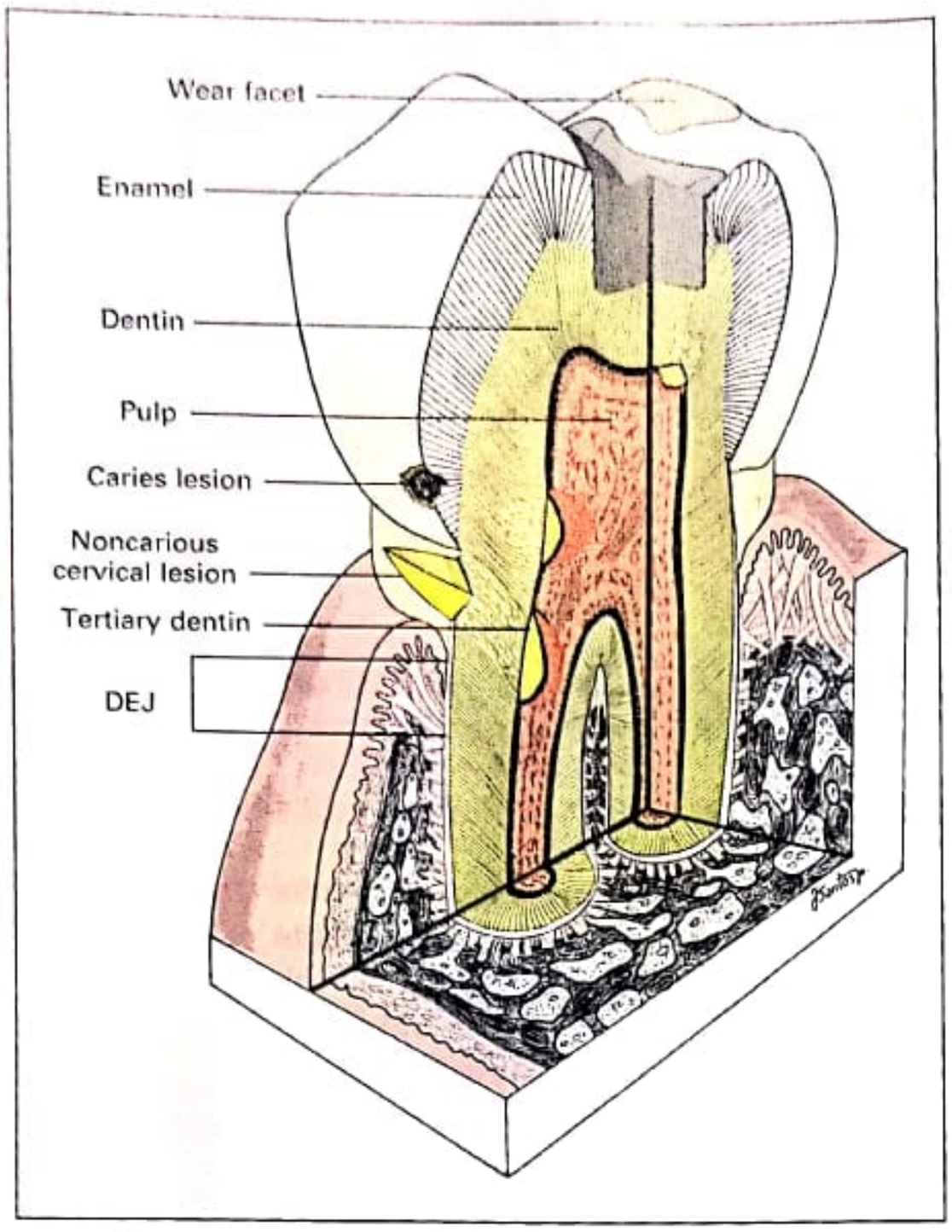

Fig 1-1 Component tissues and supporting structures of the tooth. DEJ—dentinoenamel junction.

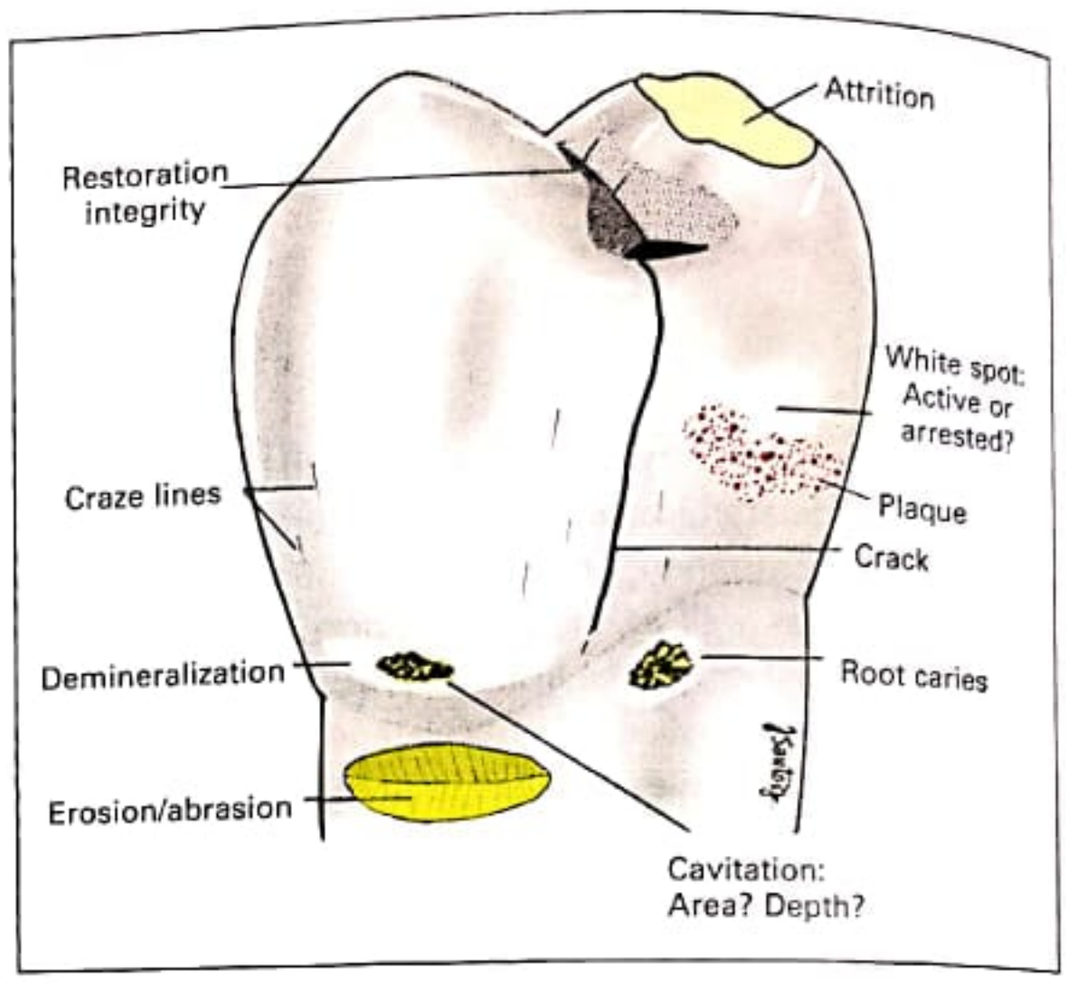

Fig 1-2 Observations of clinical importance on the tooth surface.

sources or toothpaste and from the fluoride concentrated in the biofilm (plaque) that adheres to enamel surfaces. Enamel damaged by acid-producing biofilm bacteria can be repaired by remineralization with fluoride, which increases the rate of conversion of hydroxyapatite into more stable and less acid-soluble crystals of fluorohydroxyapatite or fluoroapatite.[10] There has been a considerable amount of research recently directed at further enhancing the effectiveness of fluoride remineralization by creating new delivery systems that increase the available calcium and phosphate required to form fluorohydroxyapatite and fluoroapatite.[11] With aging, color (hue) is intensified, but acid solubility of enamel, pore volume, water content, and permeability are reduced, although a basic level of permeability is maintained.[12]

Clinical appearance and defects

The dentist must pay close attention to the surface characteristics of enamel for evidence of pathologic or traumatic conditions. Key diagnostic signs include color changes associated with demineralization, cavitation, excessive wear, morphologic faults or fissures, and cracks (see Fig 1-2).

Color

Enamel translucency is directly related to the degree of mineralization, and its color is primarily a function of its thickness and the color of the underlying dentin. From approximately 2.5 mm at cusp tips and 2.0 mm at incisal edges, enamel thickness decreases significantly below deep occlusal fissures and tapers to become very thin in the cervical area near the cementoenamel junction (CEJ). Therefore, the young anterior tooth has a translucent gray or slightly bluish hue near the incisal edge. A more chromatic yellow-orange shade predominates cervically, where dentin shows through thinner enamel. Coincidentally, in about 10% of teeth, a gap between enamel and cementum in the cervical area leaves vital, potentially sensitive dentin completely exposed.[13]

Anomalies of development and mineralization, extrinsic stains, antibiotic therapy, and excessive fluoride can alter the natural color of the teeth.[14] However, because caries is the primary disease threat to the dentition, enamel discoloration related to demineralization caused by acid from a few microorganisms, primarily mutans streptococci, within biofilm[15] is a critical diagnostic observation. Subsurface enamel porosity from demineralization is manifested clinically as a milky white



ISBN 978-81-922977-2-9