Peyman-Prajna
Principles & Practice of
Ophthalmology

Volume 1

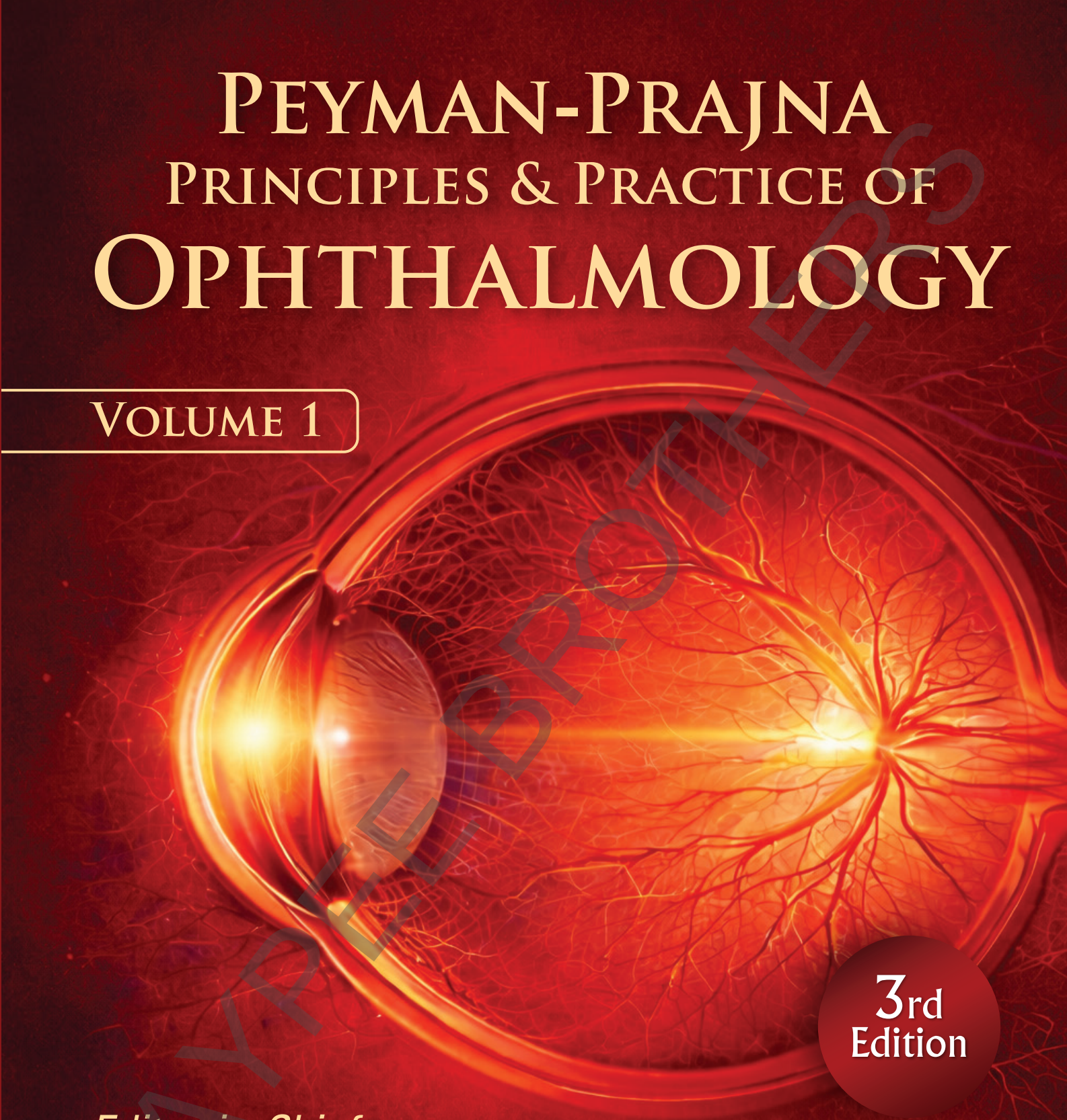

3rd Edition

Editor-in-Chief
N Venkatesh Prajna

Foreword
Gholam A Peyman

JAYPEE

JAYPEE BROTHERS

Contents

VOLUME 1

Part 1: Basic Sciences and Ocular Pathology

N Venkatesh Prajna, Anita SY Chan

Section 1: Basic Sciences

N Venkatesh Prajna

1. **Anatomy and Embryology of the Eye** 3
   Kay T Khine, David Fleischman
2. **Physiology of the Eye** 22
   Manali Hazarika, N Venkatesh Prajna
3. **Ocular Biochemistry** 65
   Divya Janakiraman, N Venkatesh Prajna
4. **Ocular Pharmacotherapy** 91
   Sankalp Singh Sharma, N Venkatesh Prajna
5. **Ocular Microbiology** 128
   Lalitha Prajna, Suneetha Viswanathaiah, Rameshkumar Gunasekaran
6. **Immunology of the Eye** 176
   K Dharmalingam
7. **Clinically Oriented Ophthalmic Genetics** 188
   Sunita Mohan, Shisong Rong, Brinda Ramanathan, Deepika Karthik Kumar, Govindasamy Kumaramanickavel

Section 2: Ocular Pathology

Anita SY Chan

8. **Basic Principles of Ophthalmic Pathology and Molecular Ophthalmic Pathology** 223
   Anita SY Chan, Deepak P Edward
9. **Ophthalmic Pathology** 241
   Martina C Herwig-Carl, Karin U Loeffler

JAYPEE BROTHERS

10. Practical Contributions of the Ophthalmic Pathologist to Ocular Oncology 255
Hind Alkatan, Deepak P Edward

10.1 Orbital Tumors 255
Hind Alkatan

10.2 External Tumors (Eyelid) 266
Hind Alkatan

10.3 Ocular Surface Tumors 270
Hind Alkatan

10.4 Intraocular Tumors 275
Deepak P Edward

Part 2: Clinical Examination

N Venkatesh Prajna

11. Clinical Examination of the Anterior Segment 291
Geetha Iyer, Shweta Agarwal, Bhaskar Srinivasan

12. Clinical Examination of the Posterior Segment 299
Parag K Shah, VR Saravanan

Part 3: Optics and Refraction

Joseph M Miller

13. Optics of Clinical Refraction 315
Joseph M Miller

Part 4: Vision Rehabilitation

August Colenbrander

14. Why Vision Rehabilitation 343
August Colenbrander, Donald C Fletcher

15. Supporting How the Eyes Function 352
August Colenbrander, Tiffany Chan

16. Supporting How the Person Functions 365
Orli Weisser-Pike, Monica S Perlmutter

Part 5: Conjunctiva and Cornea

N Venkatesh Prajna, Naveen Radhakrishnan

17. Corneal Examination and Investigations 381
Ashish Kumar, Manoranjan Das, Arun Kumar Panigrahi

JAYPEE BROTHERS

18. Infectious Conjunctivitis 425
Jeremy JSL Hoffman, Alice L Milligan, Matthew J Burton

19. Conjunctival Inflammatory Disorders 446
Aravind Roy, Paavan Kalra, Prashant Garg

20. Pterygium 462
Navneet Sidhu, Amreen Aslam, Srikanta Kumar Padhy, Murugesan Vanathi

21. Ocular Surface Disorders 480
Virender Singh Sangwan, Abha Gour, Monica Lohchab, Shilpa Das

22. Dry Eye 510
Manumuraleekrishna, Noopur Gupta, Murugesan Vanathi, Radhika Tandon

23. Infectious Keratitis 525
Naveen Radhakrishnan, N Venkatesh Prajna

23.1 Bacterial Keratitis 525

23.2 Fungal Keratitis 534

23.3 *Acanthamoeba* Keratitis 546

24. Viral Keratitis 551
Namrata Sharma, Prafulla K Maharana, Pranita Sahay, Gunjan Saluja, Tushar Agarwal

25. Immunological Disorders of Cornea 567
Jeremy D Keenan

26. Corneal Ectatic Disorders 577
Rohit Shetty, Vaitheeswaran G Lalgudi, Pallak Kusumgar, Harsha Nagaraja, Pooja Khamar

27. Corneal Degenerations 595
Saujany Vadoothker, Bennie H Jeng

28. Corneal Dystrophies 605
V Romano, B Steger, CE Willoughby

29. Eye Banking 620
Maria A Woodward, Jennifer Y Li

30. Corneal Transplantation 631
Jennifer Rose-Nussbaumer, Ariana Austin

31. Contact Lenses 652
Late Rajeswari Mahadevan, Madhumathi Subramanian, Prema Padmanabhan

32. Refractive Surgeries 674
Revathi Rajaraman, Prabhu V, Vikram Vaidee, Mangala P, Seema Ramakrishnan, Devi Rosette

JAYPEE BROTHERS

Part 6: The Lens, Cataract and Its Management

Uday Devgan

33. **Femtosecond Laser in Cataract Surgery** 717
Shawn R Lin, D Rex Hamilton

34. **Choosing the Best Intraocular Lens for the Patient's Needs** 729
Todd Driver, Uday Devgan

35. **Astigmatism Vectors in Cataract Surgery** 740
Cameron Pole, Uday Devgan

36. **Management of the Small Pupil during Cataract Surgery** 746
Sandip Suresh, Uday Devgan

37. **IOL Calculations: The Past, the Present and the Future** 752
Aazim A Siddiqui, Uday Devgan, Albert S Jun

38. **Optical Coherence Tomography Abnormalities of the Retina that may Affect the Outcome of Cataract Surgery** 756
David Xu, Juliet Essilfie, David Sarraf

39. **Intraoperative Aberrometry** 765
Shawn R Lin, D Rex Hamilton

40. **Managing a Ruptured Capsule during Cataract Surgery** 774
Juliet Essilfie, David Xu, Jean Pierre Hubschman

41. **Challenging Cataract Cases: Posterior Polar** 780
Erika Tanaka, Kevin M Miller

42. **Challenging Cataract Cases: Dense Brunescent Cataracts and White Cataracts** 787
Elisha Garg, John Bartlett

43. **Challenging Cataract Cases: Highly Myopic and Hyperopic Eyes** 798
Benjamin C Campbell, Uday Devgan

44. **Challenging Cataract Cases: Weak Zonules, Pseudoexfoliation, and Traumatic Cataracts** 806
Eric Shieh, Kevin M Miller

Part 7: Retina and Vitreous

Jayanth Sridhar

45. **Dye-Based Angiography (Fluorescein Angiography and Indocyanine Green) and Polypoidal Choroidal Vasculopathy** 819
Spencer Barrett, Giovanni Staurenghi, Ferdinando Bottoni, Andrea Giani, Marco Pellegrini, Alessandro Invernizzi, Federico Corvi, Hong-Uyen Hua

46. **Optical Coherence Tomography** 864
Kai Seely, Hong-Uyen Hua, A Yasin Alibhai, Eric M Moult, James G Fujimoto, Nadia K Waheed

JAYPEE BROTHERS

47. Fundus Autofluorescence and Multicolor Imaging 892
Yaqoob Qaseem, Steffen Schmitz-Valckenberg, Monika Fleckenstein, Frank G Holz, Kirk Hou

48. Diabetic Retinopathy and Macular Edema 908
Michelle Ko, Weilin (Melissa) Song, Marques JP, Cunha-Vaz J, Julie Kwon

49. Retinal Vascular Occlusion 924
Weilin (Melissa) Song, Katrin Fasler, Pearse A Keane, Julie Kwon

50. Age-Related Macular Degeneration 958
Weilin (Melissa) Song, Tiarnan Kennan, Emily Chew, Julie Kwon

51. Central Serous Chorioretinopathy and Pachychoroid Disease 980
Weilin (Melissa) Song, Kunal K Dansingani, Orly Gal-Or, K Bailey Freund, Kirk Hou

52. Pathologic Myopia 1008
Celine Chaaya, Nimesh A Patel, Colin S Tan, Srinivas R Sadda

53. Hereditary Macular Dystrophies 1026
Jesse D Sengillo, Etienne M Schönbach, Peter Charbel Issa, Hendrik PN Scholl

54. Peripheral Retinal Degenerations 1057
Jesse D Sengillo, Joseph M Simonett, Mark E Pennesi

55. Tumors and Paraneoplastic Disorders 1101
Maura Di Nicola, Tara A McCannel, Vidal Soberon

56. Vitreoretinal Interface Diseases of the Macula 1122
Seyyedehfatemeh Ghalibafan, Khaled Gowaily, Shayaan Kaleem, Landon J Rohowetz, Nicolas A Yannuzzi

57. Rhegmatogenous Retinal Detachment 1148
Jayanth Sridhar, Patrick Oellers, Dean Eliott

58. Principles of Vitreoretinal Surgery 1160
Jayanth Sridhar, Ferenc Kuhn, Agnieszka Kudasiewicz-Kardaszewska

VOLUME 2

Part 8: Glaucoma

Pradeep Ramulu

59. Examining the Eye for Glaucoma 1187
Alejandro Marin, John McSoley, Ta Chen Peter Chang

60. Visual Testing for the Diagnosis and Monitoring of Glaucoma 1196
Chris A Johnson

61. Optic Nerve Head and Retinal Nerve Fiber Layer Imaging in the Diagnosis and Management of Glaucoma 1217
Harsha L Rao, Zia S Pradhan, Narendra K Puttaiah

JAYPEE BROTHERS

62. Open-Angle Glaucoma: Epidemiology, Natural History, and Clinical Course under Optimal Care 1230
Dimitrios Giannoulis, Evangelia Papakonstantinou, Panagiota Ntonti, Christina Keskini, Rodanthi Christina Bartzoulianou, Eleftherios Anastasopoulos, Fotis Topouzis

63. Primary Angle-Closure Glaucoma: Epidemiology, Natural History, and Clinical Course under Optimal Care 1244
Srinivasan Kavitha, Usha Tejaswini S

64. Medical Treatment of Glaucoma 1260
Emily M Schehlein, Alan L Robin

65. Office-Based Laser Treatments for Glaucoma 1274
Moon Jeong Lee, Natasha Nayak Kolomeyer, L Jay Katz

66. Secondary Glaucomas: Modification of Treatment Algorithms to Maximize Outcomes 1282
Tamara Zompa, S Fabian Lerner

67. Trabeculectomy: Benefits, Techniques, and Management of Complications 1301
Paul R Healey

68. Surgical Alternatives to Trabeculectomy in the Management of Glaucoma 1314
Cecilia A Hernandez, Sabita Ittoop, Malik Y Kahook, Leonard K Seibold

Part 9: Pediatric Ophthalmology and Strabismus

Michael O'Keeffe

69. Corneal Disorders in Children 1333
Samer Hamada, Sundas Maqsood

70. Refractive Error in Childhood 1353
Zachary P Elkin, Scott R Lambert

71. Amblyopia 1363
Eibhlín Mc Loone, Pamela Anketell

72. Pediatric Cataract Surgery 1372
Michael O'Keeffe, Caitriona Kirwan

73. Childhood Glaucoma 1379
Maria Papadopoulos, Peng Tee Khaw

74. Congenital Abnormalities of the Retina 1394
Sarah Hull, Anthony T Moore

75. Retinopathy of Prematurity 1409
Ayad Shafiq

76. Retinoblastoma 1421
Stathopoulos C, Munier FL

77. The Chiasm in Childhood 1439
Richard Bowman, David Taylor

JAYPEE BROTHERS

78. Nystagmus 1450
Paolo Nucci, Matteo Scaramuzzi

79. Examination of a Child with Concomitant Strabismus 1460
Perumalsamy Vijayalakshmi, Sathya T Ravilla

80. Congenital Esotropia 1480
Ian Marsh

81. Accommodative Esotropia 1487
Glen A Gole, Jayne E Camuglia

82. Paralytic Strabismus in Childhood 1499
Michael X Repka

Part 10: Scleritis and Uveitis

SR Rathinam

83. Uveitis Nomenclature, Classification, and Clinical Workup in Uveitis 1511
SR Rathinam, Sunny Lisa

84. Infectious Uveitis 1528
Yunhua Loo, Soon-Phaik Chee

85. Noninfectious Uveitis 1557
Ilknur Tugal-Tutkun, Hilal Eser Ozturk

86. Uveitis Masquerades 1581
Janet L Davis, Steven S Saraf

87. Investigations in Uveitis 1598
Aniruddha Agarwal, Kanika Aggarwal, K Srinivasarao, Vishali Gupta

88. Local and Systemic Immunosuppression for Uveitis: From Conventional to Targeted Therapies 1609
Robert D Nguyen, John A Gonzales

89. The Eye and Selected Rheumatic Diseases: A Rheumatology Perspective 1628
Sung Jae Yang, Sherveen Salek, James T Rosenbaum

Part 11: Neuro-Ophthalmology

Prem S Subramanian

90. Neuro-Ophthalmic Examination 1641
Prem S Subramanian

91. Swollen Optic Nerve 1651
Michael Jordan, Collin M McClelland, Michael S Lee

92. Common Optic Neuropathies 1664
Kimberly K Gokoffski, Vivek R Patel, Prem S Subramanian

JAYPEE BROTHERS

93. Neuroimaging in Neuro-Ophthalmology 1683
Zoë R Williams, Edward Lin

94. Systemic Diseases and Neuro-Ophthalmology 1714
M Tariq Bhatti

95. Diplopia 1738
Marc A Bouffard, Dean M Cestari

96. Nystagmus and Disorders of Gaze 1754
Roksolyana Tourkevich, Anthony Brune, Daniel Gold

97. Functional Vision Loss 1770
Greg Van Stavern, Nathan Kung, James Liu

98. Topical Diagnosis of Visual Field Loss 1781
Kimberly Winges, Imran Jivraj

99. Vascular Diseases of the Central Nervous System and Orbit 1812
Courtney E Francis, Jocelyn Lam, Roberta Dalley

100. Disorders of the Pupil 1827
Aki Kawasaki, Yanjun Chen

Part 12: Orbit and Oculoplasty

Erin M Shriver

101. Anatomy and Examination of the Eyelid, Orbit, and Adnexa 1841
Suzanne W van Landingham, Mark J Lucarelli

102. Elevating Excellence: Surgical Management of Ptosis and Dermatochalasis 1855
Rolika Bansal, Hritika Hosalkar, Bobby S Korn, Don O Kikkawa

103. Eyelid Malposition 1873
Azraa Chaudhury, Monica Ertel, Gary J Lelli

104. Eyelid Neoplasms: Evaluation and Management 1883
Tracy Lu, Oded Sagiv, Thomas J Kandl, Sudip Thakar, Bita Esmaeli

105. Orbital Tumors and Vascular Abnormalities 1900
Honeylen Maryl T Teo, Hakan Demirci

106. Lacrimal Gland Tumors: Evaluation and Management 1920
Catherine J Choi, David T Tse

107. Orbital and Periorbital Infections: Evaluation and Management 1930
Md Shahid Alam, Bipasha Mukherjee

108. Orbital Inflammatory Disorders: Evaluation and Management 1946
Natalie Wolkow, Suzanne K Freitag

JAYPEE BROTHERS

109. Thyroid Eye Disease: Evaluation and Management 1958
Anthony S Wong, Pimkwan Jaru-Ampornpan, Shannon S Joseph, Erin M Shriver, Raymond S Douglas

110. Orbitofacial Trauma 1977
Marie Somogyi, Ivan Vrcek, Vikram Durairaj

111. The Anophthalmic Socket 1990
Nina M Farivari, Louise A Mawn

112. Diseases of the Lacrimal Drainage System 1999
Mohammad Javed Ali

113. Congenital Disorders of the Eyelid, Orbit, and Adnexa 2017
Jessica Chang

114. Periocular Aesthetics 2030
Stuti Misty Tanya, Merve Kulbay, Kasturi Bhattacharjee, Sara Tullis Wester, Jill Foster, Erin M Shriver, Femida Kherani

114.1 Principles of Oculofacial Aesthetics 2030

114.2 Oculofacial Skincare and Energy-Based Rejuvenation 2037

114.3 Contemporary Oculofacial Aesthetic Interventions 2058

Part 13: Miscellaneous

N Venkatesh Prajna

115. Sterilization and Aseptic Practices in an Ophthalmic Operation Theater 2073
Lalitha Prajna

116. Management of Ophthalmic Trauma 2083
Fasika A Woreta, James T Banta, Ferenc Kuhn, Nicholas R Mahoney

117. Community Perspectives to Ophthalmology 2102
Thulasiraj Ravilla, Allen Foster

Index *2123*

JAYPEE BROTHERS

10

PART

Scleritis and Uveitis

SR Rathinam

OUTLINE

83. Uveitis Nomenclature, Classification, and Clinical Workup in Uveitis
84. Infectious Uveitis
85. Noninfectious Uveitis
86. Uveitis Masquerades
87. Investigations in Uveitis
88. Local and Systemic Immunosuppression for Uveitis: From Conventional to Targeted Therapies
89. The Eye and Selected Rheumatic Diseases: A Rheumatology Perspective

JAYPEE BROTHERS

83

CHAPTER

Uveitis Nomenclature, Classification, and Clinical Workup in Uveitis

SR Rathinam, Sunny Lisa

INTRODUCTION

Uveitis refers to the inflammatory process that predominantly affects the uveal tissues with or without associated damage to the cornea, lens, retina, vitreous, and optic nerve. In several instances, the occurrence of uveitis can indicate underlying systemic diseases that affect other parts of the body and in some cases, may even be the first clinical evidence of such diseases. Hence, ophthalmologists have a crucial role in not only treating the ophthalmic condition, but also helping the early diagnosis of systemic disease.[1-4]

Causes of uveitis in different population groups vary, because of variations in climatic, socioeconomic, demographic, genetic, and systemic morbidity patterns.[5] The prevalence and severity of diseases in developing, as compared to developed countries, can differ, due to factors such as lack of primary healthcare screening, high healthcare cost, lack of insurance, and poor compliance. Uveitis experts, in addition to mastering clinical skills, should also sharpen their knowledge on epidemiological, geographical, and socioeconomical details and systemic diseases of their patients, so that a proper list of differential diagnoses (DD) can be formed.[1-4]

NOMENCLATURE

Onset Characteristics

The Standardization of Uveitis Nomenclature (SUN) working study group has defined the terminologies for onset, duration, and course of the disease **(Table 83.1)**.[6] Onset is described as either "sudden" or "insidious". The typical example of sudden onset is HLA B27-associated anterior uveitis characterized by acute pain, redness, and photophobia. The best example of "insidious" onset is anterior uveitis of juvenile idiopathic arthritis, characterized by a painless, white eye with minimal symptoms.

Table 83.1: Descriptors of uveitis—Standardization of Uveitis Nomenclature (SUN).

Category	Descriptor	Comment
Onset	• Sudden • Insidious	
Duration	• Limited • Persistent	• ≤3 months duration • >3 months duration
Course	Acute	Episode characterized by sudden onset and limited duration
	Recurrent	Repeated episodes separated by periods of inactivity without treatment ≥3 months in duration
	Chronic	Persistent uveitis with relapse in <3 months after discontinuing treatment

Source: Adapted from Jabs DA, Nussenblatt RB, Rosenbaum JT. Standardization of uveitis nomenclature for reporting clinical data: results of the first international workshop. Am J Ophthalmol. 2005;140:509-16.

Course Characteristics

The course of the uveitis may be acute or chronic. Acute uveitis is characterized by limited duration of less than 3 months. Any prompt relapse in less than 3 months on cessation of therapy will be considered as chronic uveitis. Recurrent uveitis is characterized by repeated episodes of active inflammation, interspersed by periods of inactivity.

Severity and Activity of Uveitis

Severity of uveitis is graded based on the cells and flare in the anterior chamber (AC), and cells and haze in the posterior segment. The presence of cells or increased protein (flare) in the AC is evidence of spillover from the inflamed iris or ciliary body. AC cells are mostly lymphocytes in most cases of anterior uveitis, but a considerable number of neutrophils may be present early in the course of disease.

JAYPEE BROTHERS

Excess protein in the AC is a sign of breakdown of the blood–ocular barrier. When the slit beam is obliquely aimed across the AC, the ability to visualize the path of the beam is termed flare. The amount of light scattering is directly proportional to the amount of protein; therefore, more flare indicates increased protein in the aqueous.[2] Previously, there were different systems for measuring flare and cells, making it difficult to compare. This has been rectified by a standardized set of criteria for grading, as proposed by SUN working group.[6] The accurate grading of the inflammatory signs of the AC is given in **Table 83.2**. According to this classification, the presence or absence of a hypopyon (collection of inflammatory cells which settles down in the AC) is recorded separately. Its presence will not grade as 4 plus cells.

The inflammatory cells in the vitreous mostly arise from the choroid, retina, and ciliary body. However, in certain infections, the focus of inflammation may be the vitreous. In active vitritis, cells appear white and are evenly distributed between the liquid and formed vitreous. Old cells are smaller and pigmented, while vitreous debris is pigmented but larger in size. Grading of vitreous cells is given in **Table 83.3**. Inflammatory cells that accumulate in clumps (snowballs) may precipitate onto the peripheral retina, usually inferiorly, for example, in intermediate uveitis, associated with sarcoidosis.[4]

Based on standard photographs, a grading scale for vitreous haze, based on the view of the optic nerve head and posterior retina, is used **(Fig. 83.1)**.

The SUN working group has also defined active and inactive uveitis and improving/worsening activity and remission **(Table 83.4)**. These standardized definitions help in comparing different treatment modalities.

Laterality, Age, and Gender

Uveitis can be either unilateral or bilateral. The bilaterality may be symmetrically equal as in Vogt–Koyanagi–Harada (VKH) syndrome or sympathetic ophthalmia, or asymmetric as in Behçet's syndrome or sarcoidosis.[7-9] Other parameters such as age and gender also give a clue toward the etiology.[10,11] Certain entities are known to be active only in children such as juvenile idiopathic uveitis, while Behçet's or VKH syndrome is seen more commonly in middle age. Leprosy and masquerade syndrome occur often in elderly. Certain entities are known to show a gender predilection. For example, sarcoidosis is common in women and ankylosing spondylitis is common in men.

Table 83.2: Grading scheme for anterior chamber cells and flare.

Grade cells	Cells in field*	Grade flare	Description
0	<1	0	None
0.5+	1–5	1+	Faint
1+	6–15	2+	Moderate (iris and lens details clear)
2+	16–25	3+	Marked (iris and lens details hazy)
3+	26–50	4+	Intense (fibrin or plastic aqueous)
4+	>50		

*Field size is a 1 mm × 1 mm slit beam.

Source: Adapted from Jabs DA, Nussenblatt RB, Rosenbaum JT. Standardization of uveitis nomenclature for reporting clinical data: results of the first international workshop. Am J Ophthalmol. 2005;140:509-16.

Table 83.3: Grading of vitreous cells.

Grade	Number of vitreous cells
0	No cells
½+	1–10
1+	11–20
2+	20–30
3+	30–100
4+	>100

Source: Adapted from Chorich III LJ, Klisovic DD, Foster SC. Diagnosis of uveitis. In: Foster SC, Vitale AT (Eds), Diagnosis and Treatment of Uveitis, 2nd edition. New Delhi: Jaypee Brothers Medical Publishers. p. 116.

CLASSIFICATION OF UVEITIS

Several classification systems are used when describing uveitides. They have been standardized to provide uniformity.

Anatomical Classification

Incorporating the International Uveitis Study Group (IUSG) classification scheme,[12,13] the SUN study group developed an anatomic classification **(Table 83.5)**, based on the primary site of inflammation.[6]

When the primary site of inflammation is the AC, even with minimal spillover cells in the posterior segment, the uveitis is named as anterior uveitis. It is important to note that the presence of secondary complications such as macular edema, peripheral vascular sheathing, or neovascularization will not change this classification. Some clinical examples of anterior, intermediate, posterior,

JAYPEE BROTHERS

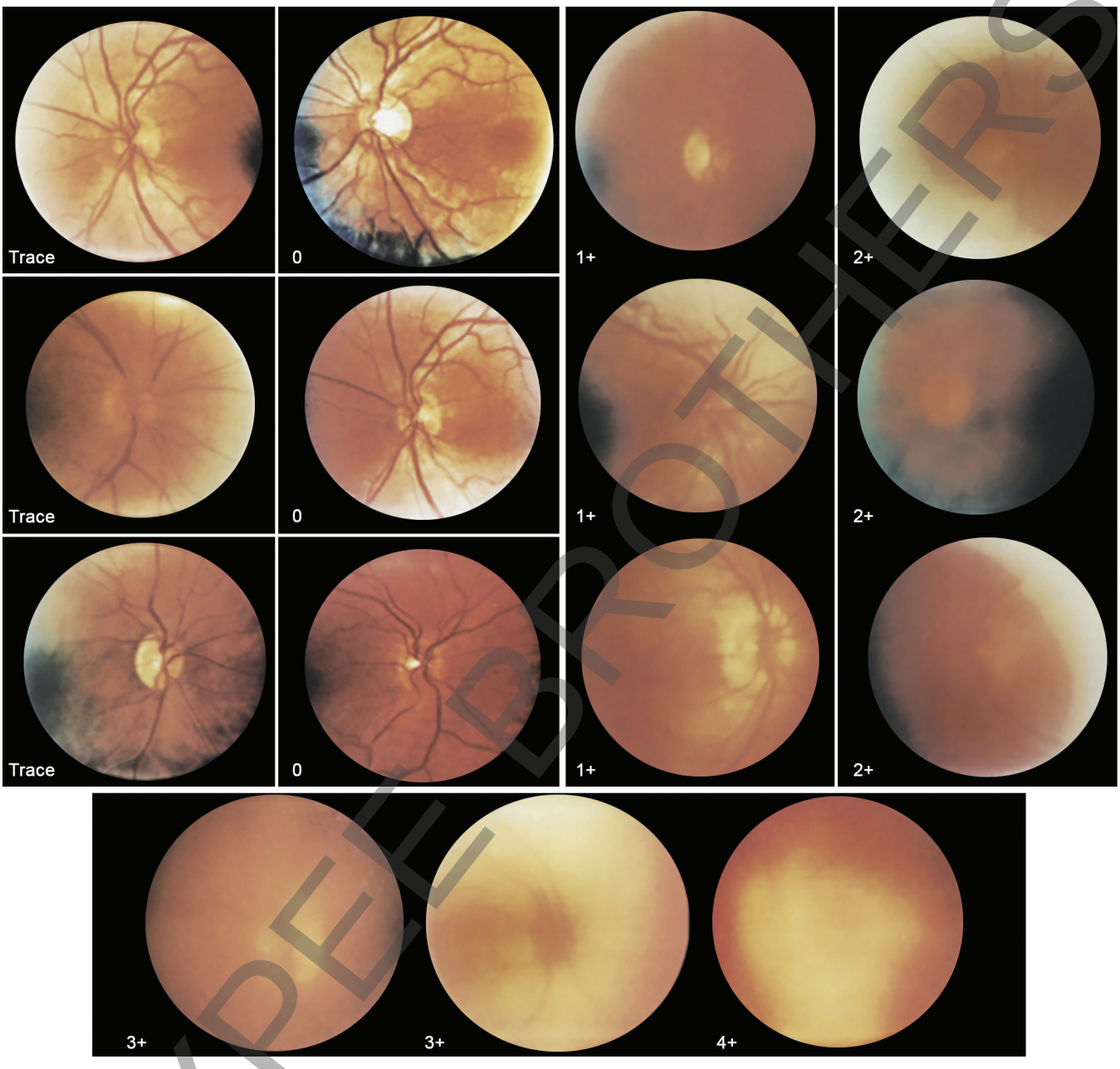

Fig. 83.1: Standardized photographic grading of vitreous haze.
Source: Adapted from Nussenblatt RB, Palestine AG, Chan CC, et al. Standardization of vitreal inflammatory activity in intermediate and posterior uveitis. Ophthalmology. 1985;92(4):467-71.

and panuveitis are given in **Tables 83.6 and 83.7** and **Box 83.1,** respectively.

Pathological Classification

Pathologically, uveitis may be classified as granulomatous or nongranulomatous. However, it has to be understood that this pathological classification is not based on any histopathological evidence but purely from a clinical presentation. Mutton fat keratic precipitates or Busacca nodules on the iris imply a diagnosis of granulomatous uveitis. Keratic precipitates are aggregates of inflammatory cells that accumulate on the endothelial surface of the cornea.

JAYPEE BROTHERS

Table 83.4: SUN working group—activity of uveitis terminology.

Term	Definition
Inactive	Grade 0 cells*
Worsening activity	Two-step increase in the level of inflammation (e.g., anterior chamber cells, vitreous haze) or increase from grade 3+ to 4+
Improved activity	Two-step decrease in the level of inflammation (e.g., anterior chamber cells, vitreous haze) or decrease to grade 0
Remission	Inactive disease for >3 months after discontinuing all treatments for eye disease

*Applies to anterior chamber inflammation.

Source: Adapted from Jabs DA, Nussenblatt RB, Rosenbaum JT. Standardization of uveitis nomenclature for reporting clinical data: results of the first international workshop. Am J Ophthalmol. 2005;140:509-16.

Table 83.5: Anatomic classification of uveitis.

Type	Primary site of inflammation	Includes
Anterior uveitis	Anterior chamber	Iritis, iridocyclitis, anterior cyclitis
Intermediate uveitis	Vitreous	Pars planitis, posterior cyclitis, hyalitis
Posterior uveitis	Retina or choroid	Focal, multifocal, or diffuse choroiditis, chorioretinitis, retinochoroiditis, retinitis, neuroretinitis
Panuveitis	Anterior chamber, vitreous, and retina or choroid	

Source: Adapted from Jabs DA, Nussenblatt RB, Rosenbaum JT. Standardization of uveitis nomenclature for reporting clinical data: results of the first international workshop. Am J Ophthalmol. 2005;140:509-16.

BOX 83.1 Clinical examples of posterior and panuveitis.

Noninfectious:
- Sarcoidosis
- Vogt–Koyanagi–Harada syndrome
- Sympathetic ophthalmia
- Behçet's disease
- Serpiginous choroidopathy

Infectious
- Bacterial:
  - Tuberculosis
  - Syphilis
  - Lyme's disease
  - Leptospirosis
  - Brucellosis
  - Septic retinitis
- Fungal:
  - *Nocardia asteroides*
  - Candidiasis
  - Histoplasmosis
  - *Cryptococcus neoformans*
  - Aspergillosis
- Viral:
  - CMV retinitis
  - Herpes simplex
  - Herpes zoster
  - Chikungunya
  - West Nile virus
- Parasitic:
  - Toxoplasmosis
  - Toxocara canis
  - Cysticercosis
  - *Onchocerca volvulus*

(CMV: cytomegalovirus)

Table 83.7: Clinical examples of intermediate uveitis.

Intermediate uveitis	Common complications
Idiopathic	Cystoid macular edema
Sarcoidosis	Cataract
Tuberculosis	Retinal vasculitis
Lyme disease	Ciliary atrophy
Syphilis	Cyclitic membrane
Leptospirosis	Cataract
Multiple sclerosis	Opaque vitreous

Table 83.6: Clinical examples of anterior uveitis

Nongranulomatous anterior uveitis	Granulomatous anterior uveitis	Noninfectious anterior uveitis	Infectious anterior uveitis
HLA B27 uveitis*	Tuberculosis	Seronegative arthropathy*	Herpetic
Traumatic	Sarcoidosis	Sarcoidosis	Tuberculosis
Behçet's syndrome	Syphilis	Traumatic	Syphilis
Leptospirosis	Leprosy	Lens induced	Leprosy
Early sarcoidosis	Herpetic	Fuchs heterochromic uveitis	Leptospirosis
Early tuberculosis	VKH/sympathetic ophthalmia	Postoperative	Parasitic
Early syphilis	Lens-induced uveitis	Juvenile rheumatoid arthritis	Fungal infection

*HLA B27-related uveitis includes ankylosing spondylitis, Reiter's syndrome, psoriatic arthropathy, and inflammatory bowel syndrome.

(VKH: Vogt–Koyanagi–Harada)

JAYPEE BROTHERS

Etiological Classification

The final classification and the most important one is the etiological classification of uveitis. The etiological classification is often challenging because several infectious and noninfectious uveitis entities may not present with a specific clinical picture. The same disease may have varying manifestations with respect to the onset, severity, and course in different patients. Similarly, several uveitis entities of varying causes can present with virtually identical clinical features.[1-4] Uveitis can happen in nearly 100 specific diseases. While infectious and noninfectious uveitis encompass a majority of uveitis cases, masquerade syndromes should be kept in mind as well. This latter group consists of malignancy, degenerative disorders, metabolic diseases, and others **(Table 83.8)**. Comprehensive history, ocular and systemic examination, laboratory workup, and meticulous follow-up will greatly enhance the chance of deriving an accurate etiological diagnosis.

Table 83.8: Disorders masquerading as uveitis.

Nonmalignant cells in vitreous	Malignant cells
RBCs in vitreous hemorrhage	Lymphomas
Pigments in vitreous—retinitis pigmentosa	Leukemia
Intraocular foreign body	Retinoblastoma
Retinal detachment	Medulloepithelioma
Drug adverse reactions—moxifloxacin	Secondaries
Myopic degeneration	Juvenile xanthogranuloma
Multiple sclerosis	Metastatic carcinoma
Postvaccination reaction	Diffuse uveal melanocytic proliferation
Metabolic diseases—amyloidosis	

SUN II CLASSIFICATION

In 2021, the SUN working group came up with a system to classify the 25 most common uveitic conditions. It should be noted that this was developed with an intent to have uniformity during research in different studies, and patients, in a real-life scenario, need not meet all the criteria mentioned in SUN II to fit into a particular diagnosis.[14]

AN ALGORITHMIC APPROACH IN THE CLINICAL WORKUP FOR UVEITIS

The workup has to start with an elaborate history, followed by a thorough examination including the systemic and ocular study. A step-wise algorithmic approach leads to a reliable DD, which helps to order relevant laboratory investigations. These tailored investigations guide the clinician toward a final diagnosis and to institute an appropriate treatment **(Flowchart 83.1)**.

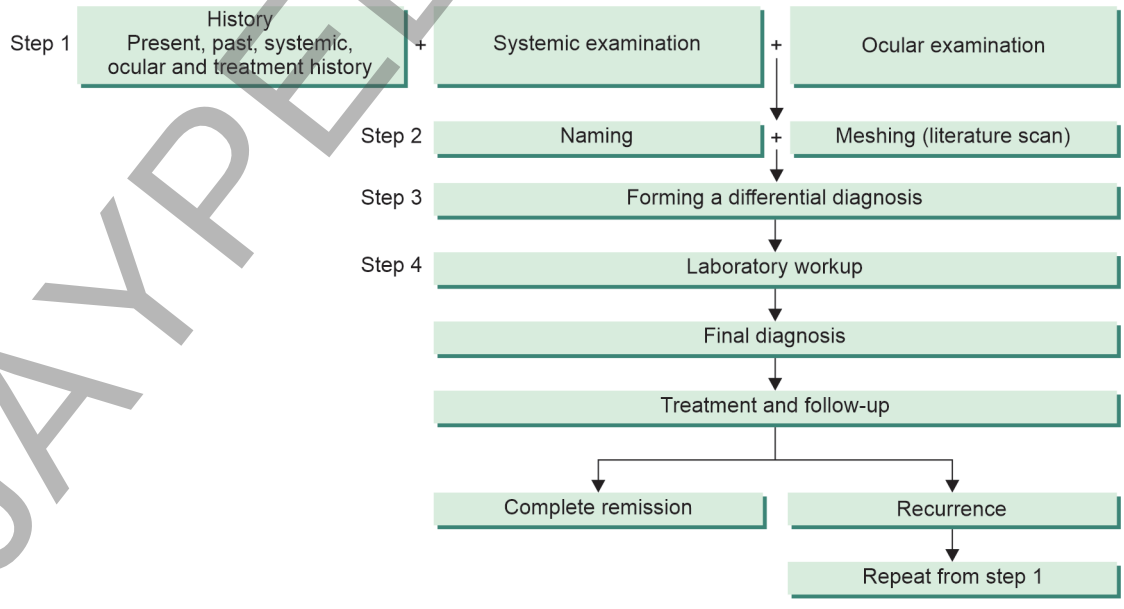

Flowchart 83.1: Algorithmic approach in uveitis.

JAYPEE BROTHERS

HISTORY TAKING IN UVEITIS

Adequate time should be spent on an elaborate history taking which includes demographic details, the relevant present and past ocular history, systemic history, and treatment history **(Box 83.2)**.[2] It has been our experience that when this process is done methodically, 70% of diagnosis can be made on this basis and unnecessary expensive investigations can be avoided. The importance of demography cannot be overemphasized. A bilateral chorioretinitis scar in a patient from sub-Saharan Africa might be due to onchocerciasis, while the same presentation in a patient from South-East Asia should raise the suspicion of tuberculosis. The social history or an occupational history alerts the physician on exposure to risk factors, while a positive family history suggests a contagious disease or genetic disorder. Likewise, histories of associated systemic symptoms act as diagnostic predictors in some patients. A choroidal granuloma in a patient with established pulmonary tuberculosis should be treated as a tubercular etiology, unless proven otherwise.

CLINICAL EXAMINATION

A comprehensive systemic examination should precede the ocular examination. In a patient with bilateral chronic granulomatous uveitis, the presence of integumentary signs such as poliosis and vitiligo may indicate a possibility of VKH syndrome **(Fig. 83.2)**, while associated erythematous skin lesions may indicate sarcoidosis.[15,16] A typical malar rash in a patient with scleritis might be suggestive of systemic lupus erythematosus **(Fig. 83.3)**.

Important systemic clinical signs that are relevant in a uveitis patient are given in **Table 83.9 (Figs. 83.2 to 83.6)**.

BOX 83.2 History taking in uveitis.

Demography
- Age
- Gender
- Socioeconomic history
  - Race
  - Residence
  - Occupation

Ocular present and past history
- Primary symptom
  - Onset
  - Duration
  - Laterality
  - Severity
  - Course
- Associated events
- Ocular treatment history

Systemic history
- Systemic symptoms associated with present eye disease
- Other systemic ailments

Treatment history



Fig. 83.2: Vitiligo and poliosis in a patient with Vogt–Koyanagi–Harada (VKH) syndrome. Bilateral granulomatous uveitis in its chronic recurrent stage.

Source: Adapted from Nussenblatt RB, Palestine AG, Chan CC, et al. Standardization of vitreal inflammatory activity in intermediate and posterior uveitis. Ophthalmology. 1985;92:467-71.



Fig. 83.3: Alopecia and butterfly rashes in a young girl with systemic lupus erythematosus.

JAYPEE BROTHERS

Table 83.9: Systemic signs in uveitis with clinical examples.

System	Sign	Disease
Integumentary system	Poliosis	Vogt–Koyanagi–Harada syndrome, sympathetic ophthalmia
	Loss of hair	Systemic lupus erythematosus, syphilis, Vogt–Koyanagi–Harada syndrome
	Vitiligo	Leprosy, sympathetic ophthalmia and Vogt– Koyanagi–Harada syndrome
	Rash	Vasculitic diseases, systemic lupus erythematosus, Behçet's disease, syphilis
	Erythema nodosum	Inflammatory bowel disease, sarcoidosis, tuberculosis, and Behçet's disease
	Scaling of the skin	Systemic lupus erythematosus, psoriatic arthritis, syphilis, and Reiter's syndrome
	Discoid lesions	Systemic lupus erythematosus, sarcoidosis, leprosy, and tuberculosis.
	Nail abnormalities	Psoriatic arthritis, Reiter's syndrome, and vasculitis
Mucosal involvement	Oral and genital lesions	Behçet's disease, Reiter's syndrome, and syphilis
	Oral ulcers alone	Systemic lupus erythematosus and inflammatory bowel disease
	Nasopharyngeal manifestations including sinusitis	Granulomatosis with polyangiitis, sarcoidosis, Whipple's disease, and mucormycosis
Musculoskeletal system	Arthralgias and arthritis	• *Autoimmune diseases*: Seronegative spondyloarthropathies, rheumatoid arthritis, Behçet's, sarcoidosis, collagen vascular diseases • *Postinfectious inflammation*: Chikungunya, West Nile virus infection Leptospirosis, syphilis, Lyme's disease, tuberculosis, lepromatous leprosy
	Cartilage loss	Relapsing polychondritis, syphilis, gonococcal disease, leprosy, and granulomatosis with polyangiitis
Respiratory system	Respiratory symptoms	Tuberculosis, sarcoidosis, granulomatosis with polyangiitis
Circulatory system and lymphatic system	Lymph nodes	Tuberculosis, sarcoidosis, lymphoma
	Vasculitis	Behçet's disease, sarcoidosis, tuberculosis, toxoplasmosis, acute retinal necrosis
Digestive system	Bowel disease	Ulcerative colitis, Whipple's disease, Crohn's disease
Nervous system	Neuropathy	Leprosy, herpes zoster, sarcoidosis, multiple sclerosis, syphilis and sarcoidosis, collagen vascular disease
	Hearing loss	Vogt–Koyanagi–Harada syndrome, sympathetic ophthalmia, sarcoidosis
Genitourinary system	Urethral discharge	Reiter's syndrome, syphilis, herpes simplex and gonococcal urethritis
	Epididymitis	Behçet's disease, tuberculosis
	Prostatitis	Reiter's syndrome, ankylosing spondylitis, and gonococcal disease
	Bladder (cystitis)	Whipple's disease and Reiter's disease
	Nephritis	Vasculitis in granulomatosis with polyangiitis, tubulointerstitial nephritis and uveitis syndrome (TINU), systemic lupus erythematosus (SLE), Behçet's disease, sarcoidosis, tuberculosis
General	Fever, fatigue, myalgia	Collagen vascular disease, tuberculosis, leptospirosis

Often uveitis patients may require additional assessment by neurologists, rheumatologists, dermatologists, and pediatricians depending upon the systemic conditions involved.

Ocular examination starts from the forehead to optic disk. Before going for the slit-lamp examination, a simple torch light examination may reveal absence of eyelashes, poliosis, and vitiligo, which may otherwise be missed. A detailed slit-lamp and gonioscopic examination followed by indirect ophthalmoscopy with scleral indentation are very important in every case of uveitis irrespective of the anatomical or etiological classification. Important ocular signs in uveitis are given with clinical examples in **Table 83.10 (Figs. 83.7 to 83.27)**.

JAYPEE BROTHERS



Fig. 83.4: Herpes zoster ophthalmicus involving left upper trigeminal branch.



Fig. 83.5: Typical malar rash in a patient with scleritis which was diagnosed as systemic lupus erythematosus (SLE).



Fig. 83.6: Recurrent mouth ulcers in Behçet's disease.

Table 83.10: Ocular signs in uveitis with clinical examples.

Anatomical location	Examples
Forehead and adnexa	
• Vitiligo	• VKH, scleroderma
• Vesicles	• Herpes zoster ophthalmicus
• Poliosis	• VKH, leprosy
• Nodules	• Sarcoidosis
• Madarosis	• Leprosy
Conjunctiva	
• Cyst	• Cysticercosis
• Granulomas	• Foreign body granulomas, sarcoid, tuberculosis, trematode granuloma
• Leproma	• Leprosy
Sclera/Episclera	
Scleritis and episcleritis	Collagen vascular disorders, syphilis, tuberculosis, leprosy, viral
Cornea	
• Band keratopathy	• Juvenile rheumatoid arthritis, sarcoidosis
• Dendritic keratitis	• Viral uveitis
• Superficial punctate keratitis	• Viral uveitis
• Sclerokeratouveitis	• Syphilis, tuberculosis, leprosy, and viral
• Exposure keratitis	• Leprosy
Iris/pupil	
• Miotic and irregular pupils	• Any uveitis except Fuchs uveitis
• Posterior synechiae	• Any uveitis except Fuchs uveitis
• Busacca nodules	• Tuberculosis, sarcoidosis, syphilis
• Relative afferent pupillary defect	• Herpetic uveitis, neurosyphilis
• Iris atrophy	• Viral uveitis, leprosy, traumatic uveitis
Anterior segment	
• Hypopyon	• Behçet's disease, leptospirosis, HLA B27-related diseases
• Hyphema	• Viral uveitis, masquerade syndrome
Gonioscopic evaluation	
• Peripheral anterior synechiae	• Sarcoidosis, tuberculosis
• Iris nodules	• Sarcoidosis, tuberculosis
• Hyphema	• Herpetic uveitis
• Foreign body	• Traumatic uveitis

(VKH: Vogt–Koyanagi–Harada)

JAYPEE BROTHERS

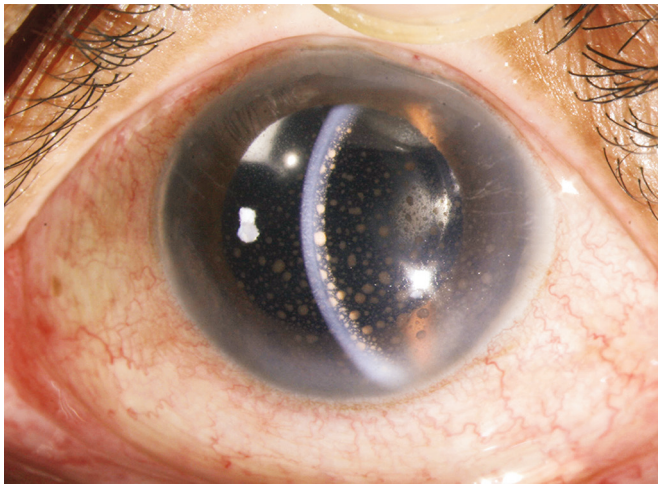

Fig. 83.7: Granulomatous keratic precipitates.

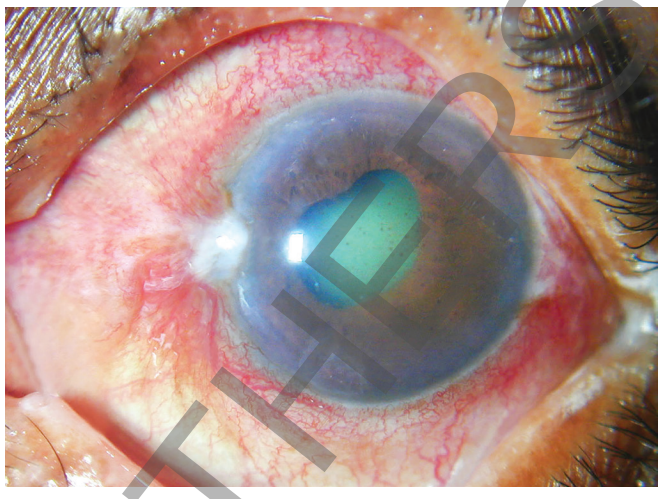

Fig. 83.10: Pigmented keratic precipitates with festooned pupil in viral uveitis.



Fig. 83.8: Multiple Busacca nodules in a patient with granulomatous uveitis.



Fig. 83.11: Annular synechiae, iris bombe and peripheral anterior synechiae in a patient with uveitic glaucoma. The patient has undergone YAG-laser peripheral iridotomy at 4 o'clock position.

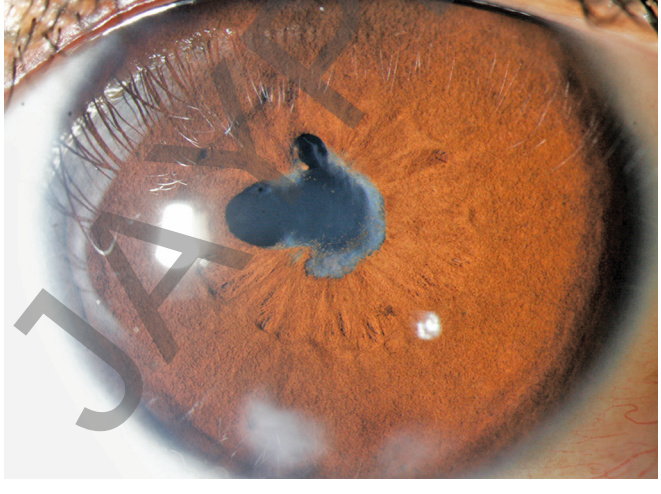

Fig. 83.9: Posterior synechiae with festooned pupil.

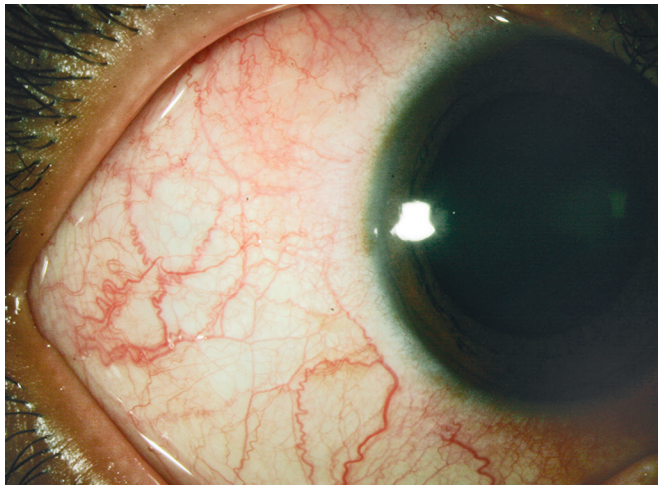

Fig. 83.12: Diffuse episcleritis in rheumatoid arthritis.

JAYPEE BROTHERS

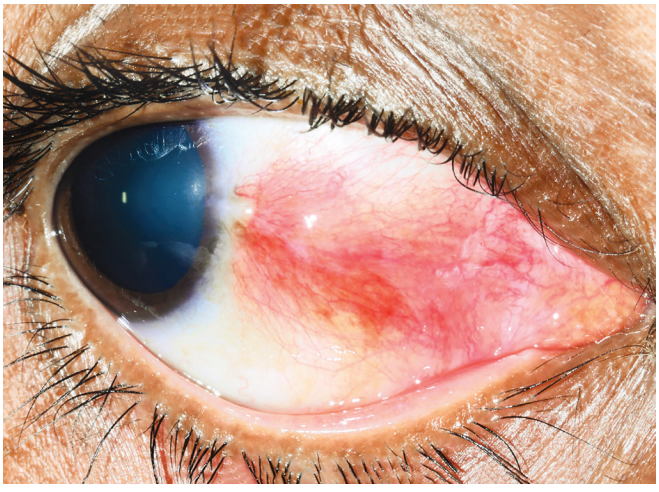

Fig. 83.13: Nodular scleritis in rheumatoid arthritis.

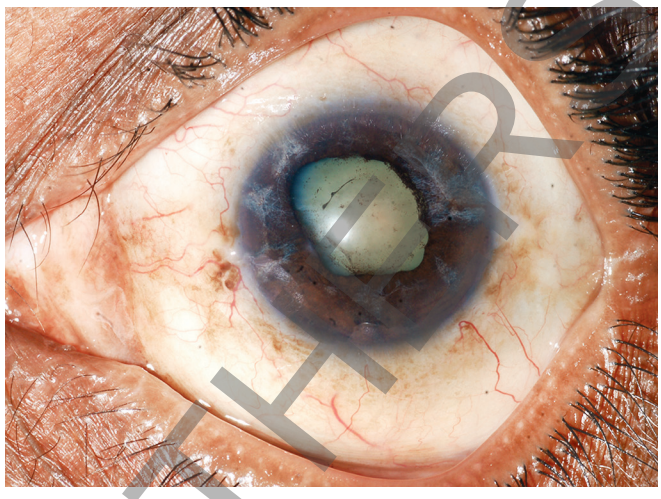

Fig. 83.16: Iris atrophic patches after viral uveitis in an elderly patient. The patient also has senile cataract.

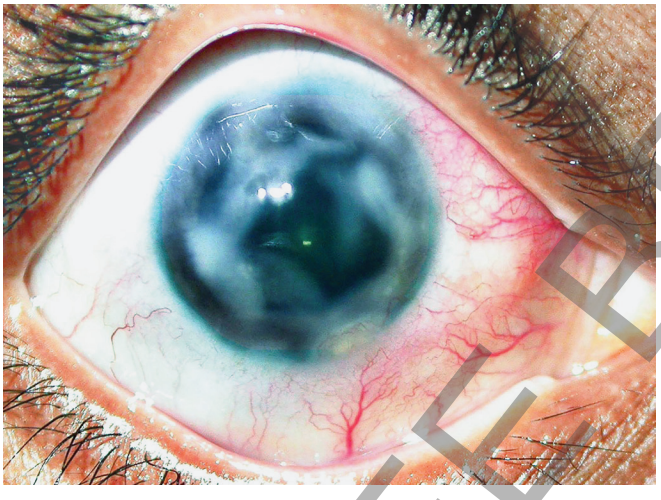

Fig. 83.14: Recurrent sclerokeratitis in a patient with tuberculosis.

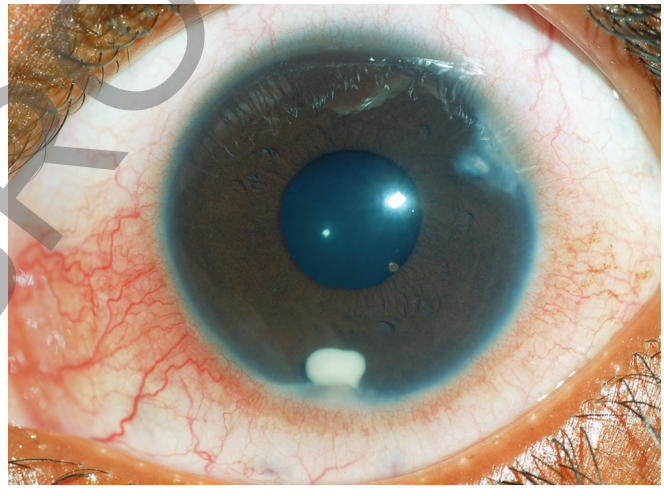

Fig. 83.17: Trematode granuloma at 2 and 6 o'clock positions in a child.

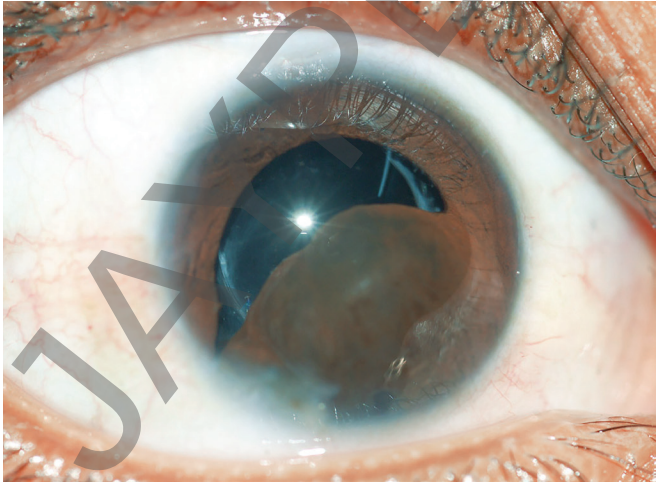

Fig. 83.15: Iris cyst after a thorn injury at 7 o'clock position. The patient has undergone intraocular lens implantation for traumatic cataract.

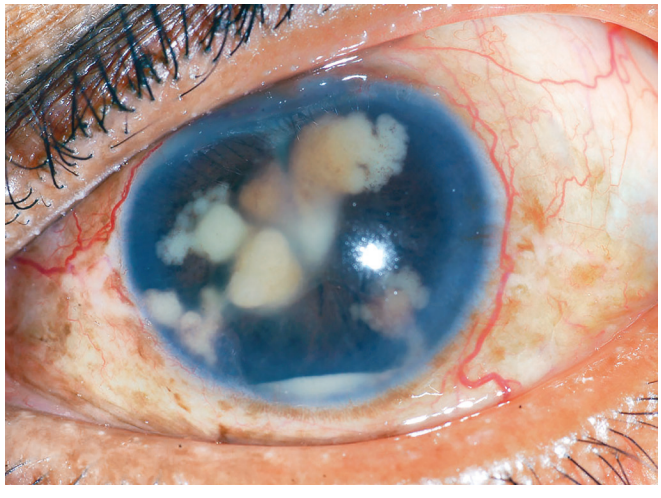

Fig. 83.18: Post-traumatic fungal granulomas with hypopyon.

JAYPEE BROTHERS

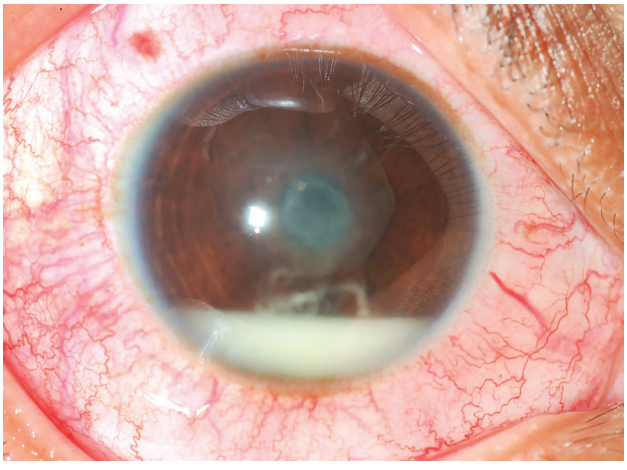

Fig. 83.19: Acute nongranulomatous anterior uveitis with fibrinous exudates and hypopyon in a patient with ankylosing spondylitis.

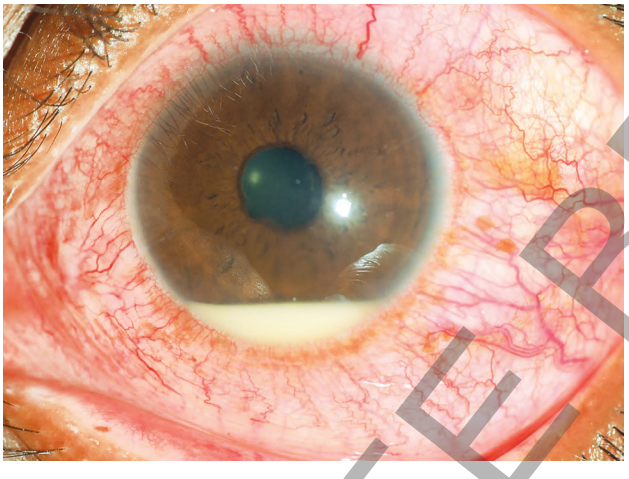

Fig. 83.20: Chronic nongranulomatous anterior uveitis with fluid level hypopyon in a patient with Behçet's disease. Note the absence of fibrinous reaction.

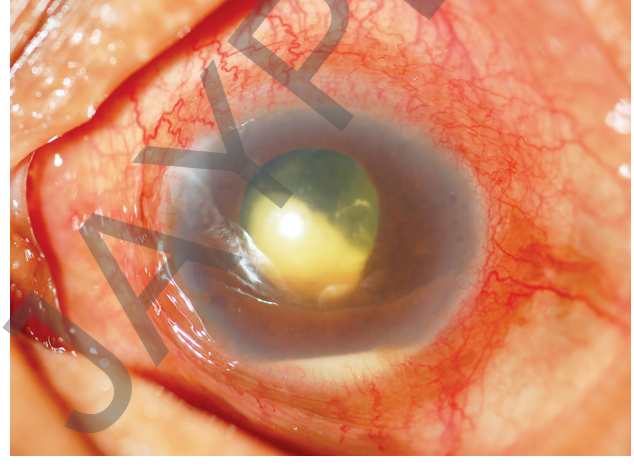

Fig. 83.21: Leaking Morgagnian cataract with hypopyon in an elderly patient. Lens is partially absorbed.

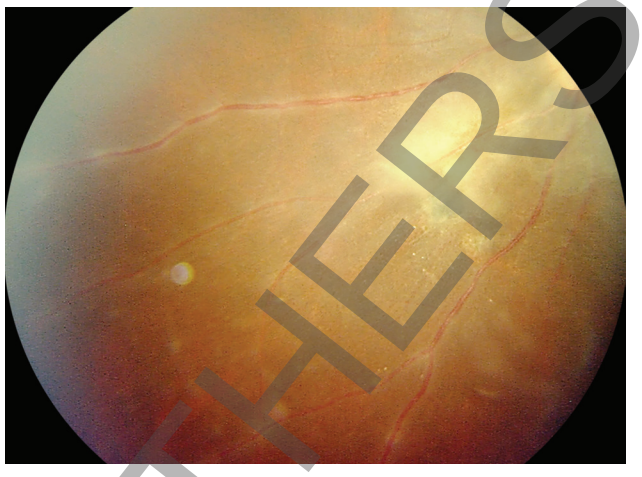

Fig. 83.22: Acute posterior uveitis with active retinitis and healed pigmented scar suggestive of toxoplasmosis. Note the phlebitis and arteritis.



Fig. 83.23: Healed focal toxoplasmic retinochoroiditis.

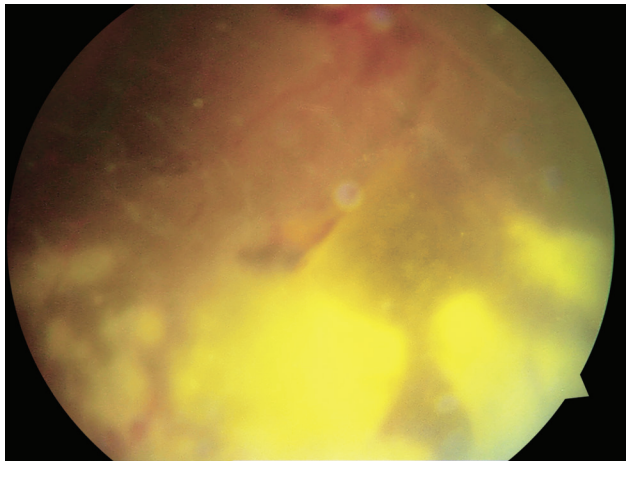

Fig. 83.24: Multifocal retinitis, vasculitis with hemorrhage and intense vitreous inflammatory reaction in acute retinal necrosis (ARN).

JAYPEE BROTHERS



Fig. 83.25: Healed juxtapapillary chorioretinal scar in a patient with treated tubercular posterior uveitis.

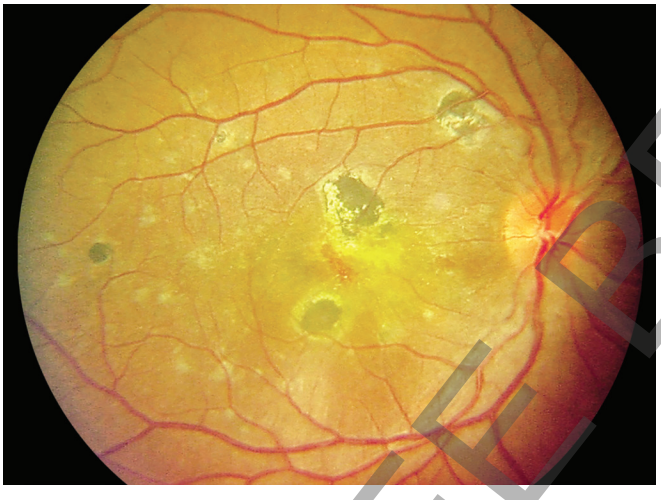

Fig. 83.26: Healed multifocal chorioretinal scars in a patient with treated tubercular posterior uveitis.

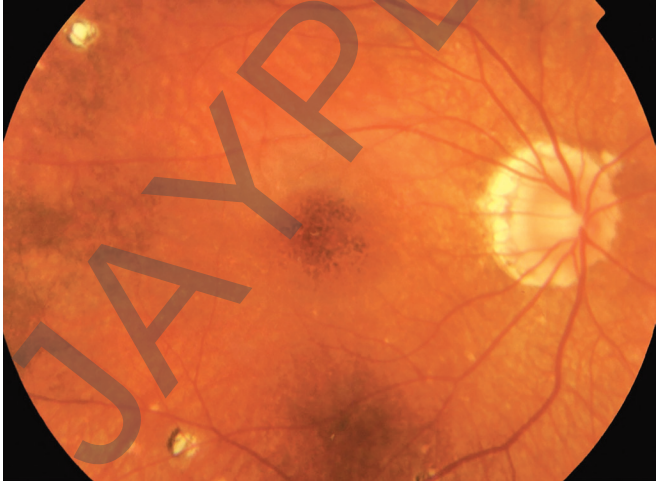

Fig. 83.27: Sunset glow fundus in a patient with Vogt–Koyanagi–Harada (VKH) syndrome. Peripapillary atrophy is seen with resolved peripheral Dalen Fuchs nodules.

Naming and Meshing

Finally, a specific name is assigned to the clinical entity by using a set of descriptive terminologies in uveitis **(Table 83.11)**.

This descriptive name can then be compared to the known uveitis patterns. This is known as the meshing step.

Some examples are given in **Box 83.3**.

DIFFERENTIAL DIAGNOSIS

Uveitis specialists need to have a thorough knowledge of all entities **(Tables 83.12 and 83.13)**. With that background knowledge, a probable list of etiologies or causes are listed as DD.

Table 83.11: Descriptive terminologies in uveitis with common clinical examples.

Onset	Examples	Age	Examples
Sudden	HLA B27 uveitis	Pediatric uveitis	JRA, pars planitis
Insidious	Sarcoidosis	Middle age	Collagen vascular disorders, sarcoidosis
Duration		Geriatric	Viral, masquerade
Limited	Traumatic	*Gender*	
Persistent	Sarcoidosis	Male	HLA B27 uveitis
Course		Female	Sarcoidosis
Acute	Acute retinal necrosis	*Pathology*	
Recurrent	HLA B27 uveitis	Nongranulo-matous	HLA B27 uveitis
Chronic	Sarcoidosis	Granulo-matous	Tuberculosis, sarcoidosis
Anatomical		*Severity*	
Anterior	HLA B27 uveitis	Mild	Fuchs' uveitis
Intermediate	Pars planitis	Moderate	Sarcoidosis
Posterior	Toxoplasmosis	Severe	Acute retinal necrosis
Panuveitis	VKH syndrome	*Etiological*	
Laterality		Infectious	Tuberculosis
Unilateral	Fuchs uveitis	Immunological	Sarcoidosis
Unilateral alternating	HLA B27 uveitis	Masquerade	Lymphoma
Bilateral	VKH syndrome	Idiopathic	

(JRA: juvenile rheumatoid arthritis; VKH: Vogt–Koyanagi–Harada)

JAYPEE BROTHERS

BOX 83.3 Naming and meshing technique in uveitis—clinical examples.

The relevant points from the history are combined with findings of ocular and systemic examination to derive a name for the uveitis.

Example 1:

A 55-year-old lady gives history of on and off eye pain, defective vision, and redness in both eyes for 5 years with history of small joints pain. Examination reveals bilateral granulomatous panuveitis, retinal vasculitis, and vitreous snowballs. Radiological examination shows evidence of hilar lymphadenopathy and her angiotensin-converting enzyme (ACE) is elevated. Her purified protein derivative (PPD) is negative and she never had any history suggestive of systemic tuberculosis. She has previously improved with oral steroids; however, she presently suffers from uncontrolled diabetes mellitus and hypertension.

Naming of this patient in nutshell is "Chronic bilateral granulomatous panuveitis with small joints pain, high ACE and hilar lymphadenopathy in a middle-aged female patient".

Meshing step compares this clinical picture with existing literature and derives a differential diagnosis (DD). The above example of bilateral granulomatous panuveitis can have DD of sarcoidosis, Vogt–Koyanagi syndrome, sympathetic ophthalmia, and tuberculosis for example. There is no history of trauma or surgery and no vitiligo or poliosis in spite of its chronicity. The workup shows high ACE and hilar lymphadenopathy with a negative PPD. Final diagnosis of sarcoidosis is made and treatment is planned accordingly.

Example 2:

A 30-year-old man presents with a history of severe pain in right eye, redness, and defective vision for 2 days. Past history reveals two similar episodes in left eye few years back. He also has early morning low back pain and neck rigidity for the past 6 years on and off. Examination reveals unilateral nongranulomatous anterior uveitis with fibrinous hypopyon and posterior synechiae. Radiological examination shows evidence of ankylosing spondylitis.

Naming of this second patient is "acute unilateral recurrent alternating anterior uveitis in a young male patient with ankylosing spondylitis."

Meshing step clearly points out a possibility of a final diagnosis of HLA-B27-related uveitis, and treatment is planned accordingly.

Laboratory Diagnosis

The laboratory diagnosis of uveitis comes after the clinical diagnosis and offers a supportive evidence. A tailored laboratory workup is always preferred than a nonselective elaborate approach. A general laboratory investigation like complete blood count is performed to know the general status of the patient at the onset of treatment and during the follow-up. Specific investigations are done for confirmation of the diagnosis or for assessment

Table 83.12: Differential diagnosis based on various anterior segment clinical signs.

Hypopyon	**Iris atrophy**
HLA B27 uveitis	Viral uveitis—herpes zoster
Behçet's disease	Viral uveitis—herpes simplex
Leptospirosis	Traumatic
Phacolysis	Postlaser atrophy
Endophthalmitis	Postoperative uveitis
Postoperative uveitis	Hansen's uveitis
Leukemia	Fuchs heterochromic uveitis
Retinoblastoma	Anterior segment ischemia
Neuroblastoma	Essential Iris atrophy
Drug induced	ICE syndrome
Hyphema	**Irregular anterior chamber depth**
Fuchs heterochromic uveitis	Iris cyst
Viral uveitis	Subluxated lens
Syphilis	Leaking Morgagnian cataract
Gonococcal uveitis	Ciliary body tumor
Leukemia	Peripheral anterior synechiae
Glaucoma in the absence of synechiae	**Low tension in uveitis**
Sarcoidosis	Bilateral exudative retinal detachment
Toxoplasmosis	Ciliary body detachment
Viral uveitis	Retinal detachment induced uveitis
Fuchs heterochromic uveitis	Ciliary shock in acute uveitis
Lens protein uveitis	Traumatic and perforated globe

(ICE: iridocorneal endothelial)

Table 83.13: Differential diagnosis of various posterior segment clinical signs.

Vitreous cells and opacities	**Retinal vasculitis and infectious causes**
Inflammatory cells	Acute retinal necrosis
Red blood cells	CMV retinitis
Degenerated old cells	Measles (SSPE)
Pigments	Chikungunya
Amyloidosis	West Nile virus
Asteroid hyalosis	Tuberculosis
Malignant cells: Leukemia lymphoma	Syphilis
Lens cortical material	Leptospirosis

Contd...

JAYPEE BROTHERS

Peyman-Prajna Principles & Practice of

Ophthalmology

Salient Features

- This new edition is the culmination of years of dedicated effort, collaboration, and commitment by the section editors, who worked closely with the contributing authors to produce a comprehensive and up-to-date resource.
- Fundamental subjects in ophthalmology—including Anatomy, Physiology, Biochemistry, Pathology, Pharmacology, Microbiology, Immunology, and Genetics—have been presented in a concise, lucid, and clinically relevant manner.
- The sections on Conjunctiva and Cornea, Retina and Vitreous, Glaucoma, Scleritis and Uveitis, Neuro-Ophthalmology, and Orbit and Oculoplasty have been extensively revised and updated by expert section editors and contributors to reflect current concepts, evidence-based practices, and recent advances in clinical ophthalmology.
- A new chapter on Periocular Aesthetics has been introduced in this edition to address the growing importance of aesthetic periocular practice in modern ophthalmology.



N Venkatesh Prajna DNB FRCOpth is the Director of Academics, Aravind Eye Care System, Madurai, Tamil Nadu, India. He has been involved in teaching the postgraduates in ophthalmology for almost 30 years and directly oversees one of the largest residency program in the country. He has been the Principal Investigator of large, landmark international clinical trials like SCUT, MUTT, and REAGIR all of which have significantly influenced the treatment regimen in the field of infectious keratitis worldwide. Currently he serves in the Advisory Board of one of the most prestigious International journal, namely JAMA Ophthalmology. He has published more than 200 papers in high impact journals. Dr Prajna has delivered many named prestigious lectures in renowned international ophthalmology centers including the Ronald G Michels lecture at Johns Hopkins University, Baltimore, Patons' lecture at Wills Eye Hospital Philadelphia and the Thygeson's lecture at UCSF, San Francisco, USA.

JAYPEE BROTHERS

Buy from ejaypee

JAYPEE BROTHERS

Shelving Recommendation
OPHTHALMOLOGY

ISBN 978-93-0952-691-6