ww.ejaypee.com, for detailed information on surgery books, visit our website www.ejaypee.com, for detailed information on surgery books, visit our website www.ejaypee.com

12th Edition

More than 5,00,000 copies sold worldwide

S DAS CONCISE TEXTBOOK OF SURGERY

Highlights

- Includes chapter on surgical instruments
- Includes more than 1500 MCQs
- Aligned with current national and international guidelines

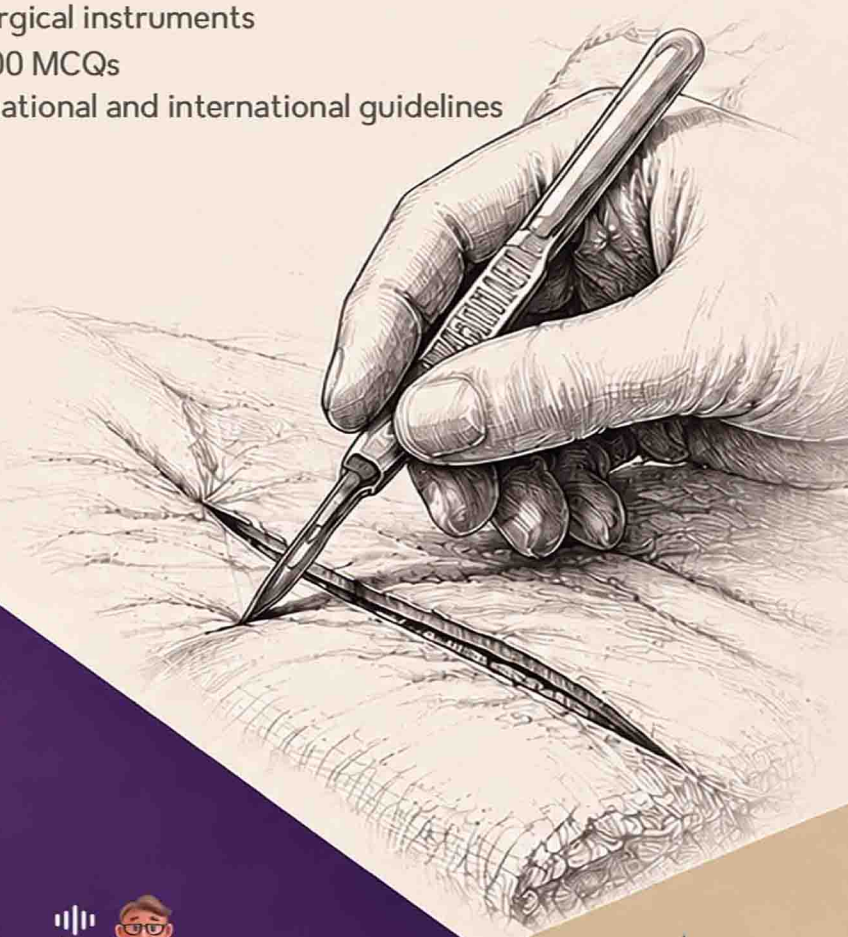

Revised by

Nilay Mandal



Genuine?
Scratch, Scan & Validate



Dr. Wise
Innovative & Genius AI Chatbot
access code inside

JAYPEE

Contents

SECTION 1: BASICS OF SURGERY

1. Wound Healing **3**

- Classification of Wound 3
- Types of Wound Healing 5
- Phases of Wound Healing 5
- Malignant Wound 10
- Management of Acute Wound 10

2. Shock **16**

- Definition 16
- Changes Secondary to Shock 16
- Classification of Shock 16
- Hypovolemic Shock 16
- Traumatic Shock 18
- Cardiogenic Shock 18
- Obstructive Shock 19
- Distributive Shock 19
- Endocrine Shock 21

3. Fluid, Electrolyte and Acid–Base Balance **23**

- Anatomy of Body Fluids 23
- Normal Exchange of Fluid and Electrolytes 23
- Water Deficit and Excess 24
- Electrolytes and Electrolyte Imbalance 25
- Parenteral Fluid Therapy 30
- Disorders of Acid–Base Balance 32

4. Hemorrhage, Hemostasis and Blood Transfusion **36**

- Hemorrhage 36
- Hemostasis 38
- Blood Transfusion 41

5. Nutrition **45**

- Nutritional Requirements 45
- Malnutrition 45

SECTION 2: GENERAL SURGERY

6. Burns **53**

- Mechanism of Burn Injuries 53
- Pathology of Burns 55
- Management of Burn Injuries 57
- Complications of Thermal Burn 65

7. Boil, Abscess, Carbuncle, Cellulitis, Erysipelas, and Impetigo **68**

- Boil (Furuncle) 68
- Abscess 68
- Carbuncle 71
- Cellulitis 72
- Erysipelas 73
- Impetigo 73

8. Basics of Oncology **75**

- Types of Neoplasm and their Characteristic Features 75
- Hallmarks of Cancer 77
- Risk Factors of Cancer 77
- Screening of Cancer 78
- Clinical Presentation of Cancer 79
- Investigations for Cancer Management 79
- Staging of Cancer 82
- Treatment of Cancer 83

9. Cysts **90**

- Classification of Cysts 90
- Clinical Features of a Cyst 92
- Complications of Cysts 92
- Dermoid Cyst 92
- Sebaceous Cyst 95

10. Common Tumors and Miscellaneous Lesions of the Skin **100**

- Benign Tumors 100
- Malignant Tumors 111
- Miscellaneous Lesions of the Skin 125

11. Ulcer, Sinus and Fistula **131**

- Ulcer 131
- Sinus and Fistula 139

12. Tetanus **143**

- Incubation Period 143
- Modes of Entry 143
- Pathology 143
- Clinical Features 143
- Diagnosis 144
- Treatment 144
- Causes of Death 145

13. Gas Gangrene **147**

- Etiology and Predisposing Factors 147
- Bacteriology 147
- Pathology 147
- Clinical Features 148
- Investigations 148
- Prophylaxis 148
- Treatment of an Established Case 148

14. Flaps and Grafts 150
- Principles of Surgery 150
- Planning of Skin Incision 150
- Skin Grafting 150
- Flap 152

15. Diseases of Arteries 156
- Arterial Occlusion 156
- Chronic Arterial Occlusive Disease 156
- Raynaud's Syndrome 160
- Acrocyanosis 162
- Thoracic Outlet Syndrome 162
- Cervical Rib and Scalenus Anticus Syndrome 165
- Buerger's Disease (Thromboangiitis Obliterans) 167
- Acute Arterial Occlusion 169
- Mesenteric Arterial Occlusion 171
- Gangrene 172
- Aneurysm 173
- Dissecting Aneurysm 177

16. Diseases of Veins 180
- Varicose Veins 180
- Venous Ulcer 190
- Deep Vein Thrombosis 191
- Superficial Vein Thrombosis (Thrombophlebitis) 192

17. Diseases of the Lymphatic System 195
- Diseases of the Lymphatics 195
- Tumors of the Lymphatics 198

18. The Peripheral Nerves 201
- Structure of a Peripheral Nerve 201
- Injury to the Peripheral Nerves 201
- Nerve Suture 204
- General Technique for Nerve Repair 205
- Brachial Plexus 206
- Axillary Nerve 207
- Long Thoracic Nerve (Nerve of Bell) 207
- Radial Nerve 207
- Median Nerve 208
- Ulnar Nerve 209
- Sciatic Nerve 210
- The Common Peroneal (Lateral Popliteal) Nerve 210
- Investigations for Nerve Injury 211
- Tumors of the Peripheral Nerves 211

19. Amputation 214
- Indications for Amputation 214
- Ideal Level for Amputation 214
- Types of Amputation 215
- Surgical Technique of Amputation 215
- Complications of an Amputation Stump 216
- Site Specific Amputations 216

20. The Hand 222
- Infections of the Hand 222
- Other Lesions of the Hand 228
- Injuries of the Hand and Fingers 232
- Principles of Hand Surgery 234

21. The Foot 238
- Rare Congenital Deformities 238
- Swellings 238
- Ulcers 238
- Pain in the Foot 239
- Ingrowing Toenail 240
- Infections of Foot 240
- Infection of the Spaces of the Foot 241
- Painful Heel 241
- Metatarsalgia 242
- Ruptured Tendo-Achilles 243

22. The Head 245
- Surgical Anatomy of Scalp 245
- Swellings of the Head 245
- Tumors 246
- Intracranial Infections 246
- Central Nervous System Tumors 248

24. Swellings of the Jaw 251
- Classification of Jaw Swellings 251
- Epulis 251
- Odontomas 252
- Osseous Tumors 255
- Inflammatory Conditions 258

25. Mouth, Tongue and Lips 262

Mouth 262
- Stomatitis 262
- Syphilis 263
- Cysts in the Mouth 264
- Tumors of the Cheek 266

The Tongue 267
- Leukoplakia 267
- Ulcers of the Tongue 269
- Neoplasms of Tongue 269
- Rare Anomalies of the Tongue 272
- Congenital Fissured Tongue 273
- Furring of the Tongue 273
- Median Rhomboid Glossitis 273
- Hairy Tongue 273
- Lingual Thyroid 273

Lips 273
- Pigmented Lips 273
- Macrocheilia 274
- Neoplasms 274
- Non-neoplastic and Premalignant Lesions of the Lip 276

26. Cleft Lip and Cleft Palate 279
- Embryology 279
- Cleft Lip 279
- Cleft Palate 281

27. Salivary Glands 284
- Parotid Gland 284
- The Sublingual Salivary Gland 287
- Minor Salivary Glands 287

- Clinical Examination of Parotid Swelling 288
- Acute Suppurative Parotitis 289
- Mumps Parotitis 290
- Recurrent Subacute and Chronic Parotitis 290
- Neoplasms of the Salivary Glands 290
- Mikulicz's Disease and Sjogren's Syndrome 295
- Parotid Fistula 296
- Sialolithiasis 296
- Submandibular Calculi 296
- Parotid Calculi 297
- Tumors of the Submandibular Gland 298
- Mucus Retention Cyst 299
- Ranula 299
- Surgical Procedures for Salivary Gland Pathologies 299

27. Swellings in the Neck 306

- Classification of Neck Swellings 306
- Branchial Cyst and Branchial Fistula 307
- Branchiogenic Carcinoma 312
- Cystic Hygroma 312
- Thyroglossal Cyst 313
- Thyroglossal Fistula 315
- Sublingual Dermoid Cyst 315
- Deep or Plunging Ranula 316
- Sternomastoid Tumor (Congenital Torticollis, Fibromatosis Colli) 317
- Carotid Body Tumor (Potato Tumor; Chemodectoma; Nonchromaffin Paraganglioma) 318
- Subhyoid Bursal Cyst 319
- Cold Abscess in the Neck 320
- Collar-Stud Abscess 322
- Pharyngeal Pouch (Diverticulum of the Pharynx) 322
- Laryngocele 324
- Cervical Rib 324
- Cervical Lymphadenopathy 325
- Clinical Examination of Cervical Lymph Node Enlargement 327

28. The Thyroid and Parathyroids 334

Thyroid Gland 334

- Embryology 334
- Anatomy 334
- Histology 336
- Physiology 336
- Assessment of Thyroid Function 337
- Goiter 338
- Tumors of the Thyroid 347
- Thyroiditis 355
- Thyroid Surgery 356
- Hypothyroidism 360
- Ectopic Thyroid Tissue 361

Parathyroid Glands 362

- Embryology 362
- Anatomy 363
- Histology 363
- Physiology 363
- Regulation of Parathyroid Secretion 364
- Hyperparathyroidism 365
- Hypoparathyroidism 368

29. The Adrenal Glands 374

- Development 374
- Anatomy 374
- Histology 375
- Adrenal Cortex 376
- Physiology of the Adrenal Cortex 376
- Cushing Syndrome 377
- Aldosteronism (Conn's Syndrome) 380
- Adrenogenital Syndrome 382
- Adrenocortical Insufficiency (Addison's Disease) 382
- Waterhouse-Friderichsen Syndrome 383
- Secondary Adrenal Insufficiency 384
- Adrenal Crisis 384

Adrenal Medulla 384

- Physiology 384
- Pheochromocytoma 384
- Adrenal Incidentaloma 386
- Adrenalectomy 386

30. The Breast 390

- Embryology 390
- Anatomy 390
- Congenital Anomalies of the Breast 393
- Gynecomastia 393
- Breast Infections 395

Benign Conditions of the Breast 396

- Benign Breast Diseases 396
- Other Breast Lesions 399
- Aberrations of Normal Development and Involution 400
- Breast Pain (Mastalgia) 400
- Cyclical Nodularity 401
- Nipple Discharge 401
- Nipple Inversion and Retraction 402

Malignant Neoplasms of the Breast 403

- Breast Carcinoma 403
- Male Breast Cancer 421
- Breast Cancer in Pregnancy 422
- Inflammatory Breast Cancer 422
- Paget's Disease of the Nipple 422

31. Trauma 428

- Types of Injury and their Mechanisms 428
- Dangerous Mechanisms of Injury 428
- Injury Prevention 428
- Trimodal and Bimodal Distribution of Trauma Death 429
- Injury Scoring Systems 429
- Triage 429
- Trauma Centers 430
- Prehospital Management 431
- Initial Assessment and Management of Trauma Patients 431
- Trauma in Special Populations 436
- Head Injury 439
- Maxillofacial Trauma 445
- Neck Injury 446

- Spinal Injury 446
- Chest Injury 448
- Abdominal Injuries 454
- Damage Control Resuscitation 464

32. Basics of Transplantation 469

- Types of Organ Transplantation 469
- Immunobiology 469
- Organ Procurement 470
- Organ Preservation 471
- Kidney Transplantation 471
- Liver Transplantation 472
- Pancreas Transplantation 472

33. Basics of Minimally Invasive Surgery 475

- Minimal Access Techniques 475
- Laparoscopic Access 476
- Basic Principle of Ergonomics 477
- Instrumentation 478
- Energy Sources 479
- Advantages, Limitations and Contraindications of Minimally Invasive Surgery 482
- Robotic Surgery 482

SECTION 3: GASTROINTESTINAL SURGERY

34. The Esophagus 489

- Anatomy 489
- Physiology 491
- Congenital Esophageal Atresia 492
- Esophageal Perforation 492
- Gastroesophageal Reflux Disease (GERD) 494
- Hiatus Hernia 496
- Achalasia Cardia 497
- Diffuse Esophageal Spasm or Corkscrew Esophagus 498
- Esophageal Diverticulum 499
- Miscellaneous Lesions of the Esophagus 500
- Caustic Injury of Esophagus 502
- Foreign Body Ingestion 503
- Tumors of the Esophagus 504
- Dysphagia 509

35. The Stomach and Duodenum 512

- Embryology 512
- Anatomy of Stomach 512
- Anatomy of Duodenum 515
- Physiology of Stomach and Duodenum 516
- Congenital Pyloric Stenosis 517
- Peptic Ulcer 517
- Perforated Peptic Ulcer 526
- Peptic Ulcer Hemorrhage 529
- Gastric Outlet Obstruction 529
- Malignant Change in Gastric Ulcer 530
- Gastric Volvulus 530
- Gastric Bezoar 531
- Gastric Neoplasms 531
- Upper Gastrointestinal Bleeding 539

36. The Liver and Portal Hypertension 544

- Anatomy of the Liver and Portal Venous System 544
- Functions of the Liver 547
- Hepatic Abscesses 547
- Cysts of the Liver 551
- Neoplasms of the Liver 556
- Portal Hypertension 562

37. The Biliary System 570

- Anatomy 570
- Physiology 571
- Congenital Anomalies of Biliary System 572
- Gallstones (Cholelithiasis) 577
- Acute Cholecystitis 580
- Chronic Cholecystitis 584
- Cholecystectomy 584
- Acute Acalculous Cholecystitis 590
- Cholesterosis (Syn. Strawberry Gallbladder) 590
- Choledocholithiasis (Stones in the Common Bile Duct) 591
- Acute Cholangitis 596
- Mirizzi Syndrome 596
- Recurrent Pyogenic Cholangitis (Oriental Cholangiohepatitis) 597
- Primary Sclerosing Cholangitis 597
- Bile Duct Stricture 598
- Gallbladder Polyp 599
- Carcinoma of the Gallbladder 599
- Bile Duct Carcinoma 601

38. The Spleen 607

- Anatomy of the Spleen 607
- Physiology of the Spleen 608
- Congenital Abnormalities 610
- Anemia for which Splenectomy is Required 610
- Miscellaneous Diseases which may be Benefitted by Splenectomy 613
- Cysts and Tumors of the Spleen 614
- Hypersplenism 616

39. The Pancreas 621

- Embryology 621
- Anatomy 621
- Physiology 623
- Congenital Abnormalities 624
- Pancreatitis 625
- Cysts of the Pancreas 638
- Neoplasms of the Pancreas 641
- Carcinoma of the Pancreas 641
- Pancreatic Neuroendocrine Neoplasms 645

40. The Small Intestine 653

- Intussusception 653
- Duodenal Atresia 656
- Midgut Volvulus 656
- Meconium Ileus 657
- Tuberculosis of the Intestine 658
- Crohn's Disease 661
- Typhoid Enteritis 665

- Diverticula of Small Intestine 665
- Blind-Loop Syndrome 668
- Short Bowel Syndrome 668
- Small Intestinal Fistula 670
- Enteroatmospheric Fistula 670
- Neoplasms 671

41. Intestinal Obstruction 677

- Etiology of Intestinal Obstruction 677
- Classification of Intestinal Obstruction 677
- Pathophysiology of Intestinal Obstruction 678
- Clinical Features in Simple Mechanical Intestinal Obstruction 679
- Physical Examination in Intestinal Obstruction 680
- Investigations in Intestinal Obstruction 681
- Management of Intestinal Obstruction 682
- Paralytic Ileus 682
- Adhesive Small Bowel Obstruction 683
- Obstruction Due to Worm Bolus 684
- Obstruction Due to Food Bolus 684

42. The Peritoneum, Omentum, Mesentery, and Retroperitoneum 687

- The Peritoneum 687
- Peritonitis 688
- Tuberculous Peritonitis 690
- Pneumococcal Peritonitis 690
- Biliary Peritonitis 691
- Spaces of Peritoneal Cavity 691
- Intra-abdominal Abscess 691
- Subphrenic Space and Subphrenic Abscess 691
- Pelvic Abscess 693
- Pseudomyxoma Peritonei 693
- The Greater Omentum 693
- The Mesentery 694
- Nonspecific Mesenteric Lymphadenitis 695
- Tuberculous Mesenteric Lymphadenitis 695
- Mesenteric Cysts 696
- Retroperitoneum 696
- Retroperitoneal Abscess 696
- Retroperitoneal Hematoma 696
- Retroperitoneal Fibrosis 697
- Retroperitoneal Tumors 697

43. The Vermiform Appendix 700

- Anatomy 700
- Congenital Abnormalities 701
- Acute Appendicitis 701
- Neoplasms 712

44. The Colon 717

- Megacolon 717
- Primary Megacolon (Hirschsprung's Disease) 717
- Acquired or Secondary Megacolon 718
- Ulcerative Colitis 718
- Crohn's Disease 723
- Ischemic Colitis 723
- Amebiasis 724
- Actinomycosis 725
- Angiodysplasia 725
- Diverticular Disease 726
- Diverticulosis Coli 726
- Diverticulitis 727
- Volvulus 728
- Acute Colonic Pseudo-obstruction 732
- Neoplasms of the Colon 733
- Polyps 733
- Carcinoma 736
- Management of Colorectal Emergencies 741

45. The Rectum and Anal Canal 746

- Anatomy 746
- Prolapse of the Rectum 750
- Anorectal Abscesses 753
- Fistula-in-Ano 755
- Hemorrhoids (Piles) 758
- Fissure-in-Ano 762
- Neoplasms of the Rectum and Anal Canal 764
- Carcinoma of the Rectum 764
- Congenital Abnormalities 769
- Proctitis 772
- Pruritus Ani 772
- Tumors of the Anal Canal 773
- Lower Gastrointestinal Tract Bleeding 775

46. Umbilicus and Abdominal Wall 780

- Embryology 780
- Anomalies of Development 780
- Omphalitis 782
- Umbilical Granuloma 782
- Pilonidal Sinus 782
- Umbilical Fistula 782
- Neoplasms of the Umbilicus 783
- Omphalith or Umbilical Calculus 783
- Causes of Discharge from the Umbilicus 783
- Discoloration of the Umbilicus 784
- Congenital Abdominal Wall Defects 784
- Diastasis of the Rectus Abdominis Muscles 785
- Rectus Sheath Hematoma 786
- Neoplasms of the Abdominal Wall 786

47. Hernia 789

- Etiology 789
- Pathology 789
- Classification 790
- Special Types of Strangulated Hernia 792
- Inguinal Hernia 792
- Indirect Inguinal Hernia 794
- Direct Inguinal Hernia 796
- Examination of Hernia 797

Femoral Hernia 805

- Surgical Anatomy 805
- Course of a Femoral Hernia 806
- Coverings of the Sac of the Femoral Hernia 806
- Clinical Features 806
- Treatment 807

Umbilical Hernia 808
Epigastric Hernia (Syn. Fatty Hernia of the Linea Alba) 811
Incisional Hernia 812
Divarication of Recti 816
Lumbar Hernia 816
Obturator Hernia 817
Other Rare Herniae 817

SECTION 4: GENITOURINARY SURGERY

48. The Kidney and Ureter 823
Embryology 823
- Development of Kidney 823
- Development of Ureter 824

Congenital Anomalies of the Kidney and Ureter 824
- Congenital Anomalies of the Kidney 824
- Congenital Anomalies of the Ureter 825
- Horseshoe Kidney 826
- Unilateral Multicystic Kidney 827
- Autosomal Dominant Polycystic Kidney Disease 827
- Simple Renal Cyst 828
- Medullary Sponge Kidney 829
- Ectopic Ureter 829
- Important Urinary Symptoms 830
- Hydronephrosis 831
- Nonspecific Infections of the Kidney 833
- Acute Pyelonephritis 834
- Chronic Pyelonephritis 835
- Pyonephrosis 836
- Renal Abscess or Carbuncle of the Kidney 836
- Perinephric Abscess 837
- Tuberculosis of the Kidney 837
- Renal Calculus 839
- Ureteral Stone 846
- Neoplasms of the Kidney 848
- Renal Cell Carcinoma 849
- Nephroblastoma (Wilms Tumor) 852
- Tumors of the Renal Pelvis and Ureter 853
- Squamous Cell Carcinoma of the Renal Pelvis 854
- Adenocarcinoma of the Renal Pelvis 854
- Tumors of the Ureter 854

49. The Urinary Bladder 860
- Development 860
- Surgical Anatomy 860
- Interior of the Bladder 861
- Structure 861
- Congenital Anomalies of the Bladder 862
- Cystitis 863
- Tuberculous Cystitis 864
- Abacterial Cystitis 864
- Interstitial Cystitis (Hunner's Ulcer) 865
- Vesical Calculus 865
- Diverticulum of the Bladder 866
- Neoplasms of the Bladder 867
- Hematuria 870
- Retention of Urine 871
- Urinary Diversion 871

50. The Prostate and Urethra 875
- Development 875
- Prostate 875
- Male Urethra 876
- The Female Urethra 877
- Benign Prostatic Hyperplasia 877
- Carcinoma of the Prostate 885
- Prostatitis 890
- Urethritis 891
- Urethral Stricture 892
- Congenital Anomalies of the Urethra 894
- Urethral Calculus 894
- Neoplasms of the Urethra 894

51. Testis, Epididymis, and Scrotum 899
- Development of the Testis 899
- Undescended Testis 900
- Retractile Testis 903
- Ectopic Testis 903
- Torsion of the Testis or Torsion of the Spermatic Cord 904
- Acute Orchitis 905
- Varicocele 906
- Acute Epididymitis 908
- Tuberculous Epididymitis 909
- Cysts Connected with the Epididymis 909
- Hydrocele 910
- Hematocele 914
- Pyocele 914
- Chylocele 914
- Tumors of the Testis 914

52. The Penis 924
- Development of Penis 924
- Anatomy of Penis 925
- Hypospadias 925
- Epispadias 927
- Ectopia Vesicae (Syn. Exstrophy of the Bladder) 927
- Balanoposthitis 928
- Balanitis Xerotica Obliterans 929
- Phimosis 929
- Paraphimosis 931
- Lymphogranuloma Venereum (Syn. Lymphogranuloma Inguinale) 932
- Granuloma Inguinale 933
- Peyronie's Disease 933
- Priapism 933
- Tumors 934

SECTION 5: ANESTHESIA AND SURGICAL INSTRUMENTS

53. Anesthesia 945
- General Anesthesia 945
- Regional Anesthesia 947

- Preoperative Fasting Recommendations before General Anesthesia and Regional Anesthesia 949
- The Enhanced Recovery after Surgery (ERAS) Protocol 949
- Local Anesthetics 950

54. Surgical Instruments 954

- Instruments Used for Antiseptic Dressing 954
- Instruments Used for Fixation 955
- Instruments Used for Giving Incision 955
- Instruments Used for Hemostasis 956
- Instruments Used for Holding Tissues 958
- Instruments Used for Suturing 961
- Urinary Catheter 969
- Metallic Bougie 972
- Suture Material 973

Index ***979***

CHAPTER

47

Hernia

A hernia is a protrusion of a part or whole of viscus through an abnormal opening in the wall of the cavity which contains it. In this chapter, only external abdominal hernia will be discussed. An external abdominal hernia is protrusion of abdominal viscus through a weak spot in the abdominal wall.

The common hernias are: (i) Inguinal hernia; (ii) Umbilical hernia; (iii) Epigastric hernia; (iv) Femoral hernia; (v) Incisional hernia.

The rare hernias are: (i) Spigelian hernia; (ii) Obturator hernia; (iii) Lumbar hernia; (iv) Gluteal hernia.

ETIOLOGY

Mainly two factors play a role in causing a hernia: (1) Weakness of the abdominal muscles and (2) Increased abdominal pressure.

1. **Weakness of the abdominal musculature** can be: (a) natural weakness; (b) congenital weakness and (c) acquired weakness.
   (a) ***Natural weakness:*** Hernia may develop through the natural weakens due to anatomical configurations, e.g., deep inguinal ring, femoral ring, lumbar triangles.
   (b) ***Congenital weakness:*** (i) Persistence of processus vaginalis—this causes indirect complete inguinal hernia in males. It is a sort of preformed sac through which the contents herniated. (ii) Patent canal of Nuck—this causes indirect inguinal hernia in females. (iii) Incomplete obliteration of the umbilical ring—this may lead to infantile umbilical hernia. (iv) Connective tissue disorders—some connective tissue disorders are associated with increased risk of hernia due to inherited imbalance in different collagen fibers.
   (c) ***Acquired weakness:*** (i) Surgical incision: A surgical scar has only 70% of the initial muscle strength. A surgical incision may lead to division of nerve fibers and thus cause muscle weakness. A direct hernia may develop following appendectomy due to division of subcostal or ilioinguinal nerve. (ii) Degeneration of connective tissue: Degeneration of connective tissue resulting from smoking, aging or systemic illness reduces the strength of abdominal muscles and fascial structures. Alterations in the structure, quantity and metabolism of collagen have been demonstrated in the connective tissues of the groin in patients with hernias. (iii) Repeated pregnancy: Hernia is more common in pregnancy due to muscle weakness and hormone-induced weakness of the pelvic ligaments.
2. **Increased abdominal pressure:** (i) Whooping cough in children and chronic cough in bronchitis, tuberculosis, etc.; (ii) Straining on micturition due to urethral stricture, bladder outlet obstruction; (iii) Repeated pregnancy; (iv) Chronic constipation.

- **Processus vaginalis** is the peritoneal outpouching through which the testes descend from the retroperitoneum to the scrotum during development.
- **The canal of Nuck** is the female equivalent of processus vaginalis. It is a pouch of peritoneum that accompanies the round ligament of the uterus through the inguinal canal toward the labia majora.
- Recent reports suggested less risk of inguinal hernia in obese population.
- Decreased type I to type III collagen ratio is demonstrated in inguinal hernia patients.

Connective tissue disorders associated with hernia development:
- Osteogenesis imperfecta
- Ehler-Danlos syndrome
- Marfan syndrome

PATHOLOGY

A hernia consists of three parts: (i) the sac; (ii) the contents of the sac and (iii) the coverings of the sac **(Fig. 47.1)**.
The sac is a pouch of peritoneum which comes out through the abdominal musculature. This sac can be divided into four parts: (a) the mouth, i.e., the opening of the sac through which the contents enter the sac, (b) the neck of

JAYPEE BROTHERS

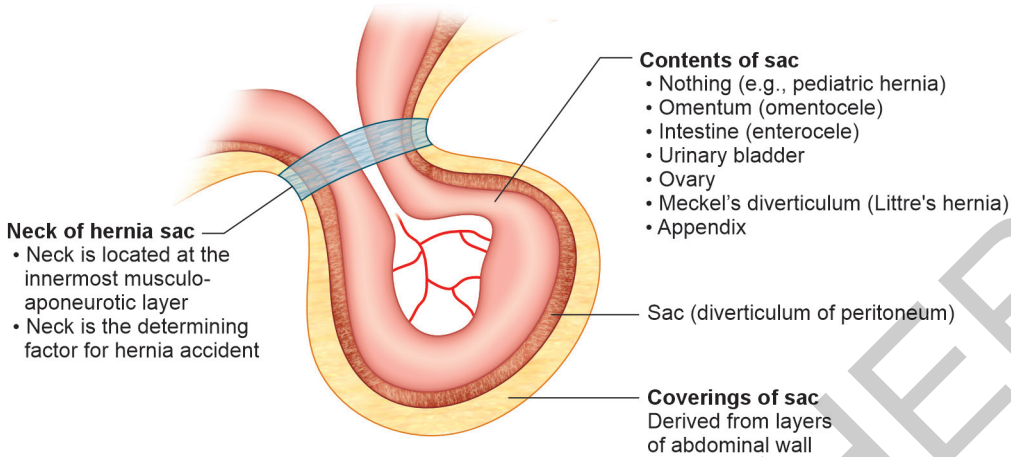

Fig. 47.1: The parts of a hernial sac.

the sac, which is the most constricted part and located in the innermost musculoaponeurotic layer. The neck is the determining factor for hernia accident, (c) the body, which is the main portion of the sac, and (d) the fundus, which is the most redundant part of the sac. In children, the sac is quite delicate whereas in adults with longstanding cases, the sac is comparatively thick.

The contents: The viscus which lies within the sac of a hernia is called the content of a hernia. Contents may be: (a) Nothing—in pediatric hernia; (b) Omentum—the hernia is called omentocele **(Fig. 47.2A);** (c) A loop of intestine—the hernia is called enterocele; (d) A portion of circumference of intestine—Richter's hernia; (e) Urinary bladder—in direct inguinal hernia or sliding hernia or femoral hernia; (f) Ovary with or without fallopian tube; (g) Meckel's diverticulum—Littre's hernia; (h) Two loops of small intestine remain in the manner of 'W'—Maydl hernia; (i) Appendix: Amyand's hernia **(Fig. 47.2B)**; (j) Fluid—slight fluid is almost always present, but it is more when it is associated with ascites. Fluid may be blood-stained in strangulated hernia.

The coverings are the layers of the abdominal wall which cover the hernial sac. This includes the skin and muscles of the abdomen.

The risk of obstruction and strangulation is more if the neck of the sac is narrow and rigid.

CLASSIFICATION

According to Site (Fig. 47.3)

(i) Groin hernia (inguinal hernia and femoral hernia); (ii) Umbilical hernia; (iii) Epigastric hernia; (iv) Incisional hernia; (v) Obturator hernia; (vi) Spigelian hernia; (vii) Lumbar hernia; (viii) Sciatic hernia; (ix) Perineal hernia; (x) Parastomal hernia and (xi) Port-site hernia.

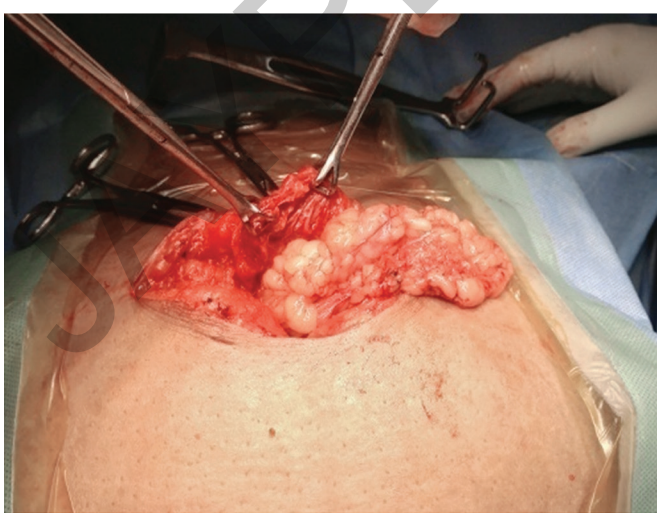

Fig. 47.2A: The hernial sac containing omentum—omentocele.

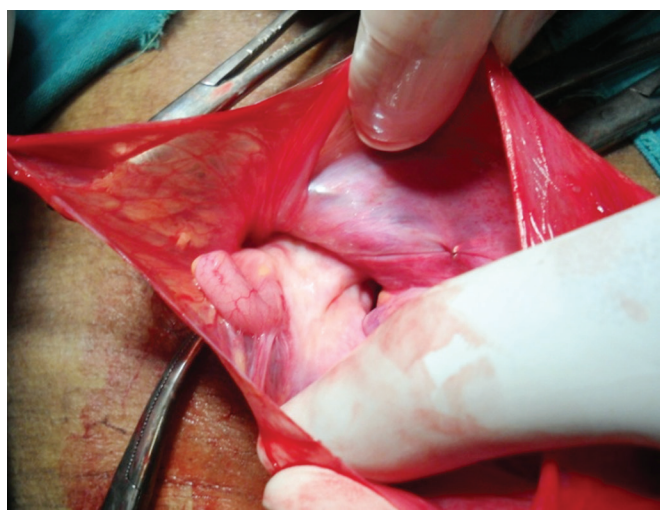

Fig. 47.2B: Appendix as a content of inguinal hernia—Amyand's hernia.

JAYPEE BROTHERS



Fig. 47.3: Different types of external abdominal hernia: Left inguinal hernia (A); umbilical hernia (B); and epigastric hernia (C).

According to Complications

(i) Incarcerated hernia; (ii) Obstructed hernia and (iii) Strangulated hernia.

Incarcerated Hernia

When the contents of the hernia cannot be returned back to the abdomen without any features of obstruction, it is called an incarcerated hernia **(Fig. 47.4).** There are various causes of incarceration: (i) Adhesion of its contents to each other; (ii) Adhesion of its contents with the sac; (iii) Adhesion of one part of the sac to the other part; (iv) Sliding hernia; (v) Narrowing of the neck of the sac due to fibrosis following continued use of the truss.

Obstructed Hernia

An obstructed hernia means that the hernia is associated with intestinal obstruction **(Fig. 47.5).** The features of obstructed hernia are: (i) The hernia is irreducible; (ii)

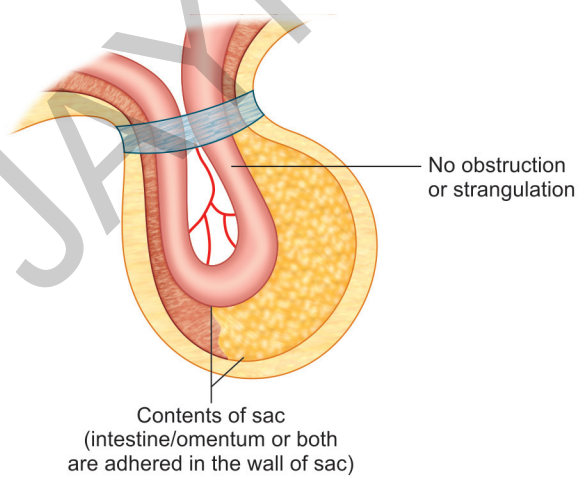

Fig. 47.4: Incarcerated hernia.

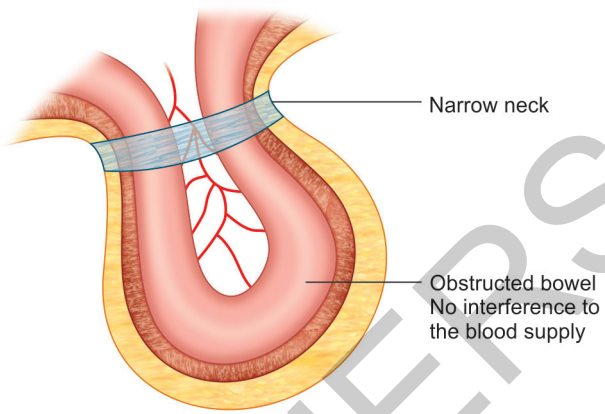

Fig. 47.5: Obstructed hernia.

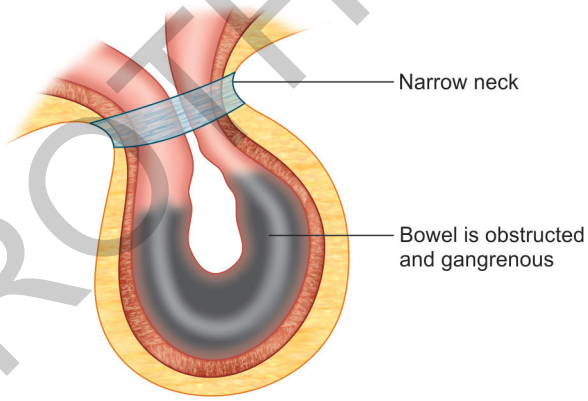

Fig. 47.6: Strangulated hernia.

Expansile cough impulse is not present; (iii) Features of intestinal obstruction; (iv) No pain over the hernia site.

Strangulated Hernia

A hernia is said to be strangulated when the blood supply of its contents is seriously impaired **(Fig. 47.6)**. Ultimately the content becomes gangrenous. This condition develops when the neck of the sac is very much constricted. When the intestine is the content, intestinal obstruction obviously takes place, but intestinal obstruction may not be present in case of omentocele, or Richter's hernia.

The features of strangulated hernia are: (i) The hernia is irreducible; (ii) The hernia is tense and tender; (iii) Features of intestinal obstruction; (iv) Patient is toxic.

The risk of strangulation is more in femoral hernia because of the:
- Narrow neck of the hernia
- Rigidity of surrounding structures

Pathophysiology of Obstruction and Strangulation

When the neck of the sac is very much constricted, intestinal obstruction first ensues and the intestine within the sac

JAYPEE BROTHERS

starts dilating. In case of enterocele, the venous return is first impeded. The intestine becomes congested and bright red. Serous fluid is seen oozing out into the sac. As venous stasis increases, the arterial supply is also impaired. Ecchymoses appear in the serosa. Blood comes out into the lumen of the intestine as also into the fluid of the sac, so the fluid in the sac becomes blood stained. The serous layer loses its shining character and gradually becomes dull and covered with fibrinous exudates. Gradually the intestine loses its tone, and it feels flabby. The vitality of the intestine diminishes and this favors migration of bacteria through the intestinal wall and the fluid within the sac which becomes full of bacteria and toxins. The mesentery within the sac becomes congested and hemorrhagic. Thrombosis of its vessels occurs. Gangrene first appears at the place of constriction and at the antimesenteric border of the intestine. In gangrenous areas the color changes from purple to black and ultimately to green. Gangrene may start as early as 5–6 hours after the onset of first symptom of strangulation.

SPECIAL TYPES OF STRANGULATED HERNIA

Strangulated omentocele: Omentum can withstand meagre blood supply for quite a long time, so onset of gangrene is usually delayed. It first occurs in the most distal part of the omentum. Patient usually presents with irreducible hernia with localized pain in the hernia site. The features of intestinal obstruction are absent.

Strangulated Richter's hernia: When a portion of the circumference of the intestine becomes the content of the sac it is called Richter's hernia. Strangulation of such a hernia often complicates a femoral hernia or small incisional hernia. In this hernia, strangulation develops without any features of intestinal obstruction. As there are no features of intestinal obstruction and minimal signs of strangulation, diagnosis becomes delayed and operation is performed late. During operation, the knuckle of bowel in the sac is often found gangrenous and peritonitis has set in.

Retrograde strangulation or Maydl's hernia (Hernia-en-W): In this condition, two loops of bowel remain in the sac, and the connecting loop remains within the abdomen and often becomes strangulated. The loops of intestine look like 'W'. The loop within the abdomen becomes strangulated first and can only be suspected when tenderness is elicited above the inguinal ligament and signs of intestinal obstruction are present. The fallacy of this condition is that even on opening the sac, the coils of intestine look normal. Only on traction of these loops, one can find the strangulated loop inside the abdomen. Since the strangulated loop is inside the abdomen, generalized peritonitis may set in early.

- Obstructed and strangulated hernia are **surgical emergencies**.
- **Features of intestinal obstruction are absent** in strangulated omentocele and strangulated Richter's hernia.
- **Diagnosis and surgical intervention are often delayed** in strangulated Richter's hernia due to absence of classical symptoms of strangulated hernia.

INGUINAL HERNIA

Inguinal hernia is the most common type of groin hernia. Another groin hernia is femoral hernia. *According to Dr Henri Fruchaud, all groin hernias develop due to a common anatomic defect, the 'Myopectineal orifice of Fruchaud,' rather than from isolated defects for each one.* An inguinal hernia is the protrusion of part of the contents of the abdomen through the inguinal region of the abdominal wall. This inguinal region is a weak part of the abdominal wall due to the presence of the inguinal canal, the deep inguinal ring and the superficial ring **(Fig. 47.7).**

The Inguinal Canal

The inguinal canal is a triangular slit almost horizontal in direction, which lies just above the inner half of the inguinal ligament. It commences at the deep inguinal ring and ends at the superficial ring. In infant, the superficial

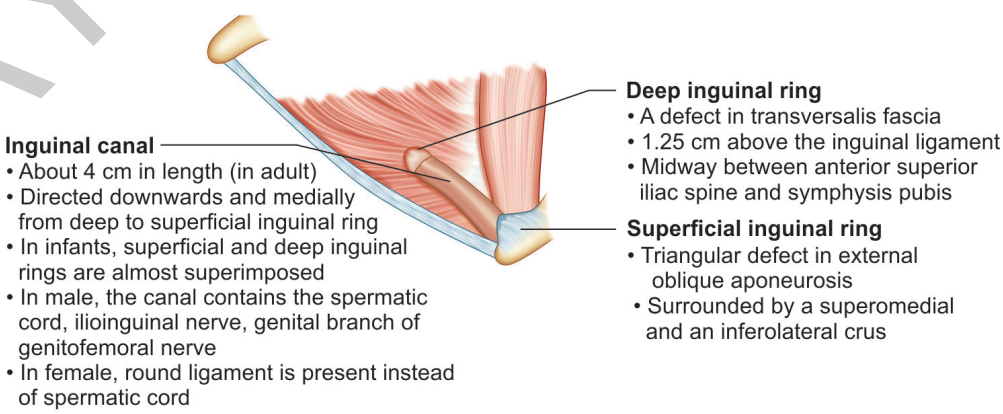

Fig. 47.7: Components of inguinal canal.

JAYPEE BROTHERS

and deep inguinal rings are almost superimposed, and the obliquity of this canal is slight. In adult, the inguinal canal is about 3.75 cm (1½ inch) long and is directed downwards and medially from the deep to the superficial inguinal ring. This canal develops due to descent of testis in the embryonic life.

The Deep Inguinal Ring

It is an opening in the fascia transversalis 1.25 cm (1/2 inch) above the mid-inguinal point, i.e., midpoint between the symphysis pubis and the anterior superior iliac spine. It is an oval shaped defect with vertical long axis. It varies in size in different individuals and is much larger in the male than in the female. At its margins the fascia transversalis is condensed. Medially, it is related to the inferior epigastric vessels. It transmits the spermatic cord in the male and the round ligament of the uterus in the female.

The Superficial Inguinal Ring

It is a triangular defect in the aponeurosis of the external oblique muscle. It is situated just above and lateral to the crest of the pubis. Its base is formed by the crest of the pubis and its sides are formed by the margins of the opening of the aponeurosis which are called the crura of the ring. The lateral crus of the ring is stronger. The superficial inguinal ring gives passage to the spermatic cord and ilioinguinal nerve in the males and to the round ligament of the uterus and the ilioinguinal nerve in females.

Boundaries of the Inguinal Canal (Fig. 47.8)

Anteriorly

Throughout its whole length there are skin, the superficial fascia and the aponeurosis of the external oblique and in its lateral 1/3rd there are the fleshy fibers of the origin of the internal oblique.

Posteriorly

The transversalis fascia along the whole length of the canal separates it from the extraperitoneal connective tissue and the peritoneum. In the medial half there are the conjoined tendon (combination of internal oblique and transversus muscles) and the reflected part of the inguinal ligament.

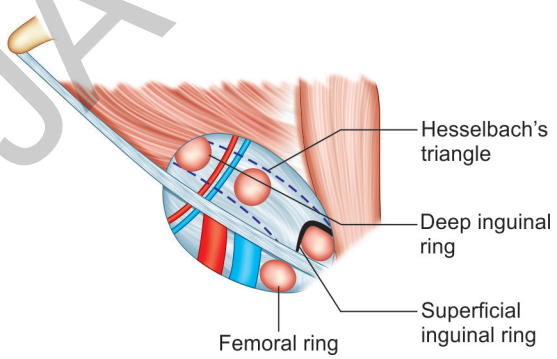

Fig. 47.8: Inguinal anatomy from anterior perspective.

Above

There are arched fibers of the internal oblique and transversus abdominis before they fuse to form the conjoined tendon.

Below or Floor

It is formed by the grooved upper surface of the inguinal ligament and its union with the fascia transversalis. At its medial end there is lacunar ligament. Presence of the canal weakens the lower part of the anterior abdominal wall. Obliquity of the canal to some extent compensates it, as increase in intra-abdominal pressure will cause approximation of the posterior wall to the anterior wall of the canal. The posterior wall is strengthened by the conjoined tendon and the reflected part of the inguinal ligament precisely behind the superficial ring and the fleshy fibers of the internal oblique strengthens the anterior wall of the canal in front of the deep inguinal ring.

Contents of the Inguinal Canal

- ***Ilioinguinal nerve*** in both sexes and it is particularly seen in the medial part of the canal. It pierces the internal oblique muscle, distributing filaments to it and then enters the inguinal canal in its midway and lies below the spermatic cord to accompany it through the superficial ring.
- In case of males, ***the spermatic cord and its coverings***
- In case of females, ***the round ligament of the uterus.***

Spermatic Cord

Coverings of the Spermatic Cord

When the testis descends through the abdominal wall into the scrotum it drags its vessels and nerves along with its ductus deferens. These structures meet at the deep inguinal ring and form the spermatic cord, which extends from the deep inguinal ring to the posterior border of the testis. In passing through the inguinal canal, the spermatic cord acquires coverings from the different layers of the abdominal wall and these coverings from within outwards are: (i) *The internal spermatic fascia* is derived from the fascia transversalis at the deep inguinal ring; (ii) The *cremasteric fascia,* which consists of a number of muscular fasciculi, constitutes the cremaster; (iii) *The external spermatic fascia* is a thin fibrous membrane continuous above with the aponeurosis of the obliquus externus abdominis at the superficial ring.

Structures of the Spermatic Cord

(i) The main constituent is the *vas deferens*; (ii) *Arteries of the spermatic cord* are—testicular artery, artery of the vas deferens and artery to the cremaster. (iii) *Pampiniform*

JAYPEE BROTHERS

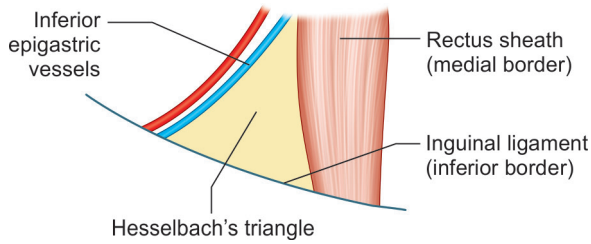

Fig. 47.9: Boundaries of the Hesselbach's triangle.

plexus of testicular veins. (iv) *Lymph vessels* of the testis. (v) *Nerves*—testicular plexus of sympathetic nerves which accompany the testicular artery and the artery of the ductus deferens, and the genital branch of the genitofemoral nerve.

Hesselbach's Triangle (Fig. 47.9)

It is a weak area of the anterior abdominal wall through which direct inguinal hernia protrudes. It is a triangle which is bounded: (i) *Medially:* By the outer border of the rectus abdominis muscle. (ii) *Laterally:* By the inferior epigastric vessels. (iii) *Below:* By the medial part of the inguinal ligament. The floor of this triangle is formed by fascia transversalis. This triangle is bisected by the medial umbilical fold which is formed by the obliterated umbilical artery. Through this Hesselbach's triangle, direct inguinal hernia comes out.

Mechanisms which Prevent Hernia in the Inguinal Region

Though inguinal region is a weak spot in the abdominal musculature, rise in intra-abdominal pressure would have caused inguinal hernia in every individual. So, there must be some defensive mechanisms which prevent hernia to occur. These are:

- **Obliquity of the inguinal canal:** When there is rise in intra-abdominal pressure the posterior wall is opposed to the anterior wall and thus prevents coming out of abdominal content through inguinal canal.
- *Shutter mechanism of the arched fibers* of the internal oblique and transversus abdominis will bring down these muscles towards the floor when they are contracted during rise of intra-abdominal pressure. It has been postulated that occurrence of direct inguinal hernia is often due primarily to a higher position of this transversus aponeurotic arch. So, when this muscle contracts, the arch is brought down, but it does not reach the inguinal ligament thereby leaving a weak area in the posterior wall of the inguinal canal.
- *Sphincter action of the transversus abdominis and internal oblique muscles* at the deep inguinal ring. There is transversalis fascial sling which is derived from the transversalis fascia and this sling reinforces the medial and inferior margin of the ring. When the transversus abdominis contracts it pulls the transversalis fascial sling superiorly and laterally. This acts both to close the deep inguinal ring around the cord and to pull the deep inguinal ring superiorly and laterally.
- *Ball-valve action of the cremaster* muscle which pulls up the spermatic cord into the canal and plug it during rise in intra-abdominal pressure.
- In front of the deep inguinal ring there are *strong fibers of the internal oblique.* This prevents entry of any abdominal content through the deep inguinal ring.
- *Strong conjoint tendon* is there in front of Hesselbach's triangle to prevent direct inguinal hernia.

Classification of Groin Hernia

Different classification systems exist, but ***EHS classification*** is mostly accepted worldwide. **P** = Primary; **R** = Recurrent **0** = No hernia detectable; **1** = <1.5 cm (one finger); **2** = <3 cm (two fingers); **3** = >3 cm (more than two fingers); **L** = lateral/indirect hernia; **M** = medial/direct hernia; **F** = femoral hernia. *A primary, direct hernia of 3.5 cm can be designated as* ***PM3****.*

Myopectineal orifice of Fruchaud (Fig. 47.10)
According to Fruchaud, all groin hernias originate within a single weak area, the myopectineal orifice. The myopectineal orifice is surrounded.
Superiorly, by internal oblique and transversus abdominis.
Inferiorly, by Cooper's ligament.
Medially, by lateral border of rectus muscle and sheath.
Laterally, by Iliopsoas muscle. The inguinal ligament and iliopubic tract divide the myopectineal orifice into *superior compartment* (indirect and direct inguinal hernia) and *inferior compartment* (femoral hernia).

INDIRECT INGUINAL HERNIA

Indirect inguinal hernia is also known as oblique or lateral hernia. In indirect inguinal hernia, the contents of the abdomen enter the deep inguinal ring *lateral* to the inferior epigastric vessels and traverse the whole length of the inguinal canal to come out through the superficial inguinal ring. This is much more common than direct inguinal hernia. This is more commonly seen among young individuals.

This hernia usually occurs when there is a preformed sac of partially or completely patent ***processus vaginalis*** in males and the corresponding ***canal of Nuck*** in females. Shortly after birth this processus vaginalis (corresponding canal of Nuck) becomes obliterated in normal individuals. Such obliteration occurs first at the deep inguinal ring, then just above the testis and finally the remaining part between the deep inguinal ring and the upper pole of the testis. Indirect inguinal hernia is more commonly seen on the right side, though in 1/3rd of the cases the hernia is or will be bilateral. If both sides are explored in an infant presenting

JAYPEE BROTHERS

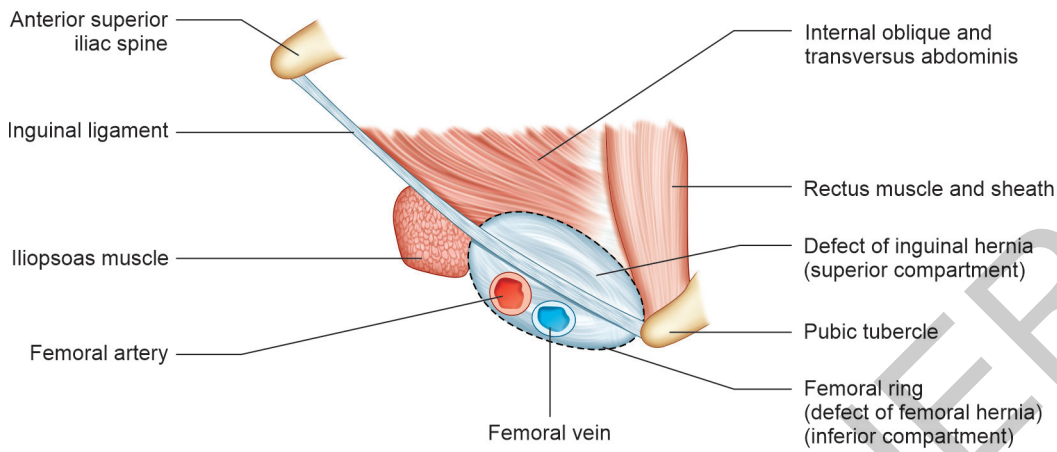

Fig. 47.10: Myopectineal orifice of Fruchaud.

with hernia on one side, in 60% of cases patent processus vaginalis will be evident on the other side. Particularly in children, hernia is more common on the right side.

- Inguinal hernia is the ***most common type of groin hernia*** in both males and females.
- Indirect inguinal hernia is the ***most common type of inguinal hernia***.
- Indirect inguinal hernias are ***more common in right side*** due to delayed obliteration of processus vaginalis in right side.
- In infants and children, inguinal hernias are ***exclusively indirect***.

According to the extent of the hernia, it can be divided into three types:

1. **Bubonocele (Fig. 47.11):** In this type, the hernia is limited in the inguinal canal and the processus vaginalis is closed at the superficial inguinal ring. This hernia presents as an inguinal swelling. The history is usually short and most of the patients are young adults.
2. **Funicular hernia (Fig. 47.12):** Here the processus vaginalis is closed at its lower end just above the epididymis. So, the content of the hernia can be felt separately from the testis, and the testis lies below the hernia. Most of this hernia occur in adults. A long-standing history is usually present in this type of hernia.
3. **Complete or scrotal hernia (Fig. 47.13):** Here the processus vaginalis is patent throughout. The hernia sac is continuous with the tunica vaginalis of the testis. In this type, the hernia descends down to the bottom of the scrotum lying in front and on the sides of the testis. The testis can be felt posterior to the hernia sac with great difficulty. Though it is a congenital hernia and commonly encountered in children, yet it may not appear until adolescent or adult life **(Fig. 47.14)**.



Fig. 47.11: Indirect inguinal hernia—bubonocele type.



Fig. 47.12: Indirect inguinal hernia—funicular type.

Coverings of Indirect Inguinal Hernia

From inside outwards the hernia sac is covered by the following structures:
(i) Peritoneum; (ii) Extraperitoneal fat; (iii) Internal spermatic fascia (derived from the fascia transversalis at

JAYPEE BROTHERS



Fig. 47.13: Indirect inguinal hernia—complete type.



Fig. 47.14: Indirect inguinal hernia in adult.

the deep inguinal ring); (iv) Cremasteric fascia and muscles (derived from internal oblique and transversus abdominis); the muscular fasciculae being separated by areolar tissue; (v) External spermatic fascia (derived from the intercrural fibers at the superficial inguinal ring); (vi) Superficial fascia.

When the hernia is a complete one, the dartos muscle of the scrotum comes in this layer.

DIRECT INGUINAL HERNIA

A direct inguinal hernia protrudes through the posterior wall of the inguinal wall medial to the inferior epigastric vessels, i.e., through Hesselbach's triangle. Such hernia lies outside the spermatic cord, either behind or above or below the cord. So, during surgery the most important differentiating feature is that the ***neck of the direct hernia lies medial to the inferior epigastric vessels, whereas the neck of the indirect hernia lies lateral to the inferior epigastric vessels.***



Fig. 47.15: Left sided direct inguinal hernia. Malgaigne's bulge is also clearly visible.

A direct hernia is usually acquired and most likely develop in elderly patients. Direct hernia almost always occurs in men. Women particularly never develop such hernia. Direct inguinal hernia rarely attains a large size. Even if it comes out through the superficial inguinal ring it never descends into the scrotum. As the neck of a direct hernia sac is wide, it rarely gets strangulated.

- Presence of both indirect and direct inguinal hernia in a same patient is termed as ***'Pantaloon hernia'***.
- ***Ogilvie hernia*** is a rare type of direct inguinal hernia where there is a small rigid circular defect in the conjoined tendon just lateral to where it inserts with the rectus sheath.

Malgaigne's bulge: Visible bilateral muscular bulge along the inguinal ligament during straining in thin individuals **(Fig. 47.15).**

Differentiating Features between Indirect and Direct Inguinal Hernia

Indirect	*Direct*
It can occur at any age, but more common in children and young adults	Elderly individuals are usually affected
Males are affected more commonly than females	Females are not affected
More often unilateral	In more than half of the patients, it is bilateral **(Fig. 47.16)**
Frequently, the hernia is complete and pyriform shaped. When it is incomplete it is oval shaped **(Fig. 47.14)**	Always incomplete and spherical shaped **(Fig. 47.15)**

Contd...

JAYPEE BROTHERS



Fig. 47.16: Bilateral inguinal hernia.

Contd...

Indirect	*Direct*
This hernia descends obliquely downwards and medially	This hernia appears as a forward bulge
Usually, this hernia is not reduced by itself	On lying down position, this hernia spontaneously reduces
In deep ring occlusion test, this hernia will not bulge out	In deep ring occlusion test, a bulge is visible medial to the occluding finger

Risk factors associated with inguinal hernia:
- Inguinal hernia in first-degree relative
- Male gender
- Decreased collagen type I : III ratio

EXAMINATION OF HERNIA

Clinical Features

History

- **Age:** Inguinal hernia can occur at any age. Indirect inguinal hernia may occur in children in the first few months of life, but is more common in the late teens and young adults. A direct hernia is mostly seen in older subjects.
- **Occupation:** Strenuous work is often associated with development of hernia. Heavy work, especially lifting weights, puts a great strain on the abdominal muscles. If underlying muscle weakness is already present, hernia may develop.
- **History of other risk factors:** History of chronic cough and constipation are important. History suggestive of bladder outlet obstruction is also very relevant because it is a risk factor and also changes the plan of management.
- **History of surgery:** History of inguinal hernia repair on ipsilateral side indicates the diagnosis of recurrent hernia.

Symptoms

- **Pain:** The most common symptom of hernia is discomfort or pain. Patient complains of a dragging or aching type of pain in the groin. Pain continues so long as the hernia is progressing but ceases when it is fully formed. In well-formed hernia, there is sense of heaviness. The patient may complain of pain all over the abdomen due to drag on the mesentery or omentum. ***When the hernia becomes very painful and tender, it is probably strangulated.***
- **Swelling in the groin:** Patient may complain of swelling in his groin for last few months. He may even notice that swelling becomes prominent on straining and gets smaller or totally disappear on lying down position. In infants and children, history of appearance of swelling in groin from his or her mother is more important because in most of these patients, hernia swelling is not obvious on clinical examination.
- **Systemic symptoms:** In obstructed inguinal hernia, cardinal symptoms of acute intestinal obstruction will appear. These are colicky abdominal pain, vomiting, abdominal distension and absolute constipation. ***Fecal smelling vomiting heralds ominous sign.***

Local Examination

The patient should be first examined in the standing position and then in the supine position. Majority of the hernia are better examined in the standing position.

Two classical signs of an uncomplicated hernia are: (i) Impulse on coughing and (ii) reducibility. Sometime must be spent for inspection.

- **Position and extent:** If the swelling descends into the scrotum or labia majora it is obviously an inguinal hernia. When it is confined to the groin, it should be differentiated from a femoral hernia. Two anatomical structures are to be considered in this respect—(a) the pubic tubercle and (b) the inguinal ligament. An inguinal hernia is positioned above the inguinal ligament and medial to the pubic tubercle, whereas a femoral hernia lies below the inguinal ligament and lateral to the pubic tubercle.
- **Shape:** A complete indirect inguinal hernia is usually pyriform shaped. A direct inguinal hernia is oval shaped.
- **Size:** Size of the indirect inguinal hernias may vary from small inguinal swelling to large inguinoscrotal swelling. Direct inguinal hernia usually presents with small to medium inguinal swelling.
- **Skin overlying the swelling:** Any operative scar over the swelling is suggestive of previous hernia repair. The

JAYPEE BROTHERS

color of the skin should be normal except in strangulated hernia.

- **Surface:** The surface is usually smooth but may vary depending on the contents of the sac.
- **Tenderness:** Uncomplicated hernia swelling is not tender, but any attempt to reduce the contents in incarcerated hernia can cause significant pain.
- **Consistency:** If the hernia contains omentum (omentocele or epiplocele) the swelling feels doughy and granular. If it contains intestine (enterocele) it feels elastic. ***A strangulated hernia feels tense and tender.***
- **Get above the swelling:** This examination differentiates a scrotal swelling from an inguinoscrotal swelling. The root of the scrotum is held between the thumb in front and other fingers behind, in an attempt to reach above the swelling. *In case of inguinal hernia, one cannot get above the swelling*, whereas in case of pure scrotal swelling, e.g., vaginal hydrocele one can get above the swelling.
- **Impulse on coughing:** When there is no swelling, the root of the scrotum is held between the index finger and thumb, and the patient is asked to cough. An expansile cough impulse can be felt as the contents of the hernia will be forced out through the superficial inguinal ring and will separate the thumb from the index finger. When hernia is already present it becomes larger and more tense on coughing. *Expansile cough impulse is absent in incarcerated hernia, obstructed and strangulated hernia.*
- **Reducibility:** The patient is first instructed to lie down on the bed. In many instances the hernia reduces itself when the patient lies down (small indirect hernia and direct hernia). The patient himself can often reduce the hernia. In the remaining cases the surgeon can reduce the hernia. The patient is asked to flex the thigh of the affected side, to adduct and rotate it internally. This will not only relax the pillars of the superficial ring but also the oblique muscles of the abdomen. The fundus of the sac is gently held with one hand and even pressure is applied to squeeze the contents into the abdomen while the other hand will guide the contents through the superficial inguinal ring. *This is known as* ***'Taxis'.***
- **Deep ring occlusion test (Fig. 47.17):** The hernia must be reduced first. A thumb is pressed on the deep inguinal ring, i.e., ½ inch above the mid-inguinal point. The patient is asked to cough. A direct hernia will show a bulge medial to the occluding finger, but an indirect hernia will not find access, so no bulge.
- **Invagination test:** After reduction of the hernia one can perform this test. The little finger is invaginated through the skin of the bottom of the scrotum and pushed up and then rotated to enter the superficial inguinal ring. Normally the superficial ring is a triangular slit which admits only the tip of the little finger. When the patient coughs the examining finger will be squeezed by the approximation of the two pillars. In indirect hernia, the impulse is felt at the tip of the finger whereas in direct hernia at the pulp of the finger. Most of the clinicians avoid this clinical method due to patient's inconvenience.
- **Zieman's technique (Fig. 47.18):** After reduction of hernia, the index finger is placed over the deep ring, middle finger over superficial ring, and the ring finger over the saphenous opening. Then, the patient is asked to cough. If an impulse is felt by the index finger, it is indirect hernia; if by the middle finger, it is direct hernia; and if by the ring finger, then it is femoral hernia.

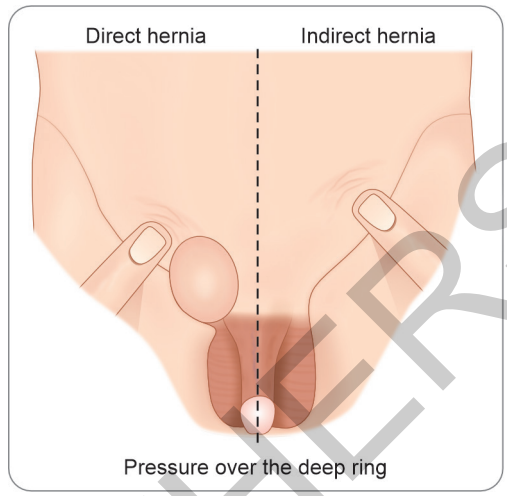

Fig. 47.17: Deep ring occlusion test.



Fig. 47.18: Zieman's technique.

- ***The cardinal features of hernia*** are reducibility and expansile impulse on coughing.
- ***Expansile cough impulse is absent*** in incarcerated hernia, obstructed and strangulated hernia.
- ***'Taxis' should not be attempted*** if any suspicion of obstruction or strangulation.
- In obese, very thin and pediatric patients, ***clinical examination*** for diagnosis of inguinal hernia is often ***inconclusive***.

JAYPEE BROTHERS

Hernia can be classified into:

- **Congenital:** When a preformed sac was present congenitally, i.e., presence of partly or completely unobliterated processus vaginalis. Most of the surgical communities believe that all indirect hernias are congenital. Though the sac was present since birth, the hernia may not appear until adult life.
- **Acquired:** When there was no preformed sac and the sac was acquired later in life. All direct hernias are acquired.

According to the contents of the sac, a hernia can be classified into:

1. **Enterocele:** When the sac contains intestine.
2. **Omentocele:** When the sac contains omentum.
3. **Entero-omentocele:** When the sac contains both intestine and omentum.

Difference between enterocele and omentocele

Enterocele	*Omentocele*
The hernial sac contains intestine	The hernial sac contains omentum
Consistency of the hernia is elastic	Consistency is doughy and granular
Reduction: This hernia reduces easily. The first part is more difficult to reduce than the last part	Reduction of hernia is difficult. The first part goes in easily but the last part resents to be reduced

Rare Varieties of Inguinal Hernia

- **Sliding hernia (Syn. Hernia-en-Glissade):** It is an unusual type of inguinal hernia where the posterior wall of the sac is formed by the sliding viscera. In such a hernia the cecum on the right side, the pelvic colon on the left side or the urinary bladder on either side may slide down. The sac may also contain the usual hernial contents.
  Sliding hernia may be suspected when it reappears very slowly after reduction. When a large globular hernia descends into the scrotum this condition is suspected.
  No attempt should be made to dissect the sliding viscera free from the peritoneum, it may cause fistula or peritonitis due to devascularization.
- **Interstitial hernia:** In this hernia, the hernial sac lies in between the muscle layers of the abdominal wall. The hernia is usually incomplete. It is commonly associated with an undescended testis. According to the position of the hernial sac such hernia can be classified into:
  - *Preperitoneal or intraparietal:* In this type of hernia, the sac lies between the peritoneum and fascia transversalis.
  - *Interparietal:* In this type, the hernia sac lies between internal oblique muscle and the external oblique aponeurosis.
  - *Extraparietal:* The hernia sac lies outside the external oblique aponeurosis in the subcutaneous tissue.

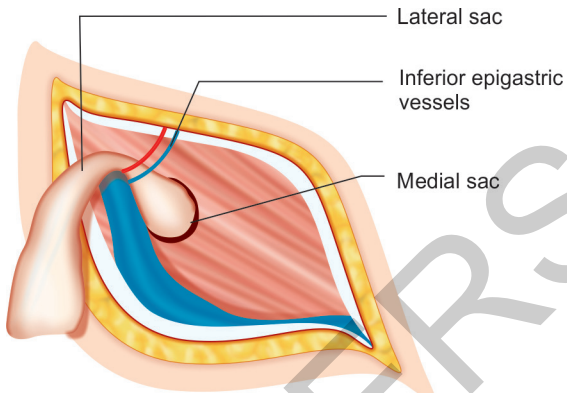

Fig. 47.19: Pantaloon hernia.

- **Richter's hernia:** Under the subheading 'Special types of strangulated hernia.'
- **Littre's hernia:** In this condition Meckel's diverticulum is the content of the hernia sac.
- **Maydl's hernia (Hernia-en-W):** Under subheading 'Special types of strangulated hernia.
- **Pantaloon hernia (Fig. 47.19):** A combination of both indirect and direct hernia. There may be a chance of recurrence if indirect sac is overlooked.

Differential Diagnosis

Differential Diagnosis of Inguinoscrotal Swelling

- **Encysted hydrocele of the cord:** When a part of the funicular process persists and remains patent, but there is no continuity of the tunica vaginalis below and peritoneal cavity above, it eventually gets distended with fluid and presents as cystic swelling either in the inguinal or inguinoscrotal region or in the scrotum. Fluctuation test and transillumination test will be positive. One can very well 'get above the swelling.' There will be no impulse on coughing. If the testis is pulled down the swelling comes down and becomes immobile. This is the traction test. The testis can be felt apart from the swelling.
- **Varicocele:** It is a condition in which the veins of the pampiniform plexus become dilated and tortuous. Usually, the left side is affected. The swelling appears when the patient stands and disappears when he lies down with the scrotum elevated. The impulse on coughing is more like a thrill. On palpation it feels like a 'bag of worms.' After occluding the superficial inguinal ring with a thumb, if the patient is asked to stand up the varicocele fills from below.
- **Lymph varix or lymphangiectasis:** It is a condition in which the lymphatic vessels of the cord become dilated and tortuous due to obstruction caused by filariasis. Past history of periodic attacks of fever with simultaneous development of pain and swelling of the cord are the main symptoms of this condition. The swelling appears

JAYPEE BROTHERS

on standing and disappears spontaneously on lying down, although slower than in case of varicocele. The impulse on coughing is thrill-like and not the typical expansile impulse found in a case of hernia. On palpation it feels soft, cystic and doughy.

- **Funiculitis:** Gonococcal infection and filariasis are mainly responsible for development of funiculitis in this subcontinent. The inguinoscrotal regions are inflamed, and the skin becomes red, edematous and shiny. It is sometimes very difficult to differentiate it from a small, strangulated hernia. Palpation just above the deep inguinal ring is of great help in differentiating these two conditions. In a strangulated hernia the abdominal contents can be felt as they enter the deep inguinal ring whereas in funiculitis no such structure can be felt.
- **Diffuse lipoma of the cord:** The cord feels soft and lobulated. The swelling is irreducible having no impulse on coughing.
- **Torsion of the undescended testis:** This condition mimics a strangulated hernia. It will give rise to tense and tender swelling without an impulse on coughing. Absence of testis in the scrotum should arouse suspicion of this condition. Slight fever, no constipation and dullness on percussion will go in favor of torsion.

Differential Diagnosis of Groin Swelling

- **Femoral hernia**
- **Saphena varix:** It is a saccular enlargement of the termination of the long saphenous vein. This swelling usually disappears completely when the patient lies down. The so-called impulse on coughing is present in this condition as well, but it is actually a fluid thrill and not an expansile impulse to the examining fingers. This condition is usually associated with varicosity of the long saphenous vein.
  Percussion on varicosities of the long saphenous vein will transmit an impulse upwards to the saphena varix felt by the fingers of the other hand- Schwartz's test. Sometimes a venous hum can be heard over the varix on auscultation.
- **Enlarged lymph node:** A search for a possible focus of infection should be made in the drainage areas. Enlarged lymph nodes secondary to inflammation are well circumscribed and tender. Malignant lymph nodes may present like incarcerated inguinal hernia. The gland of Cloquet lying within the femoral canal may be enlarged and simulates exactly an irreducible femoral hernia.
- **An enlarged psoas bursa:** Presence of osteoarthritis in the hip joint, a cystic swelling, absence of impulse on coughing and the finding that the swelling diminishes in size during flexion of the hip joint are the diagnostic points in favor of this condition.
- **Undescended or ectopic testis:** In both conditions the scrotum will be empty. Sometimes an undescended testis may be associated with an inguinal or an interstitial hernia.
- **Hydrocele of a femoral hernial sac:** A rare condition in which the neck of the sac becomes plugged with omentum or by adhesions.
- **Hydrocele of the canal of Nuck:** This swelling is fixed, smooth and translucent.
- **Femoral artery aneurysm:** A swelling with expansile pulsation below the midportion of the inguinal ligament.
- **Round ligament varicosities:** In pregnant women with groin swelling, round ligament varicosities should be considered in differential diagnosis of inguinal hernia, though it is rare.

> ***Cruveilhier's sign:*** Fluid thrill over the saphena varix when patient coughs.

Treatment

Elective surgery should be considered for all symptomatic inguinal hernias. ***"Watchful waiting"*** policy may be considered in asymptomatic or minimally symptomatic male inguinal hernia patients.

In pediatric hernia and indirect inguinal hernia in young adults, only herniotomy is indicated. In other patients, treatment of hernial sac followed by strengthening of the floor of the inguinal canal is the standard management.

Techniques of strengthening of the floor of the inguinal canal includes—(i) Primary tissue repair and (ii) Mesh-based repair. Mesh-based repair(hernioplasty) is recommended for inguinal hernias due to less risk of recurrence. *Primary tissue repair* may be considered if mesh is not available or patient is not willing to mesh use or mesh use is contraindicated. *In laparoscopic inguinal hernia repair,* reduction of hernial contents and hernial sac within the abdomen followed by placement of polypropylene mesh in the preperitoneal space covering the myopectineal orifice is the standard procedure. Laparoscopic repair is recommended for bilateral inguinal hernia repair and for recurrent hernia (if anterior primary tissue repair or mesh-repair is failed).

Primary tissue-based repair includes: (i) Modified Bassini repair; (ii) Shouldice repair; (iii) Moloney darn repair; (iv) Desarda technique; (v) McVay repair; (vi) Iliopubic tract repair.

Mesh-based repair includes: (i) Lichtenstein tension-free repair; (ii) Plug-and-patch technique; (iii) Open preperitoneal approach; (iv) Laparoendoscopic approach (TEP and TAPP).

Operations

Herniotomy: The incision is made ½ inch above and parallel to the medial 2/3rd of the inguinal ligament, i.e., almost on the inguinal canal **(Fig. 47.20A)**. The subcutaneous tissue is cut along the line of skin incision. The superficial tissue has two layers in this area—fascia of Camper, the fatty layer and

JAYPEE BROTHERS

the fascia of Scarpa, the membranous layer. Before the fascia of Scarpa is reached, the two named vessels come across the superficial epigastric and the superficial external pudendal. These vessels are ligated and divided. The fascia of Scarpa and the aponeurosis of the external oblique are cut in the same line **(Fig. 47.20B)**. The external oblique is cut up to the superficial inguinal ring so that the whole of the inguinal canal is exposed **(Fig. 47.20C)**. An incision is made on the cremasteric fascia and the internal spermatic fascia over the spermatic cord. After separating the margins of these fasciae, the white wall of the sac will come into view. The sac wall is held by a pair of forceps and is gradually separated from the spermatic cord by blunt dissections with a piece of gauze to minimize trauma to the structures of the spermatic cord. This separation should be started from the fundus and gradually extends towards the neck of the sac **(Fig. 47.20D)**.

The neck of the sac is identified by: (i) The constriction of the neck of the sac; (ii) The collar of extraperitoneal sac; (iii) The inferior epigastric vessels will be seen just medial to the neck of the sac in case of indirect hernia and lateral to it in case of direct hernia.

Direct sac should not be opened or ligated, but must be freed from transversalis fibers **(Fig. 47.20E)**. The indirect



Fig. 47.20A: The incision for inguinal hernia repair.

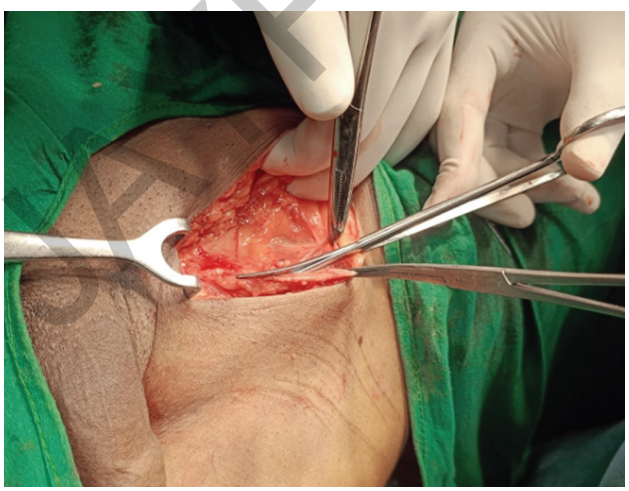

Fig. 47.20B: The external oblique aponeurosis is cut on the same direction of skin incision up to the superficial inguinal ring.

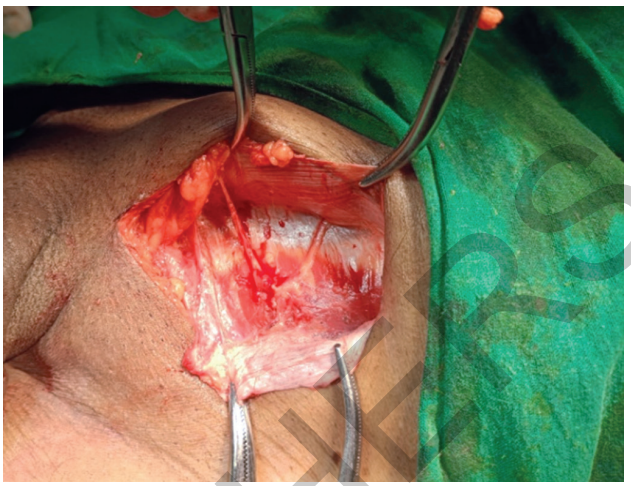

Fig. 47.20C: The inguinal canal is exposed.

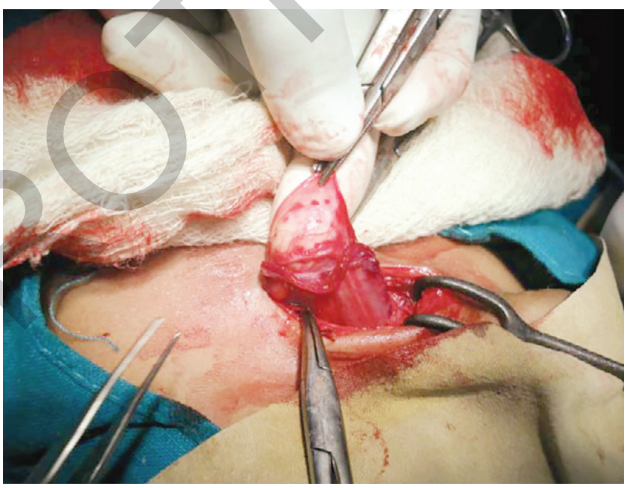

Fig. 47.20D: Dissection of indirect hernial sac.

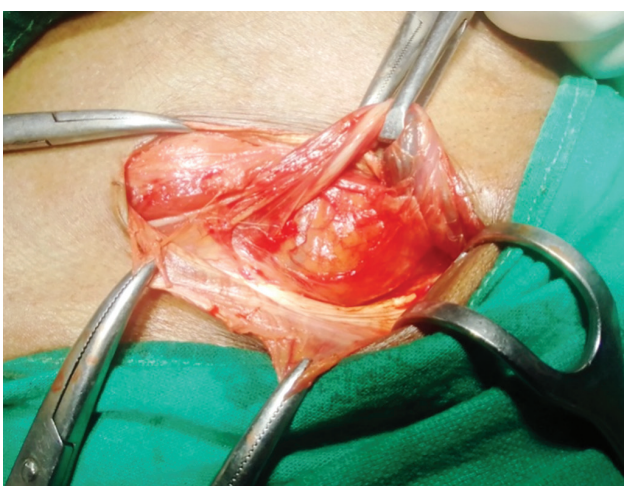

Fig. 47.20E: Direct sac should not be opened or ligated.

JAYPEE BROTHERS

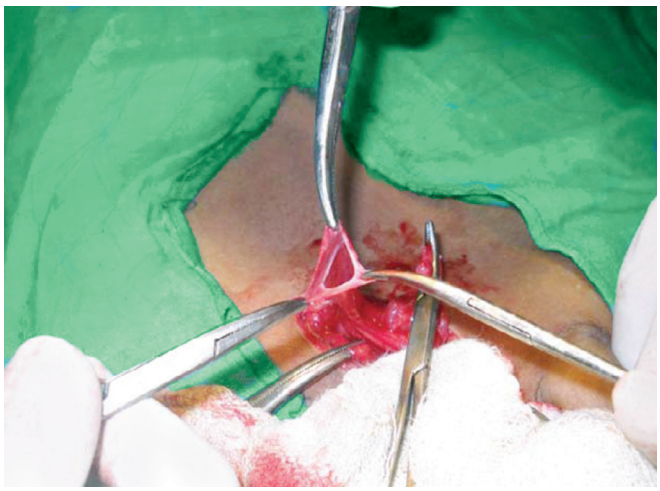

Fig. 47.21: Opening of the hernial sac.

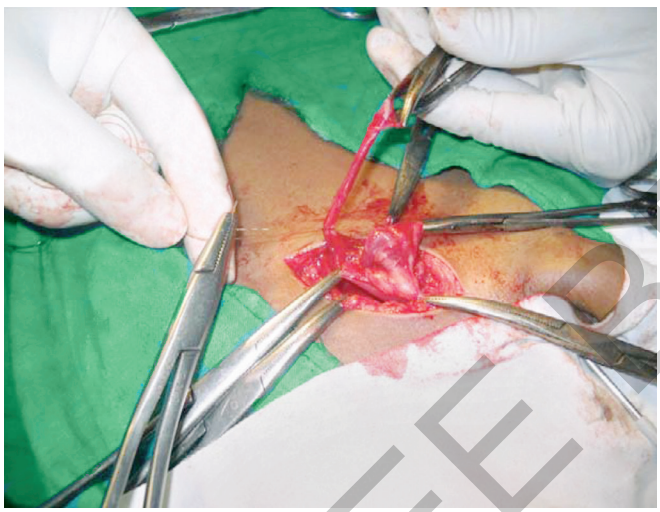

Fig. 47.22: Transfixation suture at the neck of sac.

sac is opened, and the contents are reduced **(Fig. 47.21).** ***In sliding hernia, the sac is opened but contents should not be dissected from the sac***. A finger is introduced into the sac to ensure that no contents are adherent to its neck. The neck of the sac is secured by means of a transfixing suture **(Fig. 47.22).** The sac is excised above the transfixation ligature. The stump will disappear under the arched fibers of the internal oblique. The spermatic cord is allowed to fall back to its normal position. The external oblique aponeurosis is sutured in front of the cord by continuous delayed absorbable suture. The most medial part is kept open so that a new superficial ring is constructed through which the structures of the spermatic cord emerges. The skin is closed with nonabsorbable monofilament suture or staples.

Bassini's repair: The main aim of this surgical procedure is to strengthen the posterior wall of the inguinal canal by stitching the lower margin of internal oblique and transversus abdominis and the conjoined tendon to the inner margin of the inguinal ligament behind the cord. 3 to 5 interrupted stitches are applied between the conjoined tendon on one side and the inner margin of the inguinal ligament on the other side. The most medial suture should be passed through the periosteum of the pubic tubercle instead of passing through the inguinal ligament, as this is the part through which most recurrences occur. While applying the middle suture, care must be taken not to injure the external iliac or femoral vein while taking a bite of the inguinal ligament, as these vessels lie just deep to it. The most lateral suture is placed to narrow the deep inguinal ring, and care must be taken not to exert undue constriction on the spermatic cord at the deep inguinal ring. Once repair of the posterior wall of the inguinal canal has been performed, the spermatic cord is placed in its position, and the external aponeurosis is sutured like the herniotomy procedure.

In modified Bassini's repair, after herniorrhaphy the conjoint tendon is sutured with the reflected part of the inguinal ligament by polypropylene suture.

Moloney's darn repair (Fig. 47.23): This is a tension-less tissue-based repair technique where a nonabsorbable suture (e.g., polypropylene) is used to bring down the musculoaponeurotic arch down to the inguinal ligament but without any effort to approximate the tissues under tension.

Shouldice repair: Shouldice repair is a four-layer tissue-based repair technique. In this technique, the fascia transversalis is divided. From the inferior epigastric vessels to the pubis, the fascia transversalis is then sutured with a continuous suture, 'double-breasting' the fascia starting from the pubic bone. This suture is done in two layers in which the free edge of the inferolateral flap is placed underneath the superomedial flap of the fascia transversalis. After this repair, the arched fibers of the transversus abdominis and internal oblique are sutured to the deep border of the inguinal ligament as Bassini's repair.

Desarda repair: This is a tissue-based repair technique. The repair is done by using a 1-to-2-cm strip of external oblique aponeurosis that is sutured to the inguinal ligament below and to the aponeurotic part of internal oblique above.

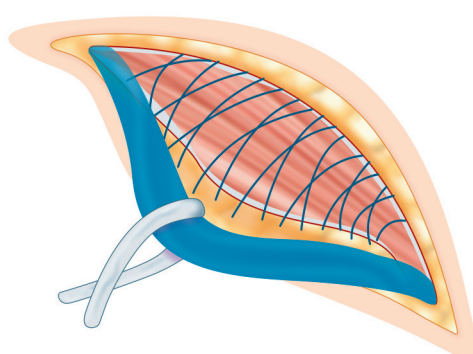

Fig. 47.23: Moloney's darn repair.

JAYPEE BROTHERS

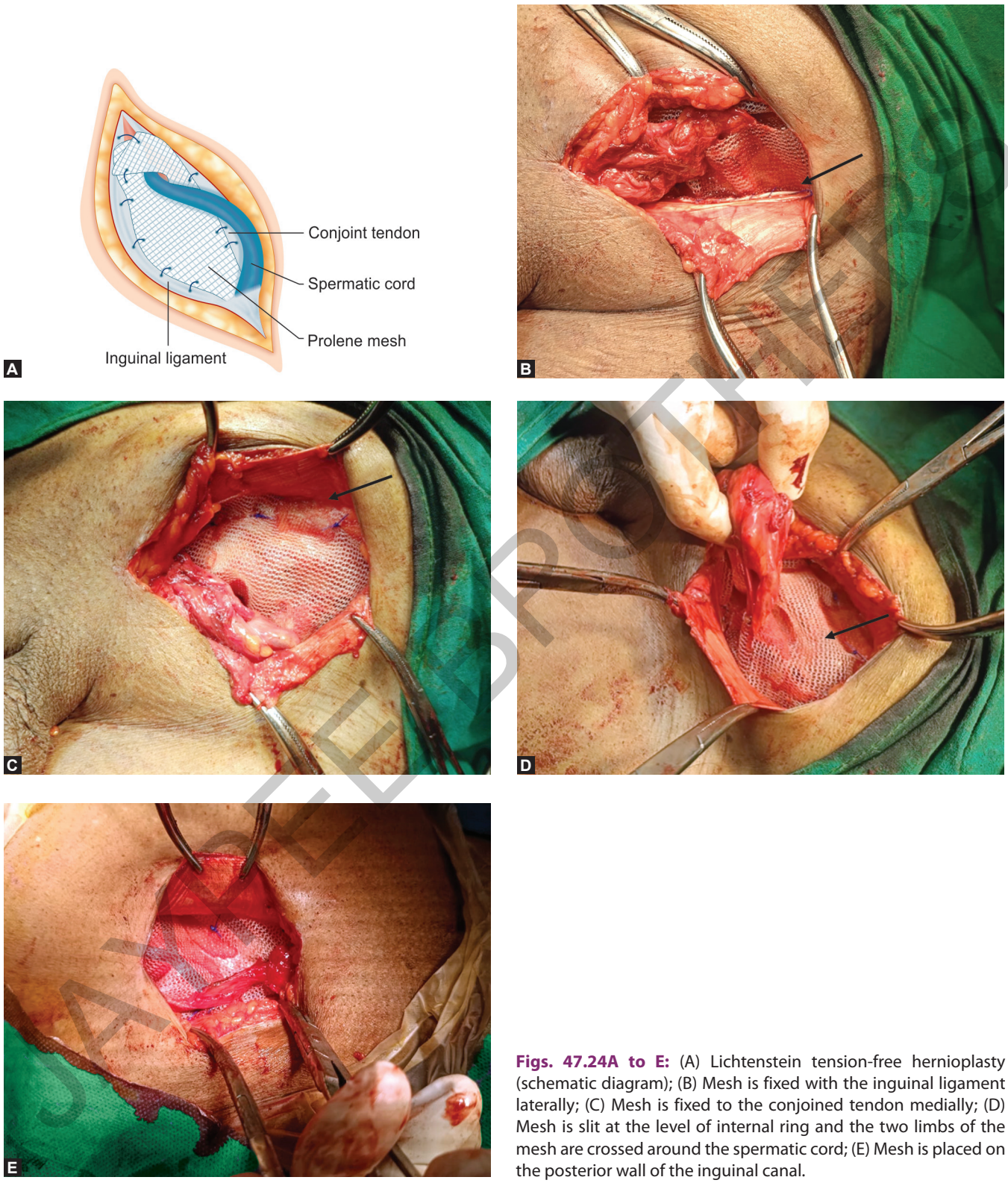

Figs. 47.24A to E: (A) Lichtenstein tension-free hernioplasty (schematic diagram); (B) Mesh is fixed with the inguinal ligament laterally; (C) Mesh is fixed to the conjoined tendon medially; (D) Mesh is slit at the level of internal ring and the two limbs of the mesh are crossed around the spermatic cord; (E) Mesh is placed on the posterior wall of the inguinal canal.

Lichtenstein repair (Figs. 47.24A to E): This is a mesh-based repair technique that includes placement of polypropylene mesh measuring 8 × 15 cm over the floor of the inguinal canal. The mesh is sutured to the fascia overlying the pubic tubercle inferiorly, conjoint tendon medially, and inguinal ligament laterally. This is the most commonly practiced hernioplasty technique worldwide.

JAYPEE BROTHERS

Laparoscopic hernia repair: This repair technique is based on reduction of hernial contents and hernia sac within the abdomen followed by placement of mesh in the preperitoneal space covering the myopectineal orifice. Laparoscopic repair is particularly indicated in bilateral inguinal hernia and recurrent hernia after open repair.

Two approaches are: (i) Transabdominal pre-peritoneal (TAPP) and (ii) Totally extraperitoneal (TEP). In both these approaches, the initial access is different, but the final target is the same (preperitoneal space). In TAPP repair, the preperitoneal space is accessed after entering into the peritoneal cavity. In TEP repair, the preperitoneal space is created just deep to the abdominal muscles without breaching the peritoneum by balloon dissector.

TAPP and TEP have almost similar outcomes, so the choice of approach should be based on surgeon's experience and expertise.

Role of Orchidectomy in Inguinal Hernia Repair

While preserving the spermatic cord, there is no doubt that we are allowing some weakness in the inguinal region, e.g., the deep inguinal ring and the superficial inguinal ring remain however narrow they may be. Hence, orchidectomy should be considered when function of testis is no more required and it can be sacrificed to give complete strength to the inguinal region to prevent recurrence. These cases are *elderly patients, with very weak inguinal musculature, with very big hernia, or recurrent hernia.* The proper counseling and consent taking should be done from the patient before the operation.

Recurrent Inguinal Hernia

In approximately 10% cases inguinal hernia may recur. Though recurrence rate is more common in direct hernia, yet due to much increased incidence of indirect hernia, incidence of recurrence is more in case of indirect hernia. There are various causes of recurrence of a hernia.

The causes can be classified as follows:

- **Types of hernia:** (i) Sliding hernia; (ii) Very large and long-standing hernia; (iii) Large direct hernia; (iv) Pantaloon hernia.
- **Type of patients:** (i) Patients with chronic bronchitis, bladder outlet obstruction or chronic constipation; (ii) patients with weak inguinal muscles, e.g., presence of long Malgaigne's bulging.
- **Operative factors:** (i) Failure to ligate the sac at the neck; (ii) Tension in the stitches in herniorrhaphy; (iii) Fault in the selection of operation. Herniotomy has been performed when herniorrhaphy should be the treatment of choice, or herniorrhaphy has been chosen in place of hernioplasty; (iv) Inadequate medial fixation of mesh in Lichtenstein repair; (v) Inadequate mesh overlap in laparoscopic repair.
- **Postoperative cause:** Surgical site infection.

It must be remembered that majority of recurrence takes place within 1 year of operation.

Appearance of new hernia: Sometimes a recurrent hernia is in fact not a recurrence but appearance of new hernia. After a correct repair of indirect hernia, a direct hernia may appear later on.

Treatment of Strangulated Inguinal Hernia

Emergency open surgery is the preferred surgical approach for suspected strangulated inguinal hernia. After admission patient should be properly resuscitated with intravenous fluids, nasogastric suction, urinary catheterization (to monitor urine output) and parenteral antibiotics. Emergency hernia repair for strangulated inguinal hernia includes resection of gangrenous gut followed by primary repair or tissue repair.

The initial steps are almost similar to elective inguinal hernia repair except that the incision should be extended further medially up to the root of scrotum.

When the hernial sac is reached it is advisable to open at its fundus before the constriction is relieved.

This is done to avoid the risk of contaminating the peritoneal cavity with highly toxic fluid swarming with the organisms in the sac containing devitalized bowel. Another advantage is that the contents of the sac will not get opportunity to slip inside the abdomen before they are thoroughly examined.

The constriction is now divided.

The constriction ring may be present (a) at the superficial inguinal ring or (b) midway between the superficial and the deep inguinal ring, (c) at the deep inguinal ring or (d) anywhere along the sac. If the constriction ring is at the level of deep inguinal ring, the inferior epigastric vessels are in danger of being injured during division of the constriction ring. In this case the constriction ring is divided parallel to the inferior epigastric vessels, i.e., upwards and inwards.

Once the constriction ring is divided, the bowel must be drawn out in order to examine the constricted area and the loop proximal to it. If the loops of intestine slip back immediately after the constriction has been divided, the affected loops of bowel should be sought for within the peritoneal cavity.

Next the viability of the bowel should be assessed.

The loop of bowel is most likely nonviable if:

- The gut becomes greenish or blackish in color.
- The gut becomes flaccid and lusterless.
- Absence of peristalsis.
- The fluid in the hernial sac is blood-stained and foul-smelling.

When the viability of the involved bowel loop is questionable, hot wet surgical mops are placed over the bowel and the anesthesiologist is asked to administer 100% oxygen. After

JAYPEE BROTHERS

about 10 minutes, the bowel is again assessed for viability. If the loop is gently pinched with a pair of nontoothed forceps, starting of peristaltic movements suggest viability. Returning of pink color also indicate returning of viability.

If the involved bowel is viable, it should be returned back to the peritoneal cavity. The sac is ligated at the neck and excised followed by mesh repair.

If the small bowel is nonviable, either resection followed by end-to-end anastomosis or resection followed by exteriorization of bowel depending on the general condition of the patient. If the large bowel is nonviable, resection followed by exteriorization of bowel is the preferred surgical approach.

If the omentum is strangulated, the healthy part above should be transfixed, and the nonviable omentum is excised.

In presence of gross enteric spillage from the gangrenous gut, primary tissue repair is the ideal option. *If gross spillage is absent,* mesh repair can be considered without any increase in 30-day wound-related morbidity.

- **Lichtenstein tension-free hernioplasty** is the most common open surgical approach for inguinal hernia.
- **Direct sac** should not be opened or ligated.
- **In sliding hernia,** no attempt should be made to dissect the contents from the sac.
- During repair of **inguinal hernia in female patients**, it is better to avoid division of round ligament.
- **McVay (Cooper's ligament) repair** is the only hernia repair technique where both inguinal and femoral hernia can be repaired.
- Indirect inguinal hernias are **more commonly strangulated** than direct inguinal hernias.
- **Small intestine is more commonly involved** than large intestine in strangulated inguinal hernia.

FEMORAL HERNIA

In this type of hernia abdominal contents pass through the femoral ring, traverse the femoral canal and come out through the saphenous opening.

Femoral hernia is the 3rd according to frequency, after inguinal and incisional hernia. It is more common in females and accounts for 20% of cases of hernia. Only 5% of cases of hernia in males are femoral hernia.

Femoral hernia is most liable to get strangulated.

SURGICAL ANATOMY

Femoral ring (Fig. 47.25) is an oval opening ½ inch in diameter (larger in women than in men) which is normally closed by the femoral septum, which is nothing but thickened extraperitoneal tissue. It is bounded:

- *In front* by the inguinal ligament.
- *Behind* by the pectineus muscle covered by its fascia and the pectineal ligament of Cooper, a thickened band along the iliopectineal line. *Medially*, it is covered by the free margin of Gimbernat's ligament (lacunar ligament). Sometimes the pubic branch of the inferior epigastric artery takes the place of the obturator artery and is known as abnormal obturator artery. This artery often curves round the medial margin of the femoral ring and is liable to be injured while cutting the medial margin of the lacunar ligament to relieve the strangulated femoral hernia.
- *Laterally* the ring is bounded by a septum which separates it from the femoral vein.

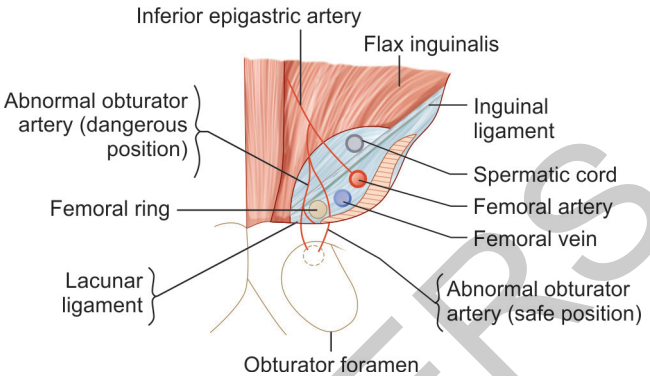

Fig. 47.25: Position of the femoral ring through which femoral hernia protrudes.

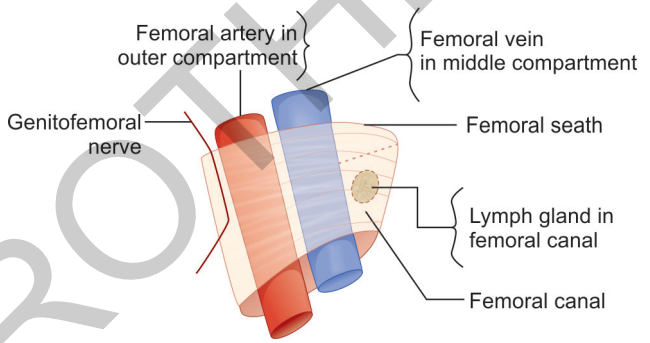

Fig. 47.26: Femoral canal.

Femoral canal (Fig. 47.26) is the innermost compartment of the three compartments of the femoral sheath. It is about 2 cm in length and is funnel shaped. The middle compartment of this sheath carries the femoral vein, while the outer compartment carries the femoral artery. *The femoral canal* contains areolar tissue, fat, lymphatic vessels and the lymph node of Cloquet. It is closed above by the femoral septum at the femoral ring. The femoral sheath is formed by two fascial layers. The anterior layer is the downward prolongation of the fascia transversalis behind the inguinal ligament and in front of the femoral vessels. The posterior layer is the downward prolongation of the fascia iliaca behind the femoral vessels. Posteriorly, the femoral sheath rests on the pectineus and adductor muscles medially and the psoas major and iliacus muscles laterally. Thus, the femoral canal lies in front of the pectineus muscle.

JAYPEE BROTHERS

for detailed information on surgery books, visit our website www.ejaypee.com, for detailed information on surgery books, visit our website www.ejaypee.com, for detailed inform

S DAS CONCISE TEXTBOOK OF
SURGERY

Salient Features

- All important surgical diseases are discussed in a concise and well-understood manner.
- New chapters, i.e., Basics of Oncology, Basics of Transplantation, and Basics of Minimally Invasive Surgery, Trauma, and Anesthesia are included in this edition.
- Multiple choice questions (MCQs) with answers are included at the end of each chapter (except Instrument chapter), total 1,500+ MCQs.
- Boxes for key points are in each chapter for quick revision.
- Diagnosis and management part are discussed based on recent national and international guidelines.
- Relevant schematic diagrams and clinical photographs (e.g., disease, imaging, and operative) are included in each chapter.

Nilay Mandal MS (General Surgery) is a Professor in the Department of Surgery, Calcutta National Medical College and Hospital, Kolkata, West Bengal, India. He has a teaching experience of more than 16 years and both undergraduate and postgraduate examiner for last few years. He has published articles in various national and international journals and also reviewer of surgical journals. He is the author of "Illustrated Surgery—A Basic Roadmap for the Postgraduates" and the chief editor of "Postgraduate Surgery", published by Jaypee Brothers Medical Publishers(P) Ltd, New Delhi, India. He is also the revisor and editor of "S Das A Textbook of Short and Long Cases in Surgery", 7th edition, and the chief editor of "Surgery MS: Suturing Your Clinical Gaps", an online course in "DigiNerve" app.

diginerve®
A Jaypee Initiative
• Video Lectures • Dr. Wise AI Chatbot
• Question Bank • Notes
Download App

Shelving Recommendation
SURGERY

ISBN 978-93-0952-799-9

Buy from ejaypee

JAYPEE BROTHERS