SANDEEP SAXENA

CLINICAL OPHTHALMOLOGY
Medical & Surgical Approach

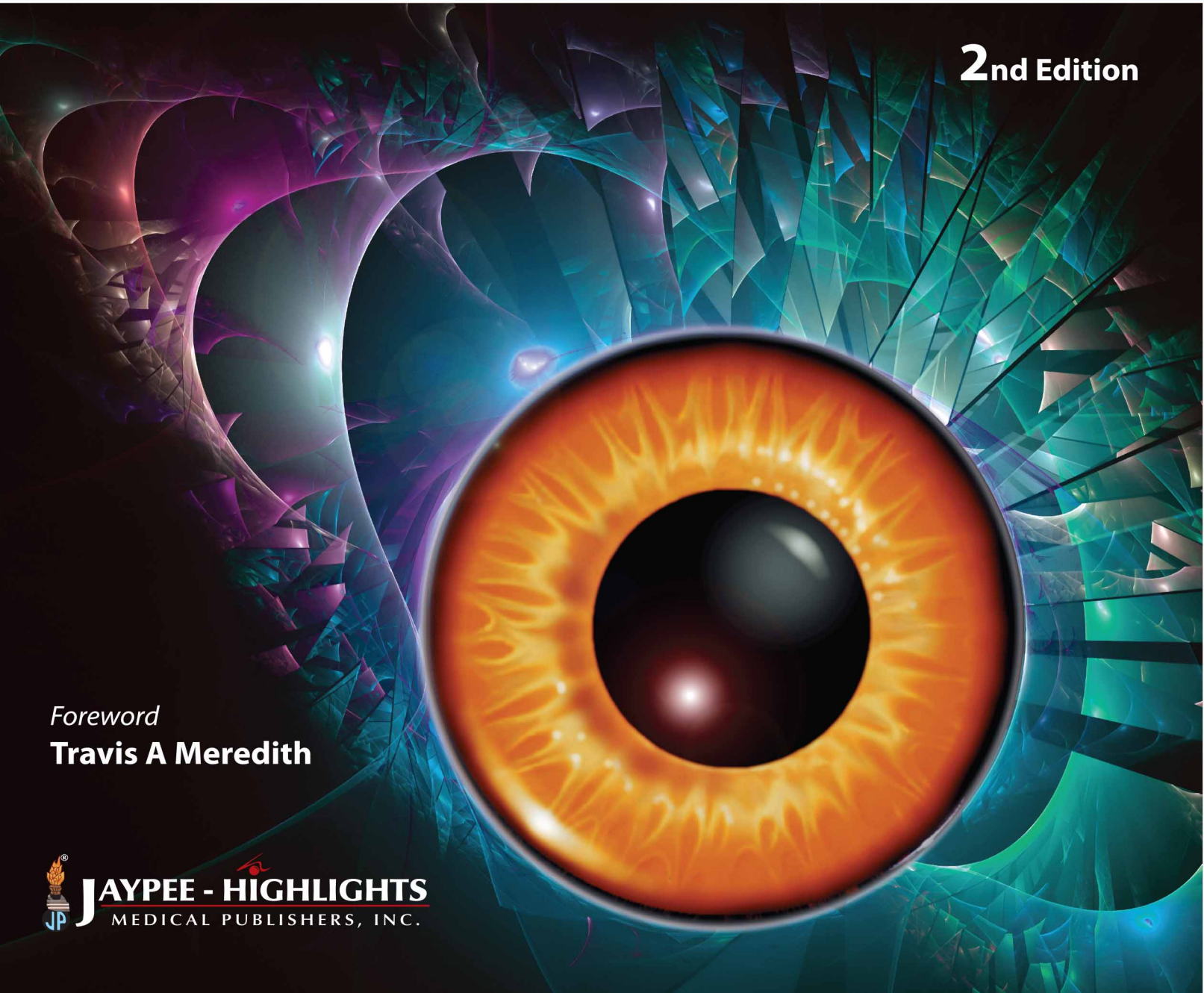

2nd Edition

Foreword
Travis A Meredith

JAYPEE - HIGHLIGHTS
MEDICAL PUBLISHERS, INC.

Contents

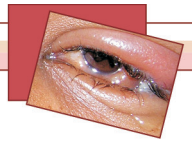

SECTION-1 Corneal and External Diseases **1**

1. Investigations for Corneal and External Diseases 3
   Poonam Kishore, Preeti Gupta
2. External Eye Diseases 14
   Samar K Basak
3. Diseases of Cornea 44
   Sunita Chaurasia, R Muralidhar, Mukesh Taneja, Virender Sangwan
4. Corneal Surgeries 70
   Srinivas K Rao, Late G Sitalakshmi
5. Refractive Surgeries 120
   Ritika Sachdev, Namrata Sharma, Rajesh Sinha, Jeewan S Titiyal

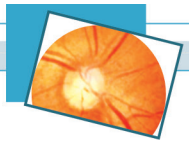

SECTION-2 Glaucoma **137**

6. Automated Visual Field Assessment, Optic Nerve and Nerve Fiber Layer Imaging 139
   M Baskaran, Arun Narayanaswamy, Lingam Vijaya
7. Optic Disc Assessment 158
   Harmohina Bagga, G Chandra Sekhar
8. Primary Congenital Glaucoma 164
   Sushmita Kaushik, Surinder S Pandav
9. Primary Angle-Closure Glaucoma 168
   Harmohina Bagga, G Chandra Sekhar
10. Primary Open-Angle Glaucoma 177
    M Baskaran, Arun Narayanaswamy, Lingam Vijaya
11. Secondary Glaucoma 189
    Kirti Singh
12. Investigative Techniques Helpful in Glaucoma Surgeries 217
    Tanuj Dada, Parul Sony
13. Glaucoma Surgeries 229
    Lingam Vijaya, M Baskaran, Ronnie George, Arun Narayanaswamy, Sachi Devi, Aditya Neog
14. Non-Penetrating Glaucoma Surgeries 261
    Kirti Singh
15. Nd:YAG Laser Iridotomy, Selective Laser Trabeculoplasty and Cyclophotocoagulation 266
    Sushmita Kaushik, Surinder S Pandav

SECTION-3 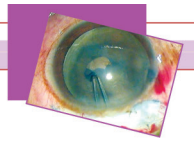 **Cataract** **273**

16. Technological Advances in Intraocular Lenses and Instrumentation 275
Jagat Ram, Gagandeep S Brar

17. Phacoemulsification 283
Kumar Doctor

18. Microincision Cataract Surgery 317
Kumar Doctor, Chanda Hingorani

19. Multifocal Intraocular Lenses 321
Leonardo Akaishi, Canrobert Oliveira

20. Small Incision Cataract Surgery 326
Albrecht Hennig, Vinita Singh

21. Pediatric Cataract Surgery and Intraocular Lens Implantation 339
Jagat Ram, Gagandeep S Brar

SECTION-4 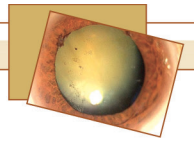 **Uveitis** **347**

22. Uveitis 349
Chinmaya Sahu, S Sudharshan, Jyotirmay Biswas

23. Surgery in Uveitis: Diagnostic and Therapeutic 397
Vishali Gupta, Sushmita Kaushik, Amod Gupta

SECTION-5 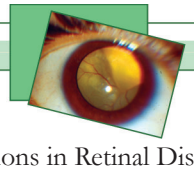 **Vitreoretinal Diseases** **407**

24. Investigations in Retinal Diseases 409
Sandeep Saxena

25. Spectral-Domain Optical Coherence Tomography in Macular Diseases 422
Sandeep Saxena

26. Macular and Allied Disorders 431
Pradeep Venkatesh, Lalit Verma, Hem K Tewari

27. Retinal Vascular Disorders 454
Taraprasad Das, Subhadra Jalali, Vasumathy Vedantham, Ajit B Majji

28. Laser Treatment in Posterior Segment Disorders 473
Pradeep Venkatesh, Satpal Garg

29. Anti-Vascular Endothelial Growth Factor Therapy 499
Atul Kumar, Subijoy Sinha

30. Vitreoretinal Surgeries 509
Lingam Gopal

31. Macular Surgeries 563
Sandeep Saxena

32. Hereditary Vitreoretinal Diseases 593
Parveen Sen, R Priya, J Manju

33. Ocular Oncology 647
Mahesh P Shanmugam, Praveen R Murthy, Krishna R Murthy

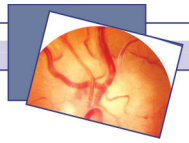

SECTION-6 Diseases of Optic Nerve 671

34. Optic Nerve Disorders 673
Radhika Tandon, Lalit Verma

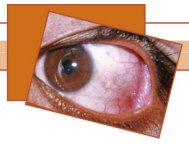

SECTION-7 Diseases of Lid, Orbit and Lacrimal System 687

35. Orbital Imaging 689
Apjit Kaur, Mohit Khattri

36. Diseases of the Eyelid and Orbit 697
Santosh G Honavar, Milind N Naik, Geeta K Vemuganti, G Chandra Sekhar

37. Diseases of Lacrimal Drainage System 720
Arnab Biswas

38. Eyelid and Lacrimal Surgeries 727
Milind N Naik, Santosh G Honavar

39. Periorbital Rejuvenation 759
Milind N Naik, Rashmi Shetty

40. Orbital Surgeries 765
Santosh G Honavar, Milind N Naik

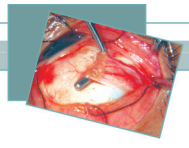

SECTION-8 Strabismus 775

41. Strabismus 777
Kanwar Mohan

42. Surgical Treatment of Strabismus 796
Vinita Singh

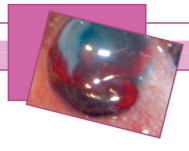

SECTION-9 Trauma 817

43. Ocular Trauma 819
S Natarajan, Kavita Rao, Arindam Chakravarti

SECTION-10 Practice Management **835**



44. Ophthalmology Practice Management 837
Sandeep Saxena, Puneet Saxena, Manoj K Tangri



Index **847**

Index *847*

Chapter



3 Diseases of Cornea

Sunita Chaurasia, R Muralidhar, Mukesh Taneja, Virender Sangwan

JAYPEE BROTHERS

BACTERIAL KERATITIS

Introduction

Bacterial keratitis is an ocular emergency that requires immediate and appropriate treatment to limit corneal morbidity and vision loss. Bacterial keratitis is the most prevalent type of serious ocular infection. The challenge for eye care providers is to distinguish bacterial keratitis from other infectious and noninfectious inflammatory conditions by assessing risk factors and evaluating clinical presentations.

Pathogens

The most common groups of bacteria responsible for bacterial keratitis are:

- Streptococcus
- Pseudomonas
- Enterobacteriaceae (including Klebsiella, Enterobacter Serratia, and Proteus), and
- Staphylococcus species.

Risk Factors

Several risk factors may lead to bacterial keratitis:

(a) Any factor that creates a breakdown of the corneal epithelium
(b) Exposure to some virulent bacteria that may penetrate intact epithelium (e.g. *Neisseria gonorrhoeae, Streptococcus pneumoniae*)
(c) Use of contact lenses, especially extended-wear contact lenses
(d) Contaminated ocular medications or contact lens solutions
(e) Decreased immunologic defenses secondary to malnutrition, alcoholism and diabetes
(f) Aqueous tear deficiencies
(g) Recent corneal disease (herpetic keratitis and secondary neurotrophic keratopathy)
(h) Structural alteration or malposition of the eyelids (entropion with trichiasis and lagophthalmos)
(i) Chronic dacryocystitis
(j) Use of topical corticosteroids

Pathophysiology

Interruption of an intact corneal epithelium permits the entrance of microorganisms into the corneal stroma, where they may proliferate and cause ulceration. Various virulence factors may initiate microbial invasion and effect or molecules may assist the infective process. Many bacteria display several adhesins on fimbriated and nonfimbriated structures that may aid in their adherence to host corneal cells. During the initial stages, the epithelium and stroma in the area of injury and infection swell and undergo necrosis. Acute inflammatory cells infiltrates base of the ulcer and cause necrosis of the stromal lamellae. Diffusion of inflammatory products (including cytokines) posteriorly elicits an outpouring of inflammatory cells into the anterior chamber and may create a hypopyon. Different bacterial toxins and enzymes (including elastase and alkaline protease) may be produced during corneal infection, contributing to the destruction of corneal substance.

History

Patients with bacterial keratitis are usually present with the rapid onset of pain, photophobia and decreased vision. It is important to document a complete systemic and ocular history in these patients to identify any potential risk factors that would have made them susceptible to develop this infection, including the following:

- Contact lens wear
- Trauma (including previous corneal surgery)
- Use of contaminated ocular medications
- Decreased immunologic defenses
- Aqueous tear deficiencies
- Recent corneal disease (herpetic keratitis, neurotrophic keratopathy)
- Structural alteration or malposition of the eyelids

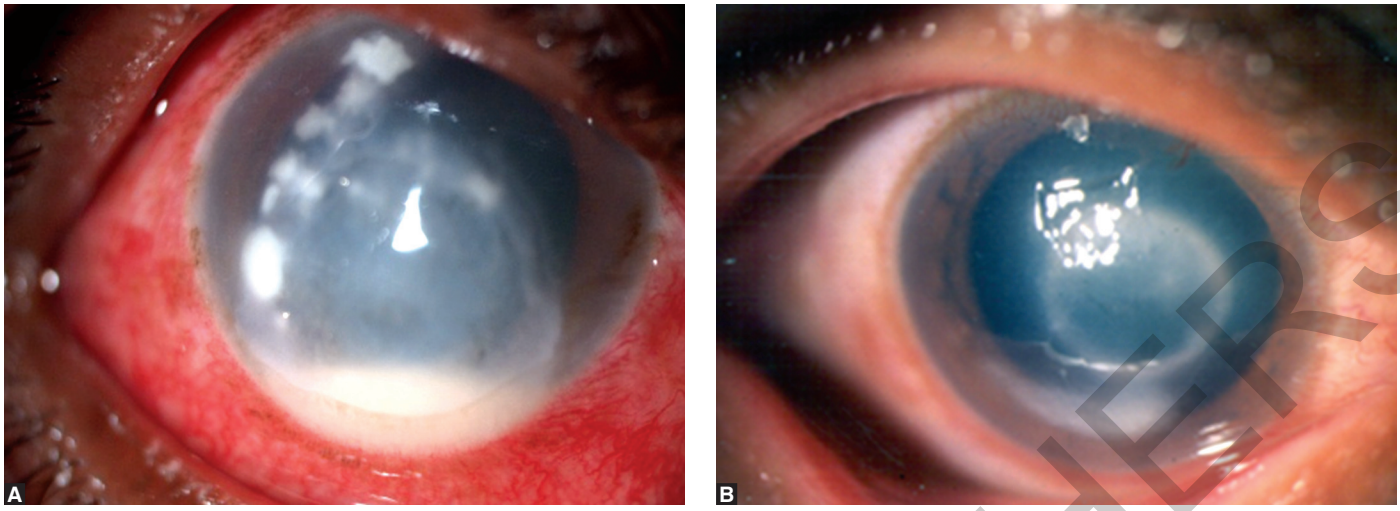

Figs 3.1A and B: Bacterial keratitis. *Pseudomonas* bacterial keratitis

Examination

On slit-lamp biomicroscopy, ulceration of the epithelium and corneal infiltration with no significant tissue loss may be observed. Dense, suppurative stromal inflammation with indistinct edges, stromal tissue loss and surrounding stromal edema may also be observed (Figs 3.1A and B and 3.2). There may be increased anterior chamber reaction with or without hypopyon, folds in the Descemet's membrane, upper eyelid edema, posterior synechiae and surrounding corneal inflammation may be observed which could be either focal or diffuse.. Conjunctival hyperemia and mucopurulent discharge is also observed. Endothelial inflammatory plaque/immune ring may also be present.

Microbiological Examination

A scraping of the corneal ulcer, including the edges, is obtained using a sterile Kimura's spatula or No. 15 Bard-Parker blade. Microscope slides are used for stained smears with Gram, Giemsa, and acid-fast stain or KOH-calcofluor white (if fungi or acanthamoeba or microsporidia are suspected) (Figs 3.3 to 3.5).

Samples of the eyelids/conjunctiva, topical ocular medications, and contact lens cases and solutions also may be cultured. If the patient has been treated partially and the keratitis is mild or moderately severe, antibiotic therapy can be suspended for 12 to 24 hours before obtaining corneal samples for culture and sensitivity, to increase the yield of a positive culture. Cotton swabs contain fatty acids, which have an inhibitory effect on bacterial growth. On the other hand, calcium alginate moistened with trypticase soy broth can be used to obtain culture material to inoculate directly onto the culture media.

Topical anesthetic (proparacaine hydrochloride 0.5%) should be used to anesthetize the patient prior to culture scraping because it has the least inhibitory effect. Repeat cultures can be obtained if the original cultures were negative and the ulcer is not improving clinically.

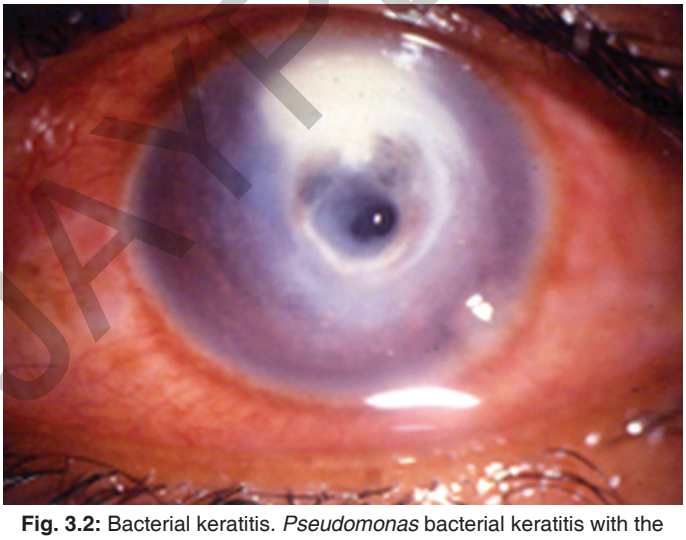

Fig. 3.2: Bacterial keratitis. *Pseudomonas* bacterial keratitis with the prolapse of iris

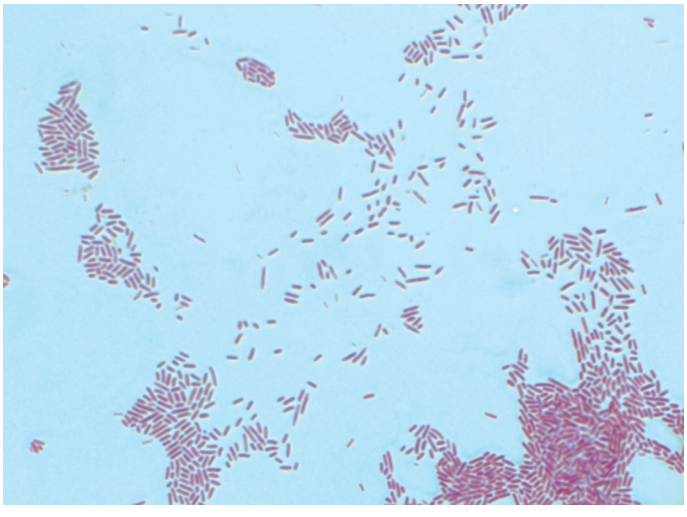

Fig. 3.3: Bacterial keratitis. Gram smears shows Gram-negative bacilli

JAYPEE BROTHERS

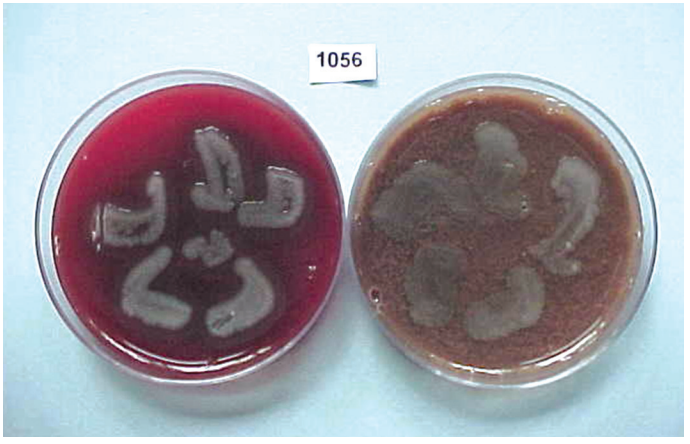

Fig. 3.4: Bacterial keratitis. Gray, moist colonies of *Pseudomonas*

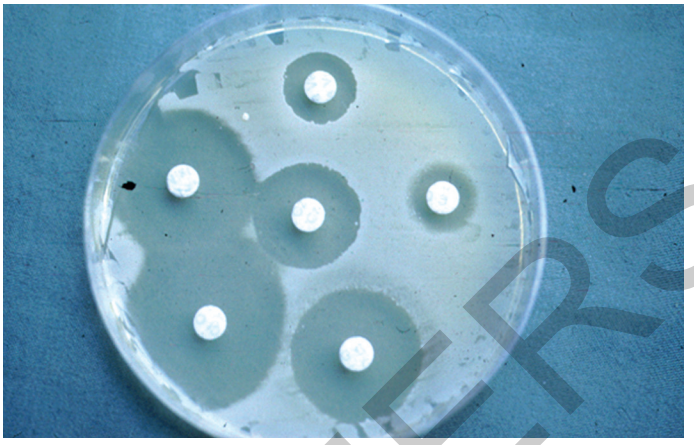

Fig. 3.5: Bacterial keratitis. Kirby Bauer disc diffusion method

Corneal biopsy using a small trephine or a corneal blade may be considered in the cases of deep stromal infiltrates, particularly if cultures are negative and the eye is not improving clinically.

Corneal Biopsy

A deep lamellar excision can be made using a disposable skin punch or a small Elliott corneal trephine. The superficial cornea is incised and deepened with a surgical blade to approximately 200 μm. Then, a lamellar dissection is performed and the material is plated directly onto the culture media. A portion also can be sent for histopathologic evaluation.

Histological Findings

During the initial stages, the epithelium and the stroma in the area of injury and infection swell and undergo necrosis. Acute inflammatory cells (mainly neutrophils) surround the beginning ulcer and cause necrosis of the stromal lamellae. In cases of severe inflammation, a deep ulcer and a deep stromal abscess may coalesce, resulting in thinning of the cornea and sloughing of the infected stroma.

As the natural host defense mechanisms overcome the infection, humoral and cellular immune defenses combine with antibacterial therapy to retard bacterial replication. Following this process, phagocytes of the organism and cellular debris take place, without further destruction of stromal collagen. During this stage, a distinct demarcation line may appear as the epithelial ulceration and stromal infiltration consolidate and the edges become rounded.

Vascularization of the cornea may follow if the keratitis becomes chronic. In the healing stage, the epithelium resurfaces the central area of ulceration and the necrotic stroma is replaced by scar tissue produced by fibroblasts. The reparative fibroblasts are derived from histiocytes and keratocytes that have undergone transformation. Areas of stromal thinning may be replaced partially by fibrous tissue. New blood vessel growth directed towards the area of ulceration occurs with the delivery of humoral and cellular components to promote further healing. The Bowman layer does not regenerate, but is replaced with fibrous tissue.

New epithelium slowly resurfaces the irregular base and vascularization gradually disappears. With severe bacterial keratitis, the progressive stage advances beyond the point in which the regressive stage can lead to the healing stage. In such severe ulcerations, stromal keratolysis may progress to corneal perforation. Uveal blood vessels may participate in sealing the perforation, resulting in an adherent vascularized leukoma.

Imaging

Slit-lamp photography can be useful to document the progression of the keratitis and in cases where the specific etiology is in doubt, it is used to obtain additional opinions, particularly in indolent and chronic cases not responding to antimicrobial therapy.

B-scan ultrasound can be obtained in eyes with severe corneal ulcers with no view of the posterior segment where endophthalmitis is being considered.

Management

Medical

If no organisms are identified on the slide smear, initiate broad-spectrum antibiotics with the following: Tobramycin/gentamicin (14 mg/mL) 1 drop every hour alternating with fortified cefazolin (50 mg/mL) 1 drop every hour. If the corneal ulcer is small, peripheral and no impending perforation is present, intensive monotherapy with fluoroquinolones is an alternative treatment. Other antimicrobials can be used, depending on the clinical progress and laboratory findings.

The fourth-generation ophthalmic fluoroquinolones include moxifloxacin and gatifloxacin and they are now being used for the treatment of bacterial conjunctivitis. Both antibiotics have better in vitro activity against gram-positive bacteria than ciprofloxacin or ofloxacin. Moxifloxacin penetrates better into ocular tissues than gatifloxacin and older fluoroquinolones; in vitro activity of moxifloxacin and gatifloxacin against

JAYPEE BROTHERS

gram-negative bacteria is similar to that of older fluoroquinolones. Moxifloxacin also has better mutant prevention characteristics than other fluoroquinolones. These findings support the use of the newer fluoroquinolones for the prevention and treatment of serious ophthalmic infections (e.g. keratitis, endophthalmitis) caused by susceptible bacteria.

In view of these findings, moxifloxacin or gatifloxacin may be a preferred alternative to ciprofloxacin as the first-line monotherapy in bacterial keratitis. Additionally, 0.5% moxifloxacin and, to a lesser extent, levofloxacin and ciprofloxacin have demonstrated significant effectiveness for reducing the number of mycobacterium abscesses in vivo, suggesting the potential use of these agents in the prevention of abscesses and keratitis. The frequency of antibiotic administration should be tapered off according to the clinical course using some of the following parameters:

Blunting of the perimeter of the stromal infiltrate; decreased density of the stromal infiltrate; decreased stromal edema and endothelial inflammatory plaque, decreased anterior chamber inflammation, reepithelialization of the corneal epithelial defect and improvement in symptoms and pain.

- *Antibiotics*

Aminoglycosides: Aminoglycosides have a broad range of bactericidal activity against many bacterial species, particularly gram-negative rods. They have a selective affinity to bacterial 30S and 50S ribosomal subunits to produce a nonfunctional 70S initiation complex that results in the inhibition of bacterial cell protein synthesis. Unlike other antibiotics that impair protein synthesis, they are bactericidal. Their clinical activity is limited severely in anaerobic conditions. They have a low therapeutic/toxic ratio.

Cephalosporins: Cephalosporins have a broad spectrum of activity, including effective action against Haemophilus species. They contain a beta-lactam ring similar to penicillins, and a dihydrothiazine ring that makes them resistant to the action of penicillinases produced by staphylococci. They inhibit the third and final stage of bacterial cell wall formation by preferentially binding to one or more penicillin-binding proteins that are in the cytoplasmic membrane beneath the cell walls of susceptible bacteria. They are well tolerated topically.

Chloramphenicol: Chloramphenicol usually is reserved for specific infections, such as those associated with *H influenzae*. Its use has been limited by toxicity, including a dose-dependent bone marrow depression.

Macrolides: Macrolides are bacteriostatic agents (e.g. erythromycin, tetracycline) that can suppress the growth of susceptible gram-positive cocci. This class of drugs works by the inhibition of bacterial protein synthesis.

Glycopeptides: Glycopeptides have activity against gram-positive bacteria and methicillin- and penicillin-resistant staphylococci. They inhibit the biosynthesis of peptidoglycan polymers during the second stage of bacterial cell wall formation, at a different site of action from that of the beta-lactam antibiotics. They also have an excellent activity against a variety of gram-positive bacilli.

Sulfonamides: Sulfonamides have a structure similar to para-aminobenzoic acid, a precursor required by bacteria for folic acid synthesis. They competitively inhibit the synthesis of dihydropteroic acid, the immediate precursor of dihydrofolic acid from para-aminobenzoic acid pteridine. This inhibition does not affect mammalian cells because they lack the ability to synthesize folic acid and require preformed folic acid. They are active against gram-positive and gram-negative bacteria, and they are the preferred drugs against Nocardia keratitis.

Fluoroquinolones: Fluoroquinolones variably inhibit the action of bacterial DNA gyrase, an enzyme essential for bacterial DNA synthesis. They have activity against most aerobic gram-negative bacteria and some gram-positive bacteria. Concern has been generated regarding the emerging resistance to fluoroquinolones among staphylococci. Emerging resistance to these antimicrobials has been reported in nonocular and ocular isolates. They have limited efficacy against streptococci, enterococci, non-aeruginosa Pseudomonas and anaerobes. Two multicenter trials compared the efficacy of ciprofloxacin 0.3% and ofloxacin 0.3% solution versus fortified cefazolin and tobramycin, and reported favorable efficacy for a single agent fluoroquinolone therapy. They also have a record for low toxicity, good ocular surface penetration and prolonged tear film penetration. Monotherapy for bacterial keratitis using these classes of antibiotics has been proved to be effective in large clinical trials. However, emerging resistance to the fluoroquinolones is now being reported in nonocular and ocular isolates.

- *Topical corticosteroids*

Anti-inflammatory agents that may impair host defenses and enhance microbial proliferation, but can reduce host inflammatory response that contributes to conjunctival or corneal scarring. Should not be used until specific antimicrobial therapy has controlled microbial proliferation and clear clinical improvement is evident. Judicious corticosteroid use entails dosage adjustment according to the severity of ocular inflammation and occurrence of side effects. Discontinuation should be gradual to minimize rebound of inflammation.

Surgical

The most common cause of corneal perforation is infection by bacteria, virus or fungus, accounting for 24 to 55% of all perforations, with bacterial infections being the most common.

Penetrating keratoplasty, sclerocorneal patch or application of cyanoacrylate tissue adhesive may be necessary in the cases of corneal perforation or imminent perforation.

Systemic intravenous antibiotics (alternatively ciprofloxacin 500 mg PO bid) should be started once an infected corneal ulcer has perforated and for three days following the penetrating keratoplasty. A clear plastic shield should be placed over the

JAYPEE BROTHERS

eye. The use of general anesthesia usually is preferred for keratoplasty surgery. Topical anesthesia can be used for the application of tissue adhesive. The size of the transplant should be the smallest trephine capable of incorporating the perforation site and any infected or ulcerated border. Donor generally is oversized by 0.5 mm. Cataract removal is left for a subsequent procedure because of the risk of expulsive hemorrhage and endophthalmitis. The anterior chamber should be irrigated to remove any necrotic or inflammatory debris. The donor cornea should be secured with 16 interrupted 10-0 nylon sutures. Subconjunctival injections of antibiotics can be given without depot steroid injection. The postoperative use of frequent topical fortified antibiotics is advocated. Corticosteroids, four times a day can be used immediately after surgery if it is believed that the infection was excised completely. Alternatively, steroids can be withheld for several days to monitor for infection. Once the acute postoperative period is over, long-term care is similar as that for uncomplicated penetrating keratoplasty. Topical antibiotics constitute the mainstay of treatment in the cases of bacterial keratitis, with subconjunctival antibiotics used only under unusual circumstances, and systemic antibiotics used only in the cases of perforation or specific organisms (e.g. *N. gonorrhoeae*). The use of topical corticosteroids remains controversial; however, when they are used, strict guidelines and close follow-up care are mandatory to ensure the best ultimate outcome of these patients.

Complications

The most feared complication of this condition is thinning of the cornea, secondary descemetocele and eventual perforation of the cornea that may result in endophthalmitis and loss of the eye.

Prognosis

The prognosis depends on several factors:

- Virulence of the organism
- Extent and location of the corneal ulcer
- Resulting vascularization and/or collagen deposition

FUNGAL KERATITIS

Introduction

Fungi are ubiquitous in the environment. Their spores can survive the extremes of temperature and desiccation. Fungi, particularly, Candida species are often a part of normal conjunctival flora. They have been isolated from the conjunctival sac in 3 to 28% of the healthy eyes. Fungi invade the ocular surface only when it is compromised, either from surface disease, topical steroid use or trauma. Ocular trauma, especially involving vegetable matter, is the most common risk factor for keratomycosis and accounts for 50% of the cases in most series. There has been an increase in the number of reported cases of fungal keratitis. The increasing use of broad-spectrum antibiotics may provide a noncompetitive environment for fungi to grow. More recently, outbreaks of fungal keratitis due to contact lens solution (*Fusarium keratitis*) have also been reported.

Structural Characteristics of Fungi

Fungi are eukaryotes, have a membrane bound nucleus, a cell wall that contains chitin and a cell membrane that contains ergosterol. There are two broad categories of fungi, the yeasts or molds. Yeasts are usually unicellular and grow by budding. Molds, also called filamentous fungi, are composed of hyphae and are multicellular. Molds grow by the extension and branching of hyphae. Filamentous fungi may be septet or acetate. Septate hyphae have pores through which cytoplasm and nuclei pass to reach the growing tip.

Classification

A convenient method of classifying fungal isolates causing keratomycosis includes several diagnostic/laboratory groups, such as yeasts, moniliaceae and dematiaceae (Table 3.1).

Table 3.1: Fungal isolates causing keratomycosis

A	*Yeast*
	Candida species: Albicans, parapsilosis, krusei, tropicalis, guilliermondii
	Trichosporon beigelii
	Cryptococcus uniguttulans
B	*Filamentous septated*
	1. Nonpigmented hyphae (hyaline)
	Fusarium species: solani, oxysporum, moniliforme
	Aspergillus species: Fumigatus, flavus, terreus, glaucus, niger
	Acremonium species
	Cylindrocarpon species
	Paecilomyces species
	Scedosporium apiospermum
	2. Pigmented hyphae (dematiaceous)
	Alternaria species
	Curvularia species
	Cladosporium species
	Colleotricum species
	Phoma species

Clinical Features

The symptoms of fungal keratitis may not present as acutely as with other forms of microbial keratitis. Patients may report the initial symptom of foreign body sensation for several days associated with increasing pain. Presence of characteristic clinical features can be used as a diagnostic aid for suppurative keratitis caused by filamentous fungi. Serrated margins, raised slough, dry texture, satellite lesions and coloration other than yellow occur more frequently in the cases of filamentous fungal keratitis than bacterial keratitis. The probability of fungal infection if one clinical feature is present is 63%, increasing to 83% if all three features were present. Microbiological investigations should be performed whenever possible; however, where facilities are not available, a rapid presumptive diagnosis of

JAYPEE BROTHERS

suppurative keratitis may be possible by scoring clinical features. The appearance of macroscopic brown pigmentation is one specific sign seen in fungal keratitis due to dematiaceous fungus. The presence of intact epithelium with a deep stromal infiltrate may also be found in fungal keratitis (Figs 3.6 to 3.10).

Diagnosis

The Gram and Giemsa stains are the most common initial stains used for rapid diagnosis. Potassium hydroxide 10 to 20% wet mounts with calcofluor white is the best stain for fungi. Calcofluor white stains the chitin in the fungal cell wall and potassium hydroxide removes the non-fungal elements from the specimen.

In histopathology sections, hematoxylin and eosin, PAS stain and Gömöri methanamine silver stains are used. Culture media should include sheep blood agar, potato dextrose agar and Sabouraud's dextrose agar. Corneal biopsy may be necessary for deep keratomycosis. Anterior chamber tap may be useful in situations where organisms have penetrated the intact Descemet's membrane. Confocal microscopy is an important noninvasive tool in the cases of deep keratomycosis.

Management

Effective eradication of fungi is frequently difficult due to deeply invasive nature of the infectious process. Penetration of the fungus through the cornea into the anterior chamber may occur. Therefore, an effective agent for treating fungal keratitis should exhibit pharmacological properties that include excellent corneal and ocular penetration. Table 3.2 shows the effective drugs available for treating mycotic ocular infections.

Table 3.2: Classification of antifungal agents

Polyenes
• Amphotericin B
• Natamycin
Imidazoles
• Clotrimazole
• Miconazole
• Econazole
• Ketoconazole
• Fluconazole
• Itraconazole
• Voriconazole

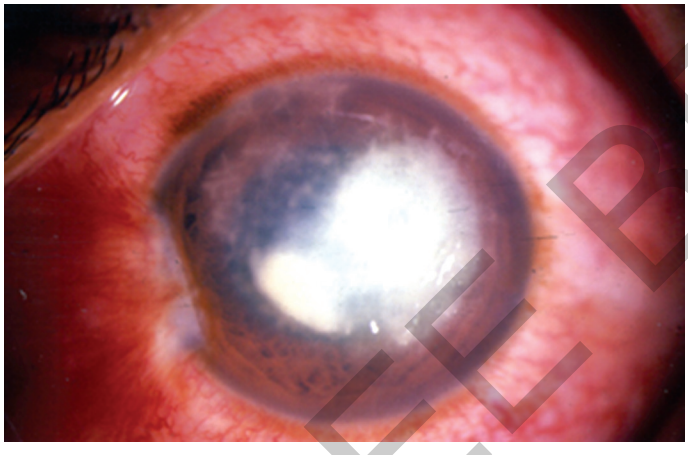

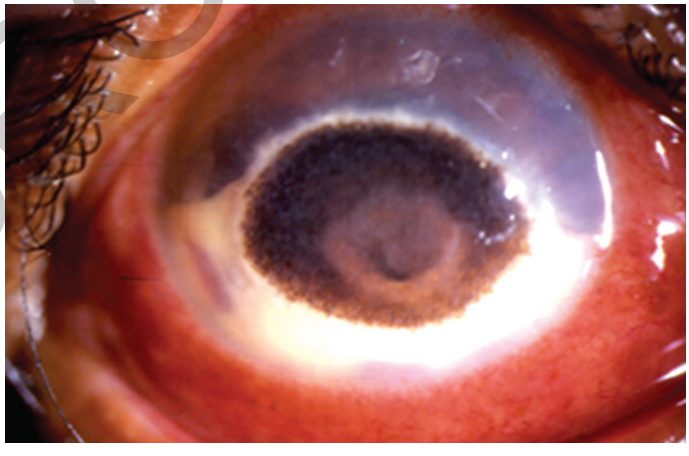

Figs 3.6 and 3.7: Fungal keratitis

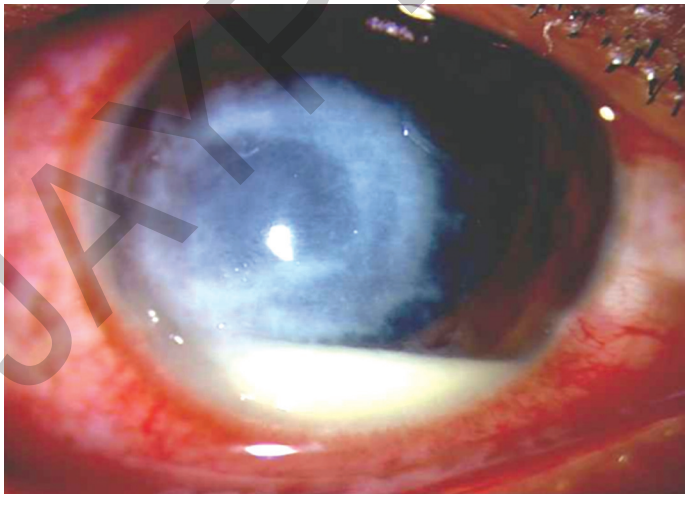

Fig. 3.8: Fungal keratitis. Hyphate edges



Fig. 3.9: Fungal keratitis. Dematiaceous fungus (pigmented plaque)

JAYPEE BROTHERS

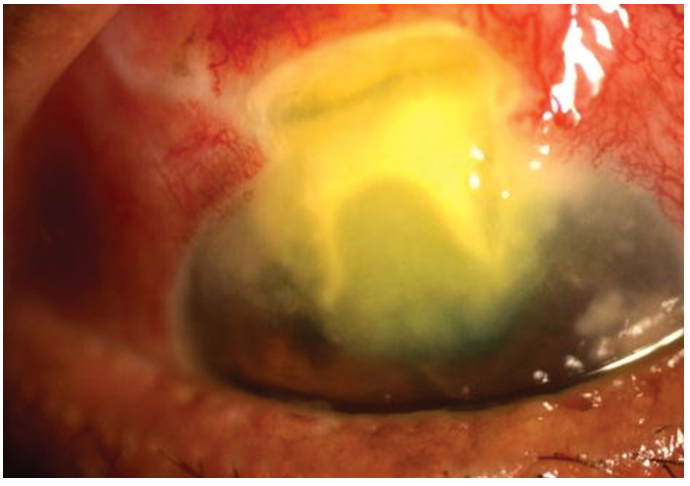

Fig. 3.10: Fungal keratitis. Postoperative tunnel infection due to filamentous fungus

Commercially available natamycin 5% suspension is the initial drug of choice for filamentous fungi. The corneal epithelium serves as a barrier to penetration in the view of high molecular mass of natamycin (665 kDa); hence debridement and superficial keratectomy are essential components in the management of fungal keratitis. If worsening is noted on topical natamycin treatment, amphotericin B 0.15% or azoles may be added as a second agent. Some of the newer antifungal agents have been tried topically. Voriconazole is one such medication, which may be promising in the management of keratitis.

Several clinical studies have reported favorable outcomes with the use of systemic antifungal agents, such as ketoconazole, fluconazole and itraconazole.

Intracameral injection of amphotericin B may have a role in the management of deep keratomycosis.

When progression of keratitis is noted, a therapeutic keratoplasty is indicated. The timing of penetrating keratoplasty is important. If the infectious agent were allowed to progress until it extends up to the limbus or sclera, outcomes of therapeutic keratoplasty would be unfavorable.

The use of corticosteroid in the postoperative period is controversial. Steroids should not be started before two weeks of penetrating keratoplasty. Majority of the recurrences occur during the initial postoperative period. Even if graft failure or rejection occurs, the patient can undergo a second penetrating keratoplasty subsequently.

Management

Treatment is influenced heavily by the interpretation of laboratory data. There is rarely a justification for empirical treatment with antifungal agents without corroborating evidence of a fungal etiology. Drug toxicity and necessity for prolonged treatment mitigate against the use of these agents empirically.

Signs of improvement include lessening of pain, decrease in the size of infiltrate, disappearance of satellite lesions and rounding out of feathery margins of the infiltrate.

HERPES SIMPLEX VIRUS KERATITIS

Introduction

Herpes simplex virus belongs to a family of viruses called Herpesviridae, which is a DNA virus that commonly affects humans.

There are two types of Herpes simplex virus, namely, type 1 and 2. In general, type 1 causes infection above, and type 2, below the waist. Therefore ocular herpes disease is usually caused by herpes simplex virus type 2 however, the rare neonatal herpes simplex virus infection, including herpetic keratitis and conjunctivitis is due to herpes simplex virus type 2 in a majority of cases as it is transmitted to neonates as they pass through the birth canal of a mother with genital herpes simplex virus type 2 infection.

Latency and Reactivation

Like other herpes viruses, herpes simplex virus has the ability to induce latent infection. After primary infection, that is, the host's first exposure at the peripheral site, the virus enters sensory nerve endings, which supply the site of peripheral epithelial infection, usually the oropharynx. Virus particles travel centripetally to the neuronal cell body by retrograde axoplasmic flow. Here, they can survive for decades, probably integrated into the host-cell nuclear DNA; yet they leave the cell morphologically, antigenically and functionally normal.

Primary Infection

Infection with herpes simplex virus for the first time can develop at any age although most cases occur within the first few years of life. Salivary contamination from a person with silent salivary shedding of herpes labialis is the most common source of infection. Aphthous stomatitis is the usual clinical picture, which can range from subclinical to very severe infection. However, primary herpes simplex virus infection can also occur in other mucous membranes, including the conjunctiva.

Primary ocular herpes simplex virus infection most commonly manifests as blepharoconjunctivitis, which is predominantly unilateral. The periorbital skin can develop intense blisters associated with conjunctivitis and blepharitis. Extensive spread on the facial skin can occur, particularly in eczematous individuals.

The conjunctivitis is usually follicular although severe cases may develop pseudo-membranous reaction. Preauricular lymphadenopathy often accompanies the conjunctivitis. Keratitis develops a few days after conjunctival involvement in 30 to 50% of cases. The morphology of the corneal lesions varies from superficial punctate keratitis, microdendrites or frank dendritic ulceration. Stromal involvement is rare. Interestingly, though subsequent recurrent disease is uncommon, it may occur as focal clusters of vesicles in the lids or as follicular conjunctivitis. In these cases corneal involvement is usually minimal or absent.

JAYPEE BROTHERS

Recurrent Infection

The major factors which dictate the severity of recurrent herpes are: immune response of the host, the viral strain and treatment. Superficial corneal lesions (dendritic and geographic ulcers) are associated with the presence of replicating virus whilst deeper lesions (stromal and uveal) appear to be predominantly due to the immune response (Figs 3.11 to 3.13).

Corneal Epithelial Disease

The vast majority of the cases of herpes simplex virus keratitis are those which are present with a corneal epithelial lesion, usually a dendritic ulcer. Such individuals may experience this first episode in adulthood. This is due to the reactivation of a latent virus from a previously unrecognized primary ocular infection or from a virus, which has reached ophthalmic neurons in the trigeminal ganglion during primary infection of the oropharynx. It usually occurs as isolated lesion(s) without the involvement of conjunctiva and lids. The presenting symptoms include irritation, watering, photophobia, and occasionally, blurring of vision.

The morphology of the lesions is quite varied. They can appear as superficial punctate keratitis, stellate epithelial lesions, and dendritic or geographic ulcers. Ulcers are usually single, but may be several. The infected epithelial cells appear as opaque lesions, which form white plaques. Further enlargement results in the dendritic ulceration. The mechanism for dendrite formation is not known, but is thought to be related to the linear spread of virus from cell to cell in a contiguous manner. With further growth of the dendrite, the central epithelium is sloughed off and the lesion stains with fluorescein. The marginal infected cells take up rose bengal stain. The linear branches characteristically end in expansions called "terminal bulbs". The stroma under the ulcer may show a faint haze and there may be evidence of mild iritis. Corneal sensation is lost in the areas where lesions are present. Repeated attacks may result in generalized corneal anesthesia.

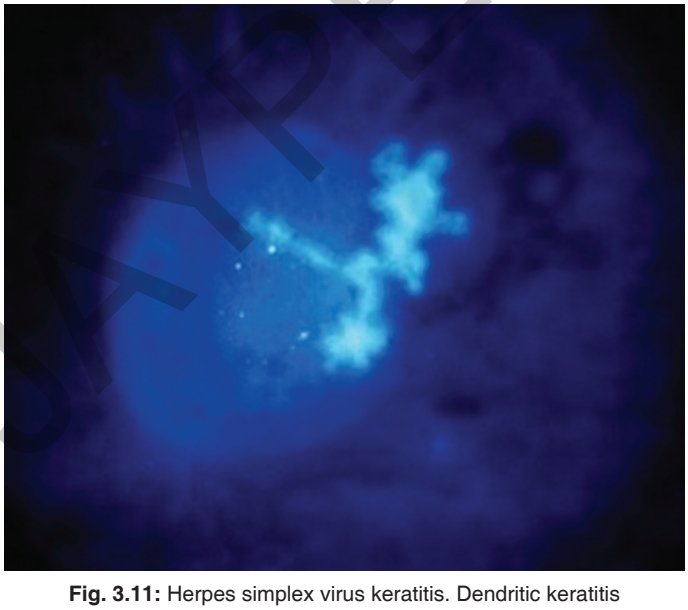

Fig. 3.11: Herpes simplex virus keratitis. Dendritic keratitis

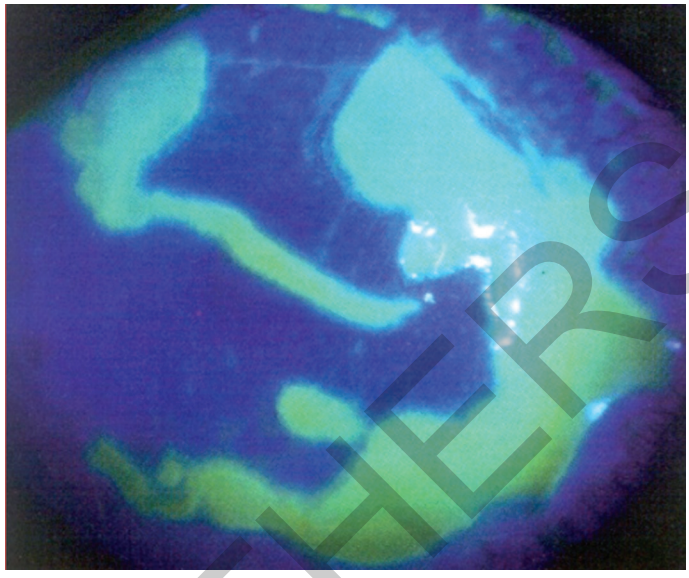

Fig. 3.12: Herpes simplex virus keratitis. Geographic ulcer

Stromal Keratitis

Sight-threatening problems associated with herpes simplex virus type 1 infection appear to be largely due to an inflammatory response involving the corneal stroma. It is predominantly immune-mediated although in few cases direct invasion and active replication of the virus play a role. Secondary stromal inflammation can follow epithelial or endothelial involvement.

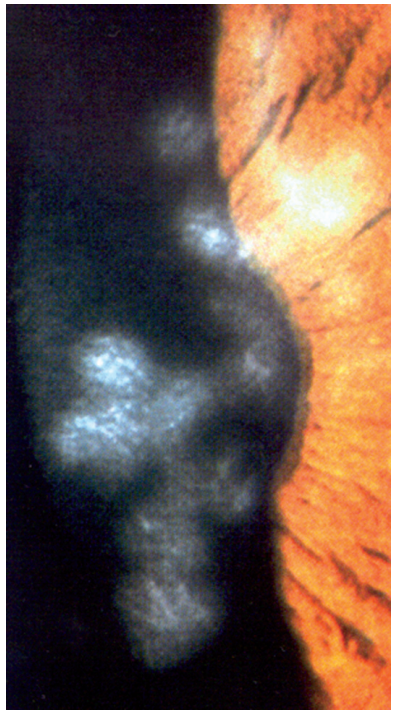

Fig. 3.13: Herpes simplex virus keratitis. Footprint scars

JAYPEE BROTHERS

Immune-mediated stromal keratitis is the most common form of the stromal disease where an antibody response is mounted against the viral antigen present in the stroma expressed as a result of persistent infection. There is the deposition of antigen-antibody complement in the stroma. Animal studies show additional mechanisms involved in the stromal tissue destruction. It is proposed that CD4+ T cells play a significant role in the recognition of antigens presented by Langerhans cells, which migrate from limbus to central cornea after herpes simplex virus type 1 infection. The activated CD4+ T cells release cytokines, in particular interleukin 2 and gamma interferon. Both factors attract large numbers of polymorphonuclear leukocytes, which are responsible for corneal tissue destruction.

Clinically, there is a stromal infiltration without necrosis and ulceration. The size and the area involved may vary and include small infiltrates to large area of stromal haze. Some cases may be associated with dendritic lesions demonstrating the presence of the entire virus. The outcomes of these lesions vary. Progression or persistence of inflammation can occur. Neovascularization, secondary lipid keratopathy, thinning of the cornea and recurrent inflammation are well recognized. Another distinct form of stromal infiltrate is the immune ring of Wesley. This represents a circular deposit of antigen-antibody complexes with polymorphonuclear leukocyte infiltrate as a result of complement activation.

Necrotizing stromal keratitis is typically associated with ulceration (Fig. 3.14). It can follow epithelial disease, superficial stromal disease or disciform keratitis, and is believed to be due to active viral replication and intense immune stromal inflammation. It may be generalized or localized. These cases may have to be differentiated from the other forms of microbial keratitis and indeed secondary infection with bacteria and fungi can complicate herpes simplex virus stromal keratitis. Secondary complications include hypopyon, uveitis, posterior synechiae, glaucoma, retrocorneal membrane, cataract and rarely perforation.

Metaherpetic Ulcer

Development of persistent epithelial defects or recurrent epithelial erosions can be seen with herpes simplex virus epithelial infection. These are generally round or ovoid ulcers with a grey and thickened margin, which is due to piled up epithelial cells.

The mechanism appears to be due to damage to underlying basement membrane at the time of epithelial infection and denervation. Consequently the epithelium fails to adhere to the basement membrane resulting in persistent defect or recurrent erosion. Additional factors like the lack of trophic innervation, drug toxicity and stromal inflammation may play a role. Viral cultures are negative and the base of the ulcer stains with both rose bengal and fluorescein. Persistent ulcers have the potential to progress to corneal melt, perforation and super infection.

Metaherpetic ulcers (sometimes referred to as "neurotrophic") have to be differentiated from geographic ulcers, which are characteristically caused by inappropriate steroid use. The latter have flat edges and stain with rose bengal stain. They also change shape due to continued viral progression. Viral cultures will be positive (Fig. 3.15).

Herpes Simplex Virus Endotheliitis

Disciform keratitis is the most common form in which a disc-shaped area of stromal edema occurs without infiltration or vascularization. The area of involvement may be diffuse and central or eccentric. The presenting symptoms include watering, photophobia, discomfort or blurred vision. A history of herpetic eye disease is usually present. The involved cornea shows appreciable thickening of all layers sometimes with epithelial edema and often with folds in Descemet's membrane.

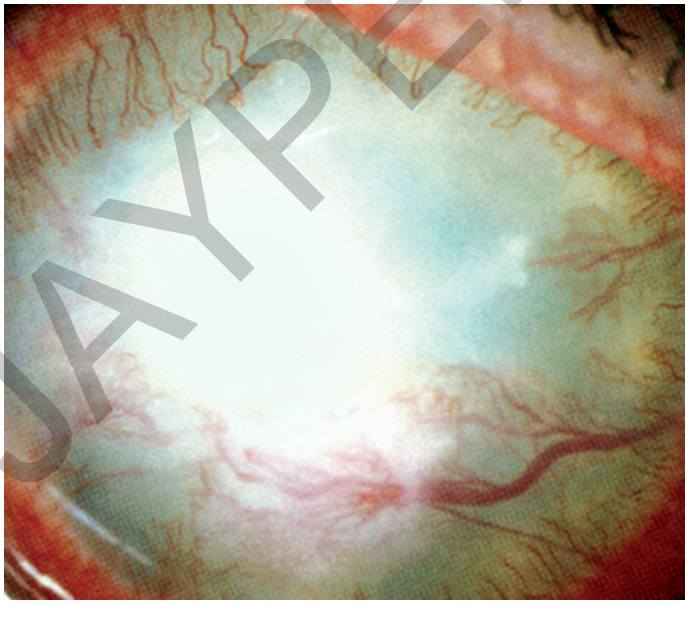

Fig. 3.14: Herpes simplex virus keratitis. Necrotizing keratitis

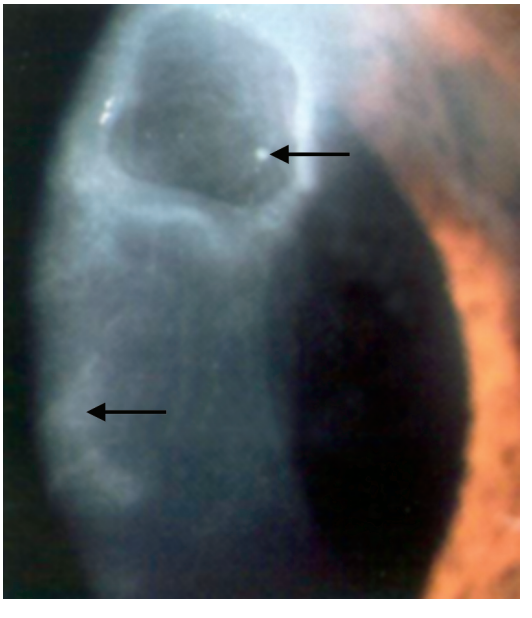

Fig. 3.15. Herpes simplex virus keratitis. Metaherpetic ulcer (←)

JAYPEE BROTHERS

Careful examination usually reveals keratic precipitates in the affected area associated with mild anterior chamber activity (Fig. 3.16). Spontaneous clearing can follow although progression to necrotizing keratitis, vascularization, scarring and thinning is also possible. Delayed hypersensitivity mediated by T lymphocytes is probably important in the pathogenesis of disciform keratitis. The distribution of keratic precipitates strictly confined to the endothelium behind the swollen area suggests cell-mediated reaction directed at herpes simplex virus determinants on the surface of endothelial cells.

Rarely linear involvement of the endothelium can occur. In these cases stromal edema is seen associated with keratic precipitates separating the involved and uninvolved cornea similar to the Khodadoust line of corneal graft rejection. Slit-lamp examination may show dark areas in the endothelium, which appear as nonreflective black endothelial areas under a specular microscope. There may be progression of the endothelial line and the associated stromal edema. Immunological studies on the aqueous aspirates have revealed herpes simplex virus antigen in several of these cases.

Occasionally diffuse involvement of the endothelium can occur resulting in generalized corneal edema associated with scattered keratic precipitates.

Herpes Simplex Virus Iridocyclitis

All deeper forms of herpes simplex virus can be associated with uveitis. However, recurrent non-granulomatous anterior uveitis may be an isolated manifestation of herpes simplex virus ocular involvement, which can occur without a prior history of ocular herpes simplex virus infection. Immunological reaction was thought to be the cause in most of the cases although in some cases live viruses have been demonstrated in the anterior chamber and in iris tissue.

Clinically the severity can vary from mild to severe inflammation, which may result in fibrin formation, hypopyon, hyphema, posterior synechiae, segmental iris necrosis similar to the picture seen in zoster keratouveitis, and inflammatory membrane in the angle of the anterior chamber with secondary glaucoma (Fig. 3.17). The recent tendency to treat severe forms of anterior segment involvement with oral acyclovir is best reserved for those cases confirmed by laboratory diagnosis, as dosages and duration of treatment have not yet been defined.

Trabeculitis

Herpetic peripheral corneal involvement may extend to the trabecular meshwork resulting in trabeculitis. The resultant secondary glaucoma may be transient or lead to permanent damage.

Laboratory Diagnosis

Laboratory tests are not an absolute requisite for the diagnosis of herpes simplex virus infection as clinical features are often highly characteristic. However, we believe whenever possible they should be undertaken to establish a firm diagnosis. The chronic nature of the condition is such that a positive diagnosis once established, is invaluable in guiding management over what may be many years.

The available methods include virus culture, immunological tests and the histopathological examination of keratoplasty specimens.

The definitive method of diagnostic testing is isolating virus in tissue culture. The lesion is swabbed and placed in viral transport medium and sent to the laboratory. It is then inoculated onto cell monolayers and incubated at 37° C. A typical cytopathic effect is generally noticed in 2–4 days.

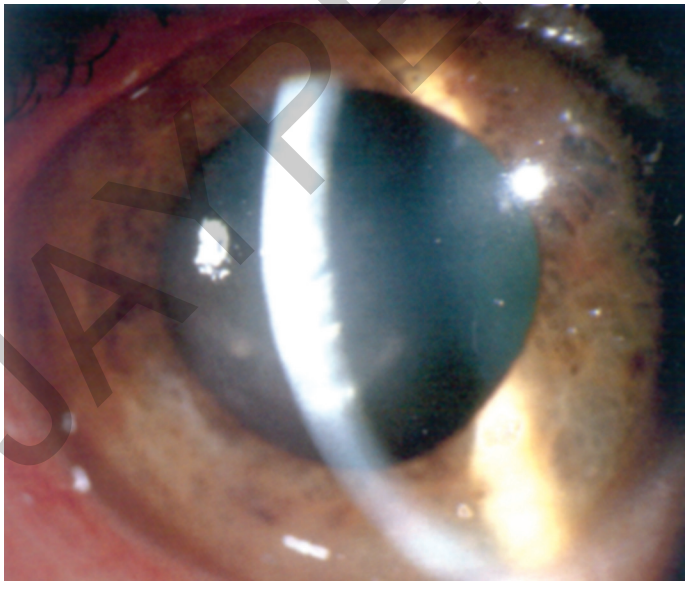

Fig. 3.16. Herpes simplex virus keratitis. Endotheliitis

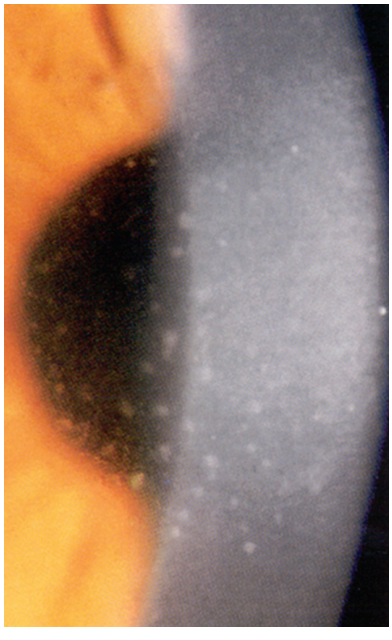

Fig.13.17: Herpes simplex virus keratitis. Iridocyclitis

JAYPEE BROTHERS

A variety of immunological tests are available to detect herpes simplex virus antigens in specimens, namely, enzyme-linked immunosorbent assay (ELISA), immunofiltration test, latex agglutination and immunoperoxidase methods. In addition, an immunoaffinity membrane test has also been described. In this test a protein-binding affinity membrane used as a blotter is gently touched to the corneal lesion and processed with peroxidase-conjugated herpes simplex virus antibody. In few centers fluorescent antibody-staining technique is available for the rapid detection of herpetic antigen in cytoplasm or the nucleus of the cell.

Histopathological examination of keratectomy specimens may show granulomatous reaction in deep stroma and around Descemet's membrane. Immunocytochemistry may demonstrate herpes simplex virus antigens in stromal keratocytes, endothelial cells and epithelioid cells. These are more often seen with the necrotizing type of herpetic stromal keratitis.

Management

Management in these cases comprises of both medical and surgical procedures.The various medical agents which can be used are as follows:

Antiviral Agents

The following topical agents are currently available for use in herpes simplex virus keratitis:

Idoxuridine, a thymidine analogue was the first agent found to be effective in the treatment of herpes simplex virus keratitis. It is incorporated into the viral DNA, produces faulty DNA chain and also inhibits viral enzymes. It also incorporates into normal host cells, which accounts for its toxicity. Though idoxuridine is useful in treating epithelial infection, the problems of toxicity allergic reaction, clinical viral resistance, poor solubility and penetration, and rapid inactivation have led to the use of other antiviral drugs. Notable ocular side effects include contact dermatitis, punctate keratitis, epithelial opacification, chronic epithelial defects, lacrimal punctal stenosis, follicular conjunctivitis, corneal pannus and teratogenicity in rabbits.

Vidarabine, the second agent developed for human use, inhibits viral DNA polymerase and gets incorporated into both viral and host DNA. It is equally effective as idoxuridine in treating epithelial disease and being highly soluble, is available only as ointment. Although it is much less toxic, punctate keratopathy (similar to idoxuridine toxicity) can be a problem with topical use. Its use is generally restricted to viral strains resistant to other antiviral agents.

Trifluridine (trifluorothymidine) is a halogenated pyrimidine inhibiting thymidylate synthetase incorporated into viral DNA impairing transcription and translation. It is more potent than idoxuridine in healing dendritic ulcers. Also trifluorothymidine is superior to idoxuridine in the management of steroid-treated corneal ulcers. Although therapeutic levels of the drug can be achieved in the anterior chamber, its role in treating deep stromal diseases and uveitis is yet to be determined. Adverse effects include superficial punctate keratitis, follicular conjunctivitis, lacrimal punctal stenosis, corneal filaments, and contact dermatitis. Viral resistance to trifluorothymidine is rare.

Acyclovir is a purine analogue. It is specifically activated by virus-induced thymidine kinase, which initiates phosphorylation. Subsequently two additional phosphates are added by host-cell kinases to produce an active triphosphate form, which is inhibitorier to viral DNA polymerase than host-cell polymerase. Thus, acyclovir is specific to viral-infected cells with low toxicity. After topical application it achieves therapeutic concentration in the anterior chamber. Acyclovir is as equally effective as trifluorothymidine and ara–A in the treatment of herpes simplex keratitis. Acyclovir is less toxic to ocular surface than earlier generation antiviral agents and as such represents a major therapeutic advance. However, mutant virus strains with deficient thymidine kinase continue to replicate; therefore, the development of drug-resistant strain may post a problem.

Corticosteroids

Cautious use of steroids is recommended in the certain types of herpes simplex virus infection of the cornea. Corticosteroids suppress inflammation by interfering with the normal immunologic response to various stimuli and are an important management tool. Clinically they reduce infiltration, edema, inflammation and neovascularization. Generally their treatment is restricted to the management of stromal keratitis and herpetic uveitis. Steroids do not appear to increase the risk of acquiring herpes simplex virus infection, but certainly promote severity of the disease when present. Disadvantages include delayed epithelial and stromal healing, increased collagenolytic enzyme production, stimulation of viral replication, and risk of secondary infection, glaucoma and cataract. Infectious crystalline keratopathy is a recognized complication of steroid treatment for herpes simplex virus keratitis. The major problem with steroids is inappropriate use at the epithelial stage, particularly as it may improve the symptoms initially. Widespread over-the-counter treatment is undoubtedly responsible for converting what may have been relatively benign disease into irreversible corneal damage.

Systemic Treatment

Oral acyclovir appears to be as effective as topical acyclovir for herpes simplex virus epithelial keratitis, but cannot be recommended as it is much more expensive. However, oral acyclovir may be beneficial in reducing the ocular recurrence and may gain a place in deep corneal disease, keratouveitis and posttransplant management in proven cases.

Specific Treatment: Primary Infection

Antiviral treatment is generally advisable even though it is not absolutely indicated as primary blepharoconjunctivitis can resolve spontaneously. Acyclovir ointment is applied over the skin lesions and in the conjunctival sac up to five times a day.

JAYPEE BROTHERS

Keratitis can be treated with antiviral alone or debridement and antiviral treatment. A shield to the eye may be necessary to prevent a child from rubbing the eye.

Specific Treatment: Recurrent Infection

Epithelial disease: Careful epithelial debridement is equally effective or even better than antiviral treatment alone. Epithelial keratitis is therefore treated with debridement, antiviral agent or a combination of both. Debridement involves removing the infected epithelial cells using a sterile cotton-tipped applicator after instillation of local anesthetic. The antiviral treatment is then initiated to improve viral clearance.

Acyclovir is the agent of choice (3% ointment, × 5 times a day). Treatment duration is usually for 10–14 days. It is to be noted that the epithelium often looks abnormal at the site of initial dendritic ulcer even resembling the original lesion, but without fluorescent staining. This may take several weeks to heal and treatment is not indicated. However, persistent epithelial lesions with the areas of fluorescent staining may indicate continued viral replication due to resistant strain or the development of metaherpetic disease. Presence of scalloped edges with progression indicates persistent infection and warrants a change of antiviral agent.

Epithelial indolent ulceration: Antiviral agents are not always needed as the underlying problem is damaged basement membrane and denervation. Generous use of lubricants, preferably unpreserved agents, often results in epithelial healing. Use of patch, bandage contact lens and occasionally a conjunctival flap, helps in resistant cases.

Stromal keratitis and immune keratitis: A combination of an antiviral agent and topical steroids is the preferred treatment. Topical steroids result in significantly reducing stromal inflammation and decrease the duration of stromal keratitis. The starting dose of topical steroids is adjusted to the level of inflammation, but it should always be a weak steroid. Once the inflammation is brought under control, gradually steroid drops are tapered and every attempt should be made to discontinue them. An individualized maintenance dose may be indicated for some patients who show frequent disease flare-up without steroid treatment. The use of oral acyclovir in addition to topical treatment does not appear to show any additional beneficial effect.

Necrotizing stromal keratitis: After culturing samples to exclude microbial secondary infection, antiviral treatment is started in suspected herpes simplex virus stromal keratitis. Topical steroids may be added cautiously if the overlying epithelium is intact. Continued stromal necrosis calls for surgical interventions, such as cyanoacrylate glue or penetrating keratoplasty.

Endotheliitis: A combination of topical steroids and antiviral agents is indicated to treat this form of herpes simplex virus infection. Additional treatment with oral acyclovir has also been found to be effective in the cases of linear endotheliitis.

Uveitis: Steroids are the treatment of choice. It is advisable to add topical antiviral treatment as some cases have been shown to be associated with live virus in the anterior chamber. Similarly oral acyclovir may be added if the response is not good or if live virus is isolated from the anterior chamber.

Trabeculitis: Antiglaucoma treatment should be initiated in addition to steroid and antiviral agents.

Surgical Procedures

Surgical procedures may sometimes be necessary to treat acute and/ or chronic complications of herpes simplex virus keratitis.

Penetrating keratoplasty: Penetrating keratoplasty is the procedure of choice to restore vision in those with significant corneal scarring due to recurrent herpes simplex virus keratitis. However, serious consideration must be given to the possibility of recurrence and rejection especially when the fellow eye may be normal. In parts of the world where donor corneas are in short supply penetrating keratoplasty for herpes simplex virus keratitis cannot be seen as a priority. Penetrating keratoplasty is also performed to re-establish the integrity of the globe after ulceration and perforation. This procedure also reduces the viral load in the cornea responsible for the repeated episodes of immune-mediated keratitis.

In patients with graft rejection, it is particularly difficult to differentiate it from the recurrence of herpetic uveitis. This is especially true in the cases of linear endotheliitis occurring in the grafted eye, which closely resembles a rejection episode with migrating line of KPs and stromal edema. However, linear endotheliitis crosses the graft host junction and responds well to oral acyclovir. It is therefore safe to treat any graft rejection with antiviral cover in such circumstances.

Other treatment modalities include the use of cyanoacrylate glue in small perforations as a temporary measure. Conjunctival flap, tarsorrhaphy and botulinum-induced ptosis may have a role in selected cases of nonhealing ulcers, particularly where access to corneal donor tissue and expert postoperative management is not available.

ACANTHAMOEBA KERATITIS

Introduction

Acanthamoeba spp. are ubiquitous organisms that can be isolated from a wide variety of environments, including water supplies, swimming pools, hot tubs, contact lenses, lens cases, and salt and bottled water. At least eight species of *Acanthamoeba* are known. *Acanthamoeba* exists in two forms, trophozoites and cysts. The trophozoite is motile and usually has one nucleolus, huge cytoplasmic vacuoles and feeds on bacteria. In unfavorable circumstances, trophozoites encyst. The cyst has a double wall containing cellulose and is 10–25 μm in diameter. The cystic form is extremely resistant to extreme conditions, such as desiccation, freezing, alterations in pH or chemical antimicrobial agents.

JAYPEE BROTHERS

Predisposing Factors

Most patients who develop infection have at least three risk factors: corneal trauma, exposure to contaminated water, or contact lens solution and contact lens wear. It has been demonstrated in the animal experiments that corneal abrasion is necessary for the development of *Acanthamoeba* keratitis.

Clinical Features

One of the important symptoms is severe pain that is not commensurate with the clinical signs at least in the early phase of infection. The major clinical signs include: epithelial haze with elevated lines, epithelial defects, epithelial ridges, microcysts, pseudodendrite, stromal infiltrate, satellite lesions and ring infiltrate (Figs 3.18 and 3.19). Table 3.3 shows the major clinical signs and stages of *Acanthamoeba* keratitis.

Table 3.3: Clinical manifestations of *Acanthamoeba* keratitis

Early	*Late*	*Advanced*
Epithelial ridges	Epithelial defects	Ring infiltrate
Epithelial haze	Stromal infiltrate	Satellite lesions
Pseudodendrites	Nummular keratitis	Stromal abscess

Laboratory Diagnosis

It is important to establish the accuracy of diagnosis, as it requires prolonged treatment to eradicate the infection. Acanthamoeba trophozoites and cysts can be identified in smears by staining with Gram and Wright-Giemsa stains. Potassium hydroxide with calcofluor white is extremely useful for identification. Culturing the specimen on a confluent lawn of *E. coli*-plated on non-nutrient agar is a specific diagnostic technique. Confocal microscopy is another very sensitive and powerful technique for identifying *Acanthamoeba* cysts.

Management

Medical therapy has employed aminoglycosides, polymeric biguanides, diamidines and imidazoles in combinations. There is no reported standardization of treatment regimen. In vitro sensitivity testing has shown that few agents are effective in killing the trophozoites, but the cysts are resistant and a higher concentration of these drugs are necessary to kill them. The down side of such high concentration is toxicity to the corneal epithelium. Because of lower surface toxicity, polyhexamethylenebiguanide 0.02% and chlorhexidine 0.02% either alone or in combination have become the favored treatment modality. Propamidine isethionate 0.15% is another recommended drug, but usage is limited due to its availability. Oral administration of ketoconazole at a dose of 400 mg/day is also recommended.

Corticosteroids

The use of steroids is controversial. Corticosteroid reduces the sequelae of inflammation. However, they may exacerbate the infection by affecting the behavior of *Acanthamoeba spp*. Treatment with dexamethasone has been shown to induce rapid excystment, which was manifested in two to six fold increase in trophozoites. Moreover, it was shown to have stimulatory proliferation effect on trophozoites.

Keratoplasty

No clear guidelines are available about the appropriate timing for penetrating keratoplasty. Conventional strategy emphasizes on reserving keratoplasty for impending perforation or for visual rehabilitation once infection has cleared completely. However, recent management strategy is to plan for deep anterior lamellar keratoplasty in advanced cases less likely to improve on medical treatment, as the available literature suggests that the Descemet's acts as a barrier to these organisms.

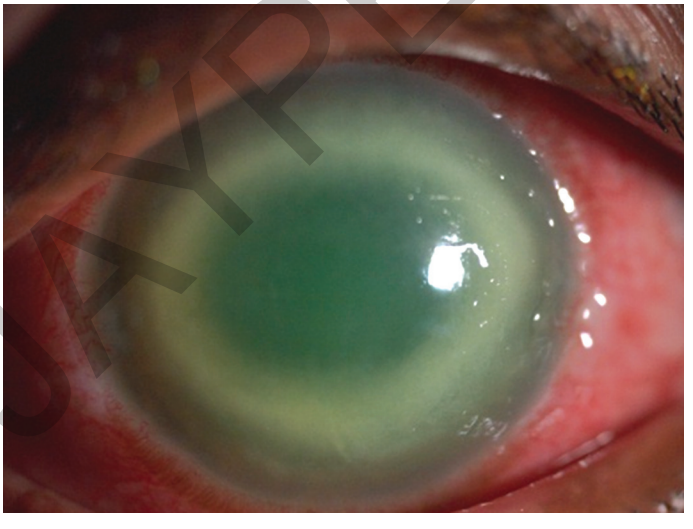

Fig. 3.18: Acanthamoeba keratitis. Ring infiltrate

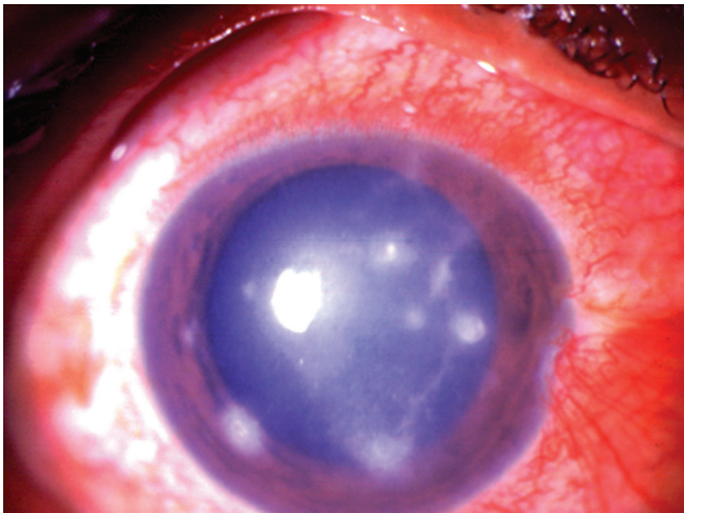

Fig. 3.19: Acanthamoeba keratitis. Contact lens related case of acanthamoeba keratitis

JAYPEE BROTHERS

CLINICAL OPHTHALMOLOGY
Medical & Surgical Approach

Clinical Ophthalmology: Medical and Surgical Approach is being launched as the second edition of *Clinical Practice in Ophthalmology*. This text attempts to update the state-of-the-art ophthalmology in a lucid, authoritative and well-illustrated manner. Ten sections encompassing forty-four chapters provide a new insight into the subject. This book is intended for the experienced ophthalmologists, postgraduate students as well as those in training.

JAYPEE - HIGHLIGHTS
MEDICAL PUBLISHERS, INC.

ISBN 978-93-5025-004-4
9 789350 250044