3rd Edition

Textbook of Clinical Electrocardiography

for Postgraduates, Residents and Practicing Physicians

SN Chugh

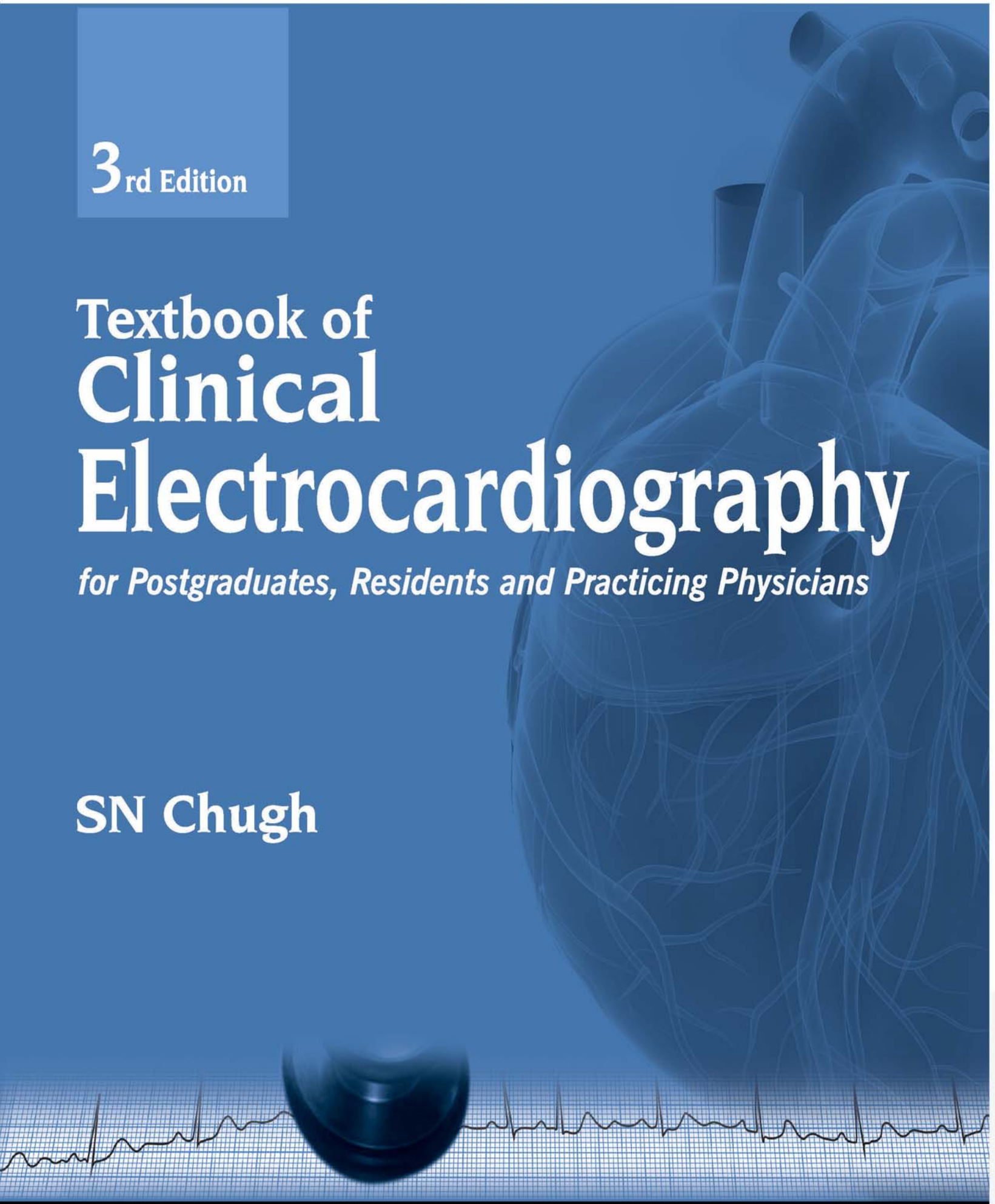

JAYPEE

Contents

SECTION ONE
Physiological Mechanisms Governing Electrocardiographic Deflections

1. Fundamentals of Electrocardiography 3
- Electrocardiogram—An Introduction 3
- Einthoven Theory of Electrical Activity 4
- Anatomy and Physiology of Conduction Tissues of the Heart 4
- Applied Physiology 5
- Modes of Activation of the Heart (Atria and Ventricles) 5

2. The Electrode and the Lead System 7
- Electrodes 7
- Lead System 7
- Arbitrary Orientation of Different Leads 9
- Continuous Monitoring System Used in Coronary Care Unit (CCU) 10
- Special or Unconventional Leads for Recording Atrial Activity from Back of the Heart 11

3. Action Potentials and Waveforms 12
- Charged or Polarized or Resting Membrane 12
- Generation of Action Potential in Pacemaker Cells 12
- Recording of Depolarization and Repolarization as Waveforms (P-QRS-T Complex) on ECG 14
- Waveforms of Electrocardiogram 15
- Atrial Depolarization Wave (Atrial Complex—P wave) 15
- Ventricular Activation Complex (Depolarization) 15
- Intrinsic or Intrinsicoid Deflections 20
- Physiology of R Wave Progression 20

4. The Cardiac Vector and the Electrical Axis 23
- Electrical Field of the Heart 23
- Axial Reference Systems 24
- Ventricular Depolarization, Instantaneous QRS Vectors and the Mean Manifest Electrical Axis 24
- Axis Deviation 29
- Abnormal P wave Axis and Associated Clinical Conditions 36

5. The Electrical Rotation of the Heart 37
- Positions of the Heart 37
- Effect of Deep Respiration on the Rotational Patterns 41

Section Two
The Electrocardiogram

6. Normal Electrocardiogram 45
- Electrocardiographic (ECG) Paper 45
- Heart Rate 46
- Natural Pacemakers and Heart Rates 47
- Prerequisite for Good Electrocardiogram Recording 48
- Normal Electrocardiogram in Adults 49
- Normal Electrocardiographic Intervals 54
- Normal Segments and Junctions on ECG 59
- Voltage Measurement 59
- Electrocardiogram in Infants 60
- Electrocardiogram in Children 60

7. Normal Electrocardiographic Variants in Adults 62
- Normal Electrocardiographic Variants in Adults—General Aspects 62
- Conditions Associated with Well Recognized Electrocardiographic Variants 64

Section Three
Chamber Hypertrophy or Enlargement

8. Atrial Hypertrophy/Enlargement 71
- Anatomy and Electrophysiology of Human Heart 71
- Chamber Enlargement 71
- Atrial Hypertrophy and Enlargement 72
- Left Atrial Hypertrophy or Enlargement 73
- Combined Right and Left Atrial Hypertrophy (Biatrial Hypertrophy) 77
- Review at Glance 80

9. Ventricular Hypertrophy/Enlargement 82
- Left Ventricular Hypertrophy (LVH) 84
- Review at Glance 90
- Right Ventricular Hypertrophy (RVH) 91
- Biventricular (Combined Right and Left Ventricles) Hypertrophy 95

Section Four
Conduction Defects

10. Intracardiac Conduction Defects 101
- Basic Concepts of Conduction 103

11. Sinus Node Dysfunction 105
- Sinus Node Dysfunction and Structural Nodal Disease 105
- Sinoatrial Blocks (SA Blocks) 106
- Sick Sinus (Lazy Sinus, Unstable Sinus) Syndrome—The Structural Nodal Disease 107
- Hypersensitive Carotid Sinus Syndrome 115

12. Atrioventricular (AV) Blocks 116
- Incomplete AV Blocks 116
- Complete (Third Degree) AV Block 121
- Clinical Significance of Second Degree AV Block and Complete AV Block 124

- High Grade AV Block 125
- Diagnosing AV Blocks at Glance 126

13. Bundle Branch Blocks 128

- Disorders of Intraventricular Conduction 128
- Bundle Branch Blocks 128
- Right Bundle Branch Block Pattern 130
- Review at a Glance 133
- Right Bundle Branch Block with Left Ventricular Hypertrophy 133
- Intermittent Right Bundle Branch Block 133
- Right Bundle Branch Block with Right Ventricular Hypertrophy 134
- Left Bundle Branch Block (LBBB) Pattern 137
- Left Bundle Branch with Left Anterior Fascicular Block 140
- Left Bundle Branch Block with Left Posterior Fascicular Block 142
- Left Bundle Branch Block with Left Ventricular Hypertrophy 142
- Review at Glance 143
- Alternating Right and Left Bundle Branch Block (Intermittent Bilateral Bundle Branch Block) 144
- Masquerading Bundle Branch Block 144
- Bundle Branch Block Alternans 144
- Nonspecific or Indeterminate Intraventricular Conduction Defect 144

14. The Fascicular Blocks or Hemiblocks 146

- Fascicular Blocks 146
- The Left Anterior Fascicular Block (Left Anterior Hemiblock) 147
- Left Anterior Fascicular or Hemiblock (LAH) Block with Left Ventricular Hypertrophy 149
- Left Posterior Fascicular Block or Left Posterior Hemiblock (LPH) 150
- Left Septal Fascicular Block 153
- Peri-infarction Block 153
- Review at a Glance 153
- Combined Fascicular Blocks 153
- Bifascicular Blocks 154
- Trifascicular Block 156

15. The S_I, S_{II}, S_{III} Syndrome 158

- Definition 158
- Mechanisms 158
- Etiology 159

Section Five
Stress Electrocardiography

16. Stress Electrocardiography 163

- Exercise Electrocardiography 163
- Pharmacological Methods of Stress Testing 178
- Pharmacological Methods of Stress Testing 180

Section Six
Continuous Ambulatory Electrocardiographic Recording

17. Continuous Ambulatory Electrocardiographic Recording 183

- Continuous Ambulatory (Holter) Monitoring 183
- Superiority of Ambulatory Electrocardiography Over Exercise Testing 187

SECTION SEVEN
Coronary Artery Disease

18. Myocardial Ischemia 193

- Pseudodepression and Pseudoelevation of ST Segment VS True (Ischemic) ST Depression and Elevation 198
- Acute versus Chronic Change 201
- Angina in a Patient with Infarction 201
- Nonspecific ST Segment and T Wave Changes 201
- Clinical and Electrocardiographic Correlation in Angina Pectoris 204
- Variant Angina (Prinzmetal's Angina) Syndrome 204
- Asymptomatic Electrocardiographic Abnormalities 209

19. Myocardial Infarction 211

- Hyperacute Myocardial Infarction 221
- Evolution of Acute Myocardial Infarction 223
- Subtle, Atypical or Nonspecific Pattern of Infarction 225
- Chronic Established Changes 230
- Localization of Myocardial Infarction by Electrocardiographic Patterns 232
- Infarction of Left Ventricle 232
- Right Ventricular Infarction 249
- Subendocardial Infarction 250
- Interventricular Septal Infarction 251
- Atrial Infarction 251
- ECG Features of Atrial Infarction 252
- Myocardial Infarction with Conduction Disturbance 252
- Ventricular Aneurysm 262

SECTION EIGHT
Congenital and Heredofamilial Disorders

20. Congenital Heart Disease 267

- Congenital Pulmonary Stenosis with Intact Septum 267
- Primary Pulmonary Hypertension 269
- Atrial Septal Defect (ASD) 269
- Atrial Septal Defect with Reversed Shunt—The Eisenmenger's Syndrome 273
- Common Atrium 274
- Ventricular Septal Defect (VSD) 274
- Malposition and Malformation of the Heart 276
- Dextrocardia (True or Mirror Image versus Technical) 277
- Patent Ductus Arteriosus (PDA) 280
- Corrected Transposition of Great Vessels 282
- Tetralogy of Fallot 284
- Pentalogy of Fallot 286
- Triology of Fallot 286
- Ebstein's Anomaly 287
- Persistent Truncus Arteriosus 288
- Aortopulmonary Communication (Window) 289
- Tricuspid Atresia 289
- Congenital Aortic Stenosis 290

21. Heredofamilial Prolonged Q-T Syndromes 292
- Acquired Prolonged Q-T Syndrome 293
- Clinical Significance 294

22. Accelerated Conduction or Pre-excitation 295
- Wolff-Parkinson-White (WPW) Syndrome 295
- WPW Variants 304

23. Hypertrophic Cardiomyopathy 308
- Etiology 308
- Macroscopic Subtypes 309
- The Electrocardiogram 309
- Clinical Significance 313

SECTION NINE
Acquired Heart Disease

24. Rheumatic Heart Disease 317
- Acute Rheumatic Carditis 317
- Chronic Rheumatic Valvular Heart Disease 318
- Floppy Mitral Valve (Mitral Valve Prolapse) Syndrome 327

25. Myocarditis and Cardiomyopathies 330
- Myocarditis 330
- Chagas' Myocarditis 332
- Review At Glance 333
- Cardiomyopathies 333

26. Pericarditis 339
- Pericarditis with Effusion 343
- Chronic Constrictive Pericarditis 345

27. Acute Pulmonary Thromboembolism (Acute Cor Pulmonale) 347
- Pathogenesis 347
- Electrocardiographic Manifestations 347
- Electrocardiogram 347
- Frontal Plane Leads (I, II, III, aVR, aVL and aVF) 347
- Horizontal Plane Leads (V_1 to V_6) 348
- Diagnosis and Differential Diagnosis 349
- Review at Glance 351
- ECG Changes in Acute Cor Pulmonale 351

28. Chronic Obstructive Pulmonary Disease (COPD) and Chronic Cor Pulmonale 352
- Chronic Cor Pulmonale 352
- Chronic Cor Pulmonale without Obstructive Disease of the Airways 356

29. Systemic Hypertension 360
- Hemodynamic Alterations 360
- Electrocardiogram 360
- Hypertension Associated with Other Conditions 362
- Effect of Treatment 362

SECTION TEN
The Disorders of Cardiac Rhythm

30. Basic Physiopathologic Considerations 367
- Anatomy and Physiology of Conduction System 367
- Classification of Cardiac Arrhythmias 368
- Basic Approach for Analysis of Cardiac Rhythm 369
- Arrhythmogenesis 370
- Other Electrophysiological Abnormalities Leading to Cardiac Arrhythmias 372
- Review at a Glance 375

31. Sinus Rhythm and its Manifestations 376
- Sinus Rhythm 376
- Sinus Arrhythmia 376
- Types 377
- Sinus Bradycardia 378
- Sinus Tachycardia 379
- Sinus Nodal Re-entrant Tachycardia 379

32. Abnormal Atrial Rhythm (Atrial Arrhythmias or Dysarrhythmias) 382
- Atrial Arrhythmias 382
- Atrial Ectopics (Extrasystoles or Premature Beats) 382
- Atrial Bigeminy / Trigeminy 385
- Atrial Interpolated Beat 385
- Atrial Escape Beat 385
- Ectopic Low Atrial Rhythm 385
- Atrial Parasystole 386
- Wandering Atrial Pacemaker Rhythm 386
- Atrial Tachycardias 387
- Review at Glance 390
- Atrial Re-entrant Tachycardia 390
- Multifocal Atrial Tachycardia (MAT) 390
- Chaotic Atrial Rhythm 391
- Atrial Flutter 391
- Review at a Glance 394
- Atrial Fibrillation (AF) 394
- Review at Glance 397

33. Atrioventricular (AV) Nodal Disturbances 398
- AV Nodal (Junctional) Escape Beats (Read Chapter 40—Escape Rhythm) 400
- Premature AV Nodal (Junctional) Complexes / AV Nodal Extrasystoles or Ectopics 402
- AV Nodal (Junctional) Rhythm 403
- Acceleration of AV Nodal Rhythm (Accelerated AV Nodal Rhythm or Idionodal Tachycardia) 403

34. Paroxysmal Supraventricular Tachycardias 408

Definition 408
Mechanisms 408
Atrioventricular (AV) Nodal Tachycardias 409

35. Ventricular Arrhythmias/Dysarrhythmias 416
- Ventricular Ectopics or Extrasystoles 416
- Idioventricular Rhythms 425

- Ventricular Tachycardia (VT) 428
- Torsades De Pointes 435
- Ventricular Flutter 436
- Ventricular Fibrillation (VF) 436
- Ventricular Asystole 437
- Dying Heart (Agonal Rhythm) Pattern 438
- Other Diagnostic Electrocardiographic Techniques for Arrhythmias 438

36. Reciprocal Rhythm and Reciprocal Tachycardia 443
- Reciprocal Rhythm 443
- WPW Syndrome and Reciprocating Rhythm / Tachycardia 448
- Tachycardia through Atrio-hisian Pathway (Lown-Ganong-Levine Syndrome with Tachycardia) 452
- Tachycardias through Mahaim Fibers 452

37. Atrioventricular Dissociation 455
- Etiology 456
- Mechanisms 456

38. Parasystole 462
- Parasystolic Ventricular Tachycardia 464
- Atrial Parasystole and Parasystolic Atrial Tachycardia 464
- Nodal Parasystole 465

39. Ventricular Aberrancy or Aberrant Intraventricular Conduction 467
- Phasic Aberrant Intraventricular Conduction 467
- Ventricular Aberrancy 473
- Atrial Fibrillation with Ventricular Aberration 477
- Atrial Flutter with Ventricular Aberration 480
- Ventricular Aberrancy versus Intermittent Bundle Branch Block 482

40. Escape Rhythm 484

Escape Beats and Escape Rhythm 484

41. Ventricular Fusion Beats 490

Ventricular Fusion Complexes or Beats 490

42. Ventricular Capture Beats 493
- Types of Ventricular Capture 493
- Timing and Conduction of Capture Beats 494
- Electrocardiographic Characteristics of a Capture Beat 494
- Significance 495

SECTION ELEVEN
Artificial Pacemakers

43. Artificial Pacemakers 499
- Electrocardiographic Patterns of Paced Complexes 509
- Malfunctioning of Pacemakers 511
- Pacemaker Re-entrant Tachycardia (Endless Loop Tachycardia) 516
- Pacemaker Syndrome 517

SECTION TWELVE
Miscellaneous Disorders

44. Heart in Endocrine Disorders and Injuries 521
- Hyperthyroidism (Thyrotoxicosis) 521
- Hypothyroidism (Myxoedema) 521
- Acromegaly 523
- Cushing's Syndrome 523
- Adrenal Insufficiency 523
- Pheochromocytoma (Catecholamines Excess) 524
- Parathyroid Disorders 524
- Physical Injuries 524
- Hypothermia 524
- Electrical Injuries 525
- Drowning 525
- Trauma to the Heart 525
- Tumors of the Heart 525

45. Drugs, Poisons and the Heart 528
- Drugs and the Heart 528
- Phenothiazines and Other Antipsychotic Drugs 534
- Antidepressants 534
- Heart in Systemic Poisonings 536
- Heart in Envenomation 540

46. The Electrolytes and the Heart 544
- Electrolyte Disturbances 544
- Hypokalemia 544
- Hyperkalemia 547
- Hypercalcemia 550
- Hypocalcemia 551
- Hypomagnesemia 552
- Hypermagnesemia 552
- Uremia 552

47. Heart in Cerebrovascular and Neuromuscular Disorders 554
- Cerebrovascular Accident (CVA) 554
- Hypokalemic and Hyperkalemic Periodic Paralysis 554
- Neuromuscular Disorders 556

Appendices

Appendix A
- Normal 12-Lead Surface ECG and its Variations in Adults 563

Appendix B 565
- Analysis of an Arrhythmia 565

Appendix C 567
- Proforma for ECG Reporting 567

Index 569

The Electrocardiogram

Section 2

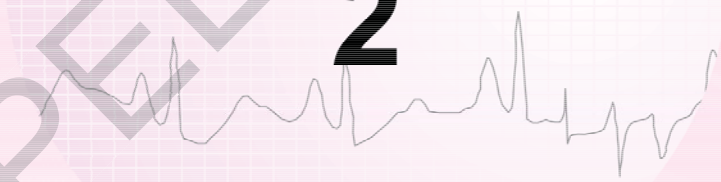

JAYPEE BROTHERS

JAYPEE BROTHERS

6

Normal Electrocardiogram

- *Electrocardiographic paper, standardization, calculation of heart rate, natural pacemakers and their discharge rates and prerequisites for good ECG recording*
- *Intervals (P-R, QRS, QT or QTc), segments (PR segment, ST segment) and junctions (R-S junction)*
- *Voltage measurement*
- *Electrocardiogram of infants and children*

JAYPEE BROTHERS

ELECTROCARDIOGRAPHIC (ECG) PAPER (FIG. 6.1)

The electrocardiographic paper is a graph paper with horizontal and vertical lines at 1 mm distance, that intersect to form large and small squares. A heavier or dark line is present after every 5 mm. Horizontal measurements indicate units of time while vertical measurements reflect voltage. One small square on vertical measurement equals to 1 mm, represents 0.1 millivolt (mV) and on horizontal measurement (width) represents 0.04 second. Each large square is equal to 5 mm, reflects 0.5 mV (height) and 0.20 second width (Fig. 6.1). After 5 big squares, the dark line of 5th big square extends on to upper white border, acts as a time marker of 1 second (5 small squares × 0.04 sec × 5 big squares = 1 second).

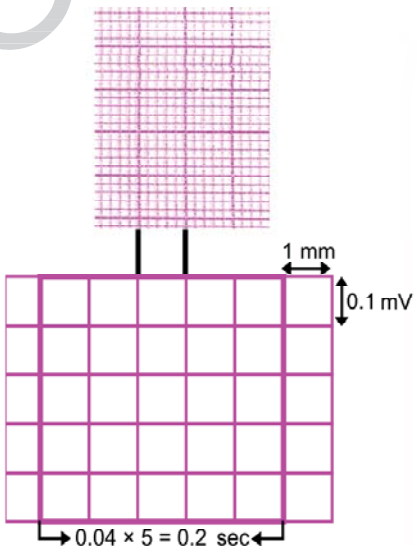

Fig. 6.1: *The ECG paper:* The width of each small square is used to calculate intervals of time; each equals to 0.04 second. Each large square equals to (5 × 0.04 sec) = 0.2 second. The height of each square is used to assess the voltage; each small square equals to 0.1 mV and a large square equals to 0.5 mV

Speed of the Paper

In routine practice, the standard speed of ECG paper is 25 mm per second. A faster speed of 50 mm/sec is occasionally used to visualize wave deflections better.

Standardization of ECG

Standardization of ECG means to adjust the voltage of QRS in order to make its interpretation easier. Standardization is adjusted to increase or decrease the size of QRS complex. The ECG is standardized for accurate measurement of voltage in vertical direction.

A special signal is inscribed in the recording and is seen in the beginning of the record called '*standardization*'. The standard signal is 1 mV deflection, equals 10 mm in height (Figs 6.2A to C).

1. **Normal or full standardization:** A 10 mm (1 mV) upward deflection from the baseline is called '*full or normal standardization*'or standardization 1.

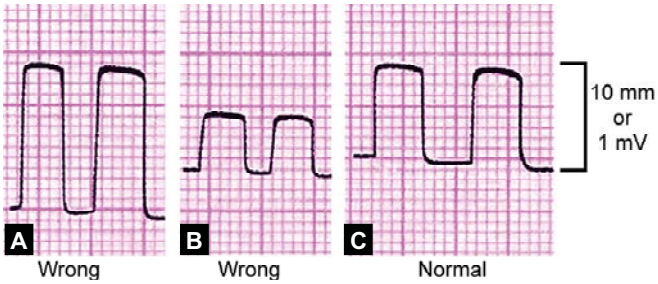

Figs 6.2A to C: The electrocardiographic paper and 1 mV calibration signals: **A.** Double standardization 2 cm = 20 mm = 1 mV; **B.** Half standardization 0.5 cm = 50 mm = 1 mV; **C.** Normal standardization 1 cm = 10 mm = 1 mV

2. **Half standardization:** Occasionally, when the voltage or height of QRS deflection is extremely high touching the upper or lower white border of the graph above or below with normal standardization; such as in hypertrophy of one or both ventricles, then voltage is reduced to half (5 mm or 0.5 mV)—called '*half standardization (Std 1/2)*'. For calculation of voltage of a complex, it has to be multiplied by 2 because here one big square (5 mm) equals 1 mV.
3. **Double standardization:** If the waveforms are too small and make the interpretation difficult, then *double standardization* is done. At double standardization, a box of 2 mV in height is recorded which equals 4 large (20 small) squares. At double standardization, 20 mm equals 1 mV (Fig. 6.2).

Variations during Standardization

Undershooting (overdamping) or overshooting (underdamping) may occur when writing stylus is either too firm or too loose on the plateform or writing edge of ECG paper, so that its excursions are somewhat retarded (undershooting) or are too free to produce spikes on the inscribed signal (overshooting).

1. **Overdamping or undershooting:** During normal standardization (Fig. 6.3A) two clear cut right angles are observed; one at the junction of the end of upstroke of inscribed signal with horizontal part and the other at the junction of downstroke with baseline. One can say that the normal inscribed signals is a box in the form of perfect rectangle with respect to baseline. In overdamping due to rigid or firm stylus, these two right angles get blunted or become rounded of (Fig. 6.3B). Due to overdamping, the electrocardiographic deflections may be diminished in amplitude and a small s wave may in fact disappears and ST segment appears as elevated—called *pseudoelevation* (Fig. 6.4).

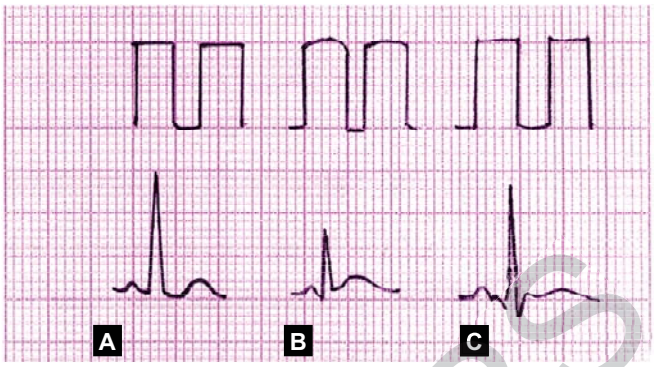

Fig. 6.3A to C: Variations during standardization: **A.**Normal standardization; **B.** Overdamping; **C.** Underdamping

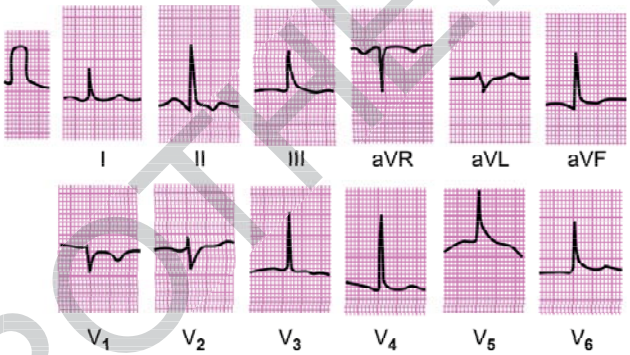

Fig. 6.4: Overdamping of stylus producing pseudoelevation of ST segment in most of the leads

2. **Underdamping or overshooting (Fig. 6.3C):** The overshooting of the upswing and the downswing of the recording stylus which is too loose or not pressed firmly, results in sharp 'spikes' at the corners of the inscribed signal box, called underdamping (Fig. 6.3C). Due to underdamping, the deflection may be inscribed more rapidly resulting in a fractionally narrower complex. Secondly the deflection gets increased in amplitude and a S wave, in fact, may become exaggerated.

HEART RATE

It is defined as number of beats per minute (bpm). On ECG, heart rate usually implies ventricular rate which means the number of QRS complexes in a minute. Normally, each QRS is preceded by a P wave, hence, heart rate also refers to atrial rate (the number of P waves in a minute). Therefore, on ECG, both ventricular and atrial rates can be calculated if there is dissociation between atria and ventricles and their rates are unequal. Normally, there is no dissociation, hence, both atrial and ventricular rates are equal.

JAYPEE BROTHERS

Calculation of Heart Rate on ECG

Whether you calculate ventricular rate or atrial rate, three methods are usually employed depending on the regularity or irregularity of the heart rhythm.

i. ***If rhythm is regular,*** then following methods may be used:

a. 1500 method
b. R-R method

a. **1500 method:** The method is called 1500 method because one minute on ECG covers 1500 small squares (1 big square = 0.2 sec; 5 big squares = 1 second; 60 big squares = 1 minute). This method is used to calculate the heart rate when rhythm is regular. On ECG paper, there is a time marker in the form of a darkline on white upper border, count the number of QRS complexes in-between 12 such lines and multiply it by 5 to get the heart rate in one minute or count in-between 30 such lines and multiply it by 2.

b. **R-R method**: Count the number of small squares between two consecutive QRS complexes in any lead. Dividing 1500 by number of small squares that you have counted, gives the heart rate (ventricular rate) per minute. Thus; *ventricular rate per minute = 1500 ÷ No. of small squares between two adjacent QRS complexes.* For example, if the distance, between two adjacent QRS is 15 small squares, then heart rate will be 1500 ÷ 15 = 100 / min (Fig. 6.5). To save time, students can make a chart that can be used for at-a-glance calculation of heart rate.

For rapid calculation, find out two consecutive R waves whose peak falls on the lines irrespective whether dark or light. Then count down the number of big squares and the remaining small squares between them. The big squares are multiplied by 5 and the remaining small squares are just added to it, gives the total number of small squares between two adjacent QRS complexes. Dividing 1500 by number of small squares that you have counted, gives the heart rate. This is similar to 1500 method.

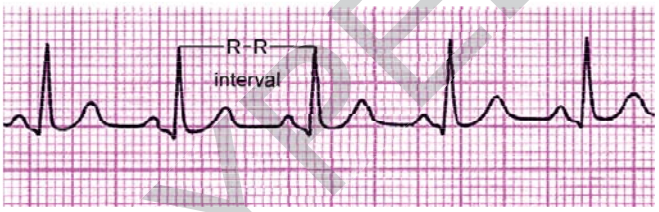

Fig. 6.5: Calculation of heart rate by R-R method: The distance between two successive QRS (R-R interval) is 15 mm, hence, heart rate is 1500 ÷ 15 = 100/min and is regular

ii. ***If rhythm is irregular***, then heart rate is calculated by : Six second method (This gives approximate heart rate).

Six second method: Provided that the heart rate is irregular and the 1500 method or R-R interval method cannot be applied, the six second method is used to calculate the heart rate. This is easiest but least accurate approach for calculating the heart rate. In this method, simply count the number of QRS complexes occurring within 6 seconds remembering that 5 big squares are equal to 1.0 sec for which a time marker in the form of a darkline on the upper white border is provided. In other words, count QRS complexes in 30 big squares or within 6 dark lines on upper white border, which equals to 6 seconds. Multiplying the result by 10, gives the approximate heart rate of that patient in one minute (Fig. 6.6A).

NATURAL PACEMAKERS AND HEART RATES

The heart has an intrinsic property to generate pace. The dominant pacemaker is sinoatrial node (SA node) situated in the right atrium. The SA node independently starts the electrical impulse which is propagated. The ability to initiate the impulses spontaneously is called *automaticity*.

Subsidiary Pacemakers

Other potential pacemaker sites in the heart are:

i. Atria
ii. Atrioventricular (AV) node
iii. Ventricles

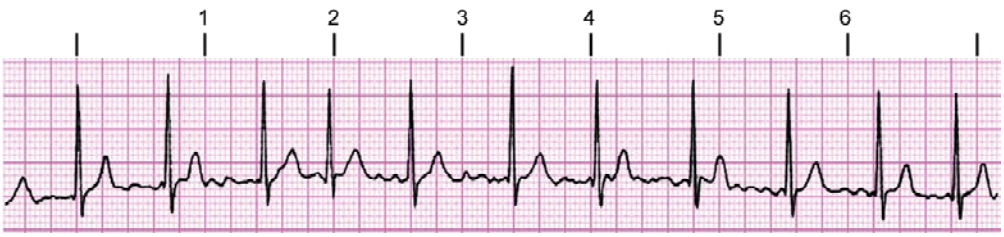

Fig. 6.6A: The calculation of heart rate on ECG by six second method. The number of QRS complexes in 6 seconds are 9, hence, heart rate is 9 × 10 = 90/min and is irregular

JAYPEE BROTHERS

These subsidiary pacemakers sites remain dormant when SA node sets the pace. All these sites have automatic pacemaker cells, which can also initiate impulses independently, usually at a slower rates than the SA node. Normally, SA node being the fastest sinus pacemaker dominates the subsidiary pacemakers and does not allow them to generate pace.

These lower (subsidiary) pacemakers generate the impulses when SA node fails to generate the impulses. The rhythm that these subsidiary pacemakers provide is called '*escape rhythm*'. These lower escape pacemaker sites act like electrical backup that fire at slower rates.

The intrinsic property of pacemakers to generate the impulses becomes slower and slower from SA node to atria, AV node and ventricles (Fig. 6.6B), therefore, the rate of discharge of various pacemakers may be written as:

SA node > Atria > AV node > Ventricles

The rate of discharge of various pacemakers are given in the information box on page 397. When SA node fails to generate the pace, and if AV node or junction takes up the activity of the pacemaker, then rhythm produced is called '*junctional or nodal rhythm*'. When both SA node and AV node fail to generate the impulses, then one of the ventricles takes up the function of the pacemaker and sets the pace of heart at slowest rate of 15 to 40 beats/min (bpm). The rhythm thus produced is regular and called '*ventricular escape rhythm or idioventricular rhythm*'. This rhythm is typically seen in AV dissociation and complete (third degree) heart block.

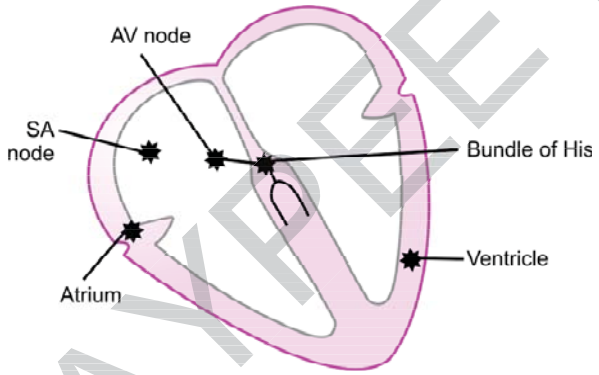

Fig. 6.6A: Pacemaker sites in the heart (diagram)

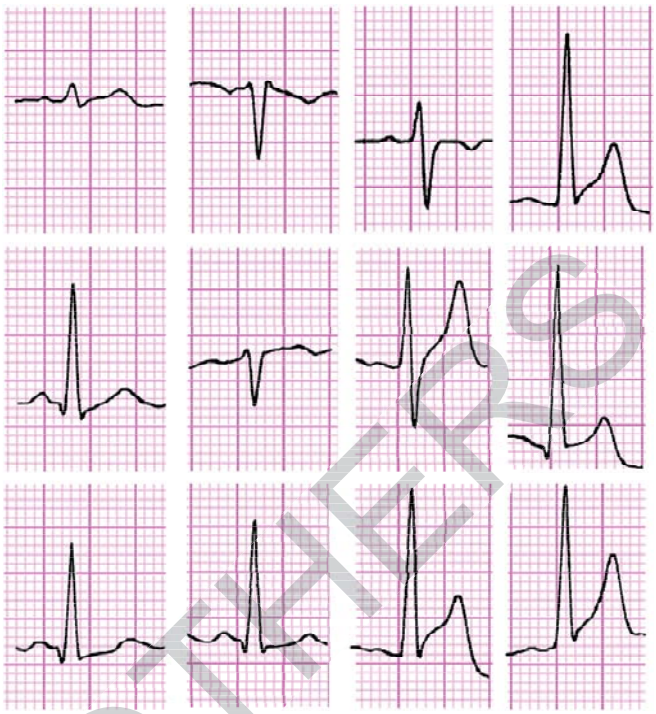

Fig. 6.7: Technically good record of electrocardiogram

PREREQUISITE FOR GOOD ELECTROCARDIOGRAM RECORDING

Artifacts and technically poor records will be obtained if following precautions are not followed:

1. The ECG should be recorded with the patient lying comfortably on a bed large enough to support the whole body. The patient must be fully relaxed. It is better to explain the procedure in advance to an apprehensive patient so as to allay anxiety or fear. The technically good record of ECG is depicted in Figure 6.7. Muscular motions and twitchings can alter the record (Figs 6.8A and B).



Figs 6.8A and B: The effect of muscular contractions/tremors: **A.** An artifact due to shivering producing irregular distortions of baseline hence baseline is darker; **B.** The lead aVF shows motion artifact. There is distortion of baseline as well as P-QRS complexes

JAYPEE BROTHERS

2. Good contact must exist between the skin and the electrode. While applying a chest electrode, attention must be paid to put the electrode on clear skin free of hair or by making space by displacing the hair so that they do not interfere. Poor contact will result in suboptimal record (Figs 6.9A and B).
3. The ECG machine must be properly standardized so that 1 millivolt (mV) will produce a deflection of 10 mm. Incorrect standardization will produce inaccurate voltage of the complexes which can lead to faulty interpretation.

   The patient and the recording machine must be properly grounded to avoid alternating current interference.
4. An electronic equipment in contact with the patient, e.g. an electrically regulated heater or electrically regulated infusion pump or suction machine can produce artifacts on the ECG (Figs 6.10A and B).
5. Improper electrode replacement:
   - Limb lead reversal (reversal of right and left arm leads). This will result in technical dextrocardia (Read dextrocardia)
   - Precordial leads reversal: It will result in unexplained decrease in R voltage in two consecutive leads with a returned of normal progression in the following leads (Fig. 6.10D).

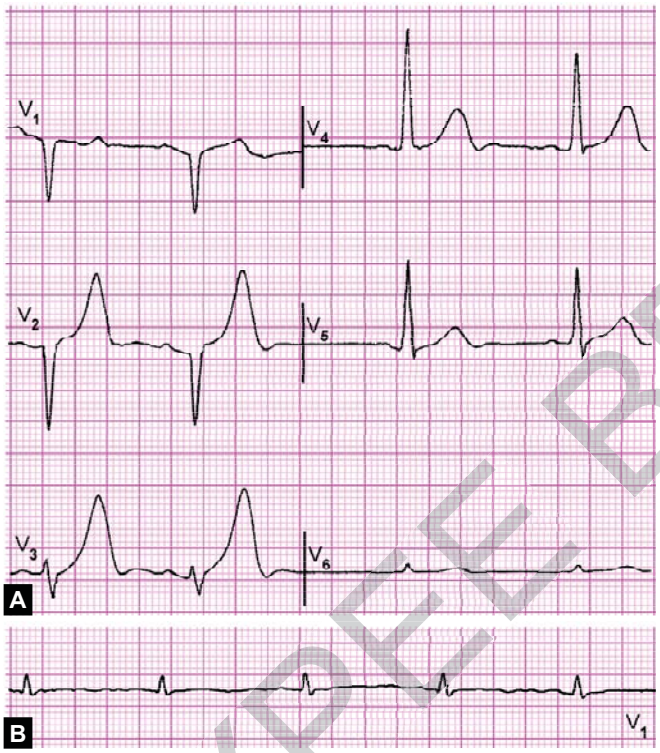

Figs 6.9A and B: Suboptimal record due to poor contact between skin and the electrode: **A.** The artifact is seen in lead V_6 involving P-QRS-T complex. There is suboptimal recording of inverted T in the same lead; **B.** Suboptimal graph (lead V_1) recording very small complexes. This was due to scratching of skin on anterior chest wall leading to poor contact between skin and exploring electrode

NORMAL ELECTROCARDIOGRAM IN ADULTS

A 12-lead normal electrocardiogram consists of 3 standard leads (I, II, III), 3 unipolar leads (aVR, aVL, aVF) and 6 chest or precordial leads (V_1 through V_6). Electrophysiologically, there are three major events that occur during each cycle, i.e. atrial event (depolarization and repolarization), ventricular depolarization and ventricle repolarization. The electrocardiographic deflections or waveforms/complexes inscribed during these events have already been discussed in Chapter 3 (Action potential and waveforms).



Fig. 6.10A: The effect of suction on electrocardiograph simulating atrial flutter. The lead V_5 shows fluttering of the baseline and electrocardiographic deflections. The ECG was recorded during suction in an unconscious patient. The artifact was suspected due to fluttering of electrocardiographic deflections which disappeared after cessation of suction

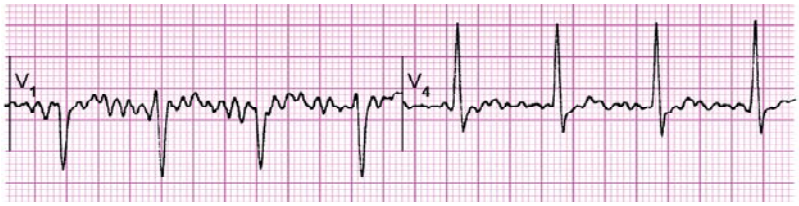

Fig. 6.10B: Effect of muscular contraction simulating atrial flutter recorded from a patient with IV drip in Rt arm. The drip was removed and ECG was repeated which was perfectly normal (not shown)

JAYPEE BROTHERS

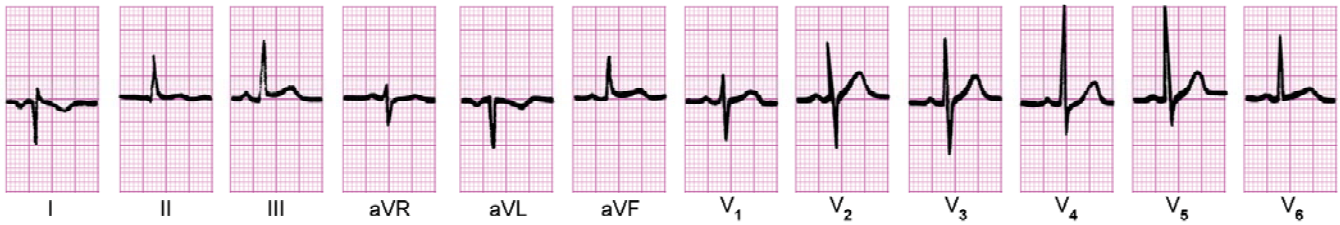

Fig. 6.10C: Improper electrode placement. In this ECG the right arm electrode has been attached to the left and vice versa. The P wave is inverted in leads I and aVL. All the chest leads are normal

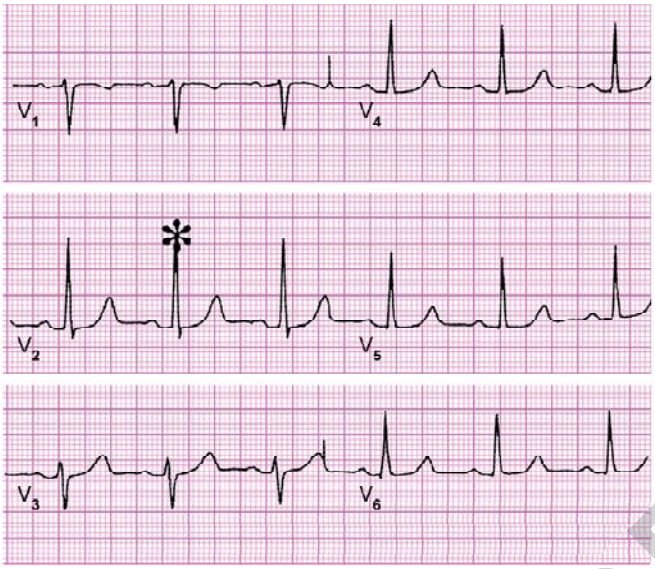

Fig. 6.10D: Precordial lead reversal. The ECG shows sinus rhythm with normal P-R interval. There is unexplained tall R-wave in lead V_1 (x) with loss of R wave in V_3 which indicate lead reversal between V_2 and V_3

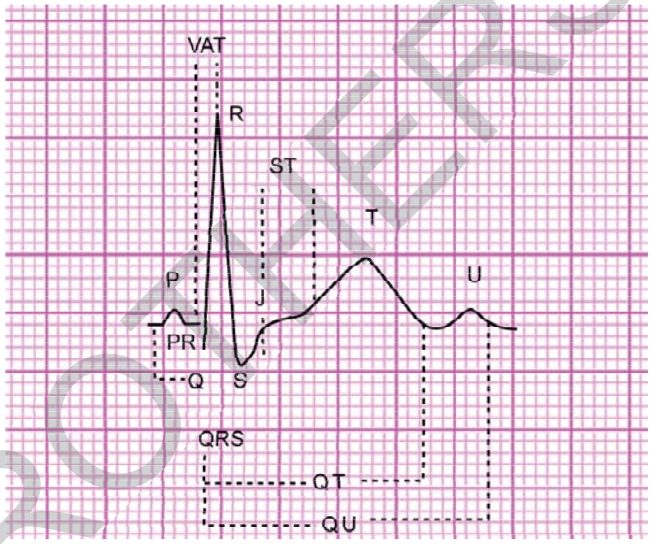

Fig. 6.11: Normal electrocardiogram showing waveforms, segments, junctions and intervals

NORMAL COMPONENTS OF AN ECG COMPLEX (Fig. 6.11)

1. Waveforms: P-QRS-TU
2. Angle: QRS-T angle
3. Segments: PR, ST, TP
4. Junction: QRS – T junction called J point
5. Intervals: P-R, QRS, QT (QTc), P-P, R-R.

Normal P Wave

It is produced by atrial depolarization. It is normally upright in leads I, II, aVF and V_2-V_6. Depending on the frontal plane axis, it may be upright or flat or biphasic in leads III and aVL (Fig. 6.12). It is always inverted in aVR. Depending on its orientation in chest leads, it may be normally upright or biphasic or flat or inverted in lead V_1 and sometimes in lead V_2 also.

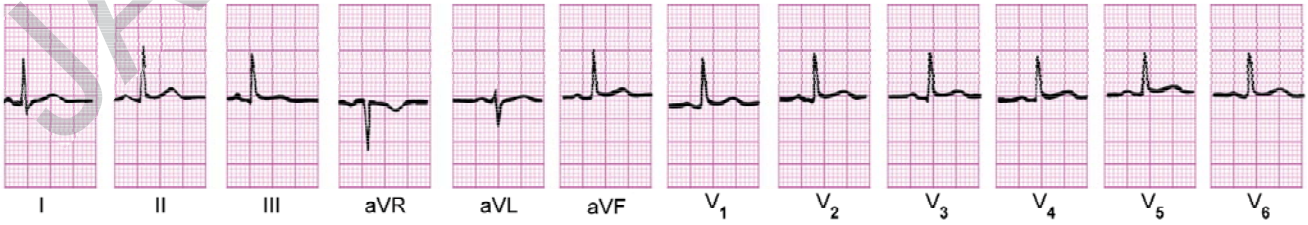

Fig. 6.10E: Lead selector left in one position. The ECG shows normal pattern in limb leads (I, II, III) aVR, aVL, aVF). The chest leads have same pattern of QRS and have same height of R wave which gives an impression that the lead selector has been left in one position. The pattern of chest leads resemble the pattern of QRS in lead aVF which indicates that chest leads, have been recorder with the lead selector left in the aVF position. The ECG was recorded in single channel recorder

JAYPEE BROTHERS

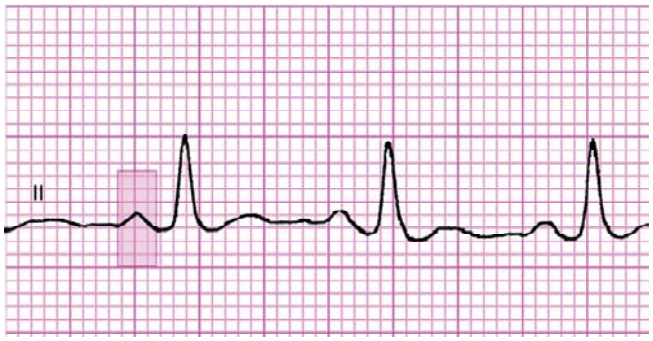

Fig. 6.12: The P wave in frontal plane leads (diagram)

P Wave Characteristics

The characteristics of normal P wave are given in the box.

Normal P Wave

- **Shape:** rounded
- **Height and width:** 2 to 2.5 mm
- **Duration:** 0.08 to 0.10 sec but not greater than 0.11 sec
- **Visibility:** It is best seen in leads II, III and aVF because normal P wave vector is directed towards the positive poles of these leads
- **P wave axis:** It has between +40 to 60°.

Normal QRS-T Complex/Deflection

The QRS complex represents ventricular depolarization and T wave represents ventricular repolarization (Fig. 6.13).

Characteristics of Normal QRS Complex

The normal QRS is positive in all leads except aVR. It is equiphasic in lead (V_3 or V_4). It has following characteristics (Fig. 6.14):

i. Height is less than 25 mm in any lead.
ii. Width or duration of QRS is 1 to 2.5 mm or 0.04 to 0.10 seconds.
iii. Intrinsic or intrinsicoid deflection. This is also called ventricular activation time (VAT).



Fig. 6.13: The electrocardiogram (lead V_5 and V_6) showing normal P-QRS-TU characteristics

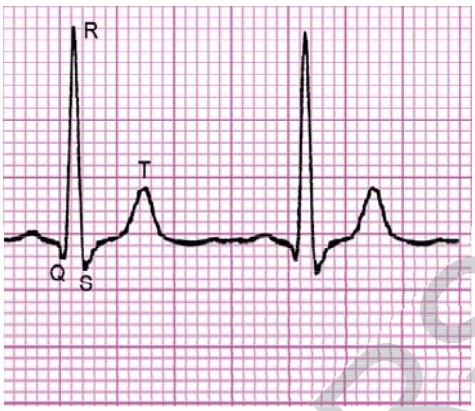

Fig. 6.14: Normal QRS complex (lead V_5). A q wave is the initial negative deflection followed by an upright R wave, which is first positive wave, and then, S wave occurs as first negative deflection after R wave

NB: Deflection means inscription of a wave above or below the baseline, it is termed as negative if it is below the baseline and termed positive if inscribed above the baseline

Normally it should not exceed 0.03 sec in right oriented leads, (V_1 or V_2) and 0.05 sec in left oriented leads (V_5 or V_6). This is shown in diagram (Fig. 3.13).

The normal QRS complex has smooth limbs with no notchings or slurrings. Exception to this is the presence of a small notching on QRS in lead III or aVL due to occurrence of the frontal plane transition zone in one of these two leads. The mean QRS duration is 0.09 sec but it ranges from 0.04 to 0.10 sec. The QRS duration > 0.10 sec, is abnormal.

A normal q wave on frontal plane does not exceed 0.03 second. Normally, it is 0.01 sec in duration and 0.05 mV or less in magnitude. A 'q' wave of more than one small square of ECG paper (>0.04 sec) is considered as an abnormal. A normal q wave is seen in leads I, aVL and V_5 or V_6.

Since lead I is oriented towards left ventricle, it will record a left ventricular epicardial complex (qR) similar to lead V_6 (Fig. 6.14), but of less amplitude because V_6 is more proximal or closer to electrical impulses of the heart.

A small terminal 's' wave may manifest in two or in all the three standard leads (I, II, III) simulating S_I, S_{II}, S_{III} syndrome and when this occurs, then leads V_5 and V_6 will also record S waves. The large S wave in leads I, II and III (S_I, S_{II}, S_{III} syndrome) is usually abnormal (Read Chapter 15).

The left oriented precordial leads (V_5-V_6) record a qR complex (left epicardial complex). The small r wave of right epicardial complex (rS) is larger than q wave

JAYPEE BROTHERS

of left epicardial complex (qR). These initial deflections are due to septal depolarization forces. A relatively tall r wave may uncommonly occur in lead V_1 as a normal variant; when this occurs, the amplitude of R wave will not exceed the amplitude of S wave in the same lead (R< S). Relatively large R wave or R wave equal to S wave may normally be seen in lead V_1 in children < 10 years of age.

The transition zone (the lead which records equiphasic qRS complex, i.e. RS complex) commonly manifests normally in lead V_3 or V_4. Usually the lead V_3 is called transition lead on horizontal plane axis. Transition zone in precordial leads means a transition between right ventricular epicardial complex (rS) and left ventricular epicardial complex (qR).

The amplitude of R wave gradually increases normally as one proceeds from V_1 towards V_5, so that, lead V_5 has invariably a taller R wave than lead V_6. This is called normal progression of R wave in precordial leads. Obese persons, mesomorphic individuals, thick persons, women with heavy breasts will tend to have low voltage of QRS-T complexes normally.

Factor Governing QRS Complex

These are given in the box.

Factors affecting QRS amplitude

Electrical force: More the electrical force generated in the left ventricle, more will be the height of R wave.

Distance between the electrode and the ventricle: Lesser the distance, larger will be the deflection. Since the chest or precordial leads are nearer to the ventricles, hence, record more QRS-T deflections than the frontal plane leads.

Body built: A thin person will tend to have large ECG complexes than an obese person.

Frontal plane QRS: If frontal plane QRS is directed to the positive pole of a lead, then that lead will show a large QRS deflection. For example, if QRS axis is +60°, i.e. towards the positive pole of lead II, then there will be a large deflection of QRS in lead II.

Age: As a whole, there may be less amplitude of QRS in old persons but, otherwise, leads I and aVL may show large deflections than other frontal plane leads due to shift of QRS axis leftwards in old age.

Progression of R Wave in Precordial Leads

Normally, the height of the R wave increases and depth of S wave decreases as one advances from leads V_1-V_6, the mechanism of which has already been discussed in Chapter 3 (see Fig. 3.15).

Abnormalities of R Wave Progression

1. Poor R wave progression (Figs 6.15A and B)
2. Early transition (Read normal variants in next chapter).

1. **Poor 'R' wave progression (PRW):** Poor R wave progression is said to be present when R wave of QRS complex does not become predominantly positive by lead V_4 or R wave in V_1 to V_3 remains small and does not increase progressively in size. It is seen in anterior or anteroseptal myocardial infarction, sometimes in left ventricular hypertrophy and other cardiac diseases such as cardiomyopathy or lung diseases such as chronic obstructive pulmonary disease (COPD).
2. **Early transition:** Early transition is said to occur when QRS complex become predominantly positive earlier than expected normally, i.e. in lead V_1 or V_2. This may be found in posterior myocardial infarction, right ventricular hypertrophy or as a normal variant in infants.

Incorrect placement of electrode may cause R wave progression abnormal

QRS Deflection with their Nomenclature (Fig. 6.16)

The QRS deflections represent ventricular depolarization. The ensuing deflections of an ECG complex are labeled in an alphabetical sequence as P-QRS-TU.

Q wave: An initial downward deflection after the P wave is termed Q wave.

R wave: An initial upward deflection after the Q wave is R wave. If Q wave is absent, then R wave follows the P wave after P-R interval.

S wave: The negative deflection following R wave is termed S wave.

Depending on the amplitude of deflection, these are denoted by *capital* or *small* letters; if it is equal to or more than 5 mm, it is noted by a capital letter, if it is less than 5 mm then it is denoted by small letter. Thus a small r wave followed by a large S wave is

JAYPEE BROTHERS

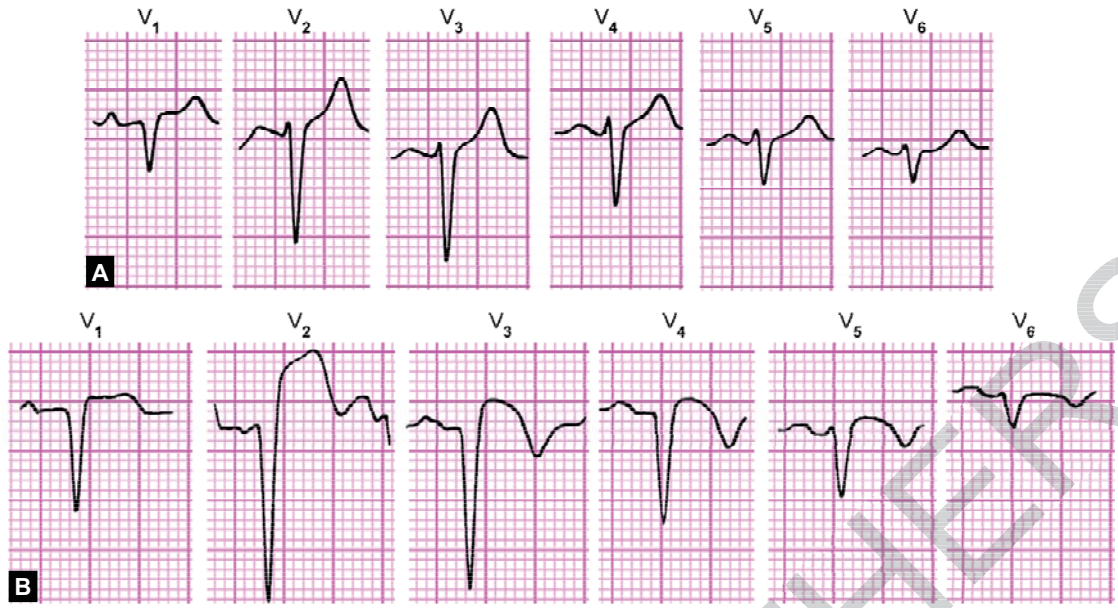

Figs 6.15A and B: Progression of R wave in precordial leads (V_1-V_6):
A. Poor progression of R waves in precordial leads
B. Nonprogression of R wave. The chest leads were recorded from a patient with anterior MI

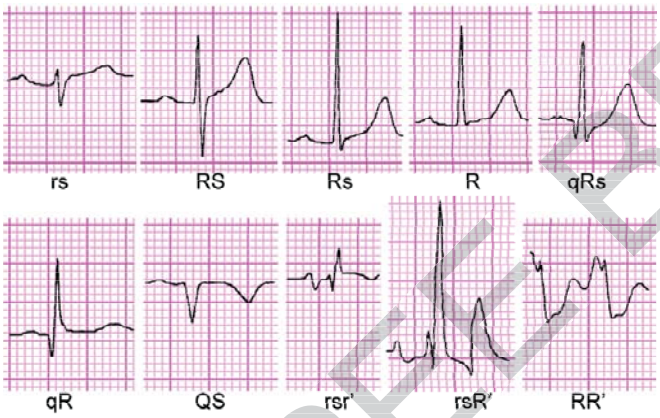

Fig. 6.16: QRS deflections and their nomenclature

termed as *rS complex.* A complex with a large R and S of equal or more or less equal amplitudes is termed as *RS complex;* if both are less than 5 mm, then it is written as *rs complex*. A large R wave (>5 mm) followed by a small S wave (<5 mm) is written as *Rs complex*. A single wave complex, which is completely positive, is termed as *R wave complex.* A complex with a small initial negative deflection followed by a large tall upward deflection, which in turn, is followed by a relatively large terminal downward deflection is written as *qRS;* a deep and wide initial downward deflection followed by a small terminal positivity is written as *Qr complex*. A complex with complete negativity is written as *QS complex.* A second positivity following R deflection is written as (r´). Thus, an *rS complex* followed by a small terminal positivity is written as *rSr´ complex;* when this terminal second positivity is large, the complex is written as *rSR´.* When the deflection is positive and notched, the complex is written as *RR´.*

Normal T Wave (Fig. 6.17)

The T wave normally is a positive deflection with blunt apex and asymmetric limbs that follows QRS complex. The T wave amplitude tends to diminish with age. The T wave is taller in athletes. Since mean T wave vector is to the left, inferiorly and somewhat anteriorly, hence, it is upright in leads I, II and aVF and is inverted in aVR. The polarity of T wave in leads III and aVL depends on the position of the heart and mean frontal plane T axis similar to QRS, i.e. if mean frontal plane T axis is between 0 to +30°, the T wave is inverted in lead III; if it lies between +60 to 90° or more, then the T wave becomes inverted in aVL instead of lead III.

Depending on anterior orientation of mean T wave vector, the T is normally either upright or inverted in lead V_1 but is upright in all other precordial leads (V_2-V_6). If T is upright in V_1, it is of lesser amplitude than T wave of lead V_6. If upright T wave of lead V_1 is either equal or larger than T wave of lead V_6 ($TV_1 \geq TV_6$), it indicates a potential presence of a cardiac disease provided other factors such as an incorrect placement

JAYPEE BROTHERS

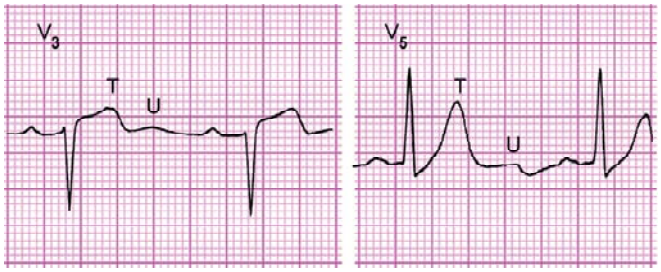

Fig. 6.17: The normal T and U waves. The ECG leads (V_3-V_5) show normal T and U waves which are normally best seen in midprecordial leads

of electrodes and woman with heavy breasts can be excluded. Tall or relatively tall T waves are not infrequently seen in midprecordial leads.

The inverted T wave in leads V_1 to V_3 occurs in infancy and childhood due to right ventricular dominance (juvenile pattern), occasionally be seen in adults called persistent juvenile pattern.

The repolarization wave or T wave is usually an upward deflection in all leads except aVR. It is usually inscribed in the same direction as the QRS complex. It has relatively blunt apex or nadir

Normal U Wave (Fig. 6.17)

The normal U wave is a small, shallow, rounded upward deflection which is inscribed immediately after T wave, is best seen in midprecordial leads (V_2-V_4) if present. It is less than 1 mm in amplitude but may occasionally be as high as 2 mm especially in athletes. It is more prominent in precordial than frontal plane leads. It has same direction as the T wave. It may not be visible in certain normal persons It becomes prominent in hypokalemia, hypocalcemia, hypothyroidism. It represents delayed ventricular repolarization. The genesis and significance of 'U' wave is not well defined.

Normal QRS-T Angle (Fig. 6.18)

The normal T wave axis on the frontal plane has more or less same direction as that of QRS. The angle between QRS and T axes on the frontal plane is called *'QRS-T angle'*, which is normally of 15 to 40° but does not exceed 60° in any circumstance, however, some authorities believe 45° as the upper limit of the normal.

Significance of QRS-T angle. The QRS-T angle becomes wide in a large number of conditions including anterior myocardial infarction. Wide QRS-T angle occurs in certain disorders which have already been discussed in Chapter 4.

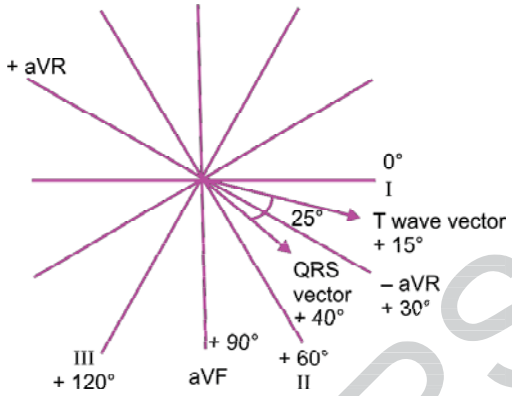

Fig. 6.18: Normal QRS-T angle of 25° drawn (diagram). The mean QRS axis is +40° and T wave mean axis is +15°

NORMAL ELECTROCARDIOGRAPHIC INTERVALS

1. P-R interval
2. QRS interval
3. QT or QTU, QTc and QTd intervals
4. P-P interval
5. R-R interval
6. JT interval

P-R Interval (Figs 6.19 and 6.20)

It is interval between the beginning of the P wave to the beginning of Q wave of QRS complex or R wave of QRS complex if Q wave is not seen. It actually represents the time taken by the impulse to travel from

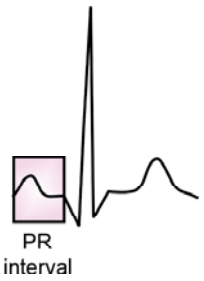

Fig. 6.19: Normal P-R interval



Fig. 6.20: The ECG lead II shows normal P-R interval of (0.16 sec) a heart rate of 83/min

JAYPEE BROTHERS

SA node to atria, then to AV node with its physiological delay, and passage of impulse through bundle of His and its branches. It ends with the beginning of depolarization of the ventricles. The characteristics of normal P-R interval and pathological conditions associated with variations in P-R interval are given in the box.

P-R interval and its abnormalities

Normal duration is 0.12 to 0.20 sec. The P-R interval varies with the heart rate. Rapid heart rate shortens it, while slow heart rate prolongs it. Normally, it is less than 0.12 sec in infants. At heart rate of 60 bpm, P-R interval of 0.22 sec may be regarded as normal.

Short P-R interval (< 0.12 sec) indicates an accelerated conduction through an accessory pathway that bypasses AV node (WPW syndrome) or seen in atrial or nodal ectopics. Certain drugs (steroids) also shorten it.

Long P-R interval (> 0.20 second): Lengthening of P-R interval occurs in various conduction blocks or delayed depolarization of atria due to drugs, hypertrophy or atrial dilatation. P-R interval is also lengthened if conduction through AV node is delayed by diseases or antiarrhythmic drugs (digitalis, beta blockers, calcium channel blockers). If sinus is sick or lazy (sick sinus syndrome), the P-R interval may get prolonged.

QRS Interval (Fig. 6.21)

It is measured from the beginning of QRS to its endpoint called 'J' point. The QRS also includes intrinsicoid deflection or ventricular activation time (VAT), thus it actually refers to time taken for complete depolarization of both the ventricles from endocardial to epicardial surfaces. The normal characteristics of QRS complex have already been discussed.

Widening of QRS complex: The QRS complex is said to be widened if its duration exceeds 2.5 mm or 0.10 sec. The causes of widening of QRS are given in the Table 6.1 and mechanism and type of widening of QRS is shown in Figures 6.22A to H.

Ventricular activation time (VAT): This is also called intrinsicoid deflection which has already been

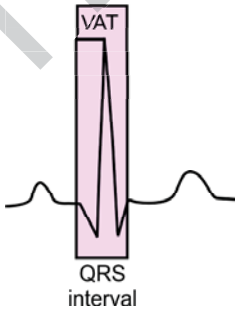

Fig. 6.21: The QRS interval: It is measured from the beginning of QRS to its end-point—the J point (an isoelectric point where S wave returns to the baseline and forms starting point of ST segment)

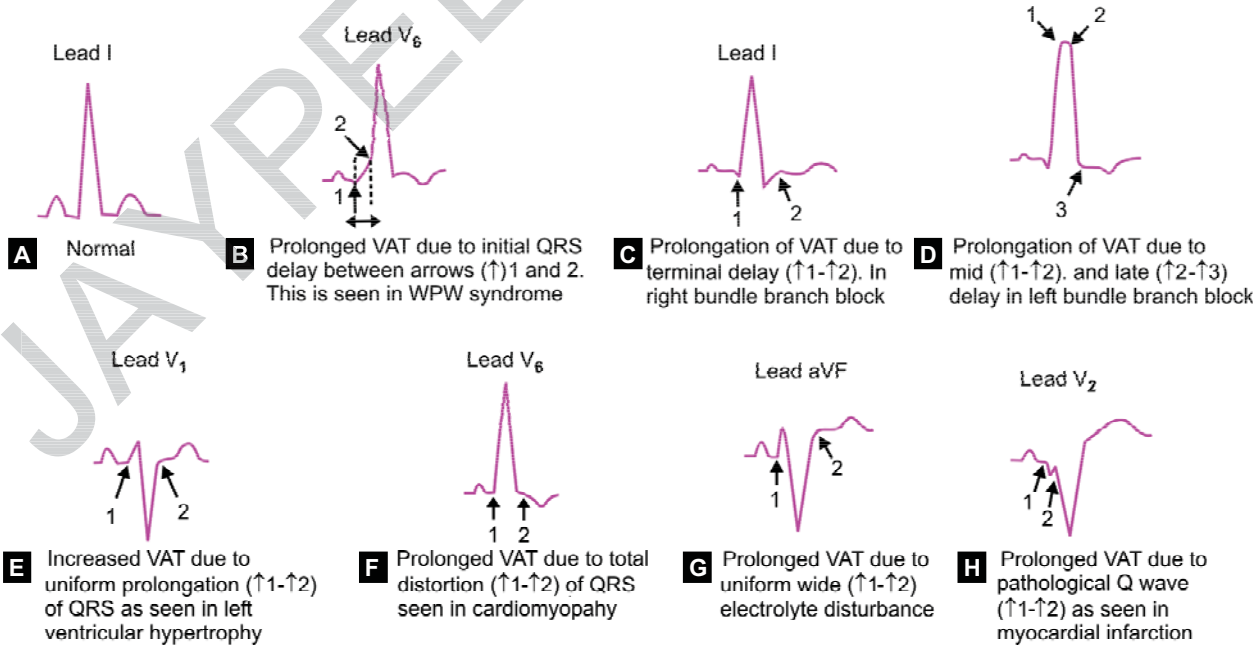

Figs 6.22A to H: Mechanism of widening of QRS and prolongation of VAT in different pathological conditions as compared to normal

JAYPEE BROTHERS

Table 6.1: Causes of widening of QRS

- Bundle branch blocks or fascicular blocks
- Intraventricular conduction delay
- Aberrant conduction within the ventricles such as supraventricular impulse(s) with aberrant conduction or with premature ventricular complexes (VPCs), idioventricular rhythm and ventricular tachycardia
- Early and abnormal activation of the ventricles through an accessory pathway or bypass tract

discussed. It is measured from the beginning of the Q wave to the top of the R wave. It should not exceed 0.03 sec in leads V_1-V_2 and 0.05 sec in leads V_5-V_6 (Fig. 6.23).

QT Interval (Figs 6.24 and 6.25A to C)

The interval from the beginning of QRS complex to the end of T wave is called QT interval. It is sum total of the time taken by depolarization and repolarization of the ventricles. The total electrical activity of the ventricles is reflected in QT interval. It is variable in different parts of the ventricles, but the QT interval measured on the surface electrocardiogram represents the total longest interval of QT.

The QT interval shortens with tachycardia and lenghtens during bradycardia. In other words, the QT changes with change in R-R interval; the latter represents the heart rate. Therefore, for meaningful expression, the QT must be corrected for heart rate-called corrected QT (QTc) interval. The QT interval is corrected for what it would be at a rate of 60 bpm.

$$\text{Corrected QT (QTc) by Bazett's formula} = \frac{QT \text{ interval in sec}}{R\text{-}R \text{ interval in sec}}$$

Measurement of QT: It is measured in seconds from the beginning of Q wave to the end of the T wave. It is difficult to measure sometimes because it is difficult to delineate the beginning and end of the interval. It is customary to measure it in the lead having 'q' wave such as leads I, II, aVL, V_5 or V_6 so as to avoid error of ignoring the initial part of QRS. Similarly, the end point of T wave may be difficult to find out, but if U wave is present, then it becomes easy as the dip between T and U wave becomes the end point of T wave.

The characteristics of QT or QTc are given in the box.

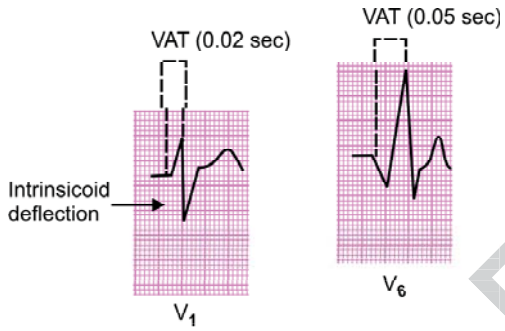

Fig. 6.23: Normal ventricular activation time in right (V_1) and left (V_6) precordial leads

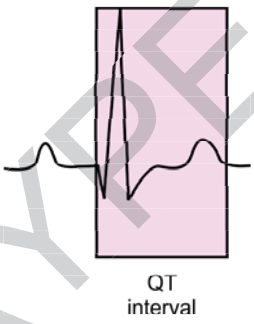

Fig. 6.24: The QT interval (diagram): It is measured from the beginning of QRS to the end of T wave (shaded area)

Characteristics of QT or QTc

Normal range of QTc is 0.35 to 0.43 sec (mean 0.39 + 0.04 sec)

Variation: Physiological variation is due to age, sex and heart rate.

It is longer in females, in old age and during slow heart rate.

Corrected QT (QTc) is measured to obviate the effect of heart rate on QT. It is less than 0.40 sec. in males and less than 0.45 sec in females.

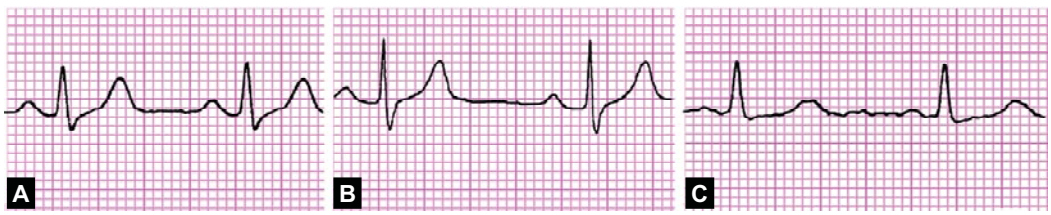

Figs 6.25A to C: The QT and QTc interval: **A.** Normal; **B.** Short; **C.** Prolonged

JAYPEE BROTHERS

Q-T interval—Upper limits of normal (in seconds)

HR/min	*Men and children*	*Women*
40	0.49	0.50
45	0.47	0.48
50	0.45	0.46
55	0.43	0.43
60	0.42	0.42
65	0.40	0.41
70	0.39	0.39
75	0.38	0.38
80	0.37	0.37
85	0.36	0.36
90	0.35	0.36
95	0.35	0.36
100	0.34	0.35

Relation of Heart Rate (R-R Interval) to QT and QTc (Tables 6.2 and 6.3)

1. The QT interval is corrected for what it would theoretically be at a rate of 60 bpm, because at this rate, the R-R interval is 1.0 second and, since the square root of 1.0 second is still 1.0 second, the QT and QTc intervals will be constant.
2. With increasing heart rates (diminishing R-R intervals), the QTc interval is increased but measured QT is decreased.
3. With decreasing heart rates (increasing R-R intervals), the QTc interval is decreased but measured QT is increased.
4. The more the deviation of heart rate from 60 bpm (R-R interval of 1.0 sec), the greater will be the correction.
5. When heart rate is >60 bpm, QT interval is increased by correction to QTc; and the faster the heart rate, the greater is the correction.
6. When heart rate is <60 bpm, the QT interval is shortened after correction to QTc; and slower the heart rate, the greater is the correction.

- *As a general rule, the QT interval does not exceed 0.39 sec with heart rates between 60 to 80 bpm.*
- *A useful rule of the thumb states that with normal heart rate of 60-100 bpm, the QT interval should not exceed half of R-R interval*

The QTc derived from different heart rates associated with constant QT interval are depicted in Table 6.2 and QT derived from different heart rate with constant QTc interval are depicted in Table 6.3.

Table 6.2: QTc derived from different heart rates associated with constant QT interval (0.39 sec)

HR/min	*R-R/sec*	*QT/sec*	*QTc/sec*
50	1.20	0.39	0.36
55	1.10	0.39	0.37
60	1.00	0.39	0.39
65	0.90	0.39	0.41
75	0.80	0.39	0.44
90	0.66	0.39	0.48
100	0.60	0.39	0.50
150	0.40	0.39	0.62

Table 6.3: QT derived from different heart rates associated with constant QTc interval (0.39 sec)

HR/min	*R-R/sec*	*QT/sec*	*QTc/sec*
50	1.20	0.43	0.39
55	1.10	0.41	0.39
60	1.00	0.39	0.39
65	0.90	0.37	0.39
75	0.80	0.35	0.39
90	0.66	0.32	0.39
100	0.60	0.30	0.39
150	0.40	0.25	0.39

The causes of long and short QT (QTc) are given in Table 6.4.

Danger: *It has dangerous consequences such as prolonged QT may lead to torsade de pointes (ventricular tachycardia)*

Table 6.4: Causes of long and short QT or QTc

Long QTc

- Physiological—During sleep
- Congenital—Prolonged QT syndrome—The Jervell and Lange-Nielsen syndrome and Romano-Ward syndrome
- Acquired
  - Hypocalcemia
  - Acute myocarditis
  - Acute myocardial infarction
  - Quinine, Quinidine and Procainamide effect
  - Antidepressants (tricyclic and tetracyclics)
  - Head injury with intracerebral bleed
  - Hypothermia
  - Idiopathic hypertrophic cardiomyopathy
  - Advanced or complete heart block
  - Ventricular tachycardia—Torsade de pointes

Short QTc

- Digitalis effect
- Hyperthermia
- Vagal stimulation
- Hypercalcemia

NB: It is essential to measure QTc in patients on anti-arrhythmatic drugs (quinidine and procainamide) or on quinine therapy

JAYPEE BROTHERS

QT Dispersion (QTd)

Recent studies have defined QT dispersion (QTd) as interlead QT variability on the surface electrocardiogram and it may reflect regional variations in myocardial recovery of excitability. The finding of a decreased QT dispersion in patients with heart diseases treated with class III agents (sotalol, amiodarone) further support the concept.

QTd is calculated on electrocardiograms where at least 9 leads show measurable QT interval. The QTd is the difference between the longest and shortest QT interval measured on the 12-lead surface ECG.

QTd = QT *maximum* – QT *minimum*
Corrected QTd (QTcd) = QTc *maximum* – QTc *minimum*

The QT interval is measured from the beginning of QRS to the end of T wave (i.e. return to the TP baseline). If U waves are present, then QT interval is measured to the nadir of the curve between the T and the U waves. For calculation of QTd, 3 consecutive cycles are measured in each lead and the mean of these 3 cycles is taken as mean QTc of that lead. The QT may be corrected by Bazett's formula already discussed.

Clinical Conditions Associated with Wide QTd Interval

There are a large number of conditions associated with wide QTd interval, the pathogenesis of which is unclear (Table 6.5).

Table 6.5: Conditions associated with wide QTd

1. Congenital or acquired prolonged QT syndrome
2. Hypertrophic cardiomyopathy
3. Mitral valve prolapse
4. Coronary artery disease

The normal mean QTc d is 45 ± 15 ms

Clinical Significance

1. QTd is believed to be a measure of electrical inhomogenity in the heart that decreases an individual's threshold for ventricular arrhythmias, hence greater the QTd, greater is the chance to develop an arrhythmia.
2. Heart rate, reflex vagal activity and cardiac afterload physiologically alter the QT dispersion.
3. A significant QT dispersion was found both in patients with congenital and acquired long QT intervals, which is presumed to be the cause of Torsade-de-pointes in these conditions.
4. Certain antiarrhythmic drugs decrease the QT dispersion, hence, QT dispersion may be used to evaluate the efficacy of the drug.

A wide QT dispersion is a stimulus for arrhythmogenesis

QU Interval

It is the interval between the beginning of the Q wave to the end of U wave provided U wave is inscribed; and it represents total ventricular depolarization and repolarization time including that of Purkinje fibers. When the end of T wave is not well visualized or demarcated due to superimposition of a U wave, then QTU (QU) interval may be measured in place of QT interval. In hypokalemia, U wave becomes prominent and QTU is prolonged while actual QT is within normal limit.

P-P Interval (Fig. 6.26)

It is the interval between two successive P waves. It is measured from the beginning of first P wave to the beginning of next P wave (Fig. 6.26). The P-P interval will be regular in normal sinus rhythm and will be equal to R-R interval. However, when ventricular rhythm becomes irregular or when atrial and ventricular rates are regular but differ from each other, then P-P interval will be measured between any 2 consecutive beats to calculate the atrial rate.

R-R Interval (Fig. 6.26)

It is the interval between two successive R waves. It is measured from the beginning of one R wave to the beginning of next R wave of QRS complexes. The R-R interval will be regular like P-P interval in regular sinus rhythm. The R-R interval is used to calculate the ventricular rate. The calculation of heart rate (ventricular rate) by R-R method has already been discussed. Slight variation in R-R interval may be normal due to respiratory effect—called *respiratory sinus arrhythmia*. Irregular R-R interval indicates irregular ventricular response or rhythm.

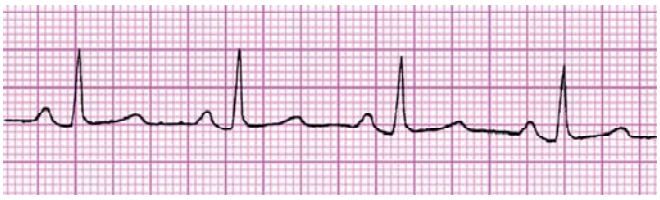

Fig. 6.26: The P-P interval. The ECG lead aVF shows normal P-P and R-R intervals

JAYPEE BROTHERS

JT Interval

It is the interval between the J point (the beginning of ST segment) to the end of T wave, indicates total ventricular repolarization. In patients of bundle branch block, QT interval includes abnormally wide QRS complex, in such patients, JT interval gives accurate assessment of ventricular repolarization time.

NORMAL SEGMENTS AND JUNCTIONS ON ECG

1. P-R segment
2. ST segment
3. TP segment
4. R-S junction

PR Segment

Usually in electrocardiography P-R interval is measured in reference to time and P-R segment is measured in reference to distance. The P-R segment is the distance from the end of P wave to the beginning of QRS complex. It serves as a baseline to evaluate depression of ST segment, hence, acts as reference baseline (Figs 6.27A and B) because it is isoelectric. A prominent Ta wave (atrial repolarization wave) may depress the P-R segment in such way that it may mimic q wave of infarction. Prominent Ta waves are seen in conditions that cause atrial injury—atrial hypertrophy/enlargement, atrial infarction, pericarditis, etc.

ST Segment

It is the distance from the end of S wave to the beginning to T wave. The point at which S wave joins the baseline is called 'J' point. Therefore, actually the portion of an ECG complex from the 'J' point to the onset of T wave is ST segment and is usually isoelectric. It may vary in shape and position with reference to baseline in certain disorders which will be discussed in appropriate sections.

The greater part of ventricular repolarization is represented by ST segment. It leaves the baseline immediately after its origin from the end of QRS, and

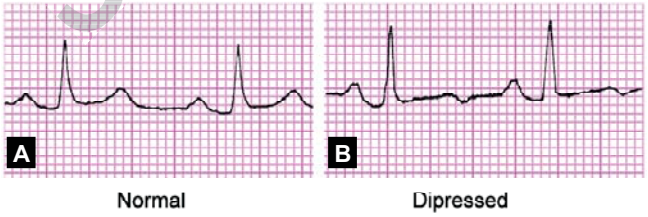

Figs 6.27A and B: **A.** The normal P-R segment; **B.** The depressed P-R segment

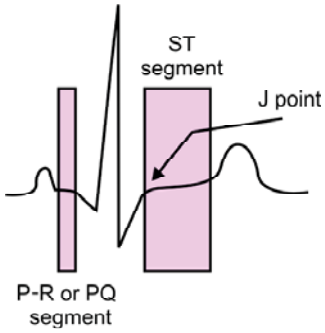

Fig. 6.28: Normal ST segment

becomes isoelectric. The ST segment merges smoothly with the proximal limb of T wave, so, it is difficult to separate them (Fig. 6.28).

The elevation / depression of ST segment is decided with reference to baseline joining the termination of T wave and the beginning of next P wave (T-P line or segment).

Segment

It is the portion of tracing between the end of T wave and the beginning of the next P wave. At normal heart rates, it is usually isoelectric and is used as baseline for determination of ST segment deviation. At rapid heart rate, it shortens and even P wave may come very near to T wave or may encroach the T wave, eliminating the isoelectric TP segment.

R-S Junction

This is a point called 'J' point at which QRS ends with S wave returning to the baseline and ST segment starts. The 'J' point in electrocardiography is important in evaluation of initial ST segment deviation, i.e. elevation / depression (Fig. 6.28).

VOLTAGE MEASUREMENT

This is an important parameter of electrocardiographic interpretation. The voltage of an upright deflection is measured from the baseline to the top of deflection. The voltage of a negative deflection is measured from the lower portion of baseline to the bottom of the wave (Figs 6.29A and B). If the voltage of QRS complex does not exceed 5 mm in any standard leads (I, II, III, aVR, aVL, aVF) and 10 mm in the precordial leads (V_1 to V_6) it is considered as a low voltage graph. The voltage of QRS complex includes both positive and negative deflections. The voltage criteria is useful for diagnosis of left ventricular hypertrophy. The conditions associated with low voltage graph are listed under chronic obstructive pulmonary disease (Chapter 27).

JAYPEE BROTHERS

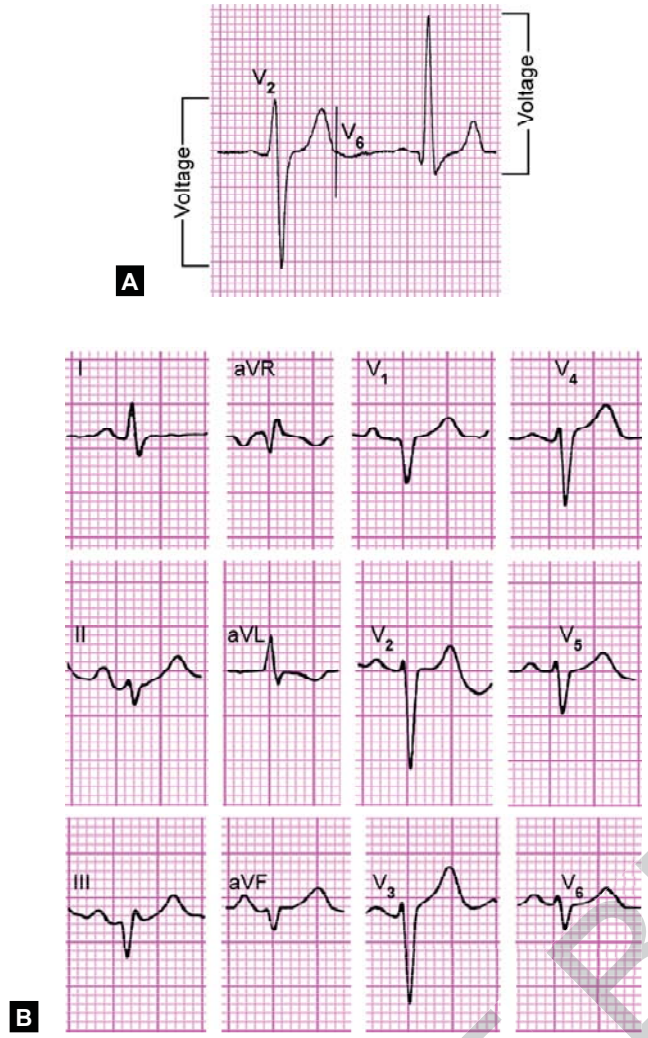

Figs 6.29A and B: **A.** The voltage measurement. The method of voltage measurement (diagram) includes both positive and negative deflections; **B.** Low voltage graph in standard leads

ELECTROCARDIOGRAM IN INFANTS (FIG. 6.30)

In fetus, there is right ventricular dominance, therefore, at birth or during infancy, there is relative hypertrophy of the right ventricle. The ECG in an infant will resemble right ventricular hypertrophy in the adult. Thus, there will be right axis deviation with tall R waves in right precordial leads (V_1-V_2). However, an initial 'q' wave will never appear in V_1. Ventricular activation time in these leads is not prolonged. Within few days of birth, upright T waves may be seen in V_2 to V_6, however, in V_1 it may be upright or inverted, after some time, T waves normally become inverted in leads V_1 to V_3.

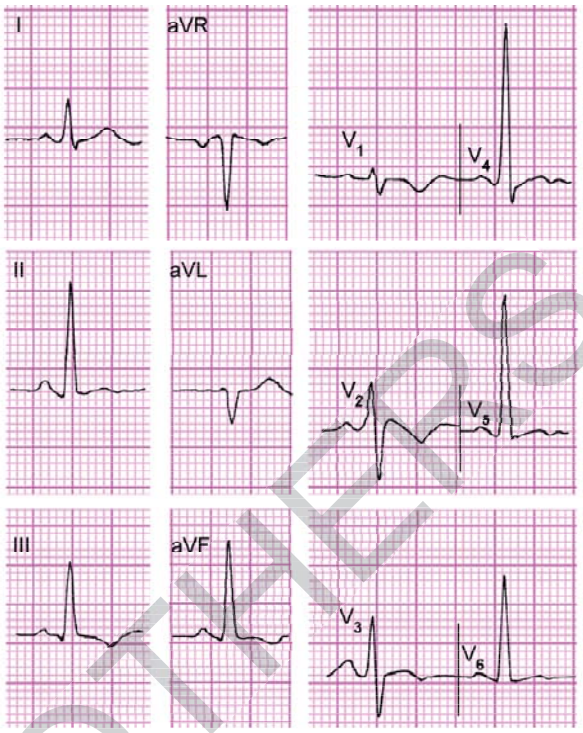

Fig. 6.30: The electrocardiogram from a child (6 years of age)

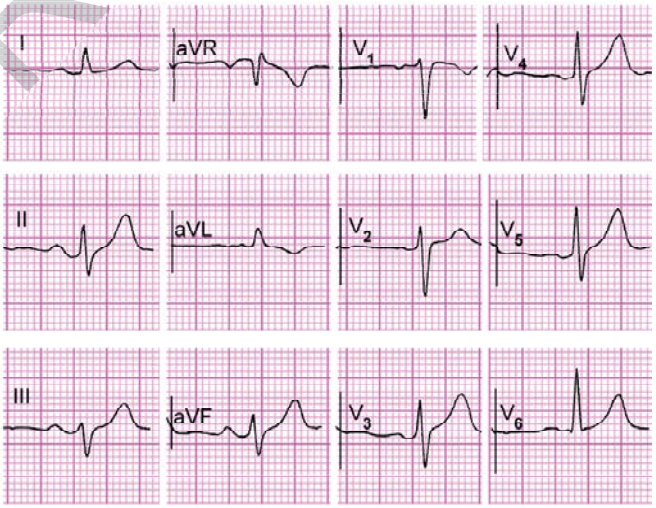

Fig. 6.31: The normal electrocardiogram in an adult. Note rudimentary r wave in V_1-V_2 as compared to ECG of a child

ELECTROCARDIOGRAM IN CHILDREN (FIG. 6.31)

The tall R wave and inverted T wave may persist in right precordial leads (V_1-V_2) for first few years of life. The tall R wave usually becomes smaller and smaller after 5 years of age and becomes smaller than S wave after 10 years of age. The inverted T waves in the right precordial leads frequently

JAYPEE BROTHERS

persists up to 2nd decade of life. This is called *juvenile pattern*. The frontal QRS axis gradually shifts to the left.

The normal electrocardiogram in adult (Fig. 6.31) is depicted for comparison. The r wave in V_1-V_2 is smaller than in children.

Suggested Reading

1. Baett HC. An analysis of the time-relations of electrocardiograms. Heart 1920;7:353.
2. Burgess MJ, Green LS, Miller K, et al. The sequence of normal ventricular recovery. Am Heart J 1972;84:660.
3. Durrer D, VanDam RT, Freud GE, et al. Total excitation of human heart. Circulation 1970;41:899.
4. Goldschlager N, Goldmann J (Eds). Principles of clinical electrocardiography, 13 edn, Prentice-Hall International Inc. 1989.
5. Lepeschkin E. Physiologic basis of U wave. In Schlant RC, Hurst JW (Eds). Advances in Electrocardiography. New York: Grune and Stratton Inc; 1972.
6. Report of Committee on Electrocardiography, American Heart Association. Recommendations for standardization of leads and of specification for instruments in electrocardiography and vector–cardiography. Circulation 1975;52:11.
7. Scher AM. The sequence of ventricular activation. Am J Cardiol 1964;14:287.
8. Surawicz B. The pathogenesis and clinical significance of primary T wave abnormalities. In: Schant RC, Hurst JW (Eds). Advances in Electrocardiography. New York: Grune and Stratton Inc; 1972.
9. VanDam RT, Durrer D. The T wave and ventricular repolarization. Am J Cardiol 1964;14:294.
10. Watanabe V. Purkinje repolarization as a possible cause of U wave in electrocardiogram. Circulation 1975;51:1030.

JAYPEE BROTHERS

JAYPEE BROTHERS

Textbook of
Clinical Electrocardiography
for Postgraduates, Residents and Practicing Physicians

Salient Features

- Unique in itself as it covers all the aspects of electrocardiography arranged in different chapters and sections.
- Emphasizes on the basic concepts of ECG, explains the text of ECG with diagrams and figures.
- This edition is colorful, contains new ECGs barring few old ones. These ECGs have been enlarged to make the interpretations clear.
- Written in simple and easy language having salient features in tables and boxes.
- Certain topics which are not covered by many other ECG books such as pacemakers, ECG in miscellaneous diseases and arrhythmias have been included to make it a comprehensive textbook.
- Helpful to the students preparing for further studies in cardiology.
- It can be carried while posted in the accidental and emergency and the ICU.
- Written especially for postgraduate students (MD DNB) in medicine and resident doctors working in the ICU and practicing physicians.



SN Chugh is a Senior Professor and Pro-Vice Chancellor of Pt BD Sharma University of Health Sciences, Rohtak, Haryana, India. He has a vast experience in teaching and guiding the postgraduate students in medicine. He has been MD examiner at various medical institutions throughout the country. He has been awarded many times during his career for teaching and academic excellence. He is the recipient of Searle's oration from Association of Physicians of India (API), GS Sainani gold medal from Indian Academy of Medical Sciences, Smt Bela Devi oration from West Delhi Physicians Forum and the Rashtriya Gaurav award from the International Social Organisation.

He had been a brilliant undergraduate and postgraduate student. He has written more than 100 papers in national and international journals. He is specialized in the field of Endocrinology and Metabolism. He is a Member of National Academy of Medical Sciences (MNAMS), Fellow of Indian College of Physicians (FICP), Fellow of Indian Academy of Clinical Medicine (FIACM), Fellow of Indian Society of Cardiology (FISC), and Fellow of International Medical Science Academy (FIMSA).

He has distinction of delivering lectures in Continuing Medical Education (CME), conferences, seminars and has taken part in workshops. He has about 11 books to his credit. He has also contributed chapters in other books including *API Textbook of Medicine*.

Available at all medical book stores
or buy directly from Jaypee Brothers through online shopping at www.jaypeebrothers.com

or call + 91-11-32558559

JAYPEE BROTHERS
Medical Publishers (P) Ltd.
www.jaypeebrothers.com

ISBN 978-93-5025-040-2