thers.com, for detailed information on anatomy books, visit our website www.jaypeebrothers.com, for detailed information on anatomy books

Lalita Kulkarni

Foreword
MN Koti

ANATOMY SIMPLIFIED

- Key questions (Upper limb, lower limb, abdomen and pelvis, thorax and head and neck)
- Short notes (Upper limb, lower limb, abdomen and pelvis, thorax and head and neck)
- Long questions (Upper limb, lower limb, abdomen and pelvis, thorax and head and neck)
- Key diagrams (Upper limb, lower limb, abdomen and pelvis, thorax and head and neck)
- MCQ tips (Upper limb, lower limb, abdomen and pelvis, thorax and head and neck)
- MCQs (Upper limb, lower limb, abdomen and pelvis, thorax and head and neck)
- Neuroanatomy (Key questions, short notes, long questions, MCQs and glossary)
- Embryology (General embryology, systemic embryology and MCQs)
- Histology
- Anatomy nomenclature

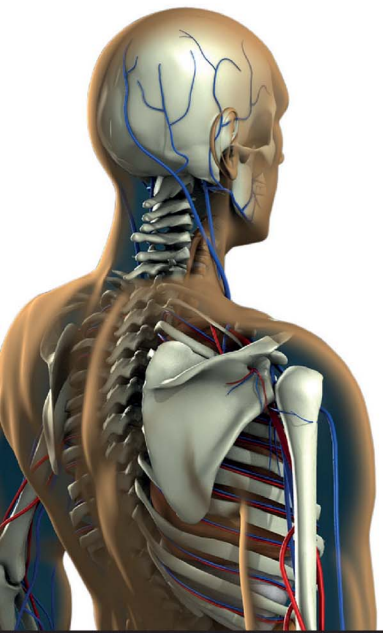

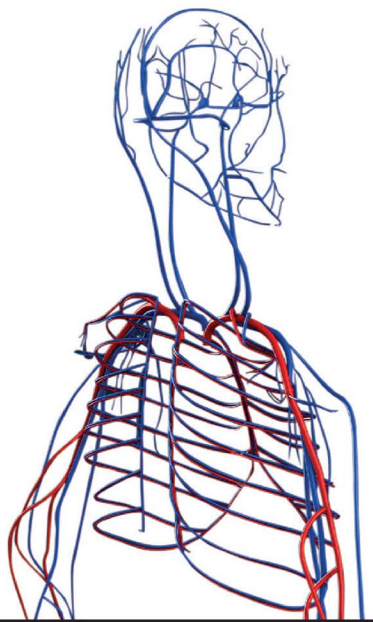

ANATOMY

Contents

Key to Anatomy 1

Introduction 3

Section I: Upper Limb 7

1. Key Questions *9*
2. Short Notes *14*
3. Long Questions *53*
4. Key Diagrams with MCQ Tips *65*
5. Multiple Choice Questions (MCQs) *70*

Section II: Lower Limb *75*

6. Key Questions 77
7. Short Notes *84*
8. Long Questions *117*
9. Key Diagrams with MCQ Tips *131*
10. Multiple Choice Questions (MCQs) *140*

Section III: Abdomen and Pelvis 149

11. Key Questions *151*
12. Short Notes *154*
13. Long Questions *194*
14. Key Diagrams with MCQ Tips *236*
15. Multiple Choice Questions (MCQs) *244*

Section IV: Thorax 249

16. Key Questions *251*
17. Short Notes *256*
18. Long Questions *269*
19. Key Diagrams with MCQ Tips *281*
20. Multiple Choice Questions (MCQs) *286*

Section V: Head and Neck **291**

21. Key Questions *293*
22. Short Notes *315*
23. Long Questions *373*
24. Key Diagrams with MCQ Tips *425*
25. Multiple Choice Questions (MCQs) *438*

Section VI: Neuroanatomy **453**

26. Key Questions *455*
27. Short Notes: Brain *462*
28. Short Notes: Spinal Cord Tracts *473*
29. Short Notes: Cranial Nerves *482*
30. Long Questions *487*
31. Multiple Choice Questions (MCQs) *501*
32. Glossary *505*

Section VII: Embryology **507**

33. General Embryology *509*
34. Systemic Embryology *536*
35. Multiple Choice Questions (MCQs) *584*

Section VIII: Histology **593**

36. Histology *595*

Section IX: Anatomy Nomenclature **619**

37. Literal Meanings of Anatomical Terms *621*

Bibliography *629*

Instructions for Students

Dear Students,

- This is an examination-oriented book; for the detailed understanding of the subject you must read the standard textbooks
- Only important topics are covered in this book, to make it **simplified**
- To remember anatomy, you must draw diagrams repeatedly; a **diagram speaks more than 1000 words**!
- Form of the questions in the examination may differ than given in this book; so read the questions carefully in the examination.

Lalita Kulkarni

Chapter

4

Key Diagrams with MCQ Tips

JAYPEE BROTHERS

Diagrams for

- Serratus anterior muscle
- Trapezius
- Dorsal interossei
- Palmar interossei
- Cubital fossa
- Flexor digitorum superficialis
- Flexor digitorum profundus
- Lymphatic drainage of breast
- Shoulder girdle

Q. Serratus anterior muscle

Ans.

- Inserted on costal surface of scapula along its medial border
- Long thoracic nerve of Bell (C5, C6, C7) supplies the muscle
- Injury to above nerve leads to 'winging of scapula'.

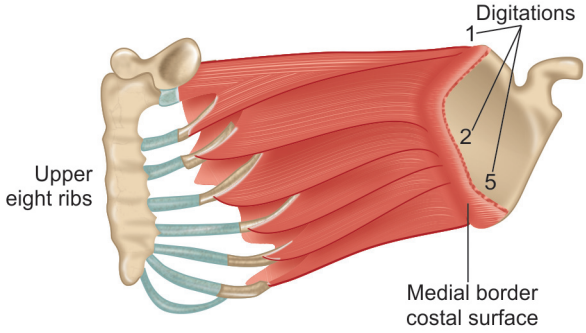

Q. Trapezius

Ans.

- Also known as shawl muscle
- Supplied by spinal part of accessory nerve
- Elevates and retracts the scapula.

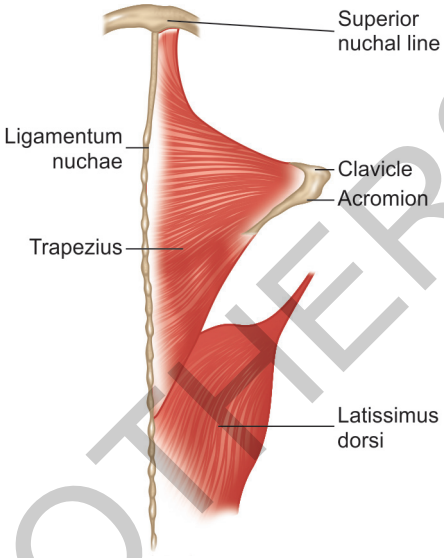

Q. Dorsal interossei

Ans.

- Bipennate muscles taking origin from adjacent sides of metacarpal bones
- Deep branch of ulnar nerve supplies all the interossei
- Abducts digits away from midline [i.e. dorsal interossei abduct (DAB)].

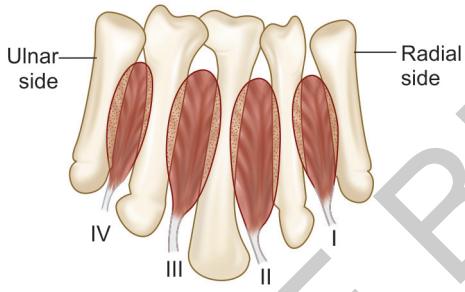

Dorsal interossei

Q. Palmar interossei

Ans.

- Unipennate muscles between the shafts of metacarpal
- Deep branch of ulnar nerve supplies all the interossei
- Adduct digits toward midline [i.e. palmar interossei adduct (PAD)].

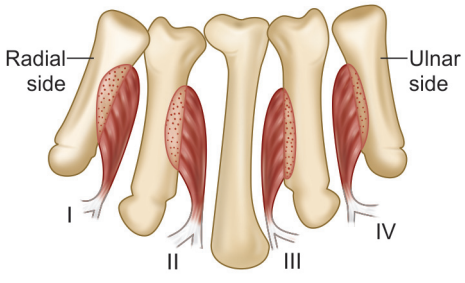

Palmar interossei

JAYPEE BROTHERS

Q. Cubital fossa

Ans.

- Brachial artery lies medial to biceps tendon
- Ulnar nerve is posterior to medial epicondyle
- Median nerve passes between two heads of pronator teres
- Radial nerves divides into superficial and deep branches
- The deep branch goes below the upper border of supinator.

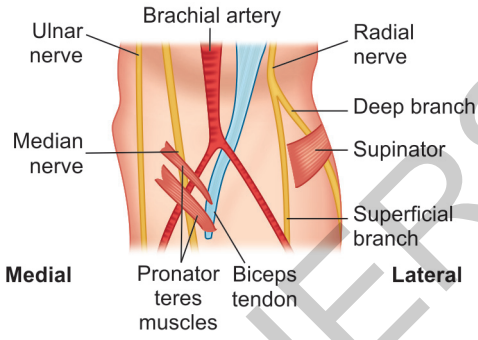

Q. Insertion of flexor digitorum superficialis

Ans.

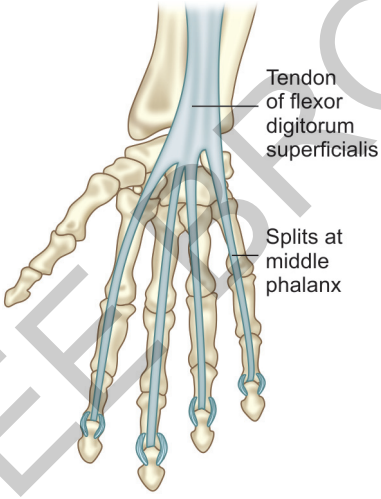

Flexor digitorum superficialis

Q. Flexor digitorum profundus

Ans.

- Flexor digitorum profundus is a hybrid muscle
- Medial half supplied by ulnar nerve
- Lateral half supplied by median nerve
- The tendon goes below the split end of flexor digitorum superficialis.



Flexor digitorum profundus

Q. Lymphatic drainage of breast

Ans.

- To axillary lymph nodes 75%
- To internal thoracic (mammary) nodes 20%

JAYPEE BROTHERS

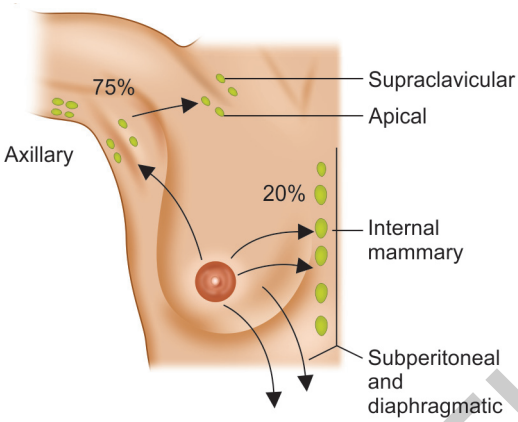

- To posterior intercostal nodes 5%
- Subareolar plexus of Sappey is present
- Radial incisions are taken to avoid cutting of lactiferous ducts
- Lymphatics from lower and inner quadrants of breast may communicate with subdiaphragmatic and subperitoneal plexus
- Staging of breast cancer depends on nodal status (size, number, fixity).

Q. Shoulder girdle

Ans.

- Connects upper limb with axial skeleton
- Two joints:
  - Sternoclavicular (synovial, compound, complex, type main bond of union is articular disk)
  - Acromioclavicular (plane synovial type).

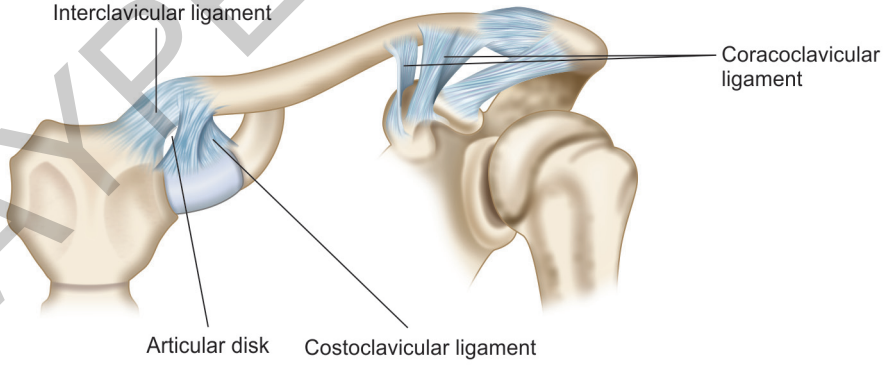

JAYPEE BROTHERS

Q. Medial epicondyle—common flexor origin.

Q. Lateral epicondyle—common extensor origin.

Q. Capitate key carpal bone, first to ossify.

Q. Pisiform—sesamoid bone in tendon of flexor carpi ulnaris, last to ossify.

Q. Palmaris brevis—subcutaneous muscle of upper limb.

Q. Epiphyseal lines and capsular attachments

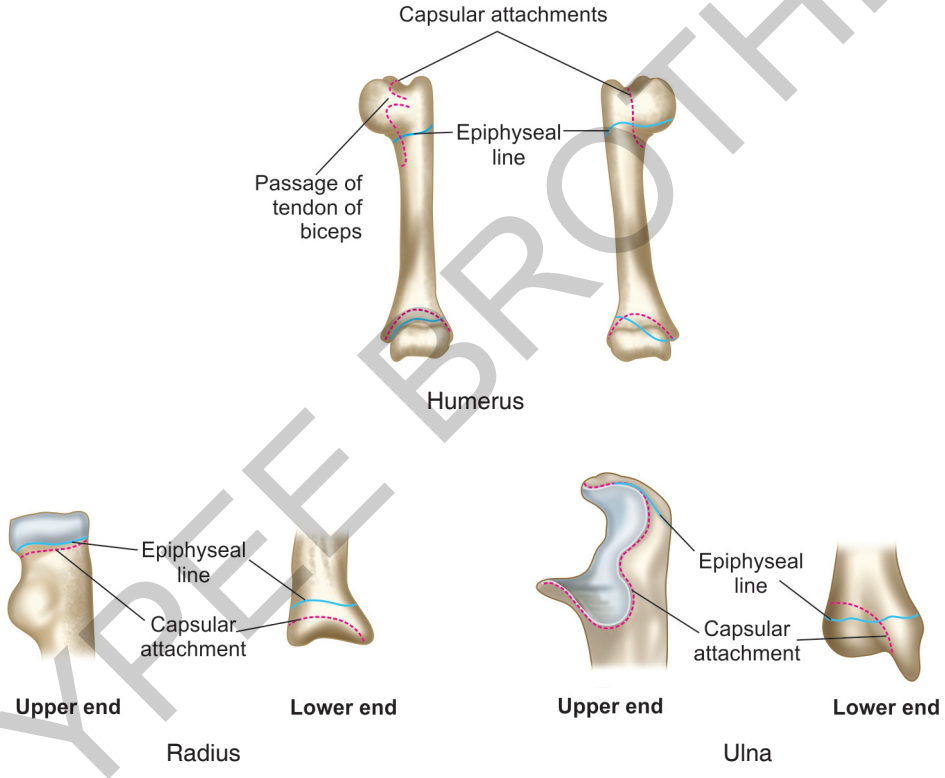

JAYPEE BROTHERS

for detailed information on anatomy books, visit our website www.jaypeebrothers.com, for detailed information on anatomy books, visit our

ANATOMY SIMPLIFIED

Salient Features

- Examination-oriented topics
- Guides students to write theory paper
- Students will be confident for viva voce
- Covers osteology expected examination questions
- Multiple choice questions (MCQs) for each section has been covered
- Meaning of Greek and Latin words are given
- Certain topics are given in tabular form
- Each topic is illustrated with an easily reproducible diagrams
- Interesting mnemonics are given to remember anatomy structures
- Can be used as guide for postgraduate (PG) entrance examinations
- Practical guide for surgeons
- Helps in quick revision before appearing for examination.



Lalita Kulkarni MBBS MS (Anatomy) DNB (Anatomy) MS (ENT) DNB (ENT) has done her MBBS and MS (Anatomy) from Jawaharlal Institute of Postgraduate Medical Education and Research (JIPMER), Puducherry, India, and has also worked in JIPMER as Senior Resident in the Department of Anatomy. She has also worked as a Lecturer in Anatomy at various private medical colleges.

Apart from a Postgraduate (PG) degree in Anatomy, Dr Lalita also possesses a PG degree in ENT from the Government Medical College in Solapur, Maharashtra, India. While in surgical field, she has experienced practical application of the knowledge of anatomy and thus strongly felt the need for students to understand anatomy at the very beginning of their medical school. She has received recognition for her presentations on anatomy and ENT given at various conferences.

Dr Lalita teaches anatomy with devotion and works hard to make it a "student-friendly" subject. Presently, she conducts Anatomy classes in Mumbai, apart from her ENT practice.

Available at all medical bookstores
or buy online at www.jaypeebrothers.com

JAYPEE BROTHERS
Medical Publishers (P) Ltd.
www.jaypeebrothers.com

Join us on facebook.com/JaypeeMedicalPublishers

Shelving Recommendation
ANATOMY

ISBN 978-93-5025-108-9
9 789350 251089