Kadasne's TEXTBOOK OF EMBRYOLOGY



DK KADASNE

Foreword
BR Kate

JAYPEE

CONTENTS

1. **Embryology** 1
Let Us See Some of the Terms Used in the Embryology 1; Let Us Get Familiar with the Terms often Used in Embryological Text 1; Growth 2; Turnover 2; Auxetic Growth 2; Totipotent 2; Chemodifferentiation 3

2. **ABC of Genetics** 4
Study of the Common Terms Used in Genetics 4; Allele 4; Genes 5; Autosomal Dominant Disorders 5; Autosomal Recessive Disorders 6

3. **Introduction to Chromosomes and Cell Division** 7
Chromosomes 7; Structure of Chromosomes 7; Classification of Chromosomes 7; Karyotyping 8; Functions of Chromosomes 8; Chromosomal Abnormalities 8; Deletion 11; Cell division 11; Mitosis 11; Meiosis 12; Stem Cells 13; Parkinson's Disease 14; Alzheimer's Disease 14; Blood Diseases 14; Spinal Cord Injury 14

4. **Development of the Tissues of the Body** 15
Epithelia 15; Development of Glands 15; Glands Arising from Ectoderm 15; Glands Arising from Mesoderm 15; Glands of Mixed Origin 15; Mesenchyme 16; Connective Tissue 16; Blood Formation 16; Histogenesis of Cartilage 16; Histogenesis of Bone 17; Enchondral Ossification 18; Development of Long Bone 18; Epiphyseal Zones 18; Metaphysis 19; Anomalies of Bones 19; Development of Striated Muscle 20; Sclerotome 21; Dermatome 21; Myotome 21; Development of Smooth Muscle 21; Cardiac Muscle 22; Development of the Neurones 22; Spongioblast 23; Formation of Myelin Sheath 23

5. **Structure of Sperm** 25
Head 26; Body 26; Tail 27; Spermatogenesis 27; Spermatogonia A 28; Ovum 29; Oogenesis 29; Formation of Ovarian Follicle 31; Role of Follicular Cells and the Oocyte 34

6. **Ovulation** 35
What Promotes Ovulation? 35; Structure of the Ovum 35; Future of the Ovum 37; Corpus Luteum 37; Corpus Luteum of Menstruation 37; Corpus Luteum of Pregnancy 38

7. **Ovarian Cycle** 41
Ovulation 41

8. **Menstrual Cycle** 43
Follicular Phase 45; Secretory Phase (Progestational Phase) 45; Formation of Decidua 46; Menstrual Phase 48

9. **Fertilization** 49
Capacitation 51; Acrosomal Reaction 51; Secondary Oocyte 51; Disintegration of the Barriers 51; Vitelline Block 52; Effects of Fertilization 52; Parthenogenesis 52; Infertility, Causes and Remedy 52; In Vitro Fertilization of Female Gamete 53; Surrogate Mother 53; Period of Gestation 53; Determination of Sex 53; Cleavage 54; Role of Zona Pellucida 55; Implantation of Blastocyst 56; Abnormal Implantation of the Blastocyst 56; Extrauterine Implantation of Blastocyst 57; Definition of Shock 57; Hydatidiform Mole

JAYPEE BROTHERS

57; Stages of Labor 58; Formation of Germ Layers 58; Formation of Primary Yolk Sac 59; Formation of Extraembryonic Mesoderm 59; Chorion 61; Amnion 61; Formation of the Primitive Streak 61; Gastrulation 62; Intraembryonic Mesoderm 62; Paraxial Mesoderm 63; Intermediate Mesoderm 64; Lateral Plate Mesoderm 64; Splanchnopleuric Layer 65; Neural Tube 65; Formation of Notochord 66; Formation of Secondary Yolk Sac 66; Folding of the Embryonic Disk 67; Connecting Stalk 68; Allantoenteric Diverticulum 69; Meckel's Diverticulum 71; Arrangement of Structures of Embryo before and after the Formation of the Head and the Tail Folds 72

10. The Placenta 75
Types of Implantation 81; Decidua 81; Process of Formation of Villi 82; Development of Placenta 82; Placental Barrier 83; Aid to Memory 83; Functions of Placenta 83; Normal Human Placenta is Hemochorial 84; Placental Circulation 84; Abnormal Implantation of the Ovum 84; Extrauterine Implantation 85; Intrauterine Abnormal Implantation 85; Anomalies of the Placenta 85; Variations of Umbilical Cord Attachments 85; Placental Classification as per the Tissues Involved 87; Hormones 88; Placental Estrogen 88; Action of Placental Estrogen 88; Placental Progesterone 88; Placental Lactogen 88; Prostaglandins 88; Placental – Homograft 88; Hydatidiform Mole 89; The Umbilical Cord 90; Wharton's Jelly 91; Meckel's Diverticulum 91; Allanto-enteric Diverticulum 92; Physiological Umbilical Hernia 92; Amniotic Cavity 92; Amniotic Fluid 94; Functions of Liquor Amnii 94; Amniocentesis 95; Hormones 95; Production of Hormones by Placenta 95

11. Prenatal Diagnosis of Birth Defects 96
Types of Abnormalities 96; Syndrome 96; Association 96; Teratogens 96

12. Methods of Prenatal Disease Detection 97
Treatment 97; Stem Cell Transplantation 97

13. Formation of Branchial (Pharyngeal) Arches 98

First Arch Syndrome (Treacher Collins Syndrome) 99; Derivatives of the First Pharyngeal Arch 101; Derivatives of the Second Arch 101; Derivatives of the Third Arch 101; Skeletal Components Derived by the Pharyngeal Arches 102; Meckel's Cartilage 102; Second Arch 102; Third Arch 103; Morphology of the Nerves of the First Arch 103; Comment on Nerve Supply of Pharyngeal Muscles 103; An Account of the Ectodermal Clefts 103; Branchial Fistula 104; Branchial Sinus 105; Modern Theory of Branchial Cyst Formation 106; Branchiogenic Carcinoma 106; Future of the Endodermal Pouches 106; First Pouch 106; Second Pouch 107; Third Pouch 107; Development of the Thymus 107; Fourth Pouch 107; Fifth Pouch 108

14. The Skin and its Appendages 109
Epidermis 109; Dermis 110; Nails 110; Hair 111; Sebaceous Gland 111; Sweat Glands 112; Anomalies of the Skin and its Associates 112; Aplasia 112; Dysplasia 112; Alopecia 112; Congenital Alopecia 113

15. Development of Mammary Gland 114
Anomalies of the Breast 115

JAYPEE BROTHERS

16. The Skeleton 116
Cartilage Bones 116; Cleidocranial Dysostosis 117; Development of Vertebral Column 117; Congenital Anomalies of the Vertebral Column 118; Spina Bifida 119; Hemivertebra 119; Anterior Spina Bifida 119; Congenital Fusion of Vertebral Bodies 120; Development of Ribs 121; Development of Sternum 121; Accessory Ribs 121; Anomalies of Ribs and Chest Wall 122

17. The Skull and Limbs 123
Anomalies of the Skull 124; Radial Club Hand 124; Ulnar Club Hand 125; Radioulnar Synostosis 125; Pseudoarthorsis of the Clavicle 125; Club Foot (Talipes Equinovarus) 125; Treatment of Club Foot in Early Cases 125

18. Mouth and Teeth 127

19. Development of Teeth 128
Formation of Temporary or Milk Teeth 131; Formation of Permanent Teeth 132 Anomalies of Teeth132; Inherited Abnormalities 132

20. Development of the Tongue 133
Development of Alveolingual Groove 135; Anomalies of the Tongue 135; Salivary Glands 135; Development of Parotid Gland 135; Submandibular Salivary Glands 135; Sublingual Salivary Glands 136; Tonsil 136; Pharynx 137

21. Development of the Thyroid Gland 138
Histogenesis of Thyroid Gland 138; Median Ectopic Thyroid 139; Pyramidal Lobe140; Lateral Aberrant Thyroid 140; Anomalies of the Thyroid Gland 140; Isthmus 140; Lobes 140; Abnormal Sites of Thyroid 140; Sites of Ectopic Thyroid Tissue 141; Anomalies of the Thyroglossal Duct 141; Thyroglossal Cyst 141; Thyroglossal Fistula or Sinus 142; Treatment of Thyroglossal Fistula 142

22. Development of Parathyroids 143

23. Development of Face 144
Nose 145; Intermaxillary Segment 147; Cleft Lip 148; Oblique Facial Cleft 149; Median Cleft Lip 150; Nasal Cavities 150; Vomeronasal Organs of Jacobson 151

24. Development of Palate 152
Secondary Palate 152; Anomalies of the Palate 152; Anomalies of Lip, Palatal and the Drugs 155; Other Anomalies of the Face 155

25. Body Cavities 156
Mesothelium 157; Separation of Cavities 157

26. Development of Respiratory System 158
Development of Larynx 159; Lungs 160; Bronchopulmonary Segments 162; Anomalies of the Larynx 162; Anomalies of the Trachea 162; Anomalies of the Lung 163

27. Development of Diaphragm 166
Separation of Pericardial, Pleural and the Peritoneal Cavities 167; Anomalies of the Diaphragm 168; Congenital Diaphragmatic Hernia 168; Parasternal Hernia 168; Foramen of Bochdalek 169; Eventration of Diaphragm 169; Accessory Diaphgram 169

28. Alimentary System 170
Esophagus 172; Esophageal Stenosis 172; Congenital hiatal Hernia 172; Esophageal Atresia 173; Highlight of Ten's 174; Achalasia Cardia 174; Dysphagia lusoria 174; Stomach 175; Formation of Curvatures 177; Histogenesis of the Stomach 177; Congenital

JAYPEE BROTHERS

Anomalies of the Stomach 177; Congenital Hypertrophic Pyloric Stenosis 177; Formation of Lesser Sac or Omental Bursa 177; Development of Spleen 179; Histogenesis of the Spleen 179; Anomalies of the Spleen 179; Duodenum 180; Anomalies of the Duodenum 180; Duodenal Atresia 180; Duodenal Stenosis 180; Duodenal Diverticuli 181; Development of Liver 181; Congenital Anomalies of Liver 183; Development of the Gallbladder 183; Anomalies of the Biliary Apparatus 183; Biliary Ducts (Extrahepatic) 184; Atresia 184; Development of Pancreas 186; Histogenesis of Pancreas 188; Annular Pancreas 188; Ectopic Pancreatic Tissue 188; Inversion of the Pancreatic Ducts 188; Derivatives of the Midgut 189; Development of Jejunum and Ileum 189; Development of Cecum and Appendix 189; Development of Ascending Colon 190; Development of Transverse Colon 190; Development of Descending Colon 191; Development of Rectum 191; Endodermal Cloaca 191; Development of Anal Canal 191; Anomalies of the Hindgut 193; Congenital Megacolon (Hirschsprung's Disease)193; Common Cloaca 193; Rectovesical Fistula 193; Rectovaginal Fistula 194; Rectourethral Fistula 194; Imperforate Anus 195; Ectopic Anus 195; Physiological Herniation 195; Rotation of the Midgut 195; Formation of Mesentery 197; Congenital Umbilical Hernia 199; Comparison between Omphalocele and Gastroschisis 199; Anomalies of Vitellointestinal Duct 199; Duplication and Diverticuli of the Gut 200; Jejunal Diverticuli 201; Meconium 201; Errors of Rotation 201; Errors of Fixation 202; Situs Inversus 202; Recall of the Developmental Anomalies of the Gut 202

29. Cardiovascular System 203

Atria 204; Division of Atrioventricular Canal 205; Separation of Primitive Atrium 205; Formation of Septum Primum 207; Development of Atria 208; Absorption of Sinus Venosus into the Right Atrium 208; Absorption of Pulmonary Veins 209; Development of Aorticopulmonary Septum 210; Primitive Ventricle and Part of the Right Atrium 210; Ventricular Cavity 212; Formation of the Valves of the Heart 213; Development of Aortic and the Pulmonary Valves 213; Conducting System of the Heart 214; Pericardial Cavity 214; Formation of Sinuses of the Pericardial Cavity 216; External Form of Heart 216; Congenital Anomalies of the Heart 216; Arch Arteries 220; Patent Ductus Arteriosus 223; Aortic Arches and their Derivatives 224; Highlights of 4 225; Coronary Artery Dominance 225; Brachiocephalic Artery 225; Right Subclavian Artery 226; Development of Left Subclavian Artery 226; Development of Common Carotid Artery 226; Internal Carotid Artery 226; Descending Aorta 228; Pulmonary Arteries 228; Developmental Anamolies of the Arch Arteries 228; Septal Anomalies 229; Abnormal Right Subclavian Artery 229; Aortic Stenosis 229; Coarctation of Aorta 230; Branches of Dorsal Aorta 230; Pre-costal Anastomosis 231; Seventh Cervical Intersegmental Artery 231; Derivatives of Anastomoses 232; Formation of the Vertebral Artery 232; Internal Mammary Thoracic Artery 233; Limb Arteries-Upper Limb 233; Anomalies of the Radial Artery 233; Right Subclavian Artery 234; Lower Limb 234; Axis Artery of the Lower Limb 234; Umbilical artery 234; Veins of the Embryo 235; Portal Vein 237; The Umbilical Veins 239; Cardinal Veins 239; Development of Intracranial Venous Sinuses 240; Cavernous Sinus 240; Sigmoid Sinus 240; Transverse Sinus 240; Superior Petrosal Sinus 241; Inferior Petrosal Sinus 241; Sagittal Sinus 241; Left Brachiocephalic Vein 241; Internal Jugular Vein 241; Superior Vena Cava 241; Double Superior Vena Cava 244; Left Superior Vena Cava 244; Posterior Cardinal Veins 244; Subcardinal Veins 244;

JAYPEE BROTHERS

Supracardinal Veins 245; Azygos Venous Lines 245; Subcentral Veins 247; Renal Collar 247; Formation of the Inferior Vena Cava 247; Anomalies of the Inferior Vena Cava 248; Double Inferior Vena Cava 248; Retrocaval Ureter 248; Development of Left Renal Vein 248; Fetal circulation 249

30. Development of Lymphatic System 252
Development of Thoracic Duct 252

31. Urogenital System 255
Development of Kidney 256; Pronephros 257; Mesonephros 258; Metanephros 258; Ascent of the Kidney 260; Rotation of Kidneys 261; Juxtaglomerular Apparatus 261; Probable Causes of Rotation of the Kidney 261; Anomalies of the Kidneys 261; Hydronephrosis 262; Anomalies in the Ascent of Kidneys 262; Defects of Rotation 264; Congenital Polycystic Kidney 264; Congenital Polycystic Kidney is of Two Types 264; Treatment 264; Aberrant Renal Artery 265; Dietl's Crisis 265; Absorption of Caudal Part of the Mesonephric Ducts into the Cloaca 265; Development of the Ureter 266; Anomalies of the Ureter 266; Development of the Urinary Bladder 268; Congenital Anomalies of the Urinary Bladder 268; Development of the Female Urethra 270; Development of the Male Urethra 270; Anomalies of the Urethra 271; Development of Prostate 272; Female Homologues of Prostate 274; Paramesonephric Duct 274; Development of the Uterus 274; Anomalies of the Uterus 276; Anomalies of the Uterine Tubes 276

32. Development of Vagina 277
Summary of Development of Vagina 277; Anomalies of the Vagina 278; Paramesonephric Ducts in Males (Mullerian Ducts) 278; Development of External Genitalia 279; Development of Female External Genitalia 279; Development of Male External Genitalia 279; Development of Male Urethra 279; Prenatal Diagnosis of Sex 281; Anomalies of Male External Genitalia 282; Anomalies of Female External Genitalia 282; Development of Testes 283; Duct System of Testis 284; Descent of Testis 285; Processus Vaginalis 286; Anomalies of the Testis 288; Ectopic Testis 289; Tails of Lockwood 290; Anomalies of the Duct System of Testis 291; Anomalies of the Processus Vaginalis 291; Development of the Ovary 291; Descent of the Ovary 293; Succus Vaginalis in Females 293; Anomalies of the Ovary 293; Derivatives of the Mesonephric Duct 293; Remnants of Mesonephric Tubules 294; Factors Responsible for Determination of the Sex 295; True Hermaphrodite 296; Pseudohermaphroditism 296; Greater Vestibular Glands 296; Comparison between Bulbourethral and Greater Vestibular Glands 296

33. Nervous System 297
Nervous System 297; Neural Tube 297; Cavities of the Brain 298; The Neural Crest 298; Spinal Cord 300; Neurons of the Posterior Gray Column 301; Histogenesis of the Neural Tube 302; Medulla Oblongata 304; Pons 304; The Midbrain 305;

34. Cerebellum 307
Formation of Peduncles 308; Formation of Cerebral Hemisphere 309; Development of Thalamus and the Hypothalamus 311; Development of Corpus Striatum 311; Cerebral Cortex 313; Commissural Fibers 314; Association Fibers 314; Interconnecting Axons 314; Asending Fibers 314; Cerebral Commissures 315; Anomalies of the Brain and the Spinal Cord 315; Variation of Spina Bifida 315; Arnold-Chiari Deformity 316; Dandy

JAYPEE BROTHERS

Walker Syndrome 317; Hydranencephaly 317; Autonomic Nervous System 317; Parasympathetic Neurons 318; Sacral Parasympathetic Outflow 319

35. Ear 320
Development of the Internal Ear 320; Middle Ear 321; External Ear 323; Auricle 324; Congenital Anomalies of the Ear 325

36. Eye 327
Development of Retina 330; Development of Ciliary Body 331; Development of Iris 331; Development of the Lens 332; Development of the Anterior and Posterior Chamber of the Eye 333; Development of the Cornea 333; Development of the Choroids and the Sclera 334; Eyelids 334; Ptosis 335; Lacrimal Gland 335; Nasolacrimal Duct 335;

37. Hypophysis Cerebri 338

38. Pineal Gland 340

39. Adrenal Gland 341
Adrenal Gland 341; Anomalies of the Adrenal Gland 342; Chromaffin Tissue 342

40. Formation of Limbs 343
The Skull of Newborn 343; Functions of the Fontanelle 343; Joints 344; Other Anomalies of the Limbs 345; Story of Thalidomide 346

41. Age of an Embryo 347

42. Twining 348
Dizygotic Twins 348; Monozygotic Twins 349; Parasitic Twins 351

43. Role of Ultrasound in Pregnancy 352

44. Stages in Embryology 354
Highlights of the 2nd Week 354

***Prologue to Human Molecular Biology* 355**

Index 357

JAYPEE BROTHERS

Chapter

4 Development of the Tissues of the Body

Epithelia

Source of formation of epithelium can be from the three basic embryonic layers like ectoderm, endoderm and the mesoderm, i.e. the epithelium arising from the ectoderm are epithelium of the skin, epithelium of the cornea and the conjunctiva. Epithelium of the gastrointestinal tract except some part of the mouth and the anal canal come from the endoderm.

The epithelium of the renal tubules, urinary bladder, uterine tubes and the testes develop from the mesoderm.

Development of Glands

Glands develop from the diverticulum or diverticuli of the epithelium. Initially the diverticulum is solid which gets canalized later. The site of origin of the gland is maintained as the opening of the duct of the gland. (Duct of the submandibular salivary gland). Contrary to this the duct of the parotid gland opens in the vestibule of the mouth though the origin of the duct is at the primitive angle of wide mouth.

Glands Arising from Ectoderm

- Sweat
- Sebaceous
- Mammary
- Parotid gland.

Glands Arising from Mesoderm

Suprarenal.

Glands of Mixed Origin

Prostate.

JAYPEE BROTHERS

Mesenchyme

It has already been seen that the mesoderm develops from mesenchyme which is capable of forming chondroblast, osteoblast and erythroblast while rest of the mesenchyme forms the connective tissue.

Connective Tissue

It does the job of binding the tissues of the body. Mesenchyme gives rise to fibroblast and the fibroblast produce ground substance and the collagen fibers. In addition to it, the mesenchyme contribute to the formation of histiocyte, plasma cells, mast cells including the fat cells.

Blood Formation (Fig. 4.1)

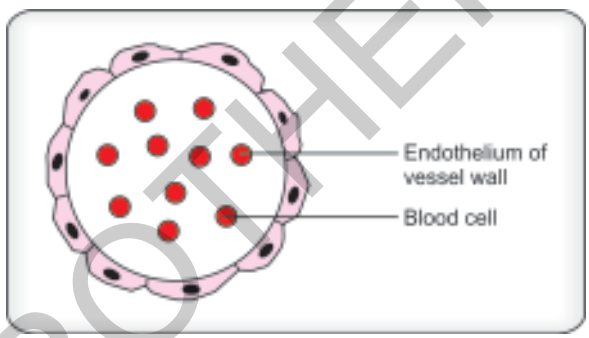

Fig. 4.1: Formation of blood cells and the vessel wall

Blood formation begins before the somites appear and continues till the end. The wall of the yolk sac, allantoenteric diverticulum and the connecting stalk are the sites of blood formation. In the third week of intrauterine life mesodermal cells form blood islands forming blood vessels and the blood cells. The cells at the periphery form the angioblasts form the blood vessels while the cells in the center form the hemopoietic stem cells. Yolk sac blood cells are replaced by permanent cells arising from the mesoderm around the aorta. They form colonies in the liver. These colonies are engaged in the process of blood formation till the 6th month of intrauterine life. Liver remains the vital source of blood formation. From the liver hemopoietic cells migrate to the bone marrow. These stem cells form colony forming units which produce certain type of cells like erythrocyte, megakaryocyte, granulocyte, monocyte, macrophages and lymphocyte. Due to rapid division of the erythropoietic stem cells it appears as if the cell is on the verge of bursting (BFU).

Histogenesis of Cartilage (Figs 4.2 to 4.4)

Chondroblasts are formed from mesenchymal cells. Chondroblasts lay down intercellular substance. As the chondroblast gets trapped and isolated they become the chondrocyte. Collagen fibers are not visible in the hyaline cartilage, however plenty of collagen fibers make their appearance in the fibrocartilage, and elastic fibers are predominantly present in the elastic cartilage. Mesodermal covering of the cartilage is known as perichondrium.

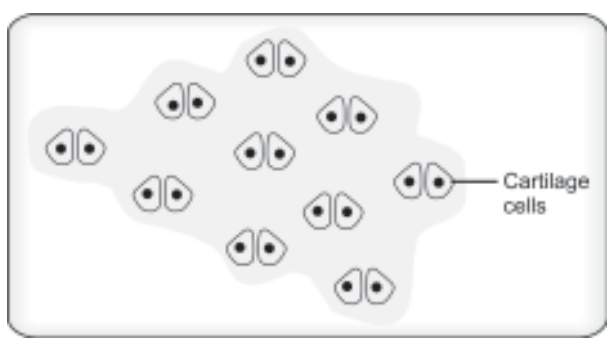

Fig.4.2: Hyaline cartilage

JAYPEE BROTHERS

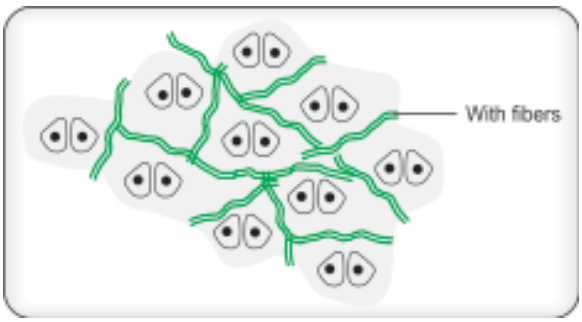

Fig.4.3: Fibrocartilage

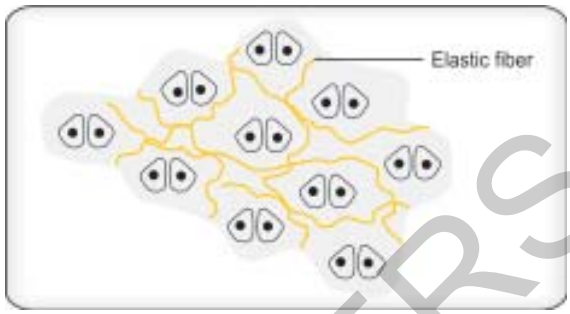

Fig. 4.4: Elastic cartilage

Histogenesis of Bone (Figs 4.5 and 4.6)

Osteocytes, osteoblasts and osteoclasts are the bone cells. Bones develop from the mesoderm. Mesenchymal cells form the cartilage which is replaced by the bone. This formation of bone is called enchondral ossification and the bone is known as cartilage bone. Defective formation of the cartilage bones, results in formation of a dwarf. When bone is formed directly from the mesenchyme is called the membrane bone. Due to defective formation of the membrane bones results in cleidocranial dysostosis. In this condition, the shape of the skull is deformed and the clavicles are absent.



Fig. 4.5: Mesenchyme

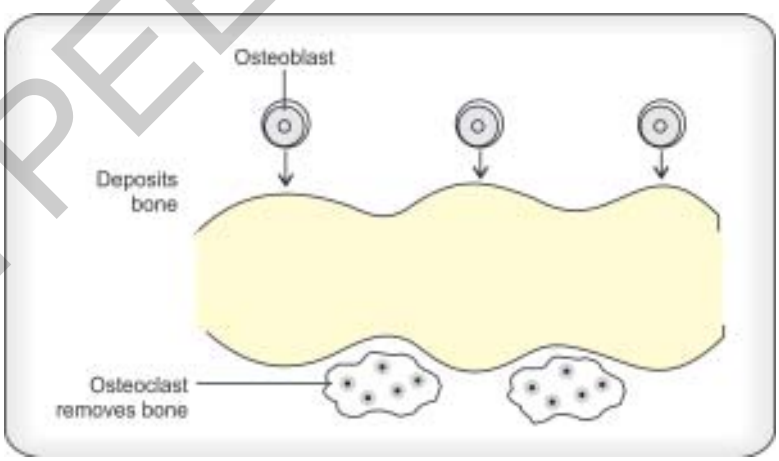

Fig. 4.6: Roll of osteoblasts and osteoclasts in addition and the depletion of the bone

JAYPEE BROTHERS

Enchondral Ossification

Mesenchymal condensation forms chondroblast which forms hyaline cartilage.

Chondroblasts enlarge and the intercellular matrix gets calcified. Calcification of the matrix obstructs the flow of nutrition of the chondroblast. Eventually, they die leaving the empty spaces behind which are called primary areolae. Periosteal bud consisting of osteoblasts, the osteoclasts and blood vessels grow from the periosteum. It grows inside and engulf the calcified matrix surrounding the primary areolae. It is due to the erosion of the walls of the primary areolae by the osteoclast, the smaller primary areolae get converted into larger secondary areolae. The plates of the calcified cartilage bounding the secondary areolae get lined by the osteoblast. Osteoblast lay down osteoid tissue which is made of ossein fibres + gelatin matrix. After calcification of the osteoid tissue, the bony lamellus is formed. Number of lamellae are piled on the top of each other. Osteoblast caught in between the lamillae becomes the osteocyte. This leads to the formation of bony trabeculae

Development of Long Bone (Fig. 4.7)

At first let us see the definition of ossification. Ossification is the process of deposition of calcium in the osteoid tissue. It begins in the middle of the long bone forming primary center of ossification which forms the diaphysis. When the center of ossification appears at the ends of the bone, the part of the long bone formed by the secondary center of ossification is known as the epiphysis. At the same time, layer on the surface of the cartilage model forms the perichondrium. With the bone formation the perichondrium is called as periosteum. The process of formation of the bone by the osteogenic cells of the periosteum is known as intramembraneous ossification. This forms the periosteal collar around the cartilaginous model of the long bone. Periosteal collar provides strength to the cartilage bone particularly at the zones weakened by formation of secondary areolae. Periosteal collar extends towards both ends of the bone. The process of addition of new bone by the osteoblast on the periphery and the depletion of the bone by the osteoclasts from inside, keeps formation of the bone under control. As a result the cartilage bone is completely replaced by the membrane bone added from the periphery by the osteoblasts. It can be inferred that the major portion of the long bone is formed by the membrane bone. Plate of cartilage separating the epiphysis and the diaphysis is called the epiphyseal plate, which plays an important role in growth of the bone. Trabeculae in the center of the bone are removed by the osteoclasts forming the marrow cavity. The epiphyseal plate is not encroached by the marrow cavity.

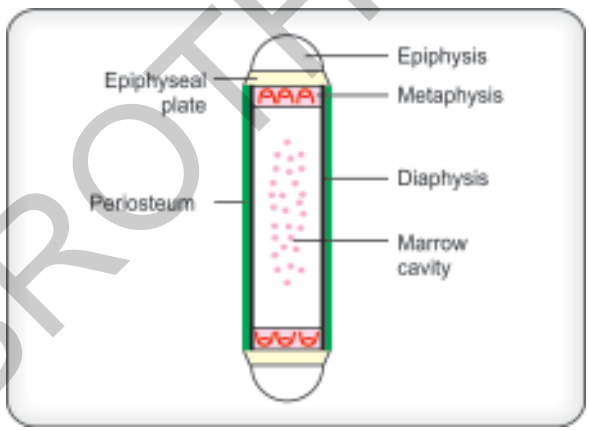

Fig. 4.7: Parts of the developing long bone

The Epiphyseal Plate has Three Zones

1. Zone of resting cartilage
2. Zone of proliferating cartilage
3. Zone of calcifying cartilage

JAYPEE BROTHERS

The zone of calcifying cartilage is followed by the zone of bone formation. The conversion of epiphyseal cartilage into bone helps in increasing the length of the bone.

Metaphysis (Figs 4.7 to 4.9)

Metaphysis is the part of the diaphysis in close proximity of the epiphyseal plate. Important factors regarding the metaphysis are as under:

1. Metaphysis is more vascular where the blood vessels form the hairpin bends. Due to the formation of hairpin bends, blood flow slows enabling the organisms (staphyloccoci) to settle in the metaphysis leading to the condition of acute osteomyelitis.
2. The zone is susceptible to infections.
3. It has high calcium turnover after completion of the bone growth.

When growth occurs through cell multiplication and adding of the intercellular substance it is called interstitial growth. As the growth occurs in all the directions the original shape of the bone remains unchanged. When the growth of the bone is by deposition of bone on the surface it is known as oppositional growth.

Process of removing the redundant bone is called modeling which maintains the shape of the bone. Trabeculae are formed and get organized as per the needs of weight transmission and weight bearing. It is called the internal modeling.

Anomalies of Bones

Molecular biology and genetics have succefully found the role of fibroblast growth factor (FGF) and fibroblast growth factor recepter (FGFR) in producing skeletal dysplasias. Nine members of the FGF and four (4) receptors regulate the cellular proliferation, differentiation and migration.

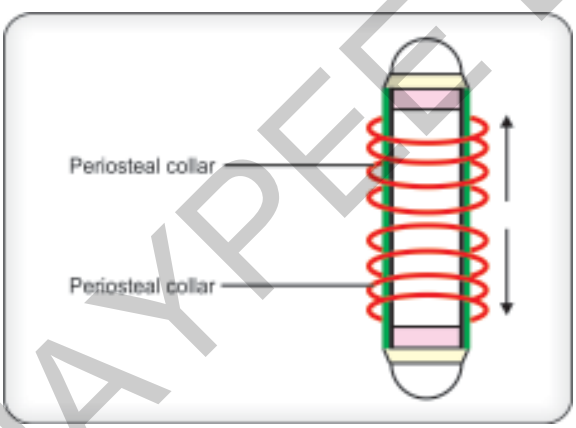

Fig. 4.8: Formation and growth of periosteal collar progressing towards the ends of the long bone

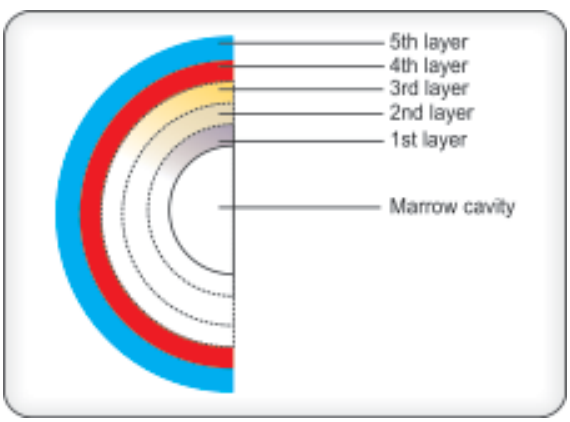

Fig. 4.9: Development of long bone

Note that 1st, 2nd and the 3rd layers have disappeared. The 4th and 5th layers are newly added remain. Addition from out and depletion from in keeps the bony mass relatively static in spite of addition of the layers. Thus preventing ugly and extrabone formation

JAYPEE BROTHERS

Achondroplasia: Due to the defective bone formation of the epiphyseal plate the growth of the long bone is affected and the individual becomes a dwarf.

Cleidocranial dysostosis: In this condition, there is defective formation of the membrane bones leading to deformed vault of the skull and the absence of the clavicles.

Osteogensis imperfecta: Due to abnormality of collagen I, there is deficient bony matrix leading to fragility and short strature. The condition is marked with multiple repeated fractures.

Marble bone disease: Fragility and density (Osteopetrosis) of the bone is increased with sclerosis which is classically described as *bone within the bone*. The condition is associated with cardiovascular, ophthalmic, skeletal and the soft tissue defects.

Multiple epiphyseal dysplasia: Patients suffer from joint pains, and waddling gait.

Diatropic dysplasia: The condition is marked by short stature and typical thumb deformity (Hitchhiker's thumb).

Development of Striated Muscle (Figs 4.10 and 4.11)

The voluntary muscles of the body wall develop from the paraxial mesoderm which is the medial most column of the intraembryonic mesoderm. Each somite has three parts.

- Sclerotome
- Dermatome
- Myotome

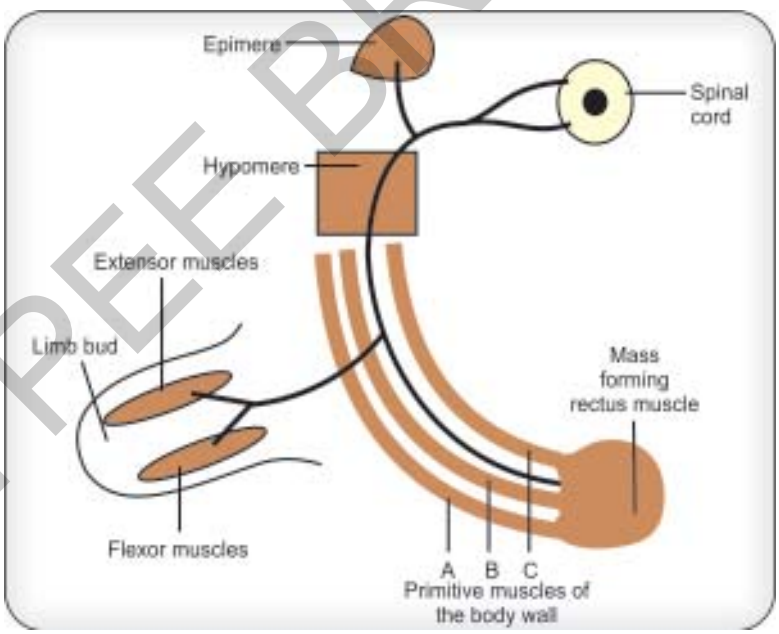

Fig. 4.10: Skeletal muscles of the body wall and the limb

JAYPEE BROTHERS

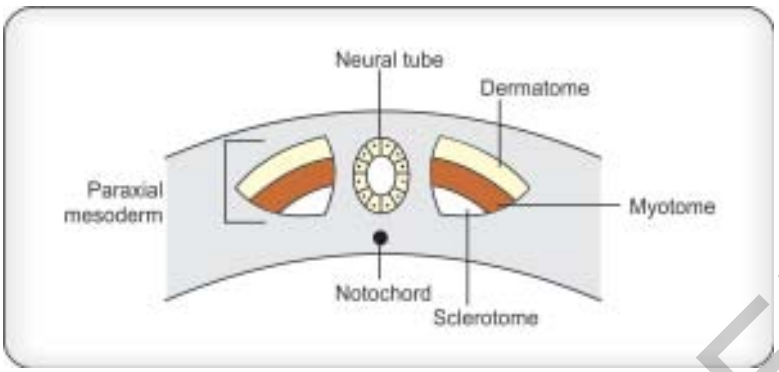

Fig. 4.11: Parts of the paraxial mesoderm

Sclerotome

It migrates medially towards the notochord and the nural tube and contributes to the formation of the vertebral column.

Dermatome

It forms the skin of the back and the subcutaneous tissue.

Myotome

It gets segmented and form the myotomes having cavity in the middle known as mycele.

Occipital myotomes give rise to the muscles of the tongue which are supplied by the 12th cranial nerve. Preoccipital myotomes form the muscles of the eyeball which are supplied by the 3rd, 4th and the 6th cranial nerves. Each myotome of the cervical and thoracic region divides into two forming the epimere and the hypomere. The muscles of the epimere are supplied by dorsal primary ramus of the spinal nerve. Muscles of the hypomere are supplied by the ventral ramus of the spinal nerves. Epimeres forms the extensor muscles of the back, while the hypomeres give rise to the muscles of the body wall and the limbs. Epimere forms two muscular columns, the lateral and the medial. The lateral column forms the longissimus and the iliocostalis muscles and the medial column forms spinalis, semispinalis capitis and multifidus muscles. The hypomere forms the transversus abdominis, internal oblique and the external oblique muscles of the body wall. The ventral extensions of the muscles fuse infront of the anterior abdominal wall forming the rectus abdominis muscle. Similarly, sternalis muscle is seen at times infront of the thorax. In addition to it, the hypomeres also form the extensors and the flexors of the limb.

Development of Smooth Muscle

Smooth muscles of the viscera come from the splanchnopleuric mesoderm such as that of stomach and intestine. It must be remembered that the muscles of the iris, i.e. sphincter and dialator pupillae and the myoepithelial cells of the sweat glands are ectodermal in origin.

JAYPEE BROTHERS

Cardiac Muscle

It develops from the myoepithelial mantle of the splanchnopleuric mesoderm of the pericardium. Each muscle cell gives number of branches which join each other. Each muscle cell elongates and comes into contact with the adjacent muscle cell. However, their cell membranes remain intact. The junctional zone of the cell membranes forms the intercalated disk. Myofibrills appear within the cells which give striated appearance to the cardiac muscle.

In brief the microscopic appearance of the cardiac muscle can be described as under:

Short, branched, striated with central nucleus and the intercalated disk.

Intercalated disk contains inter cellular junctions for electrical and mechanical linkage of cotinguous cells.

Development of the Neurones (Fig. 4.12)

It has already been seen that the neural tube has three layers namely the ependymal, mantle and the marginal from inside out. Essentially, the ependymal layer forms the ependymal lining of the ventricles and the central canal of the spinal cord.

The fate of the ependymal cells is as under:

Ependymal cells go to the mantle layer and form apolar neuroblast.

The cell develops processes on both sides and becomes bipolar neuroblast.

One process disappears and the neuroblast becomes unipolar.

Only one process elongates to form axon while other processes form the dendrites, forming the multipolar neuroblast.

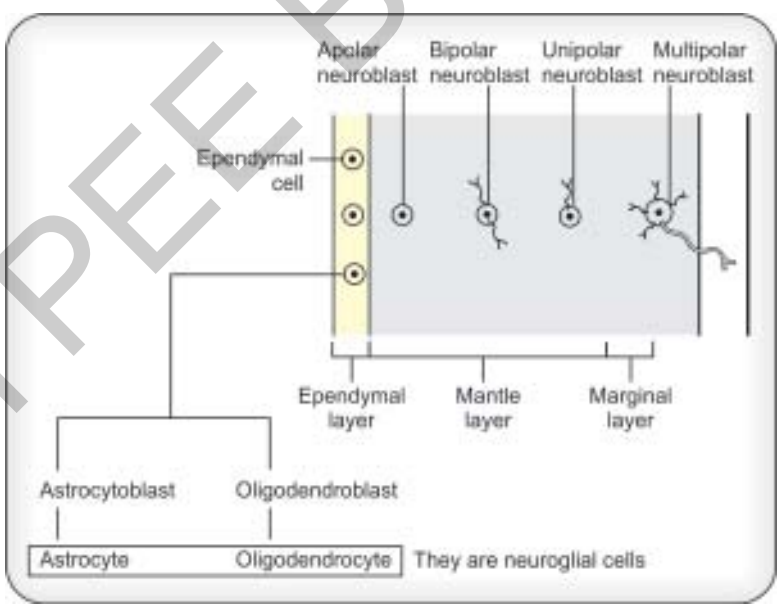

Fig. 4.12: Histogenesis of spinal cord

JAYPEE BROTHERS

Spongioblast (Fig. 4.12)

Spongioblasts form astrocytes and the oligodendrocytes. Some of the ependymal cells migrate to the mantle and the marginal layers to form the astroblasts which get converted into astrocyte. Some of the ependymal cells migrate to the mantle and the marginal layers and form oligodendroblasts which get converted into the oligodendrocytes. Oligodendrocytes get lined on either side of the nerve fiber and the tracts in the marginal layer. They form the myelin sheath for the nerve fibers of the central nervous system. Due to the myelination of the tracts, the area of the tracts look white. Axons of the multipolar neurones enter the marginal layer to form the tracts. Appearance of the Nissl's granules or bodies makes the neuron incapable of further divisions. The microglia arise from the mesoderm and not from the neuroectoderm.

The neuroblasts as well as the neuroglia come from the ependymal cells arising from neuroectoderm.

Formation of Myelin Sheath (Figs 4.13 and 4.14)

Nerve fibers within the brain, spinal cord and the peripheral nervous system are provided with a sheath from the neuroglial cells. The nerve fibres outside the central nerovous system are provided with a sheath called the neurolemma. Neural crest gives rise to the Schwann cells. The covering which develops on the inner side of the neurolemma is called myelin sheath. Schwann cells give rise to the myelin sheath of the peripheral nerves while the myeline sheath for the nerves in the central nervous system comes from oligodendrocytes of due to the absence of the Schwann cells in

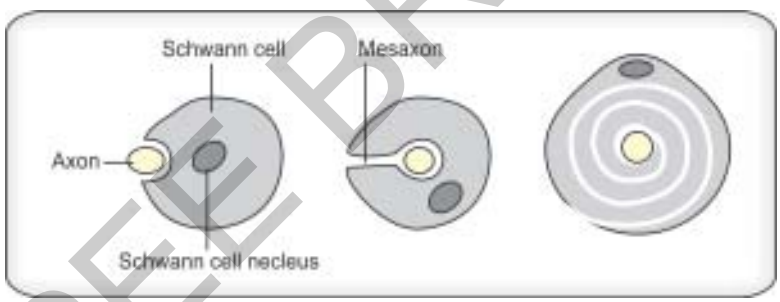

Fig. 4.13: Formation of myelin sheath

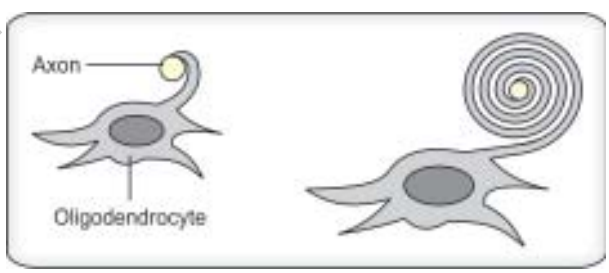

Fig. 4.14: Myelination of nerve fiber in the central nervous system by an oligodendrocyte

JAYPEE BROTHERS

the central nervous system. Axon invaginates the Schwann cell forming the double layered mesoaxon. It is due to elongation and the rotation of the mesoaxon, typical myelin sheath is formed. The myelination of the nerve fibers of the central nervous system begins in the 4th month of the intrauterine period and is not complete upto 2 to 3 years of the life. It is well known clinically that the extensor response of the great toe becomes flexor only after the completion of myelination of the nerves in the central nervous system. In cases of the head injury normal flexor response of the great toe becomes extensor (Babinki's sign or reflex) in case of damage to the upper motor neurons (Damage to the pyramidal tract).

Blood vessels of the brain are mesodermal in origin. It is believed that the pia and the arachnoid mater of the brain and the spinal cord arise from the neural crest. However, the dura mater comes from the mesoderm.

Clinical

There is dorsiflexion of the great toe instead of plantar when the lateral aspect of the sole of the foot is stroked. It is known as Babinski's sign or reflex.

JAYPEE BROTHERS

Kadasne's TEXTBOOK OF EMBRYOLOGY

Salient Features

- A concise yet comprehensive text
- Presents the text in a lucid and diligent manner
- Covers all the aspects of human embryology
- Includes excellent, linear and reproducible diagrams and clinical photographs
- Useful for the UG and PG students as well as teachers of Anatomy, Physiology and Embryology; practising gynecologists, pediatricians, cardiovascular and ophthalmic surgeons, radiologists, etc.

DK Kadasne was born on 22nd April, 1932 at Wahi in district of Yeotmal, Maharashtra, India. He obtained his MBBS and MS degrees in Anatomy from the Government Medical College, Nagpur. During his preclinical days, he was a merit scholar. He worked in Government Medical College, Nagpur as Lecturer and Reader of Anatomy. His crowded lecture hall is the proof of his able and excellent teachership. In the United Kingdom, he worked under Professor GJ Romanes in Medical School at Edinburgh.

He did his FRCS in General Surgery from the Royal College of Surgeons at Edinburgh in 1968. He is also a Fellow of the International College of Surgeons of the USA (FICS). He was appointed as Professor designate of Anatomy in the BJ Medical College, Pune; however, he preferred to join as Civil Surgeon and had his successful tenure in four districts of Maharashtra including Nagpur.

In the Mayo General Hospital and Indira Gandhi Medical College, Nagpur, he was In-charge of a surgical unit and was a guide for MS (Surgery) under Nagpur University. After retirement, he joined Pandit Jawaharlal Nehru Medical College at Sawangi, Wardha and worked as a Visiting Professor of Anatomy for the period of 10 years. Recently, he has been conferred with the title of Emeritus Professor of Anatomy at Datta Meghe Institute of Medical Sciences, Sawangi, Wardha (a Deemed University). He is a qualified anatomist and practising surgeon which is in itself a rare combination for authorship of the book on anatomy with clinical applications.

Available at all medical book stores
or buy directly from Jaypee Brothers through online shopping at www.jaypeebrothers.com

or call + 91-11-32558559

JAYPEE BROTHERS
Medical Publishers (P) Ltd.
www.jaypeebrothers.com

ISBN 978-93-5025-152-2