MEDICINE *for* YOGA THERAPISTS



Padiki Nagaraja Rao

Foreword
R Nagarathna

JAYPEE

Contents

1. General Information 1
Anatomy 1
Physiology 1
Pathology 1
Cell 2
Tissue 5
Membranes 8
Anatomical descriptive terms 9
Philosophical background 11

2. Cardiovascular System 13
Heart 13
Cardiac cycle 17
Blood vessels 18

3. Blood 24
Functions of blood 25
Blood groups 26
White blood cells 26
Blood vessel and cell relationship 27
Lymphatic system 28
Pulse 29
Blood pressure 29

4. Clinical Conditions Related to Vascular System 31
Ischemic heart disease 31
Hypertension 33
Stress 35
Aneurysm 36
Peripheral vascular disease (PVD) 36
Venous obstruction 37
Varicose veins 37
Philosophical background 38

5. The Respiratory System 40
Thoracic cavity 40
Classification of respiratory system 41
Nose 42
Pharynx 44
Larynx 44
Trachea 45
Bronchi 46
Lungs 46
Pleura 47
Muscles of respiration 48
Respiration 49

6. Clinical Conditions Related to Respiratory System 51
Sinus infection 51
Sore throat 51
Laryngitis 51
Bronchitis 52
Bronchiectasis 52
Lung diseases 52
Pneumothorax 53
Emphysema 53
Bronchial asthma 54
Philosophical background 55

7. The Digestive System 57
Oral cavity 57
The esophagus 61
Stomach 62
Small intestine 62
Large intestine 64
Liver (L—Hepar) 64
Pancreas 66

8. Foods We Eat 69
Carbohydrates 69
Fats 70
Proteins 72
Vitamins and others 74

9. Clinical Conditions Related to Digestive System 75
Insufficient food intake and defective absorption 75
Obesity 75
Medical terminologies 76
Gastritis 77
Peptic ulcer 77
Inflammatory bowel disease (IBD) 78
Pruritus 78
Hemorrhoids 78
Functional bowel syndrome 79
Volvulus 79
Intussusception 79
Diseases of pancreas 79
Diseases of liver 79
Jaundice 80
Philosophical background 81

10. Organs of Special/Ordinary Senses 84
Skin 84
Nose 86
Tongue 86
Ear 86
Eye 89
Philosophical background 91

11. The Endocrine System 94
Pituitary gland (Hypophysis) 95
Thyroid gland 97
Parathyroid glands 99
Thymus gland and defence mechanism 99
Adrenal glands 101
Pineal body 103
Pancreas and diabetes 103
Philosophical background 104

12. The Reproductive System 106
Abdominal cavity 106
The male reproductive system 108
Female reproductive system 111

Puberty 113
Menopause 113
Some of the common clinical condition related to reproductive system 114
Polycystic ovary syndrome 114
Philosophical background 114

13. The Urinary System 116
Kidney 117
Ureter 119
Urinary bladder 120
Urethra 120
Micturition 120
Some of the clinical condition related to urinary system 121
Philosophical background 123

14. The Nervous System 125
Nerve cells (Neurons) 126
Neuroglia 129
The meninges 129
Cerebrospinal fluid (CFS) 130
The brain 131
Basal ganglia 135
Thalamus 136
Hypothalamus 137
Midbrain 137
Pons 137
Medulla oblongata 137
Cerebellum 138
Reticular formation 139
Limbic system 139
Special areas of cortex 140
Spinal cord 140
Autonomic nervous system 143
Spinal nerves 145
Some of upper extremity nerves, the muscles supplied by them and the effect of nerve injury 146
Lower extremity nerves, the muscles innervated by them and effect of nerve injury 151
Cranial nerves 155

15. Clinical Conditions Related to the Nervous System 158
Peripheral neuropathy 158
Guillain–Barré syndrome 159
Hemiplegia 159
Blood Supply to the brain 159
Parkinsonism 166
Cerebral palsy (CP) 169
Multiple sclerosis 171
Incoordination 173
Frederick's ataxia 173
Syringomyelia 173
Amyotrophic lateral sclerosis 174
Poliomyelitis 174
Spinal cords injuries 179

16. Psychiatry 182
Psychosis 182
Neurosis 184
Personality disorders 184
Mood disorders 185
Philosophical background 185

17. Myology 189
Clinical conditions affecting muscles 195
Myotonic dystrophy 197
Myositis 198
Myasthenia gravis 198
Myositis ossificans 198
Metabolic myopathy 199
Volkmann's ischemic contracture 199
Philosophical background 199

18. The Skeletal System 201
Bone 201
Cartilage 202
Joints 203
Head 205
Upper extremity 206
Lower extremity 211
Back 216

Arthritis 224
Fractures 226
Philosophical background 227

19. Philosophical Background 228

Index 235

.

2 Cardiovascular System

In this chapter, we will discuss the heart, blood vessels and the lymphatic system. The circulatory system makes sure that the blood reaches each and every part of the body so that every cell gets required nutrition, oxygen and gets the waste products removed. Substances like hormones and antibodies are carried to different parts of the body through blood. Circulatory system also helps in the regulation of body temperature.

HEART (FIGS 2.1A and B)

This is a muscular organ situated in the thoracic cavity. It occupies a larger part of mediastinum (the space between two lungs). In addition to the heart, mediastinum contains esophagus, trachea, thymus and the great vessels. The apex of the heart is situated in the left fifth intercostal space, about nine centimeter (9 cm) from the midline. The heart measures the size of the fist of the individual and weighs about 300 gm. Sternum is situated anterior to the heart, while the trachea and esophagus are posterior to it.

The heart has three layers. The outer layer is pericardium, the inner layer is the endocardium and the middle layer is muscular tissue. The pericardium consists of an outer fibrous layer and an inner double walled layer with serous membrane. The outer fibrous layer is attached to the diaphragm. It also continues with the outer coverings of great vessels. Between the two layers of the serous membrane, there is a small amount of serous fluid.

The inner endothelial layer (endocardium) consists of flat epithelial cells, which provide a smooth surface to the interior of the heart. The middle layer, which is made up of muscle tissue is

JAYPEE BROTHERS

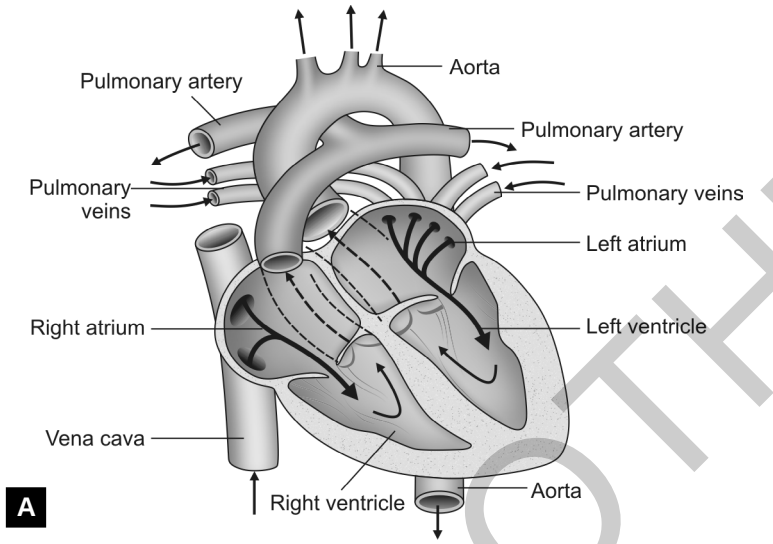

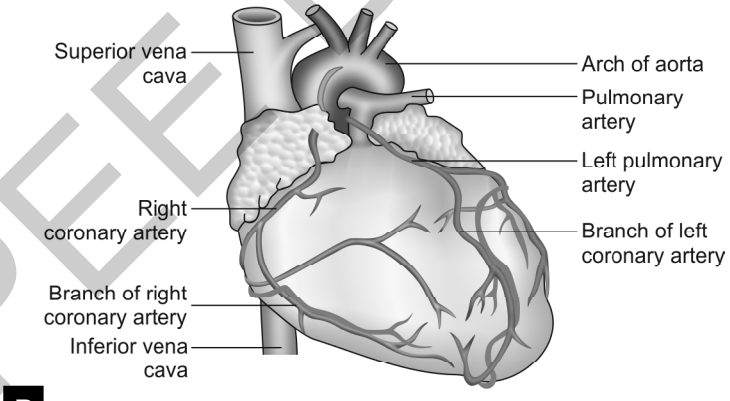

Figs 2.1A and B: Heart

JAYPEE BROTHERS

thick. In the ventricles, particularly in the left, the muscle mass is more.

While discussing 'tissue', earlier in this book, muscle was mentioned as one of the main tissues. A muscle cell is capable of contraction and relaxation depending upon external stimuli, which may be mechanical, chemical or electrical. Muscle fibers are classified into three types–skeletal, visceral and cardiac. The skeletal muscle fibers are voluntary and give a striated appearance under microscope. The visceral muscle fibers are involuntary and are not striated. The cardiac muscle fibers present striated appearance but are involuntary. The cardiac muscle fibers branch so that the adjacent fibers are in close continuity with each other and the junction between the muscle fibers is known as 'intercalated disks'. This type of arrangement helps in smooth coordinated cardiac muscle contraction.

The interior of the heart is divided into right and left halves by a septum. Each half of the heart is further divided into upper and lower chambers. The upper chambers are called atria (left atrium and right atrium) and the lower chambers are left and right ventricles.

The right atrium receives blood from three sources: (a) The superior vena cava, which drains the head, neck and upper extremities (b) The coronary sinus which collects blood from cardiac musculature and (c) The inferior vena cava, which brings blood from the rest of the body. The right atrium pumps blood into the right ventricle. The opening between the right atrium and the right ventricle is guarded by a tricuspid (consisting of three cusps) valve. This valve allows the blood flow only from the atrium into the ventricle. When the right ventricle contracts, the valve closes so that the blood cannot go into the right atrium again. When the right ventricle contracts, blood enters the pulmonary artery. The blood in the pulmonary artery is deoxygenated. The opening of the pulmonary artery is also guarded by a tricuspid valve. This valve makes sure that the blood flows only from the right ventricle into the pulmonary artery but not in reverse direction. In the lungs, the blood gets oxygenated and then returns to the left atrium. When the left atrium contracts, it pumps the blood into left ventricle. There is a bicuspid valve (valve with two cusps) between left atrium and left ventricle. This valve is also known as mitral valve. Blood can only flow from the left atrium

JAYPEE BROTHERS

into the left ventricle. When the left ventricle contracts, blood enters the aorta. Even the opening of the aorta is provided with a tricuspid valve, which makes sure that the blood cannot get back into the left ventricle. The aorta carries the oxygenated blood to various parts of the body. The venous blood from different parts of the body is returned to the right atrium by the superior vena cava and inferior vena cava.

The blood flow from the heart to the lungs and return of blood from the lungs to left atrium is called 'pulmonary circulation'. The blood circulation from the left ventricle to various parts of the body and its return to the right atrium constitutes 'systemic circulation'.

Heart gets its blood supply from a pair of coronary arteries—left and right. Aorta gives off these vessels just distal to the aortic valve. It is estimated that about 5 percent of the blood coming out of the left ventricle enters the coronary arteries, making sure that the heart has a good amount of blood supply to cope up with its constant activity. The left coronary artery branches into anterior interventricular and circumflex arteries. The right coronary artery divides into posterior interventricular and transverse branches. These coronary arteries make a big network of smaller vessels. The venous blood from the heart is collected by the 'coronary sinus', which empties, directly into the right atrium.

Nerve supply: Nerve supply to the heart is from both sympathetic and parasympathetics. The vagus nerve is parasympathetic. The parasympathetics cause slowing of the heart rate while the sympathetics increases the heart rate. The medulla oblongata of the brain contains 'vasomotor center', which regulates the heart rate through its connection with the autonomic nervous system.

Electrical activity: The heart muscle fibers have an inherent contractile power. They can contract and relax on their own without any external stimulus. This property of the cardiac muscle fibers is known as 'Autorhythmicity'. However, for a smooth and coordinated contraction of the heart, there is a well-organized mechanism in the heart. In certain places in the heart, where the impulse generation and conduction is the main function, the muscle fibers are specialized and are referred to as neuromuscular cells. They form a conducting system in the heart, which consists of sinoatrial (SA) node, internodal pathway, atrioventricular (AV) node, atrioventricular bundle and Purkinje system.

JAYPEE BROTHERS

SA node is also called the 'pacemaker'. When the SA node starts a stimulus, it spreads all over the heart and all the muscle fibers respond to this stimulus rather than all of them contracting by themselves. SA node is situated in the right atrium at the opening of superior vena cava. AV node is situated at the level of atrioventricular valve. AV node is capable of acting as a pacemaker, if the SA node becomes defective. Normally, the impulse originating at SA node is much faster than AV node. AV node continues as bundle of 'His' which further divides into left and right bundle branches and continues to divide into smaller branches called 'Purkinje fibers'.

The electrical impulse takes about 0.1 of a second to travel through ventricles. This delay allows the atria to contract first and only then the ventricles contract. The passage of electrical current in the heart can be recorded by electrocardiography (ECG). Normally, the ECG shows five waves, which are labeled as PQRST. The 'P' wave represents the electrical impulse in the atria. 'QRS' waves show the electrical activity from the AV node to the Purkinje fibers. 'T' wave represents relaxation of ventricles.

CARDIAC CYCLE (FIGS 2.2A and B)

When the heart contracts, blood is pumped out and when it relaxes, blood enters in. When atria relax, the right atrium receives blood from superior vena cava, inferior vena cava and coronary sinus; the left atrium receives blood from pulmonary vein. When the atria contract, the blood enters their respective ventricles. When

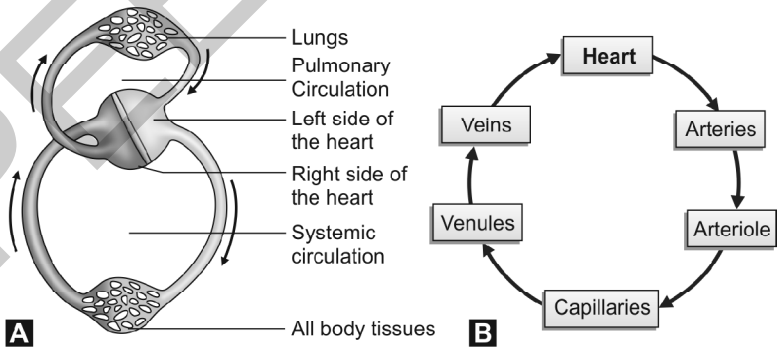

Figs 2.2A and B: Systemic and pulmonary circulations

JAYPEE BROTHERS

the ventricles contract, blood from right ventricle enters pulmonary artery and the blood from the left ventricle enters the aorta. Contraction of the heart is called 'systole' and relaxation is called 'diastole'. The heart beats about 70 times a minute (normal 60 to 80). As the heart musculature are contracting and relaxing, the valves between the atria and ventricles and those at the root of aorta and pulmonary arteries open and close to allow blood flow in one direction. Closures of these valves produce sounds, which can be heard through a stethoscope. Closure of atrioventricular valves produce the first heart sound, which is dull and is of long duration. It sounds like 'Lubb'. The second sound is produced when the aortic and pulmonary valves close. This sound is of short duration and sounds like 'Dubb'.

In addition to these two heart sounds, sometimes we may hear some abnormal sounds. They are called 'murmurs'. They are produced either because of structural or physiological abnormalities. Murmurs may be heard during conditions like anemia, fever, thyrotoxicosis and pregnancy. When there are structural changes in the heart like valvular diseases, shunts and narrowing of vessels, murmurs are heard. Some of the conditions frequently seen include mitral valve stenosis, pulmonary valve stenosis and atrial septal defect.

The term 'stroke volume' refers to the amount of blood pumped out by the ventricle each time it contracts. The 'heart rate' refers to the number of heart beats in a minute. Normally, about 70 ml of blood is pumped out of each ventricle with each beat. Cardiac output is the product of stroke volume and heart rate, which is (70 x 70) approximately 5 liter.

BLOOD VESSELS

There are two types of blood vessels in the body. The vessels, which carry blood from the heart to other organs, are called arteries and the vessels, which bring blood to the heart, are called veins.

Arteries

Arteries carry oxygenated blood from the heart to various organs. Their wall has three layers. Tunica adventitia is the outer fibrous layer. The middle layer is made up of smooth muscle fibres. Inner layer is an epithelial layer, which is called tunica intima or endothelium.

JAYPEE BROTHERS

Even the blood vessel has to receive its blood supply. Small arterial branches called 'vasa vasorum' supply blood to the blood vessels. Thin arteries can get oxygen and nutrients directly from the blood in them. The blood vessels are supplied by autonomic nervous system, mainly the sympathetics. The sympathetic nerve stimulation causes the blood vessels to contract (vasoconstriction). When sympathetic activity is reduced, the vessels dilate resulting in increased blood supply to the area which they supply. Vasodilatation can also occur after exercises, inflammatory conditions or due to local chemicals like histamine.

The arteries make connection with other arteries at various levels through small connecting arteries. This phenomenon is known as 'Anastomosis'. This arrangement makes sure that the circulation remains intact, even if one of the arteries is blocked.

The major arteries divide into smaller ones, which further divide into still smaller vessels called 'arterioles'. The terminal part of these arterial branches is made up of `capillaries`. The capillary walls contain only the endothelial layer along with a thin basement membrane. The arteries, which are beyond the anastomosis link, are called 'end arteries'. If these end arteries get blocked, the tissues supplied by them die.

Aorta

Aorta is the largest artery in the body. It arises from the left ventricle. From its origin, it initially ascends, then arches and finally descends behind the heart. After passing through thorax (thoracic aorta), it enters the abdominal cavity by passing behind the diaphragm at the level of 12th thoracic vertebra. In the abdomen, at the level of 4th lumbar vertebra, it divides into right and left common iliac arteries.

The branches of the aorta in the thorax include:

- Coronary arteries
- Brachiocephalic artery
- Left common carotid artery
- Left subclavian artery
- Branches to bronchi, esophagus and intercostal arteries.

The brachiocephalic artery divides into right common carotid and right subclavian arteries.

Subclavian artery: There are two subclavian arteries, one on the right side and the other on the left side. This artery passes behind

JAYPEE BROTHERS

the clavicle and enters the axila to continue as 'axillary artery'. Subclavian artery gives off internal thoracic and vertebral arteries. Internal thoracic supplies the thorax. The vertebral artery ascends and enters the skull through the foramen magnum. In the neck, this artery passes through the openings in the transverse processes of the cervical vertebrae. After entering into the skull, both the vertebral arteries unite to from basilar artery. The basilar artery divides into two posterior cerebral arteries.

The axillary artery continues into the arm, where it is called 'brachial artery'. The brachial artery passes distally and just below the elbow, it divides into radial and ulnar arteries. The brachial artery at the elbow level is used to record blood pressure.

Radial artery runs on the radial side of the forearm. At the wrist level, it is palpable. The ulnar artery is placed on the ulnar side of the forearm. The radial and the ulnar arteries anastomose in the palm and supply the hand and fingers.

Common carotid artery: The right common carotid artery is a branch of the brachiocephalic artery. The left common carotid artery arises directly from the aortic arch. The common carotid divides into external carotid and internal carotid arteries at the level of the upper border of the thyroid cartilage. At this level, the common carotid artery is slightly enlarged and has a thin wall. This enlarged part consists of two types of receptors and is supplied by the glossopharyngeal nerve. One set of receptors are known as 'baroreceptors'. They are sensitive to the changes in the blood pressure. They carry the impulse to the vasomotor center in the medulla oblongata, which helps to regulate the blood pressure. The enlarged part of the common carotid artery, which is also called carotid sinus, also contains a second set of receptors known as 'chemoreceptors'. They are sensitive to the chemical changes in the blood (carbon dioxide and oxygen levels of the blood). Increased CO_2 causes blood pH to fall. They carry information to the respiratory center in the medulla oblongata, which helps to regulate respiration and correct the pH of blood.

External carotid artery supplies the outer part of the head, thyroid gland, tongue and the face. One of the branches of the external carotid, the middle meningeal artery enters the skull.

Internal carotid is the main artery of the brain. It enters the skull through carotid foramen in the temporal bone. The two

JAYPEE BROTHERS

internal carotid arteries with the vertebral arteries form an anastomosis called 'Circle of Willis'.

Abdominal aorta is a continuation of the thoracic aorta. The aorta divides at the level of 4th lumbar vertebra. The main branches of the abdominal aorta are:

- *Inferior phrenic arteries (paired):* They supply diaphragm.
- *Coeliac artery (unpaired):* It further divides into left gastric, splenic and hepatic arteries. They supply stomach, spleen, pancreas, liver and gallbladder.
- *Superior mesenteric (unpaired):* Supplies small intestine and proximal half of large intestine.
- *Renal arteries (paired):* Supply the kidneys.
- *Gonadal (paired) (testicular or ovarian):* They supply the testicles in men and ovaries in women.
- *Inferior mesenteric (unpaired):* It supplies distal half of large intestine.The terminal branches of the aorta are the two common iliac arteries. Each artery divides into external and internal iliac arteries. The internal iliac supplies the structure within the pelvis.

The external iliac artery continues as the femoral artery in the thigh. The femoral artery can be felt at a point just distal to the midpoint of the inguinal ligament. The femoral artery passes on the anterior and medial side of the thigh and enters the backside of the thigh to become popliteal artery. In the distal part of the popliteal fossa, the artery divides into anterior tibial artery and posterior tibial artery. Anterior tibial artery descends between tibia and fibula, runs in front of the ankle to enter the dorsal part of the foot to become the dorsalis pedis artery.

The posterior tibial artery gives off peroneal artery, which supplies lateral side of the leg. The posterior tibial artery, after supplying the posterior aspect of the leg, enters the plantar aspect of the foot, by running between the heel and the medial malleolus and becomes plantar artery. The posterior tibial artery can be felt easily at the ankle level. Dorsalis pedis pulse is also palpable. In the foot, there is an anastomosis between the plantar artery and the dorsalis pedis artery.

Veins

The blood returns to the heart from various parts of the body through veins. The walls of the veins also have three layers like

JAYPEE BROTHERS

arteries, but their walls are very thin compared to the arteries. When an artery is cut, the lumen can be seen but when a vein is cut, the walls collapse causing the lumen to close. The blood pressure is also low in veins. The blood rushes out of a cut artery while the blood just flows out through the cut end of a vein. As the blood flows slowly in veins, there is a tendency for the blood to stagnate in them. The blood flows only in the direction of the heart and its flow in reverse direction is prevented by the presence of valves in the veins.

The capillaries continue as venules. The venules continue as veins. There are two types of veins—superficial and deep type. The deep veins follow the route taken by the arteries. The superficial and deep veins communicate with each other at various levels.

From the head and neck, blood is collected by external jugular and internal jugular veins. The blood from outside of the skull is collected by external jugular vein, which joins the subclavian vein. Various venous sinuses collect the blood from inside of the skull. A venous sinus is nothing but a folding of dura mater lined by endothelium. There are many venous sinuses like, superior sagittal, inferior sagittal, straight, transverse and sigmoid sinuses. The blood from these sinuses reaches the internal jugular vein, which in turn joins the subclavian vein to form the brachiocephalic vein. The left and the right brachiocephalic veins join to form the superior vena cava, which opens into the right atrium.

From the upper extremity, ulnar and radial veins collect the blood. They join and continue as brachial vein, and then as axillary vein and finally as subclavian vein. There are many superficial veins in the upper extremity. Among the major superficial veins, prominent ones are: Cephalic vein, basilic vein, median vein and the median cubital vein. The median vein collects the blood from the palm whereas the basilic vein collects blood from the medial aspect of the dorsum of the hand. Basilic vein joins the axillary vein. The cephalic vein also joins the axillary vein.

The lower extremities also have superficial and deep veins. Among the superficial veins, the long (great) and the short saphenous veins are more prominent. Long saphenous vein starts from the medial aspect of the dorsum of the foot. It runs upward on the medial side of leg and the thigh and empties into the femoral vein. The short saphenous vein runs on the posterior aspect of the leg and joins the popliteal vein.

JAYPEE BROTHERS

The femoral vein continues as the external iliac vein, which joins the internal iliac vein to form common iliac vein. The left and the right common iliac veins unite to form inferior vena cava, which enters the thoracic cavity by passing through the central tendon of the diaphragm. The inferior vena cava ends in the left atrium.

Portal circulation: Earlier in this chapter, systemic and pulmonary circulations have been discussed. In addition to these two, there is one more circulation called 'portal circulation'. In the abdomen, aorta gives off coeliac artery, which divides into left gastric, splenic and hepatic arteries. The hepatic artery enters the liver and supplies liver and gallbladder mainly. The liver is also supplied by portal vein. Portal vein is formed by splenic vein (which gets blood from spleen, pancreas, superior mesenteric and inferior mesenteric veins), gastric vein and cystic vein (from the gall bladder). Both hepatic artery and the portal veins branch freely in the liver. The blood leaving the liver is collected by the hepatic veins which drain into the inferior vena cava. This circulation in the liver is known as 'portal circulation'.

JAYPEE BROTHERS

Medicine *for* Yoga Therapists

Salient Features

- A simple and concise text
- Presents systemic anatomy and physiology of human body as a part of curricula for different yoga courses
- Focuses on various body ailments, clinical conditions, and their yogic treatment
- Explains how mind and body are connected to each other and form the basis of holistic approach to healing
- Includes at the end of each chapter *adhyatma vidya* (knowledge about self), a brief discussion on philosophy
- Useful for all students of yoga and yoga therapists, diploma and undergraduate students of medicine, and all those who have keen interest in the study of yoga.



Padiki Nagaraja Rao is a medical graduate with MBBS degree from Bengaluru University. After obtaining the degree in 1965, he went to New York city in USA to do his postgraduation in physical medicine and rehabilitation. He served as a resident, chief resident and as a fellow at the famous Kings Brook Jewish Medical Center and obtained his Certificate of Diplomat of "The American Board of Physical Medicine and Rehabilitation" in 1973.

After this, he served as a Chief of Prosthetic and Orthotic Center in the same hospital. He also served as Director of rehabilitation services at Unity Hospital, Green Point Hospital, Wood Hull Hospital, Interfaith Hospital in New York.

He returned to India in 1981. He served at the Accident Care Hospital, Bengaluru as a Professor. At present, he is working at the Yoga University in Jigini, Bengaluru as a Professor and Chief Medical Officer.

He has been interested in Philosophy. He has written three books in Kannada language on philosophy and yoga. His latest book in English called *Knowing the Unknown* has become popular worldwide.

His knowledge in both medical science and ancient scriptures has made him to write this present book entitled *Medicine for Yoga Therapists* with philosophical background.



Available at all medical book stores
or buy directly from Jaypee Brothers through online shopping at www.jaypeebrothers.com

or call + 91-11-32558559

JAYPEE BROTHERS
Medical Publishers (P) Ltd.
www.jaypeebrothers.com

ISBN 978-93-5025-375-5