PART II

WHEN, WHY AND WHERE IN ORAL AND MAXILLOFACIAL SURGERY

KC Gupta

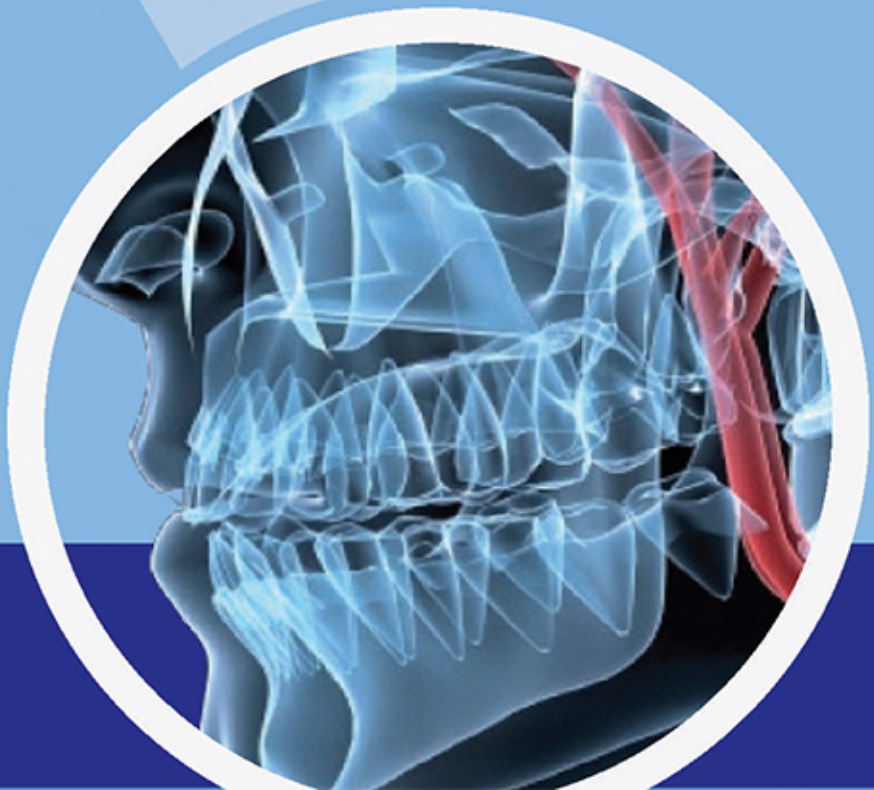

JAYPEE

CONTENTS

1. Growth and Development (Head and Neck Region) 1

- Definition of Growth and Development *1*
- Differentiating between Growth and Development *2*
- Sex Difference in the Skull *2*
- Development of Face *3*
- Development of Tongue *5*
- Development of Mandible *8*
- Development of Maxilla *12*
- Development of Temporomandibular Joint *14*
- Development of Salivary Gland *15*
- Development of Thyroid Gland *15*

2. Surgical Anatomy of Head and Neck Region 17

- Introduction *18*
- Surgical Anatomy of Scalp *18*
- Surgical Anatomy of Skin of Face *19*
- Surgical Anatomy of Temporomandibular Joint *20*
- Surgical Anatomy of Cavernous Sinus *25*
- Surgical Anatomy of Maxillary Sinus *28*
- Surgical Anatomy of Parotid Gland *29*
- Surgical Anatomy of Submandibular Gland *34*
- Surgical Anatomy of Orbit *36*
- Surgical Anatomy of Tongue *45*
- Surgical Anatomy of Trachea *50*
- Surgical Anatomy of Larynx *53*
- Surgical Anatomy of Pharynx *55*
- Surgical Anatomy of Nose *58*
- Surgical Anatomy of Ear *62*
- Surgical Anatomy of Hard Palate *66*
- Surgical Anatomy of Soft Palate *67*
- Surgical Anatomy of Floor of Mouth *68*
- Surgical Anatomy of Mandibular Third Molar *70*
- Surgical Anatomy of Middle Third of Facial Skeleton *72*

- Applied Surgical Anatomy of Mandible *77*
- Surgical Anatomy of Thyroid Gland *80*
- Surgical Anatomy of Parathyroid Gland *84*
- Deep Structures in the Neck *86*

3. Musculature (Head and Neck Region) 87
- Muscles *87*
- Facial Muscles or Muscles of Facial Expression *88*
- Muscles of Mastication *93*
- Muscles of Tongue *101*
- Muscles of Orbit *104*
- Muscles of Soft Palate *108*
- Muscles of Pharynx *110*
- Muscles of Larynx *113*
- Muscles of Ear *115*
- Muscles of Neck *116*
- Muscles of Back of the Neck *118*

4. Classification (Diseases/Disorders/Conditions/ Materials and Methods) 120
- Suture Materials *121*
- Sterilization *122*
- Medically Compromised Condition *123*
- Hemorrhage *125*
- Hemophilia *126*
- Syncope *126*
- Shock *126*
- Local Anesthetic Agents *127*
- Classification of LA Complications *128*
- General Anesthetic Agents *129*
- GA Complications *130*
- Dental Elevators *132*
- Impacted Mandibular Third Molar *133*
- Impacted Maxillary Third Molar *135*
- Impacted Maxillary Canine *136*
- Trismus *139*
- Fascial spaces *140*
- Osteomyelitis *141*

- Cyst of Jaw and Oral Cavity *145*
- Tumors of Jaw and Oral Cavity *152*
- Salivary Glands *155*
- Salivary Gland Diseases or Disorders *157*
- Salivary Gland Tumors *158*
- Diseases of Maxillary Sinus *159*
- Precancerous Lesion *159*
- Oral Submucous Fibrosis *159*
- Preprosthetic Surgical Procedure *161*
- Vestibuloplasty *163*
- Alveoloplasty *163*
- Fibro-osseous Lesions *164*
- Giant Cell Lesion *165*
- Temporomandibular Joint Disorders *165*
- Temporomandibular Joint Ankylosis (Hypomobility) *169*
- Temporomandibular Joint Hypermobility *170*
- Orofacial Pain *170*
- Nerve—Injuries *172*
- Facial Paralysis *172*
- Fracture of Mandible *173*
- Middle Third Facial Skeleton *185*
- Zygomatic Complex Fracture *189*
- Orbital Fracture *191*
- Nasoethmoidal Orbital Fracture *191*
- Tracheostomy *192*
- TNM Staging *193*
- Neck Dissection *194*
- Cleft Palate and Cleft Lip *195*
- Dental Implant *196*
- Classification of Jaw Deformities *197*

5. Management (Different Lesions/Diseases Conditions/Disorders)..... 200

- Shock *201*
- Syncope *204*
- Dental Treatment in Hemophilic Patient (Surgical) *205*
- Bleeding in Exodontia *207*

- Postextraction Trismus *208*
- Dry Socket *208*
- Postextraction Edema *209*
- Postoperative Paresthesia (Numbness) *210*
- Facial Paralysis due to Local Anesthesia *210*
- Toxicity due to Overdose of Local Anesthesia *211*
- Allergic Reaction due to Local Anesthesia *211*
- Cellulitis *213*
- Acute Alveolar Abscess *214*
- Pericoronitis *215*
- Osteomyelitis *216*
- Osteoradionecrosis *219*
- Ludwig's Angina *220*
- Cavernous Sinus Thrombosis *223*
- Acute and Chronic Maxillary Sinusitis *223*
- Removal of Root/Tooth/Foreign Bodies from Maxillary Sinus *225*
- Management of Oroantral Fistula *225*
- Trigeminal Neuralgia *228*
- Facial Paralysis *231*
- Bell's Palsy *232*
- Cyst of Jaw and Oral Cavity *233*
- Tumors of Jaw and Oral Cavity *234*
- Temporomandibular Joint Surgery *237*
- Temporomandibular Joint Ankylosis (Hypomobility) *238*
- Temporomandibular Joint Hypermobility Subluxation *240*
- Temporomandibular Joint Dislocation (Luxation) *240*
- Myofacial Pain Dysfunction Syndrome *242*
- Salivary Gland Disease *243*
- Sialadenitis *243*
- Sialadenosis or Sialoses *244*
- Sialorrhea or Ptyalism *245*
- Salivary Gland Tumor/Pleomorphic Adenoma of Parotid Gland *245*
- Salivary Fistula/Parotid Fistula *246*
- Frey's Syndrome *246*

- Xerostomia *247*
- Primary Assessment and Management of a Patient with Maxillofacial Injuries *247*
- Mandible Fracture *257*
- Principles of Treatment of Condylar Fracture *261*
- Management of Fractures of Edentulous Jaw *263*
- Management of Mandibular Fracture in Children *263*
- Maxilla Fracture *266*
- Zygomatic Complex Fracture *268*
- Nasal Fracture *272*
- Naso-ethmoidal-orbital Fracture *272*
- Preprosthetic Surgery *274*
- Precancerous Lesions *276*
- Oral Cancer *277*
- Cleft Lip and Palate *280*
- Cardiopulmonary Resuscitation *283*
- Postoperative Care of Tracheostomy Patient *288*
- Epileptic Attack (Convulsion) during Dental Procedure *289*
- General Care of Surgical Patient *290*
- Specific Management Problems *293*

6. Syndromes in Oral and Maxillofacial Region 299

- Albright's Syndrome *301*
- Aglossia-adactylia Syndrome *301*
- Anderson Syndrome or Familial Osteodysplasia *302*
- Angio-osteohypertrophy Syndrome *302*
- Apert's Syndrome/Acrocephalosyndactyly *302*
- Ascher's Syndrome *303*
- Blepharo–naso–facial Syndrome *303*
- Burning Mouth Syndrome *303*
- Carpenter's Syndrome *304*
- Costen's Syndrome *304*
- Cerebro-costo-mandibular Syndrome *304*
- Cracked Tooth Syndrome *305*
- Crouzon's Syndrome or Craniofacial Dysostosis *305*
- Cushing's Syndrome *305*

- Craniomandibular Syndrome or Temporomandibular Joint Dysfunction Syndrome *306*
- Cerebellar Syndrome *306*
- Central Cord Syndrome *307*
- Down's Syndrome or Trisomy of 21 or Mongolism *307*
- Eagle's Syndrome *308*
- Ehlers–Danlos Syndrome or Rubber Man *308*
- Edwards' Syndrome (Trisomy 18 Syndrome) *308*
- Elashy Water's Syndrome or Brachioskeletogenital Syndrome *309*
- Fanconi's Syndrome *309*
- First Arch Syndrome *309*
- Frey's Syndrome or Auriculotemporal Syndrome *309*
- Fetal Alcohol Syndrome *310*
- Fifth Seventh Cranial Nerve Syndrome or Tic Convulsive *310*
- Gardner's Syndrome *310*
- Goltz-Gorlin Syndrome or Focal Dermal Hypoplasia *311*
- Goldenhar's Syndrome *311*
- Grinspan's Syndrome *312*
- Gorham's Syndrome or Massive Osteolysis or Phantom Bone *312*
- Heerfordt's Syndrome *312*
- Hecht-Beals-Wilson syndrome *312*
- Horton's Syndrome or Sphenopalatine Neuralgia/Alarm Clock Headache *313*
- Hajdu–Cheney Syndrome *313*
- Jaw Winking Syndrome or Marcus–Gunn Phenomenon *313*
- Jaw Cyst/Basal Cell Nevus/Bifid Rib Syndrome/Gorlin-Goltz Syndrome *314*
- Larsen's Syndrome *314*
- Long Face Syndrome (Vertical Maxillary Excess) *315*
- Marfan's Syndrome *315*
- Moebius Syndrome/Congenital Facial Dysplasia *316*
- Myofacial Pain Dysfunction Syndrome *316*

- Melkersson-Rosenthal Syndrome *317*
- Median Cleft Face Syndrome or Frontonasal Dysplasia *317*
- Mohr's Syndrome *317*
- McCune-Albright's Syndrome *318*
- Nagar's Syndrome or Acrofacial Dysostosis *318*
- Orofacial Digital Syndrome *318*
- Oromandibular Limb Hypogenesis Syndrome *319*
- Oto-palato-digital Syndrome *319*
- Orbital Syndrome *320*
- Postextraction Syndrome (Osteomyelitis Syndrome or Dry Socket) *320*
- Plummer-Vinson Syndrome *320*
- Pfeiffer's Syndrome *321*
- Raeder's Syndrome or Paratrigeminal Syndrome *321*
- Ramsay Hunt's Syndrome *321*
- Sjögren's Syndrome *322*
- Superior Orbital Fissure Syndrome *322*
- Styloid Process Syndrome *322*
- Syngnathia–Popliteal Pterygium Syndrome *323*
- Scheuthauer–Marie–Sainton Syndrome/Cleidocranial Dysplasia *323*
- Tricho-dento-osseous Syndrome *323*
- Trotter's Syndrome *324*
- Temporomandibular Joint Dysfunction Syndrome *324*
- Treacher Collins Syndrome/Mandibulofacial Dysostosis *324*
- Van der Woude's Syndrome *325*
- Whistling Face Syndrome/Cranio-carpalotarsal Syndrome *325*
- XXXXY Syndrome *326*
- Zygomatic Syndrome *326*

7. Diagnostic Clinical Signs in Maxillofacial Region ... 327

- Ball in Hand Configuration *328*
- Beaten Silver Appearance of Skull *329*
- Bull's Eye Ring or Tram Line Pattern *329*

- Bucket Handle Appearance *329*
- Battle's Sign *329*
- Bell's Phenomenon or Bell's Sign *329*
- Bird Face Appearance *330*
- Birn Hypothesis or Dry Socket/Postextraction Syndrome *330*
- Brudzinski's Sign *330*
- Champy's Principle *331*
- Crow's Foot Skin Creases *331*
- Cherry Blossom Appearance *331*
- Circle of Willis *331*
- Coleman's Sign *332*
- Commando Operation *332*
- Cracked Pot Sound *332*
- Crocodile Tear/Crocodile Tear Syndrome *332*
- Carotid Siphon *332*
- Dish-shaped Face/Dish Pan Face *333*
- Difficulty Index *333*
- Dog Ear Wound Closure *334*
- Danger Area of the Face *334*
- Epstein's Pearls *334*
- Elephant Foot Deformity *335*
- Frozen or Mask-like Face *335*
- Facelift Surgery (Rhytidectomy) *335*
- Golden Hour *336*
- Goose Foot (Parotid Plexus or Pes Anserinus) *336*
- Greenstick Fracture *336*
- Guerin Sign *336*
- Glasgow Coma Scale *336*
- Hilton's Law *337*
- Hooding of the Eyes *337*
- Jug Handle View *338*
- Kiesselbach's Plexus or Little's Area *338*
- Langer's Lines *338*
- Levine Sign *338*
- Lincoln Highway of Neck *338*

- Millard's Rule of 10 *339*
- Modiolus *339*
- Open Sky Incision *339*
- Pinto Ligament *339*
- Pruned Tree Appearance or String of Sausages *340*
- Peau d' Orange Skin *340*
- Pott's Puffy Tumor *340*
- Panda Facies or Moon Facies *340*
- Parade Ground Fracture *340*
- Raccoon Eyes or Raccoon Sign *341*
- Slob Rule (Clark's Tube Shift Technique) *341*
- Tongue Tie *341*
- Tinel's Sign *342*
- Thomas Principle *342*
- Vossius Ring *342*
- Whiplash Injury *342*
- Water's View *343*
- War Lines *343*
- Witch's Chin *343*
- White Strawberry Tongue and Red Strawberry Tongue *344*
- Wry Neck *344*
- Wrinkle Line or Natural Line *344*
- Wolff's Law *345*

8. Typical Radiographic Picture in Different Conditions 346

9. Test in Oral and Maxillofacial Surgery 350

- Bowie–Dick Test *351*
- Brown's Test *351*
- Chick–Martin Test *351*
- Conduction Test (Diagnostic Test for Facial Paralysis) *352*
- Forced Duction Test *352*
- Frey's Hair Test *352*
- Handkerchief Test *352*
- Hess Test *353*
- Nose Blowing Test *353*

- Paget's Test *353*
- Riedel–Walker Test *354*
- Schirmer's Test *354*
- Starch Iodine Test *354*
- Tobey–Ayer Test *355*
- Tourniquet Test *355*
- TST Test *355*
- Valsalva Test *355*

10. Red Lesions of the Oral Cavity 356
11. White Lesions of the Oral Cavity 357
12. Yellow Lesions of the Oral Cavity 359
13. Blue/Black/Brown/Purple Lesions 360
14. Ulcerative Lesions of the Oral Cavity 361
15. Pericoronal Radiolucencies 362
16. Solitary Cyst-like Radiolucencies 363
17. Multilocular Radiolucencies 365
Index 367

Chapter 1

Growth and Development
(Head and Neck Region)

Chapter Outline

- Definition of Growth and Development
- Difference between Growth and Development
- Sex difference in the Skull
- Development of Face
- Development of Tongue
- Development of Mandible
- Development of Maxilla
- Development of Temporomandibular Joint
- Development of Salivary Gland
- Development of Thyroid Gland

DEFINITION OF GROWTH AND DEVELOPMENT

Growth

Craniofacial growth is a complex phenomenon. Growth center is considered an anatomic phenomenon. Growth is qunantitative.

For example, it is a measurable aspect of biologic life. Growth is change or difference in quantity.

Development

In simple words, progression towards maturity. Development can be considered as a continuum of casually related events

JAYPEE BROTHERS

from the fertililization of ovum onwards. Development is a physiological and behavioral phenomenon.

DIFFERENTIATING BETWEEN GROWTH AND DEVELOPMENT

Growth	*Development*
Growth is "increase in size"	Development is "progression towards maturity"
It is an anatomic phenomenon	It is a physiological and behavioral phenomenon
It is quantitative	It includes growth + differentiation + translocation
Growth highlights the normal dimensional changes over a period of time	It comprises sequential events from fertilization till death
Growth might cause change in form or proportion. Increase or decrease in size, change in texture or complexity	It includes all the changes in life of a subject from his/her origin as a single cell till death

SEX DIFFERENCE IN THE SKULL

- No sex differences until puberty.
- Post puberty differences are:

Features	*Males*	*Females*
Weight	Heavier	Lighter
Size	Larger	Smaller
Walls	Thicker	Thinner
Capacity	Greater	10% less than males
Mascular ridge	More marked	Less marked
Temporal lines	More marked	Less marked
Mastoid process	More marked	Less marked
External occipital protuberance	More marked	Less marked
Tympanic plate	Larger and rough	Smaller and less rough
Supera orbital margin	Rounded	Sharp
Forehead	Sloping	Vertical
Vault	Rounded	Somewhat flattened

Contd...

JAYPEE BROTHERS

Contd...

Frontal and parietal tubera	Less prominent	More prominent
Contour of face	Longer, chin is bigger skull is more rough zygomatic bones are more massive	Rounded Facial bones are Smoother Mandible and maxilla are smaller

DEVELOPMENT OF FACE

Introduction

In general two terms which are closely related –

a. Development is the progression towards maturity.
b. Growth is increase in the size.
   Different organs grow at different rate at different time.

Scheme of Development of Face

1. Prenatal period – Intrauterine (from fertilization till birth)
   a. Pre-embryonic period or period of ovum (from fertilization till 2 or 3 weeks)
   b. Embryonic period (from 3rd or 4th week till 8th week)
   c. Fetal period (from 9th week till birth)
2. Postnatal period (extrauterine)

Key Points

Prenatal Period

A. "Pre-embryonic period or period of ovum"
   – This period extends from the fertilization of the ovum to about 3 week
   – During this period, the single cell zygote multiplies rapidly by segmentation
   – Three germ layers ectoderm, endoderm, and mesoderm are formed during this period

Contd...

JAYPEE BROTHERS

Contd...

- The ovum is fertilized by spermatoon and a zygote is formed in the fallopian tube.

B. "Embryonic stage"

- Rudiments of all organs formed during this period
- A one-month-old embryo has no face as such.
- Approximately 1 month after fertilization growth center associated with the development of face, nose, palate and jaws
- These centers are located around a depression known as stomodeum or primitive face or Rathke's pouch which is lined by ectodermal cells.

C. "Fetal Period"

- During the fetal period, the individual facial bones undergo rapid and co-ordinated growth pattern closely associated with the brain, orbit and nasal cavities
- Rapid growth of the brain and nasal septum to play an important role in facial skeletal development
- The resorption and deposition at an other surface permits the bones to maintain, their proper association, dimension and morphological appearances during critical growth period.

Postnatal Period

1. Bone formation
2. Growth process
   a. Displacement
   b. Remodeling
3. Postnatal age changes in facial growth
4. Growth of the cranial base
5. Growth of mid facial skeleton
6. Growth of mandible
7. Growth of paranasal sinus
   a. Frontal sinus
   b. Sphenoid sinus
   c. Maxillary sinus
   d. Ethmoid sinus.

JAYPEE BROTHERS

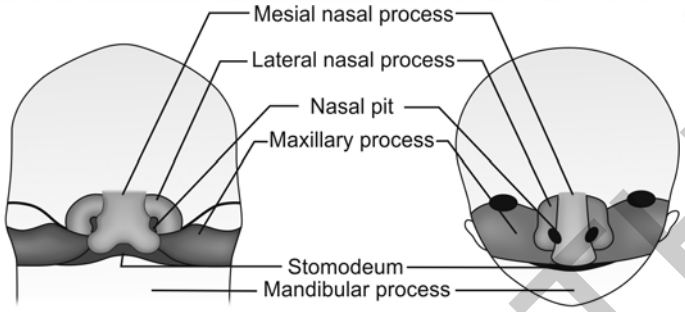

Fig. 1.1: Development of face

Summary of Origin of Different Parts of Mouth and Face

1. Stomodeum–Rathke's pouch: Anterior pituitary/lip/teeth/hard palate/anterior part of the soft palate.
2. Median nasal process: Premaxilla (2 central incisors)/nasal septum/philtrum/frenum of upper lip.
3. Lateral nasal process: Cribriform plate/lateral mass of ethmoid/inferior nasal concha/upper part of body of maxilla/frontal process/lacrimal and other nasal bones/lateral cartilage of nose and part of alar cartilage of nasal septum.
4. Maxillary process: Part of body of maxilla/upper alveolar process/lateral part of premaxilla/hard palate except premaxillary part/zygomatic bone/zygomatic process of temporal bone/upper lip except philtrum.
5. Mandibular process: Body of mandible/lower alveolar process/lower lip/part of cheek.

DEVELOPMENT OF TONGUE

Introduction

Tongue is a major organ because it develops from more than one branchial arches.

JAYPEE BROTHERS

Tongue is composed of: Base, body and tip.

It has two surfaces: Dorsal and ventral and two lateral borders.

The dorsal surface of the tongue is divided into anterior 2/3rd and posterior 1/3rd by the sulcus terminalis which is V shaped groove. In the center of the V is the foramen cecum.

Development

1. The tongue arises from the ventral wall of the primitive oropharynx from the lining of the branchial arches.
2. The tongue develops from 1st, 3rd, 4th arches at about 4th week *in utero*. Paired lingual swellings appear in the mesenchyme of the 1st branchial arch.
3. From the 3rd arch behind the lingual swellings arise the tuberculum impar a median swelling.
4. Behind the tuberculum impar is a pit called the foramen ceacum that marks the site of origin of the thyroid diverticulum. It extends into the pharynx to form the major portion of the thyroid gland.
5. The lingual swellings grow and fuse with each other and growing over the tuberculum impar to form the anterior 2/3rd of the tongue.
6. Two ventral parts of the 2nd, 3rd and 4th arches fuse to form the copula in the midplane. The posterior portion of the eminence forms the hypobranchial eminence.
7. The circumvallate papillae along the sulcus terminalis form at 2 to 5 months *in utero*. Fungiform papillae develop at the 11 weeks *in utero*.
8. Muscles are derived from the occipital somites and are supplied by the hypoglossal nerve.
9. The tongue grows rapidly at 6-7 weeks *in utero*.
10. The tongue descends to occupy a lower position in the increased oral volume and allows the palatal shelves to elevate.

JAYPEE BROTHERS

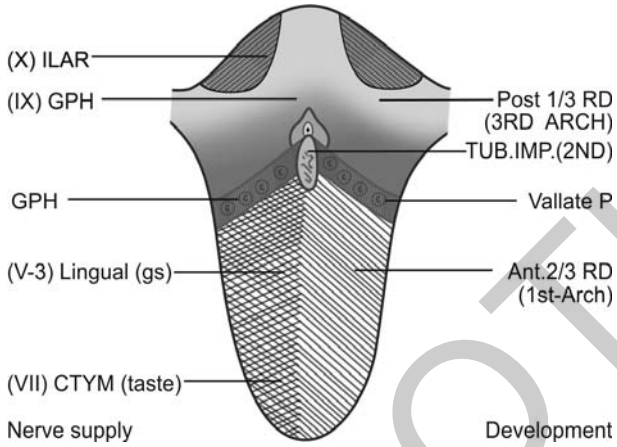

Fig. 1.2: Development of tongue

11. The sensory supply of the anterior 2/3rd of the tongue is by the lingual nerve. Gestation by the chorda tympani nerve and posterior 1/3rd by glossopharyngeal nerve; and posterior most part by vagus nerve.
12. In the infant stage of life, tongue is an important organ because it helps in the process of sucking. The tongue is placed between the gumpad to create an oral seal.
13. The tongue attains adult size at about 8 years of age. The size of the tongue is almost double when the size of the newborn is compared with the adult tongue.

Developmental Anomaly

1. Macroglossia: Abnormally large tongue, commonly seen in hyperpitutarism, clinically crenations on lateral borders of tongure are seen.
2. Microglossia: Smaller tongue.
3. Aglossia: Absence of tongue.

JAYPEE BROTHERS

DEVELOPMENT OF MANDIBLE

Introduction

Mandible is derived from the 1st branchial arch which is called the mandibular arch. The branchial arches start developing at about 4th week in utero.

Branchial arches are bilateral mesodermal swellings. The mesodermal core of each arch is surrounded by invasion of the ectomesenchymal tissue that augments it. There are five branchial arches in total. The fifth being transitory. The first arch is the mandibular and second arch is the hyoid arch. The cartilage of the 1st arch is called Meckel's cartilage, developing at about 41st to 45th day *in utero*. The Meckel's cartilage provides a template for the development of mandible.

Development

- The mandible starts its development as a swelling which grows ventromedially to approach the fellow of the opposite side.
- By 5th week of intrauterine life, the mandibular processes of both sides approach each other and are fused.
- The Meckel's cartilage extends from the area of the future ear to the midlines of the fused mandibular processes.
- At about 6th week, the cartilaginous rods begin to chondrify which is continuous from the malleolus region to the future symphysis. The rods are separated in the midline. The rods support the forming skeletal framework of the mandible.
- The part of the mandible mesial to mental foramen undergoes endochondral ossification while the lateral to mental foramen undergoes intramembranous ossification.

JAYPEE BROTHERS

- The process of ossification proceeds anteriorly and posteriorly. Posterior intramembranous ossification forms the rest of the body and the ramus of the mandible.

Development of Condyle and Coronoid

- The formation of condylar process starts only at the 10th week, hence, till such time malleus and incus function as a temporary joint with the glenoid fossa of the temporal bone to permit mandibular movements.
- The Meckel's cartilage is replaced largely by bone and remnant of it is left as the bones of malleus and incus. And the soft tissue part as sphenomandibular ligament.
- Ossification center is present at the site of future mental foramen.
- The condylar cartilage is a secondary cartilage and its origin is unrelated to the Meckel's cartilage which is primary cartilage. The condyle arises as a separate mesenchymal condensation that is cone shaped at about 10th week of intrauterine life.
- The process of ossification does not start till 14th week. The cartilage is replaced by bone except the region of the tip of the head of the condyle superior which is maintained till teens for future growth.
- Now that condyle is established the TMJ is shifted anteriorly the ossification of ramus proceeds and the condyle is soon fused to the mandible at about 16th week.
- Coronoid process develops from secondary cartilage that arises at about 10th to 14th week in utero. Soon the growing intramembranous ossification fuses the coronoid process to the ramus.

JAYPEE BROTHERS

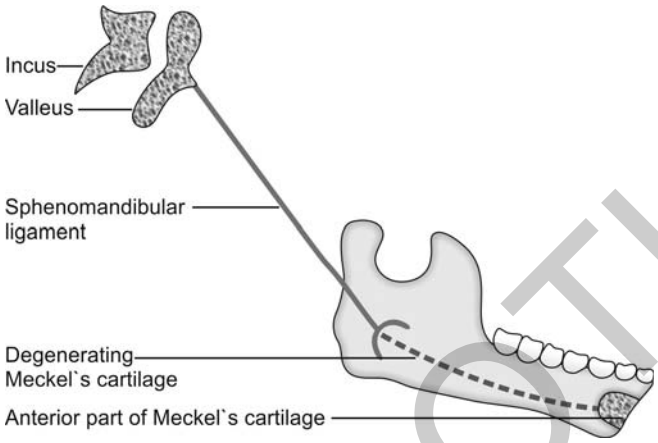

Fig. 1.3: Contribution of Meckel's cartilage

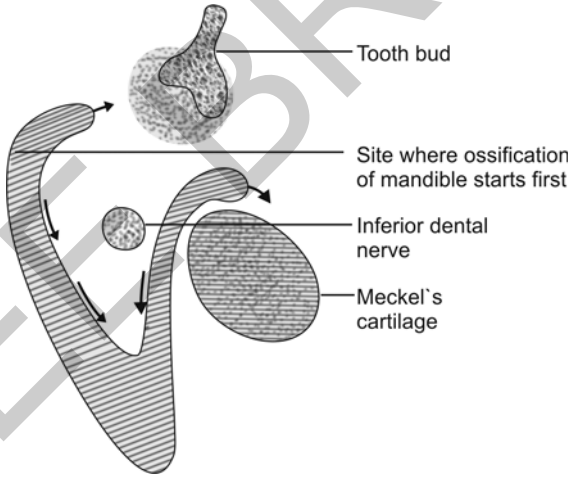

Growing mandible (Coronal section)

Fig. 1.4: Development of mandible

JAYPEE BROTHERS

Anomaly

The failure of fusion of both the mandibular process from both side known as midline cleft.

Postnatal Growth of Mandible

Mandible at Birth

- Mandible at birth is much smaller in size.
- There is slight variation in shape from the adult form.
- The infants mandible has a short horizontal ramus with obtuse gonial angle.
- The condyles are low and at the position of the occlusal plane.
- The symphyseal suture has not ossified.

Growth in the First Year

- The growth of mandible in the 1st year of life involves growth at the symphyseal suture.
- Anterior expansion in the anterior region to accommodate the erupting anterior teeth.
- The mental foramen is directed at right angle to the surface of the corpus.
- There is increased deposition in the posterior surface of the ramus of the mandible.
- The infants mandible is suite for the sucking activity. Since the condyle and glenoid fossa is flat which helps in the anteroposterior movement of the mandible.

Mandible in the Adult

- Mandible in the adult is different from the mandible of an infant.
- The ramus is longer.
- The gonial angle is less obtuse.
- The bone is longer on the whole. Condyle is well developed.

JAYPEE BROTHERS

DEVELOPMENT OF MAXILLA

Introduction

Maxilla is a pair of bones on either side of the middle- third of the face formed by intramembranous bone formation.

Growth of maxilla closely follows the neurak growth curve in the Scammon's curve.

Development

- By about 4th week of intrauterine life the facial process arises from the 1st arch which corresponds to the mandibular process.
- Later the mandibular processes give two more swellings which grows ventromedially. These are maxillary process.
- The maxillary process grows ventromedially towards the nasal processes.
- The maxillary and the medial nasal processes are initially separated by the epithelial nasal fin which soon degenerates so that, the mesenchyme of the two processes fuse.
- The maxillary and mandibular processes fuse at the sides form the cheek tissue.
- The lateral nasal process forms the alae of the nose.
- The medial nasal process of both sides fuse to form the globular process in the middle which gives rise to the– tip of nose, columella, the philtrum, the labial tuberculum and the entire primary palate.
- The maxillary process forms the alveolus which bears teeth distal to the canines and the secondary palate.
- The area of fusion of the maxillary and mandibular processes forms the commisures or corner of the mouth.
- As the two processes grow towards the fellow of the opposite side and stomodeum is narrowed.

JAYPEE BROTHERS

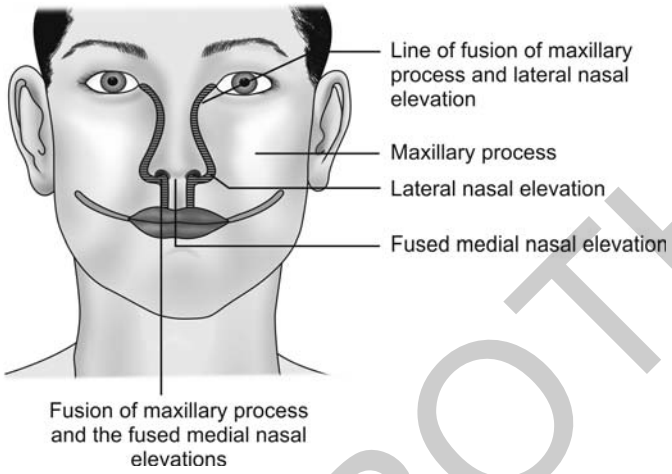

Fig. 1.5: Development of maxilla

Postnatal Growth of Maxilla

- Maxilla is a membranous bone and the development/growth of maxilla is completed early when compared to the mandible.
- According to the cephalo-caudal gradient of growth-growth does not proceeds proportionately in humans.
- So in the case of maxilla it completes its growth early in life in certain aspects relative to the mandible.
- The maxilla especially width also follows closely the neural growth curve more than the general growth curve in the Scammon's curve.
- The growth of maxilla occurs by the following processes:
  a. Connective tissue proliferation at the sutures
  b. Translation
  c. Remodeling.

JAYPEE BROTHERS

WHEN, WHY AND WHERE IN ORAL AND MAXILLOFACIAL SURGERY

Salient Features

- Covers maximum topics of basic oral and maxillofacial surgery
- Explains in simple and lucid language
- Pointwise and diagrammatic representation
- Easy to understand and remember
- Helpful in diagnosis and management.

KC Gupta MDS is an eminent teacher and clinician. At present, he is a postgraduate teacher (since 2005) and Professor and Head, Department of Oral and Maxillofacial Surgery, Modern Dental College and Research Centre, Indore, Madhya Pradesh, India.



Previously, he headed the Oral and Maxillofacial Surgery, Government Dental College, Jamnagar, Gujarat, India.

Shelving Recommendation
DENTISTRY

Available at all medical book stores
or buy directly from Jaypee Brothers through online shopping
at www.jaypeebrothers.com

JAYPEE BROTHERS
Medical Publishers (P) Ltd.
www.jaypeebrothers.com

ISBN 978-93-5025-929-0