SECOND EDITION

HUMAN ANATOMY

for Students



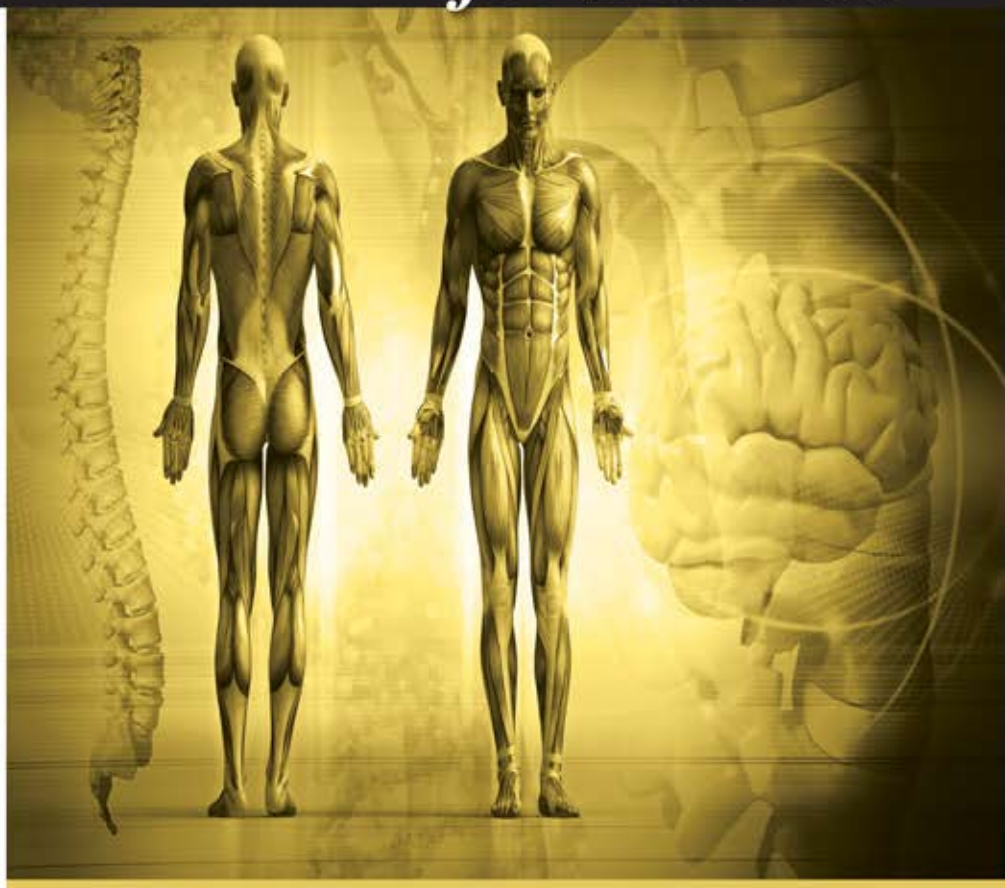

Forewords
Ramjee Singh
SM Desarda
Jadi Rajamallu
Tanmoy Mitra

BYAS DEB GHOSH

JAYPEE

Contents

1. Introduction 1

- Human Anatomy 1
- Techniques and Methods of Knowing about Living Anatomy 2
- Planes of the Body 3 • Anatomical Terms in Relation to Different Aspects 4
- Some Important Anatomical Terms 4

2. Superior Extremity 9

- Shoulder Joint 9 • Elbow Joint 13 • Wrist (Radiocarpal) Joint 17
- Radial Artery 20 • Ulnar Artery 22 • Median Nerve 23
- Ulnar Nerve 26 • Radial Nerve 29 • Axilla 32 • Axillary Artery 34
- Axillary Lymph Nodes 38 • The Brachial Plexus 39 • Axillary Nerve 42
- The Musculocutaneous Nerve 43 • Brachial Artery 44
- Anastomosis Around the Elbow Joint 46 • Cubital Fossa 46
- Adult Female Breast 47

3. Short Notes on Superior Extremity 54

- Anatomical Snuff Box 54 • Flexor Retinaculum of Hand 54
- Palmar Aponeurosis 56 • Superficial Palmar Arch 59
- Deep Palmar Arch 60 • Extensor Retinaculum of Hand 60
- Erb's Point 61 • Sibson's Fascia or Suprapleural Membrane 62
- Clavipectoral Fascia 62 • Arteria Profunda Brachii 63
- Biceps Brachii 64 • Triceps Brachii 64 • Brachialis 66
- Deltoid 67 • Pectoralis Major 68 • Latissimus Dorsi 69
- Trapezius 69 • Intrinsic Muscles of Hand 70
- Muscles of Thenar Eminence and Adductor Pollicis 71
- Muscles of Hypothenar Eminence and Palmaris Brevis 73
- Muscles Acting on the Fingers 74

4. Thorax 78

- Mediastinum 78 • Pericardium 83 • Heart 86
- Arterial Supply of the Heart 99 • Arch of Aorta 106 • Lungs 109
- Bronchopulmonary Segments 115 • Pleura 117
- Esophagus 121 • Thoracic Duct 124 • Trachea 126
- The Diaphragm 129 • Azygos Vein 131 • Superior Vena Cava 132

5. Abdomen and Pelvis 136

- Stomach 136 • Small Intestine 145 • Duodenum 145
- Jejunum 152 • Ileum 153 • Cecum 154 • Appendix 156
- Spleen 159 • Pancreas 164 • Liver 170
- Extrahepatic Biliary Apparatus 180 • Kidneys 185 • Ureters 194

JAYPEE BROTHERS

- Rectum 198 • Anal Canal 205 • Penis 209 • Testes/Testis 214
- Descent of the Testis 217 • Prostate 219 • The Ovaries 225
- Uterine Tube (Fallopian Tubes) 229 • The Uterus 231 • Vagina 239
- Urinary Bladder 243 • Internal Trigone 247 • Male Urethra 249
- Female Urethra 253 • Abdominal Aorta 254 • Celiac Trunk 256
- Superior Mesenteric Artery 256 • Inferior Mesenteric Artery 258
- Inferior Vena Cava 259 • Portal Vein 262

6. Short Notes on Abdomen and Pelvis 265

- Linea Alba 265 • Holden's Line 266 • The Umbilicus or Omphalos 266
- Inguinal Ligament/Poupart's Ligament 268
- Falx Inguinalis/Conjoint Tendon 269 • Rectus Sheath 270
- Inguinal Canal 271 • Defensive Mechanism of the Inguinal Canal 272
- Scrotum 274 • Spermatic Cord 276 • The Mesentery 277
- Epiploic Foramen 278 • Meckel's Diverticulum 278 • Peyer's Patches 280
- Cisterna Chyli 280 • Renal Fascia or Fascia of Gerota 281
- Ischiorectal Fossa 282 • Perineal Body/Central Tendon of the Perineum 285
- Superficial Perineal Pouch 286
- Deep Perineal Pouch 287 • The Suprarenal Glands 288
- Name Different Regions of Abdomen and Their Important Contents 291

7. Inferior Extremity 293

- Muscles of Anterior Aspect of Thigh 293 • Hamstring Muscles 295
- Muscles of The Medial Aspect of the Thigh 296
- Muscles of Gluteal Region 298
- Structures Deep to the Gluteus Maximus 299 • Femoral Artery 301
- Relations 302 • Popliteal Artery 303 • Anterior Tibial Artery 306
- Posterior Tibial Artery 307 • Femoral Nerve 309
- Obturator Nerve 310 • Sciatic Nerve 312 • Common Peroneal Nerve 314
- Deep Peroneal Nerve (Anterior Tibial Nerve) 315
- Superficial Peroneal Nerve 316 • Tibial Nerve 317
- Hip Joint 319 • Knee Joint 326 • Bursae Around the Knee Joint 330
- Ankle or Talocrural Joint 336

8. Short Notes on Inferior Extremity 340

- Deep Fascia of Thigh/Fascia Lata 340 • Iliotibial Tract 340
- Saphenous Opening 341 • Inguinal Lymph Nodes 342
- Femoral Sheath 343 • Tendocalcaneus or Tendoachilles 345
- Plantar Aponeurosis 346 • First Layer of Muscles of Sole 347
- Lateral Plantar Artery 348 • Medial Plantar Artery 349
- Plantar Arterial Arch 349 • Superior Extensor Retinaculum 350
- Inferior Extensor Retinaculum 351 • Superior Peroneal Retinaculum 352
- Inferior Peroneal Retinaculum 352 • Flexor Retinaculum 353
- Arteria Profunda Femoris 354 • Arteria Dorsalis Pedis 355
- Superficial Veins of the Lower Limb 356 • Great Saphenous Vein 356

JAYPEE BROTHERS

- Small or Short Saphenous Vein 358 • Arches of the Foot 359
- Structures Maintain the Foot Arches 361 • Greater Sciatic Foramen 363
- Lesser Sciatic Foramen 363 • Femoral Triangle 363
- Adductor Canal/Hunter's Canal or Subsartorial Canal 367
- Popliteal Fossa 368 • Anastomosis Around the Knee Joint 369

9. Head, Neck and Face 372

- Middle Ear or Tympanic Cavity 372 • Eyeball 377 • The Larynx 387
- Mechanism of Speech (Phonation) 398 • The Pharynx 398
- Anterior Triangle of Neck 405 • Posterior Triangle of Neck 409
- Thyroid Gland 412 • Parotid Gland 417
- Parotid Duct or Stensen's Duct 422 • Tongue 422
- Muscles of the Tongue 425 • Common Carotid Artery 431
- External Carotid Artery 433 • Internal Carotid Artery 441
- Internal Jugular Vein 443 • Temporomandibular Joint 445

10. Short Notes on Head, Neck and Face 449

- Scalp 449 • Extent 449 • Muscles of the Face 452
- Carotid Sheath 456 • Waldeyer's Lymphatic Ring 456 • Palatine Tonsil 457
- Posterior Cricoarytenoideus or Safety Muscle of Larynx 460
- Styloid Apparatus 461 • The Orbits 461 • Extraocular Muscles 464
- Muscles of Mastication 467 • Soft Palate 470 • Palatine Aponeurosis 471
- Muscles of Soft Palate 472 • Lateral Wall of Nose 473
- Nasal Septum 477 • Tympanic Membrane or Eardrum 480
- Pharyngotympanic or Auditory or Eustachian Tube 482
- The Circulus Arteriosus or Circle of Willis 485 • Blood-Brain Barrier 486
- The Optic Chiasma 487 • Dural Sinuses 488 • Cavernous Sinuses 492
- Otic Ganglion 494 • Ciliary Ganglion 495
- Ansa Cervicalis or Ansa Hypoglossi 496 • Nasociliary Nerve 496
- Paranasal Sinuses 497 • Lacrimal Apparatus 501 • Vertebral Artery 503
- Pituitary Gland 505 • Sternocleidomastoid Muscle 508

11. Brain and Spinal Cord 510

- Cerebrum 510 • Basal Nuclei 522 • Internal Capsule 526
- White Matter of the Cerebrum 529 • Fourth Ventricle 530
- Lateral Ventricles 534 • Third Ventricle 538 • Thalamus 540
- Metathalamus 543 • Epithalamus 544 • Pineal Body 545
- Habenular Nuclei 545 • Hypothalamus 545
- Subthalamus 546 • Cerebellum 547 • Spinal Cord 552
- Internal Structures of the Spinal Cord 557 • Meninges 561
- Cerebrospinal Fluid 569 • Brainstem 571

12. Other Short Notes 591

- Umbilical Cord 591 • The Placenta 593 • Fetal Circulation 594
- Horner's Syndrome 595 • Turner's Syndrome 595

JAYPEE BROTHERS

- Down's Syndrome or Mongolism 596 • Notochord 596
- Right Atrioventricular Valve or Tricuspid Valve 597

13. Cranial Nerves and Some Neural Pathways 600

- Olfactory Nerve 600 • Optic Nerve 601 • Oculomotor Nerve 604
- Trochlear Nerve 606 • Trigeminal Nerve 607 • Abducent Nerve 609
- Facial Nerve 611 • Vestibulocochlear Nerve 615
- Glossopharyngeal Nerve 616 • Vagus Nerve 618
- Accessory Nerve 621 • Hypoglossal Nerve 622
- Visual Pathway 624 • Auditory Pathway (Pathway of Hearing) 626
- Vestibular Pathway 627 • Taste Pathway 627 • Olfactory Pathway 627
- Pathway of Touch/Tract of Conscious Proprioceptive Impulses 628
- Pathway of Pain and Temperature or Lateral Spinothalamic Tract 628
- Reticular Formation 629 • Limbic System 630

14. Dissection 631

- Dissection of Anterior Triangle of Neck 631
- Dissection of Posterior Triangle of the Neck 634
- Dissection of Parotid Region 635
- Dissection of Suboccipital Triangle 637 • Dissection of Axilla 638
- Dissection of the Front of the Arm 641
- Dissection of the Triangular and Quadrangular Spaces 642
- Dissection of Cubital Fossa 644 • Dissection of the Front of the Forearm 647
- Dissection of the Palm 649 • Dissection of the Dorsum of the Hand 653
- Dissection of Rectus Sheath 654 • Dissection of Inguinal Canal 657
- Dissection of Femoral Triangle 659
- Dissection of Adductor Canal/Hunter's Canal 663
- Dissection of Gluteal Region 664 • Dissection of Popliteal Fossa 666
- Dissection of Sole of Foot 670

15. Histology (T.S.) 674

- General Structures of the Gastrointestinal Tract (T.S.) 674
- T.S. of Stomach 675 • T.S. of Duodenum 675 • T.S. of Jejunum 676
- T.S. of Ileum 677 • T.S. of Vermiform Appendix 677
- T.S. of Large Intestine 677 • T.S. of Spleen 678
- T.S. of Pancreas 678 • T.S. of Liver 679 • T.S. of Gallbladder 680
- T.S. of Kidney 680 • T.S. of Ureter 681 • T.S. of Prostate 682
- T.S. of Testis 682 • T.S. of Epididymis 683 • T.S. of Ovary 684
- T.S. of Fallopian Tube 684 • T.S. of Uterus 685
- T.S. of Suprarenal (Adrenal) Glands 685 • T.S. of Thyroid Gland 686
- T.S. of Lung 686 • T.S. of Tongue 687 • T.S. of Cerebrum 688
- T.S. of Cerebellar Cortex 689 • T.S. of Spinal Cord 689
- T.S. of Hyaline Cartilage 690 • T.S. of Elastic Cartilage 690
- T.S. of Fibrocartilage 691 • T.S. of Compact Bone 692 • T.S. of Skin 692

JAYPEE BROTHERS

16. Radiology 693

- Radiology of Head, Neck and Skull 693 • Radiology of Vertebral Column 695
- Radiology of Thorax/Chest 696 • Radiology of Abdomen and Pelvis 699
- Radiology of Superior Extremity 704
- Sequences of Ossification and Union 707
- Radiology of Inferior Extremity 709

17. Surface Anatomy 713

- Head, Neck and Face 713 • Thorax 719 • Heart 720
- Lungs 721 • Abdomen and Pelvis 722
- Superior Extremity 729 • Inferior Extremity 730

18. Osteology 735

- Introduction 735 • Osseous System or Skeletal System 735
- Bones of Upper Limb 736 • Clavicle 736 • Scapula 739
- Humerus 747 • Radius 754 • Ulna 757 • Skeleton of the Hand 763
- Bones of Lower Limb 764 • Hip Bone 764 • Femur 774 • Patella 779
- Tibia 781 • Fibula 786 • Skeleton of the Foot 791
- Tarsus/Tarsal Bones 791 • Talus 791 • Calcaneus/Calcaneum 794
- Metatarsal Bones 797 • Phalanges 798 • Ribs and Sternum 798
- Ribs 798 • Typical Ribs 799 • Atypical Ribs 802 • Sternum 803
- Cervical Vertebrae 806 • Thoracic Vertebrae 812 • Lumbar Vertebrae 813
- Sacrum 815 • Skull 824 • Occipital Bone 831 • Temporal Bone 835
- Mandible 841 • Sphenoid Bone 844 • Parietal Bone 852
- Frontal Bone 853 • Maxillae 859

19. Oral Questions and Answers 863

- Larynx 863 • Heart 864 • Aorta 869 • Trachea 870
- Lungs 872 • Esophagus 873 • Diaphragm 874 • Thorax 875
- Stomach 876 • Appendix 879 • Spleen 880 • Pancreas 883
- Liver 884 • Kidneys 887 • Gallbladder 888 • Uterus 889
- Abdomen and Pelvis 892 • Superior Extremity 894
- Inferior Extremity 898 • Head and Neck 900
- Foramina of Skull 907 • General Anatomy 908
- Miscellaneous Oral Questions and Answers 909

Index 913

JAYPEE BROTHERS

4 Thorax

MEDIASTINUM

Definition

It is an intrathoracic tissue space between the two pleural sacs, containing various types of organs which are belonging to different types of systems, such as cardiovascular, respiratory, alimentary and nervous systems, etc.

Boundaries (Fig. 4.1)

Anteriorly
Sternum.

Posteriorly
Thoracic part of the vertebral column.

Superiorly
Thoracic inlet.

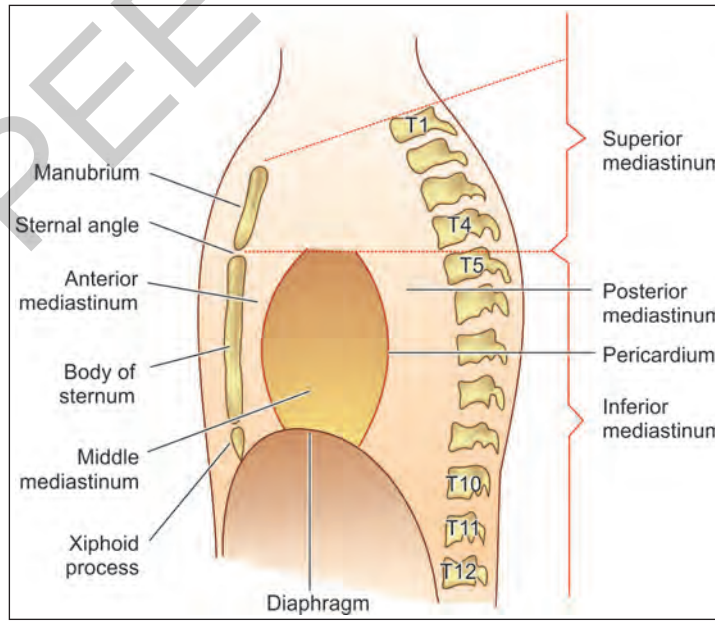

Fig. 4.1 Subdivision of mediastinum

JAYPEE BROTHERS

Inferiorly
The diaphragm.

Laterally
Mediastinal pleura.

Divisions

Mediastinum is divided into two by an imaginary horizontal line, which passes anteriorly from the sternal angle to posteriorly lower border of 4th thoracic vertebra.

1. Superior mediastinum
2. Inferior mediastinum.

Inferior mediastinum is further subdivided by the pericardium containing heart and the root of great vessels into three:

a. Anterior mediastinum
b. Middle mediastinum
c. Posterior mediastinum

Superior Mediastinum

Boundaries (Fig. 4.2)

Anteriorly: Manubrium sterni.

Posteriorly: T1 to T4 with their intervertebral disks and anterior longitudinal ligament.

Superiorly: Thoracic inlet.

Inferiorly: An imaginary horizontal line.

Laterally: Mediastinal pleura.

Boundaries of thoracic inlet are given below:

Anteriorly: Jugular notch.

Posteriorly: Body of T1.

Laterally: Inner border of first rib.

Contents (Fig. 4.3)

Arteries

i. Arch of aorta
ii. Brachiocephalic trunk
iii. Left common carotid artery
iv. Left subclavian artery
v. Internal thoracic arteries.

Veins

i. Upper one-half of SVC
ii. Right brachiocephalic vein
iii. Left brachiocephalic vein
iv. Left superior intercostal vein
v. Internal thoracic veins.

Others (Figs 4.4 and 4.5)

i. Trachea
ii. Esophagus (Thoracic part)
iii. Atrophied part of thymus gland.

Muscles

i. Origin of sternothyroid
ii. Origin of sternohyoid
iii. Origin of longus colli (up to T3).

Nerves

i. Right and left vagus nerves
ii. Right and left phrenic nerves

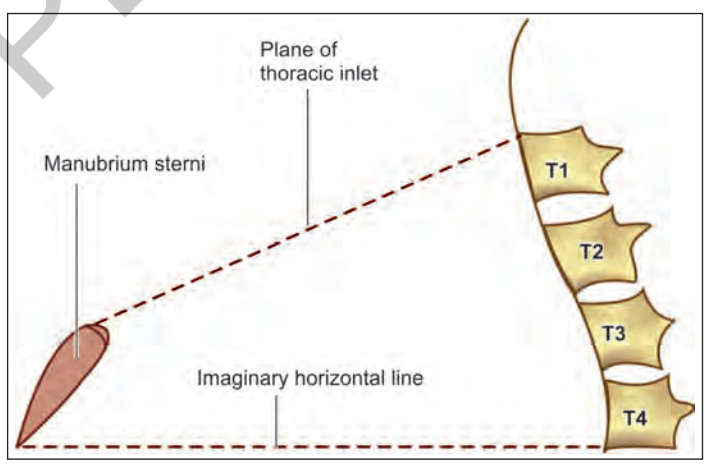

Fig. 4.2 Boundaries of superior mediastinum

JAYPEE BROTHERS

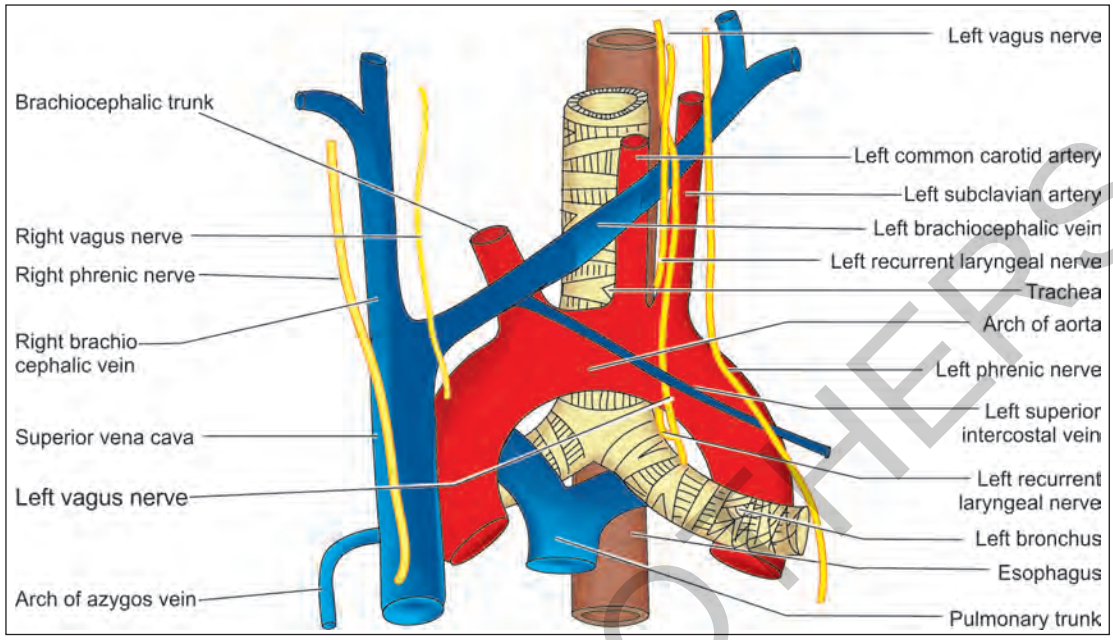

Fig. 4.3 Contents of superior mediastinum

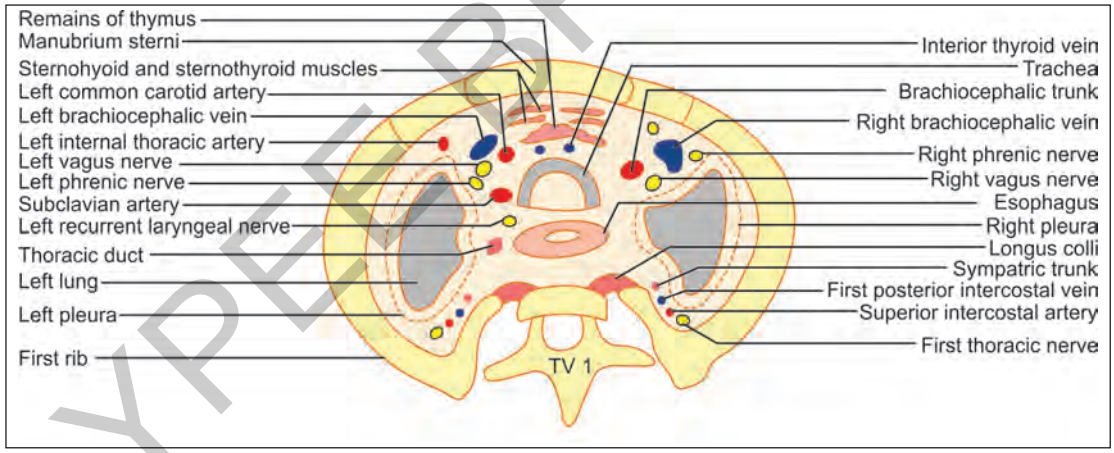

Fig. 4.4 Structures passing through the inlet of the thorax

iii. Left recurrent laryngeal nerve
iv. Superficial cardiac plexus
v. Cardiac nerves.

Lymph Nodes and Tissues

i. Thoracic duct
ii. Paratracheal, brachiocephalic and tracheo-bronchial lymph nodes.

Subdivisions of Inferior Mediastinum (Fig. 4.6)

Anterior Mediastinum

It is the narrowest of all mediastinum.

Boundaries

Anteriorly: Body of sternum

Posteriorly: Anterior aspect of pericardium

JAYPEE BROTHERS

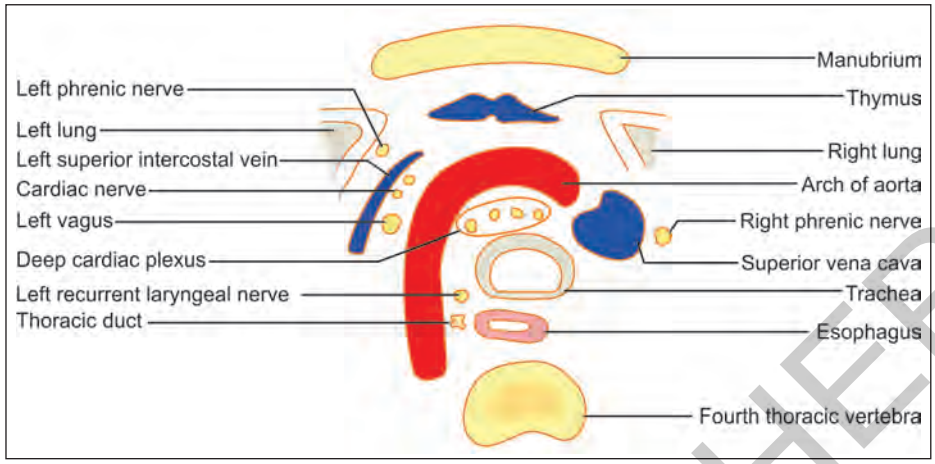

Fig. 4.5 Transverse section of the thorax passing through the fourth thoracic vertebra

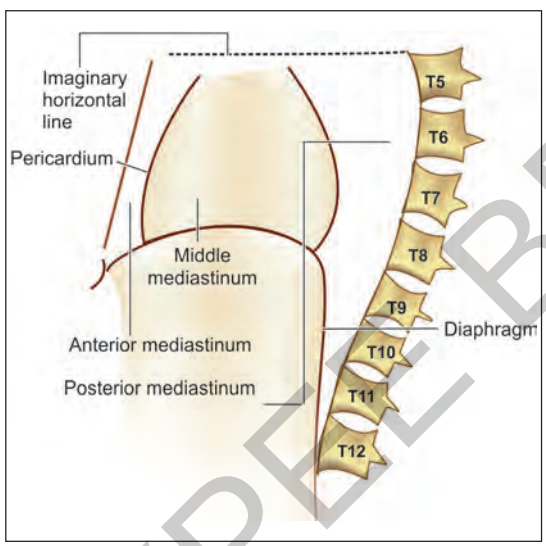

Fig. 4.6 Boundaries of inferior mediastinum

Superiorly: Imaginary horizontal line

Inferiorly: The diaphragm

Laterally: Mediastinal pleura

Contents

i. Some mediastinal twigs of the internal thoracic (mammary) arteries
ii. Around 2 to 3 lymph nodes and vessels
iii. Superior and inferior bands of sternopericardial ligaments
iv. Sometimes lowest part of the atrophied part of the thymus gland
v. Some loose areolar tissue.

Middle Mediastinum

It is the widest of all mediastinum.

Boundaries: It is bounded by the pericardial sac and laterally limited by the mediastinal pleura.

Contents

i. Heart, enclosed within the pericardium
ii. Ascending aorta
iii. Left and right coronary arteries
iv. Lower one-half of the SVC
v. Arch part of the azygos vein
vi. Pulmonary trunk and its divisions into right and left pulmonary arteries
vii. Bifurcation of trachea
viii. Right and left pulmonary veins
ix. Right and left bronchi
x. Right and left phrenic nerves
xi. Pericardiophrenic vessels
xii. Deep cardiac plexuses (right and left)
xiii. Tracheobronchial lymph nodes.

Posterior Mediastinum

Boundaries

Anteriorly: From above downwards:

i. Tracheal bifurcation
ii. Pulmonary vessels
iii. Posterior aspect of the pericardium

JAYPEE BROTHERS

iv. The upper surface of the posterior part of the diaphragm.

Posteriorly: T5 to T12, with their intervertebral disks and anterior longitudinal ligament.

Superiorly: An imaginary horizontal line.

Inferiorly: The diaphragm.

Laterally: Mediastinal pleura.

Contents (Fig. 4.7)

Arteries: Descending thoracic aorta with its branches.

a. Posterior intercostal arteries on each side
b. The subcostal arteries on each side
c. The left bronchial arteries
d. Esophageal branches (4-5 in numbers)
e. Pericardial branches
f. Mediastinal branches (for lymph nodes and areolar tissues)
g. Superior phrenic arteries.

Lymphatics: Thoracic duct and posterior mediastinal lymph nodes.

Tube: Esophagus (thoracic part).

Veins: Azygos vein, hemiazygos vein, accessory hemia-zygos vein and some posterior intercostal veins.

Nerves: The nerves are described below:

i. Right and left vagus nerves
ii. Sympathetic chain, forming splanchnic nerves, given below.
   a. *Greater splanchnic nerves:* By the union of 5th to 9th or 10th thoracic sympathetic ganglia.
   b. *Lesser splanchnic nerves:* By the union of 9th and 10th thoracic sympathetic ganglia.
   c. *Least splanchnic (or renal) nerve:* By the lowest thoracic sympathetic ganglion.

CLINICAL ANATOMY

1. **Mediastinitis:** Structures of the mediastinum are embedded by loose connective tissue which is continued above to the root of the neck, so a deep infection from the neck spread into the thorax producing mediastinitis
2. **Mediastinal tumors or cysts:** A tumor of the lung can easily spread to involve the mediastinal lymph nodes which may produces following results:
   a. Compress the left recurrent laryngeal nerve, produces hoarseness of voice
   b. A cyst or tumor may partially occlude the SVC produces congestion of the vein of the upper part of the body

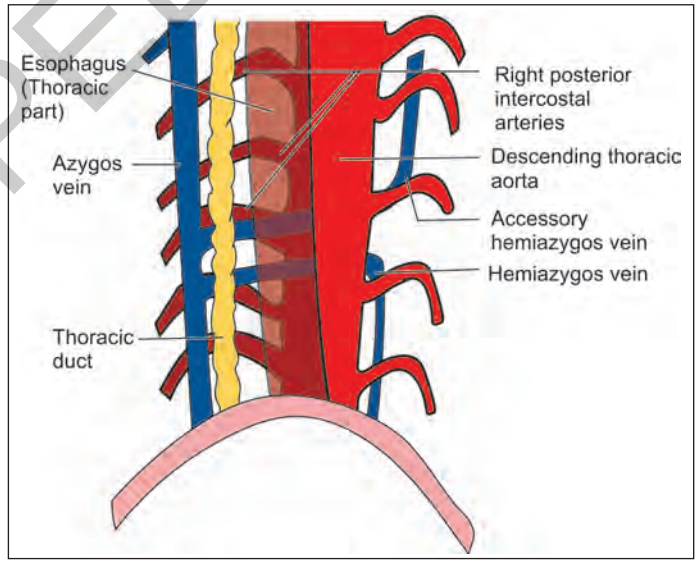

Fig. 4.7 Contents of posterior mediastinum

JAYPEE BROTHERS

c. It may also press on the sympathetic trunks, phrenic nerves, trachea, bronchi and esophagus.

3. Any growth in the mediastinum tends to spread towards right side due to the dead space present in the right side for the expansion of thin walled large veins present at the right side.
4. **Spread of infection:**
   a. Any infection from retropharyngeal space may extend into the superior mediastinum. As this space is continuous below with the superior mediastinum.
   b. Pretracheal fascia is continuous below with the fibrous pericardium, so infection from the neck can extends to anterior mediastinum.
   c. Infection between the pretracheal and prevertebral fasciae of the neck may descend to superior mediastinum also to the posterior mediastinum.
5. **Mediastinoscopy:** It is a diagnostic procedure to collect the sample of tracheobronchial lymph nodes.

Procedure

A small incision is made on the midline just above the jugular notch and is explored down to the region of the bifurcation of the trachea.

PERICARDIUM

Definition

Pericardium is a fibroserous sac, which covers the heart and roots of the great vessels.

Shape

Conical.

Situation

In the thoracic cavity, forming the middle mediastinum, opposite the body of sternum with the 2nd to 6th costal cartilages.

Vertebral Level

In between the bodies of T5 to T8 vertebrae.

Layers of Pericardium (Fig. 4.8)

Two Layers

i. Outer layer/fibrous pericardium
ii. Inner layer/serous pericardium

The heart lies within the fibrous pericardium, but outside the serous pericardium.

Outer Layer/Fibrous Pericardium

Attachments

Above: Its apex is fused with the walls of the external coat of ascending aorta and pulmonary trunk and is continuous with the pretracheal layer of the deep cervical fascia.

Below: Its base is attached to the central tendon of the diaphragm and a part of musculature of the left part of the diaphragm.

In front: It is attached with the back of sternum by the superior and inferior bands of sternopericardial ligament.

Relations

Anteriorly:

i. Anterior chest wall but separated by anterior margins of both lungs and pleurae
ii. Below the left 4th costal cartilage, pericardium is directly in contact with the left half of lower two pieces of the body of sternum
iii. Before puberty sometimes remains of the thymus gland.

Posteriorly:

i. Right and left bronchi
ii. Esophagus
iii. Esophageal plexus of nerves
iv. Descending thoracic aorta
v. Thoracic duct
vi. Azygos vein
vii. Hemiazygos veins
viii. Posterior part of the mediastinal surfaces of lungs.

Laterally:

i. Cardiac impressions of lungs, but separated by mediastinal pleura
ii. Phrenic nerves
iii. Pericardiophrenic vessels.

JAYPEE BROTHERS

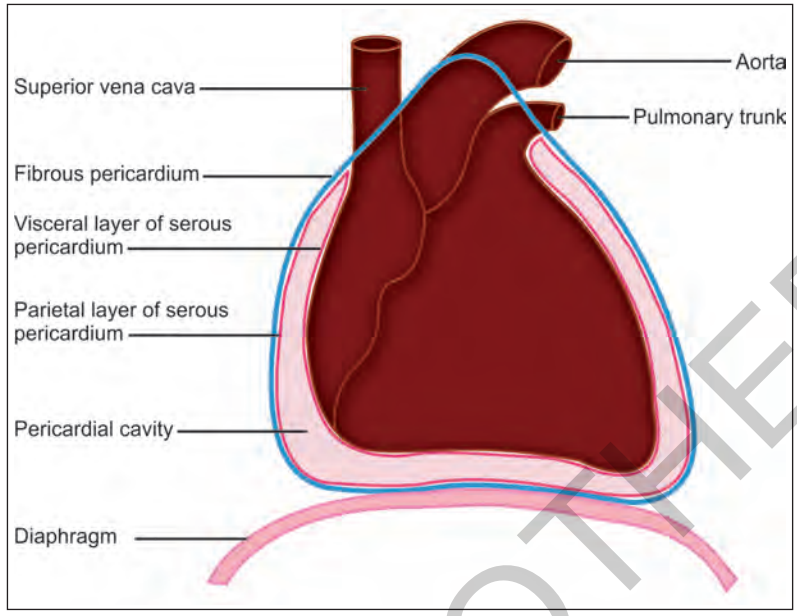

Fig. 4.8 Layers of pericardium

Inferiorly:
i. The diaphragm
ii. The liver(left lobe)
iii. Fundus of stomach.

Structures Piercing the Fibrous Pericardium

i. Ascending aorta
ii. Superior vena cava
iii. Inferior vena cava
iv. Right and left pulmonary arteries
v. Four pulmonary veins (2 from each lung).

Functions

i. It keeps the heart in position
ii. Prevents over-distension of the heart
iii. Minimizes friction during action of the heart.

Inner Layer/Serous Pericardium

i. The inner layer or serous pericardium is thin, double layered closed sac, lies within the fibrous pericardium
ii. The two layers of the serous pericardium are continuous with each other at the roots of the great vessels.

Subdivisions of Serous Pericardium

1. ***Parietal layer:*** It blends with the inner surface of the fibrous pericardium.
2. **Visceral layer/epicardium:**
   i. This layer fused to the heart and the roots of the great vessels, except along the sulci, where it is separated from heart by the blood vessels
   ii. In between the parietal and visceral layers the serous pericardium forms a cavity known as pericardial cavity, which is filled with a thin layer serous fluid.

Sinuses of Pericardium (Fig. 4.9)

Transverse sinus and oblique sinus.

Transverse Sinus

Boundaries

Anteriorly:
a. Ascending aorta
b. Pulmonary trunk.

Posteriorly: Intrapericardial part of superior vena cava.

Superiorly: Bifurcation of pulmonary trunk.

Inferiorly: Upper surface of left atrium.

On each side: It opens into the pericardial cavity.

JAYPEE BROTHERS

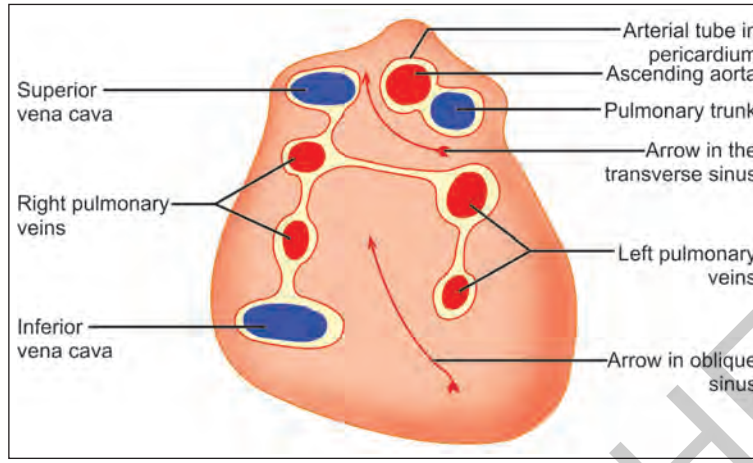

Fig. 4.9 Sinuses of the pericardium showing the boundaries

Oblique Sinus

It is closed from all sides except below.

Situation: Behind the left atrium.

Shape: Inverted `J`- shaped

Boundaries

Anteriorly: Left atrium.

Posteriorly: Parietal pericardium.

To the right:

a. Right pulmonary veins
b. Inferior vena cava.

To the left: Left pulmonary veins.

Superiorly: Upper margin of the left atrium.

Below and to the left: It opens into the pericardial cavity

Arterial supply

1. Fibrous and parietal pericardia supplied by the branches of:
   i. Internal thoracic arteries
   ii. Pericardial branches of descending thoracic aorta
   iii. Musculophrenic arteries.
2. Visceral layer supplied by the coronary arteries.

Venous drainage

1. Fibrous and parietal pericardia drain into:
   i. Azygos system
   ii. Internal thoracic vein
2. Visceral layer drain into coronary sinus.

Lymphatic Drainage: Lymph vessels drain into the mediastinal lymph nodes and some directly enters into the thoracic duct.

Nerve supply

1. **Fibrous and parietal pericardia:** Phrenic nerves
2. **Visceral layer:**
   i. Parasympathetic—vagus nerves
   ii. Sympathetic nerves via the coronary plexus.

CLINICAL ANATOMY

1. **Aspiration of pericardial fluid:** Pericardial fluid is aspirated by pricking the needle through the left 5th or 6th intercostal space close to the sternum to avoid injury to the internal thoracic artery or through the left costoxiphoid angle.
2. **Pericardial cavity distension:** If pericardial fluid accumulated rapidly, it disturbs the heart function. But if it accumulates gradually heart function is tolerated.

JAYPEE BROTHERS

HEART

Definition

Heart is a conical, hollow muscular organ, consisting of four chambers, covered by pericardium situated within the middle mediastinum and acts as a central pumping organ of cardiovascular system (the Greek name for the heart is cardia).

Measurements

Length

12 cm (from base to apex).
Transversely: 8 to 9 cm (at its broadest part).
Anteroposteriorly: 6 cm.

Weight

Male	-	280 to 340 gm
Average	-	300 gm
Female	-	230 to 280 gm
Average	-	250 gm

Weight in percent *According to sex*

Male	-	0.45 percent of the body weight
Female	-	0.40 percent of the body weight.

Shape

Somewhat conical or pyramidal.

Situation

The heart is situated obliquely behind the body of the sternum and adjoining parts of the costal cartilages, its one-third part lies to the right and two-thirds to the left of the median plane.

External Features (Fig. 4.10)

Borders of the Heart

1. **Superior border:** It is slightly oblique, formed by the two atria, mainly by the left atrium.
2. **Inferior border (acute margin):**
   i. It is a sharp nearly horizontal border extending from opening of the inferior vena cava to the apex of the heart
   ii. This border is mainly formed by the right ventricle and a small part of it near the apex is formed by the left ventricle
   iii. Close to the apex, presents a notch known as apical notch or incisura.

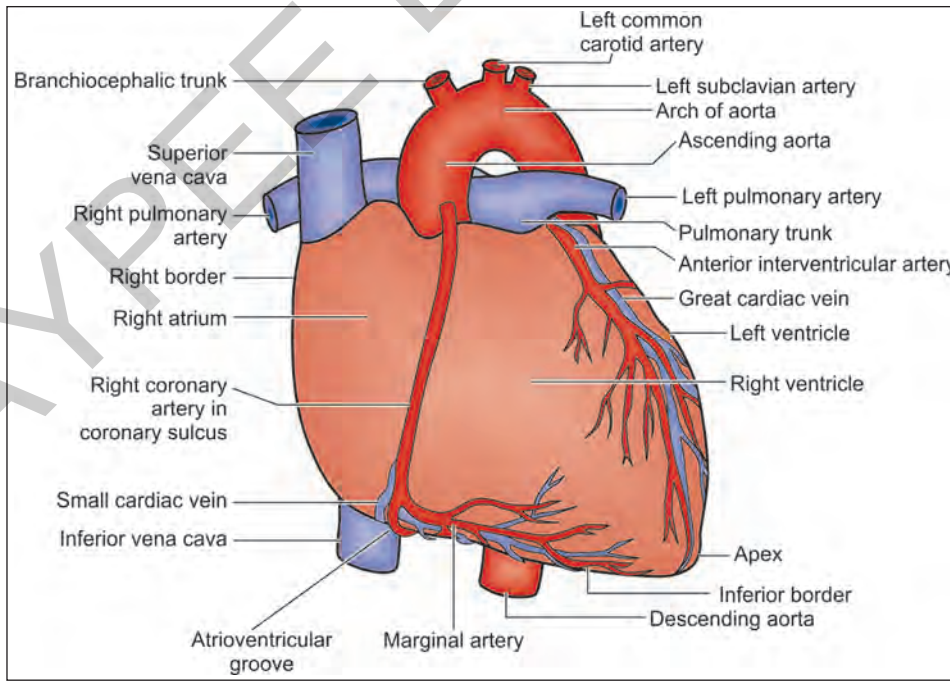

Fig. 4.10 Heart with its great vessels

JAYPEE BROTHERS

Importance of Apical Notch

i. Here anterior and posterior interventricular grooves meet
ii. Near to it, anastomosis takes place between following arteries:
   a. Posterior interventricular branch of right coronary artery
   b. Anterior interventricular branch of left coronary artery
   c. Right and left marginal arteries.

3. **Right border:** It is nearly vertical and is formed by the right atrium.
4. **Left border (obtuse margin):**
   i. This border is oblique and convex border
   ii. It separates the sternocostal and left surfaces
   iii. It is mainly formed by the left ventricle, and partly by the left auricle.

Surfaces of the Heart

Anterior or sternocostal surface

Direction: This surface facing forwards and upwards.

Formation

i. Anterior surface of the right atrium and its auricle
ii. A small part of the left auricle
iii. Anterior surface of the right ventricle (two-thirds)
iv. Anterior surface of the left ventricle (one-third).

Features

i. Anterior part of the atrioventricular groove:
   a. It passes downwards and to the right between the right atrium and right ventricle
   b. It lodges the trunk of the right coronary artery and is crossed by the anterior cardiac vein.

ii. Anterior interventricular groove:
   a. This groove passes downwards and parallel to the left border of the heart
   b. It ends at apical notch on the inferior border of the heart
   c. It indicates the site of anterior attachment of the interventricular septum
   d. It lodges the anterior interventricular branch of the left coronary artery and great cardiac vein.

Relations

i. Covered by the pericardium
ii. Posterior surface of the body of the sternum, and 3rd to 6th costal cartilages of both sides
iii. Anterior borders of both lungs and pleurae, except a part lies behind the cardiac notch of the left lung
iv. This uncovered area, the pericardium comes in direct contact with anterior chest wall and dull on percussion, clinically this area is known as area of superficial cardiac dullness.

Inferior or diaphragmatic surface

Direction: It is flat, rests on the central tendon and a small part of the left muscular part of the diaphragm, it slopes downwards and forwards a little towards the apex.

Formation

i. Two-thirds by the left ventricle
ii. One-third by the right ventricle.

Features

Posterior interventricular groove:
   a. It is traversed obliquely and ends at the apical notch
   b. It indicates the posterior attachment of the interventricular septum
   c. It lodges the posterior interventricular branch of the right coronary artery, middle cardiac vein, and anastomosis between the interventricular branches of both coronary arteries

Relations

i. Pericardium
ii. Central tendon and a small left muscular part of the diaphragm
iii. Cardiac impression of the liver and fundus of stomach, below the diaphragm.

Left surface

Direction: It is facing upwards, backwards and to the left.
Formation: It is mostly formed by the left ventricle and partly by the left atrium and its auricle.

JAYPEE BROTHERS

HUMAN ANATOMY

for Students

Salient Features

- Covers human anatomy in a very attractive and planned way
- Covers syllabi of all universities imparting education in health science field
- Brings up-to-date information on human anatomy, useful for the medical students, postgraduate aspirants and professionals
- Clinical anatomy after each description is really worth appreciating
- Text has been arranged in small classified parts to remember and recall easily
- Adequately illustrated with simple line diagrams and photographs of dissected specimens
- Saves the valuable time of the students and also relieves their anxiety and tension of the examination
- Oral questions and answers have been rearranged and updated for different universities.

Byas Deb Ghosh is a professor of anatomy, DKMMHMC, Aurangabad, Maharashtra, India. He is a member of Anatomical Society of India (West Bengal Chapter), examiner to Government of West Bengal and Maharashtra University of Health Sciences (MUHS), Nashik, Maharashtra, India. He delivered lectures on anatomy at different colleges and also attended several seminars on anatomy all over India.



After obtaining 31 years' teaching experience, he authored many books, such as *An Approach to Human Anatomy, Advanced Anatomy and Human Anatomy for Students*.

Shelving
Recommendation
ANATOMY

Available at all medical book stores
or buy directly from Jaypee Brothers through online shopping
at www.jaypeebrothers.com

JAYPEE BROTHERS
Medical Publishers (P) Ltd.
www.jaypeebrothers.com

ISBN 978-93-5025-942-9
9 789350 259429