THIRD EDITION

OPHTHALMIC

Diagnosis & Treatment

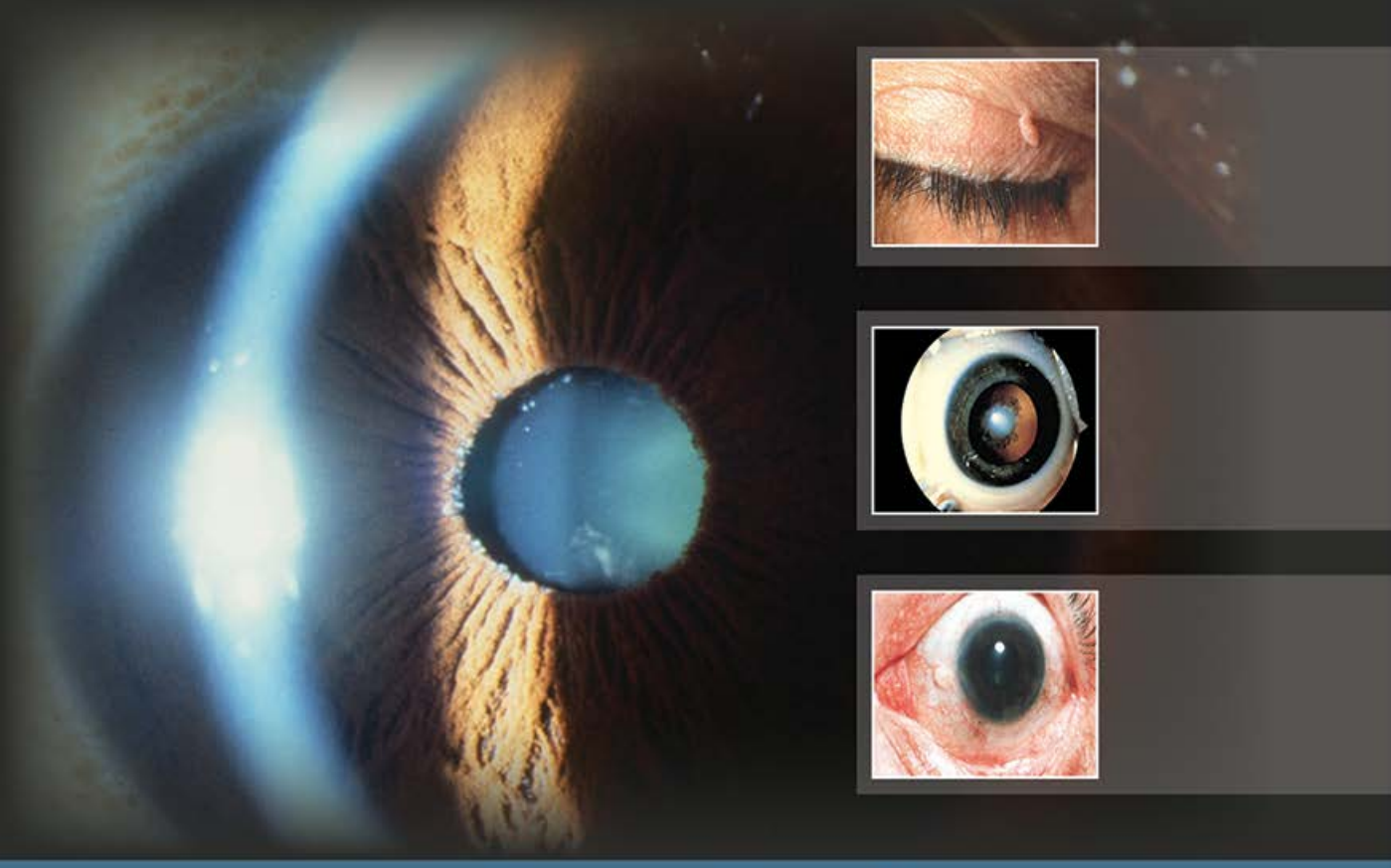

Myron Yanoff

Prathima Thumma
Yelena Doych
Arjun Dirghangi
Amanda Lehman
Robert Spector
Raza Shah

JAYPEE

Contents

Contents by Specialty xvii
How to use this book 1

A

Acute Posterior Multifocal Placoid Pigment Epitheliopathy (363.15) 2
Acute Retinal Necrosis (363.13) 6
AIDS-Related Ocular Manifestations (042) 8
Albinism (270.2) 14
Amblyopia (368.0) 18
Anatomically Narrow Angle (365.02) 22
Angioid Streaks (363.43) 26
Anterior Ischemic Optic Neuropathy, Arteritic (Giant Cell Arteritis, Temporal Arteritis) (377.30) 30
Anterior Ischemic Optic Neuropathy, Nonarteritic (Idiopathic) (377.41) 34
Anterior Uveitis: Iritis (Acute 364.0, Chronic 364.1), Iridocyclitis (Acute 364.0, Chronic 364.1) 36
Asteroid Hyalosis and Synchysis Scintillans (379.22) 40

B

Bacterial Endophthalmitis (360.0) 42
Binocular Vision Disorders (368) 46
Blepharitis (373.0) and Blepharoconjunctivitis (372.2) 48
Blepharophimosis Syndrome (374.46) 50

C

Cataract, Congenital (743.30) 52
Cataract, Secondary to Ocular and Other Complications (366.3) 56
Cataract, Traumatic (366.22) 60
Cataract, After (366.53) 64
Cataract, Age-Related (Senile) (366.15) 68
Cataract, Infantile, Juvenile, and Presenile (366.0) 72
Cavernous Sinus Syndrome (Cavernositis 607.2) 76

JAYPEE BROTHERS

Chemical Burns (941.02) 78
Chiasmal Syndrome (377.5) 82
Chorioretinitis (363.0) 86
Chorioretinopathy, central serous (362.41) 90
Choroid Dystrophies (363.5) 94
Choroidal Detachment (after filtration surgery) (363.70) 98
Choroidal Rupture (363.63) 102
Commotio Retinae (Berlin's Edema) (921.3) 104
Conjunctival Degenerations: Pinguecula (372.51) and Pterygium (372.40) 106
Conjunctivitis, Acute (372.0) 110
Conjunctivitis, Chronic (372.1) 114
Corneal Abrasions (918.1) and Foreign Body (930.0) 118
Corneal Edema (371.24) 122
Cyclodeviations (378.33) 126

D

Dacryoadenitis (375.0) 128
Dacryocystitis [375.30 or 375.32 (Acute)] 132
Delayed Visual-System Maturation (369.20) 136
Dermatochalasis (374.87) 138
Diabetic Retinopathy (362.0) 142
Duane Syndrome (378.71) 146

E

Esotropia (378.0) 148
Exophthalmos, Noninfectious and Nonendocrine (376.3) 152
Exotropia (378.1) 156
Eyelid Ectropion (374.1) 160
Eyelid Entropion (374.0) 162
Eyelid Hemorrhage (374.81) 164
Eyelid Noninfectious Dermatoses (373.3) 168

JAYPEE BROTHERS

F

Foreign Body, Intraocular (871.6) 170
Fourth-Nerve Palsy (Trochlear) (378.53) 174
Fuchs' Heterochromic Iridocyclitis (364.21) 178

G

Glaucoma Associated with Congenital Anomalies (365.44) 180
Glaucoma Suspect: Open Angle with Borderline Findings, High Risk (365.05) and Low Risk (365.01) 184
Glaucoma Associated with Anterior-Chamber Anomalies (365.41) 186
Glaucoma Associated with Elevated Episcleral Venous Pressure (365.82) 188
Glaucoma Associated with Ocular Inflammation (365.62) 192
Glaucoma Associated with Ocular Trauma (365.65) 196
Glaucoma Associated with Other Anterior-Segment Anomalies (365.43) 200
Glaucoma Associated with Scleritis (365.62) and Episcleritis (379.0) 202
Glaucoma, Congenital (365.14) 206
Glaucoma, Phacolytic (365.51) 210
Glaucoma, Pigmentary (365.13) 212
Glaucoma, Primary Open-Angle (365.11) and Normal-Tension (365.12) 216
Glaucoma, Pseudoexfoliative (365.52) 220
Glaucoma, Pupillary Block Angle-Closure (365.2) 224
Glaucomatocyclytic Crisis (Posner-Schlossman Syndrome) (364.22) 228
Graves Disease (Thyroid Eye Disease, Graves Ophthalmopathy) (242.0) 230

H

Hypertension, Ocular (365.04) 234
Hypertensive Retinopathy (362.11) 236
Hyphema (361.41) 238

JAYPEE BROTHERS

I

Internuclear Ophthalmoplegia (378.86) 242
Iridocyclitis, Acute and Subacute (364.0) 246
Iris Atrophy, Essential or Progressive (Iridocorneal-Endothelial Syndrome) (364.51) 250

K

Keratitis (370.9) 252
Keratoconus (371.60) 256

L

Lattice Degeneration (362.63) 258
Leber's Hereditary Optic Neuropathy (377.39) 260
Leukokoria (360.44) 264

M

Macular Degeneration, Age-Related (362.5) 268
Macular Edema, Cystoid (Postoperative) (362.53) 274
Macular Hole, Idiopathic (362.83) 276
Macular Pucker and Idiopathic Preretinal Macular Fibrosis (362.56) 278
Marcus-Gunn (Jaw-Winking) Syndrome (374.73) 280
Mechanical Strabismus (378.60)—Brown, Fibrosis, and "Heavy Eye" Syndromes 282
Mechanical Strabismus (378.63), Blowout Fracture (802.6) and Graves' Dysthyroid Orbitopathy (242) 288
Microhyphema (364.41) 292
Monofixation Syndrome (378.34) 294
Myasthenia Gravis, Ocular (358.0) 298

N

Nasolacrimal Duct Obstruction, Congenital (375.22) 302
Nystagmus, Congenital (379.51) 306

JAYPEE BROTHERS

O

Oblique Muscle Dysfunctions and Dissociated Vertical Deviation (378.31) 308
Oculosympathetic Paresis (Horner's Syndrome) (337.9) 312
Ophthalmia Neonatorum (771.6) 316
Optic Neuritis (377.3) 320
Orbital Inflammation, Acute (376.0) 324
Orbital Inflammation, Chronic (376.1) 328

P

Pars Planitis (363.21) 332
Phacoanaphylactic Endophthalmitis (360.19) 334
Phakomatoses 336
Pseudoexfoliation of the Lens (366.11) 340
Pseudotumor Cerebri (Idiopathic Intracranial Hypertension) (348.2) 344

R

Refraction and Accommodation Disorders (367.0) 348
Retinal Artery Occlusion (362.31) 350
Retinal Degeneration, Peripheral Cystoid (362.62) 354
Retinal Detachment (361) 356
Retinal Dystrophies (362.70) 360
Retinal Vein Occlusion (362.35) 362
Retinitis Pigmentosa (362.74) 366
Retinopathy of Prematurity (362.21) 370
Rubeosis Iridis (364.42) and Neovascular Glaucoma (365.63) 376

S

Seventh-Nerve Palsy (Facial) (351.0) 380
Sixth-Nerve Palsy (Abducens) (378.54) 384
Skin Tumor, Benign (216.1) 388
Skin Tumor, Malignant (173.1) 392

JAYPEE BROTHERS

T

Third-Nerve Palsy (Oculomotor), Partial (378.51) and Complete (378.52) 396
Tonic Pupil (379.46) 400
Toxic Retinopathies (362.55) 402

U

Uveal Malignant Melanoma, Primary (190.6) 406
Uveitis Sympathetic (360.11) 412

V

Vitreous Detachment, Posterior (379.21) 416
Vitreous Hemorrhage (379.23) 418

Index *421*

JAYPEE BROTHERS

DIAGNOSIS

Definition

Any disease or condition of the eye or ocular adnexa that arises from a patient's underlying systemic acquired immunodeficiency syndrome (AIDS) infection or associated immunosuppression.

Synonyms

None

Symptoms

- Decreased vision, floaters, double vision
- Eye pain
- Facial rash
- Floaters
- Red eye
- Shadow.

Signs

Human immunodeficiency virus (HIV) retinopathy (noninfectious)

- Nerve fiber layer (NFL) and inner retinal hemorrhages
- Microaneurysms
- *Cotton-wool spot*: the most common manifestation of AIDS retinopathy.

Infectious Agents

Adnexa

- Herpes zoster ophthalmicus (HZO)
- Molluscum contagiosum.

Cryptococcus: papilledema, multiple choroiditis, meningitis, endophthalmitis.

Cytomegalovirus (CMV) retinitis: classic intraretinal hemorrhages with white infiltrates (*see* Fig. 1).

Granular form: "brush fire" appearance.

Hemorrhagic form: "tomato ketchup fundus".

Herpes retinitis [*acute retinal necrosis* (*ARN*) *or progressive outer retinal necrosis* (*PORN*)]: aggressive retinitis in which multiple white retinal infiltrates coalesce, leading to retinal detachment and visual loss (*see* retinal necrosis, acute).

Pneumocystis choroiditis: multiple, deep, yellow-orange lesions at the level of the choroid (*see* Fig. 2).

Toxoplasmosis: multifocal outer retinal lesions that spread quickly; normally, little vitreous inflammation is seen in immunocompetent patients; occurs in previously diagnosed patients (*see* Fig. 3).

Microsporidia: chronic keratoconjunctivitis.

Syphilis: plaque-like serous elevations in the posterior pole.

Differential Diagnosis

Cotton-wool spots: of diabetes, hypertension, ocular ischemia and vasculitis

Cause

HIV infection

Diagnosis continued on p. 10

JAYPEE BROTHERS

TREATMENT

Diet and Lifestyle

Compliance with highly active antiretroviral therapy (HAART).

Pharmacologic Treatment

For Cytomegalovirus Infection

- Intravenous (IV) therapy with ganciclovir, foscarnet or cidofovir
- Intravitreal ganciclovir implant (sustained-release device) placed in the pars plana of the eye
- Intravitreal injections of ganciclovir or foscarnet.

For Pneumocystis sp. Infection

Bactrim, pentamidine.

For Herpes Simplex or Zoster Infection

Aggressive treatment with IV acyclovir.

For Toxoplasmosis

Pyrimethamine, sulfa drugs or clindamycin.

Treatment Aims

- To control the infection with appropriate antiviral and antimicrobial agents
- To stabilize or improve vision
- To treat secondary complications (e.g. retinal detachment) with laser or surgery.

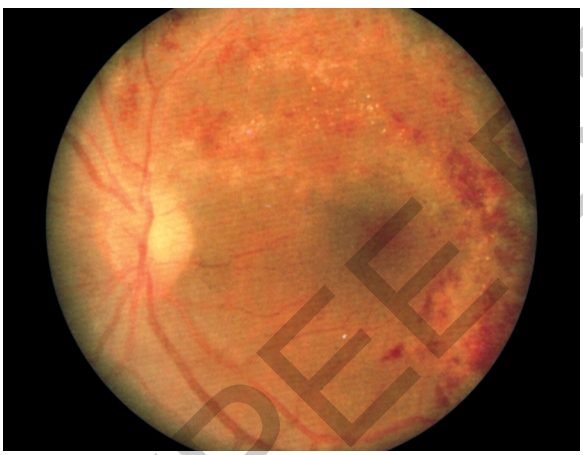

Fig. 1: Cytomegalovirus retinitis with the characteristic white perivascular retinal infiltrates and intraretinal hemorrhages or “pizza pie fundus”.

Treatment continued on p. 11

JAYPEE BROTHERS

DIAGNOSIS—cont'd

Tumors

- *Kaposi's sarcoma*: flat purplish lesion on the eyelid or conjunctiva similar to lesions seen on the skin; may be mistaken for subconjunctival hemorrhage
- Central nervous system (CNS) lymphoma
- Lymphomas
- Squamous cell carcinoma of the eyelid.

Neurologic Manifestations

- Cranial nerve palsies
- Papilledema
- Nystagmus
- Optic neuritis
- Visual field defects.

Investigations

Careful history: reviewing the patient's past medical history often gives clues to the cause.

CD4+ count: usually less than 50 cells/mm^3 when patients develop CMV retinitis.

Cryptococcus: high risk of CNS infection.

Progressive outer retinal necrosis: CD4+ count greater than 50 cells/mm^3.

Acute retinal necrosis: CD4+ count less than 50 cells/mm^3.

Pneumocystis jiroveci (previously P. carinii): CD4+ count less than 200 cells/mm^3.

Fluorescein angiography: helpful in differentiating retinal infections.

Computed tomography and magnetic resonance imaging scans: may be necessary for patients with CNS abnormalities.

Vitreous biopsy with analysis of polymerase chain reaction: helps distinguish herpes simplex from zoster and CMV when the clinical picture is not clear-cut.

Sequential fundus photographs: help monitor patients for response to therapy and evidence of disease progression.

Complications

- Visual loss
- Retinal detachment.

Medication-related

- *Cidofovir*: anterior uveitis and profound hypotony
- *Rifabutin (prophylaxis for atypical myobacterial infection)*: severe (sometimes bilateral) anterior uveitis.

Diagnosis continued on p. 12

JAYPEE BROTHERS

TREATMENT—cont'd

For Syphilis

High-dose IV penicillin for 10–14 days.

Cryptococcus

Intravenous amphotericin, IV itraconazole, vitrectomy and intravitreal amphotericin for endophthalmitis.

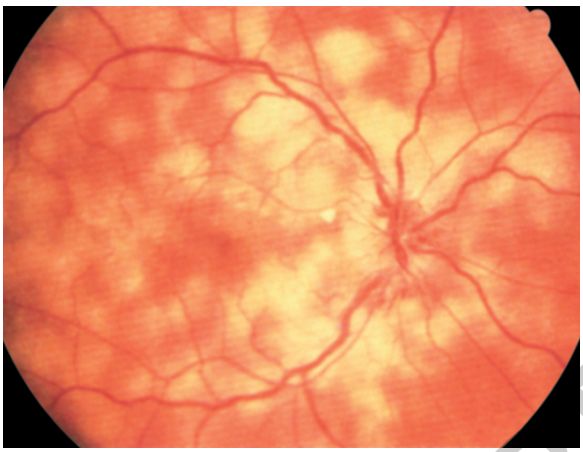

Fig. 2: *Pneumocystis* choroiditis showing deep choroidal, creamy yellow-orange infiltrates throughout the posterior pole.

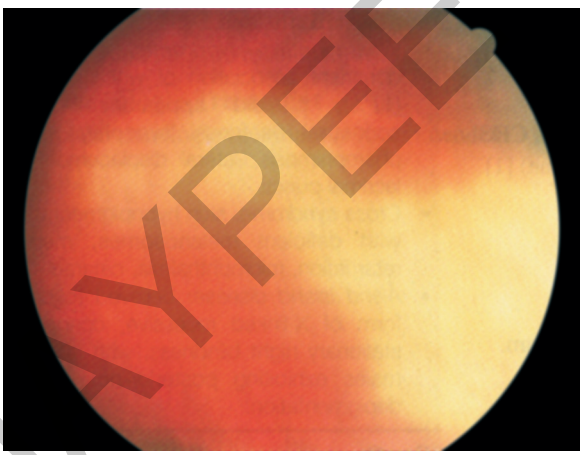

Fig. 3: Outer retinal toxoplasmosis in an AIDS patient showing the "brush fire" advancement of the infection.

Treatment continued on p. 13

JAYPEE BROTHERS

DIAGNOSIS—cont'd

Pearls and Considerations

- Dilated fundus examination (DFE) should be performed every 3 months in patients with a CD4+ count less than or equal to 50 cells/mm^3 because of the potential for asymptomatic CMV retinitis. Once the CD4+ count rises above 100 cells/mm^3, the risk of retinitis is small.
- Acquired immunodeficiency syndrome patients' complications should be treated cautiously with steroids because of the potential for further immunosuppression and infection
- Approximately 70–80% of AIDS patients will require treatment for an ocular complication at some time in their lives
- Cytomegalovirus is the most common severe and sight-threatening ocular infection in AIDS patients
- Infections of the cornea and adnexa are less common than intraocular infections in AIDS patients
- With HAART, many patients can reduce the detectable viral load to zero and can lead otherwise normal lives. Only when their immunity drops do they develop complications.

Referral Information

Variable and specific to the etiology of each complication.

JAYPEE BROTHERS

TREATMENT—cont'd

Microsporidia

Topical fumagillin up to every 2 hours initially, and then taper slowly.

Nonpharmacologic Treatment

Regular periodic ocular examinations (e.g. CD4+ count < 50, every 3 months).

JAYPEE BROTHERS

GENERAL REFERENCES

Copeland R, et al. (2006). Ocular manifestations of HIV. [online]. Available from www.emedicine.com. [Accessed July, 2012].

Holland GN, Levinson RD. Ocular infections associated with acquired immunodeficiency syndrome. In: Tasman W, Jaeger EA (Eds). Duane's Clinical Ophthalmology (CD-ROM). Philadelphia: Lippincott Williams & Wilkins; 2004.

Lightman S. HIV and the eye. London: Imperial College Press; 2000.

Moraes HV. Ocular manifestations of HIV/AIDS. Curr Opin Ophthalmol. 2002;13(6):397-403.

Rescigno R, Dinowitz M. Ophthalmic manifestations of immunodeficiency states. Clin Rev Allergy Immunol. 2001;20(2):163-81.

Rhee DJ, Pyfer MF (Eds). Acquired immunodeficiency syndrome (AIDS). The Wills Eye Manual. Philadelphia: Lippincott Williams & Wilkins; 1999. pp. 435-45.

OPHTHALMIC
Diagnosis & Treatment

This unique work provides current expert recommendations and treatments for common and uncommon conditions encountered by ophthalmologists, including

- Cataract and systemic and orbital disorders
- Corneal and external diseases
- Glaucoma
- Neuro-ophthalmic disorders
- Pediatric ophthalmic disorders
- Retinal and vitreous disorders

The book has been designed to permit rapid access of information, with topics listed alphabetically. In each chapter, essential information has been condensed into tabular summaries on two pages, with diagnostic details on the left and treatment details on the right.

Each condition features a definition, synonyms, common signs and symptoms, differential diagnosis, complications, treatment, and follow-up and management, as well as ICD-9 codes and images.

Written and edited by a team of experts led by Myron Yanoff, MD, Professor and Chairman, Department of Ophthalmology, Drexel University School of Medicine, Philadelphia, Pennsylvania, USA.

Shelving
Recommendations
OPHTHALMOLOGY
OPTOMETRY

ISBN 978-93-5025-952-8

9 789350 259528

Available at all medical bookstores
or buy directly from Jaypee Brothers
at www.jaypeebrothers.com

JAYPEE BROTHERS
Medical Publishers (P) Ltd.
www.jaypeebrothers.com