Basavaraj Subhashchandra Phulari

An Atlas on CEPHALOMETRIC LANDMARKS

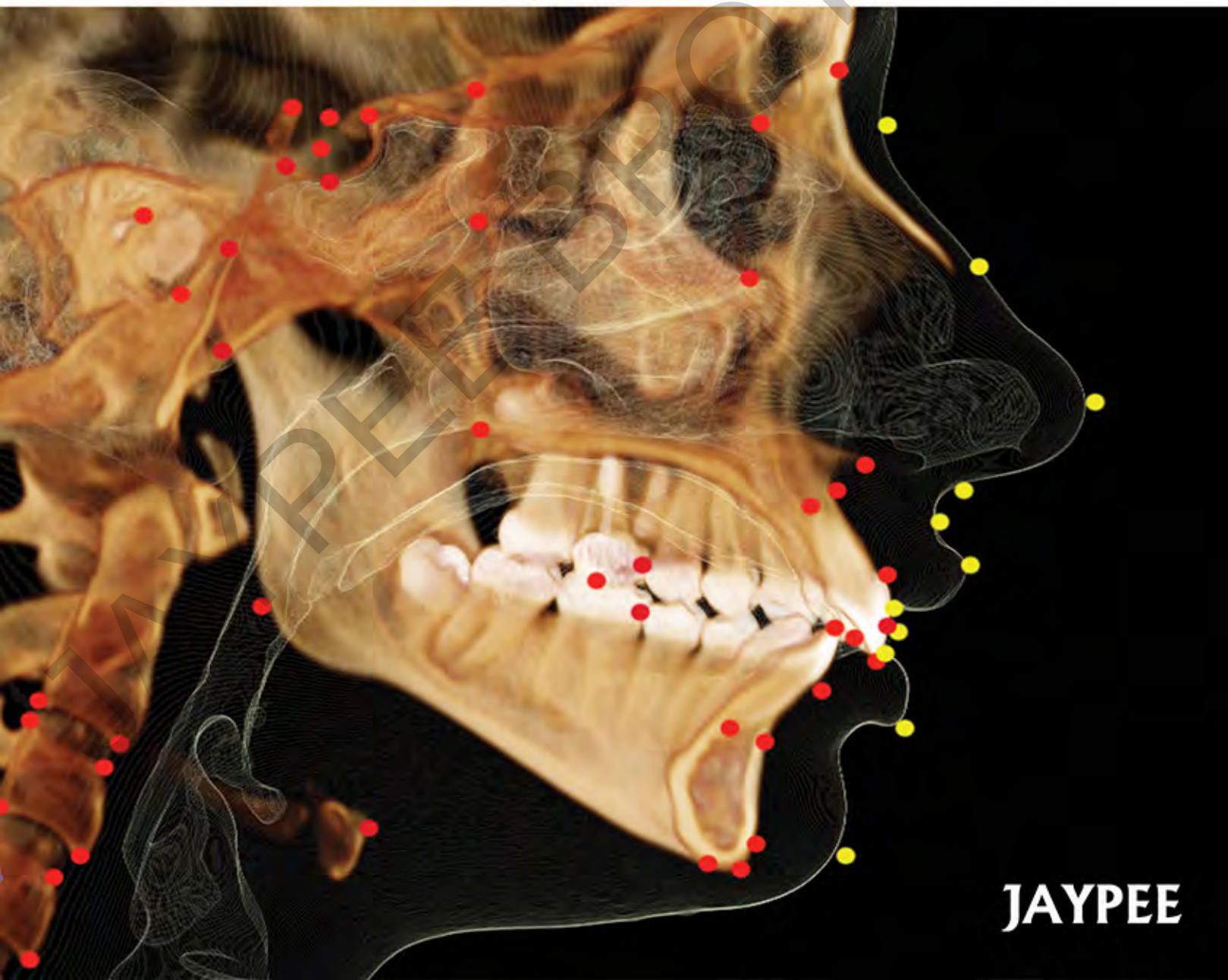

JAYPEE

JAYPEE BROTHERS

Contents

Section 1: Introduction and History

1. Cephalometry in Orthodontics 3

Technical Aspects 4
Cephalometric X-ray Tracing Techniques 4

Section 2: Classification of Cephalometric Landmarks

2. Classification of Cephalometric Landmarks 7

Classification of Cephalometric Landmarks (Points) 7

Section 3: Cephalometric Landmarks Related to Cranial Bones

3. Cephalometric Landmarks Related to Frontal Bone 15

Parts of Frontal Bone 15
Articulation of Frontal Bone 15
Cephalometric Landmarks (Points) on Frontal Bone 15
Radiographic Anatomy of Frontal Bone 15
Nasion 16
Supra-Orbitale 17
Roof of the Orbital Cavity 17
Frontonasal/Frontomaxillary Nasal Suture 18

4. Cephalometric Landmarks Related to Ethmoid Bone 21

Parts of Ethmoid Bone 21
Articulation of Ethmoid Bone 21
Cephalometric Landmarks (Points) on Ethmoid Bone 21
Temporale 21
Neck of Crista Galli 23
Medio-orbitale 23
Sphenoethmoidal Point 24
Ethmoidale 24

5. Cephalometric Landmarks Related to Nasal Bone 26

Articulation of Frontal Bone 26
Radiographic Anatomy of Nasal Bone 26
Nasion 26
Frontonasal/Frontomaxillary Nasal Suture 28
Rhinion 29

6. Cephalometric Landmarks Related to Temporal Bone 31

Articulation of Temporal Bone 31
Radiographic Anatomy of Temporal Bone 31
Cephalometric Landmarks (Points) on Temporal Bone 31
Porion 32
Zygomatic Arch 32
Mastiodale 33

7. Cephalometric Landmarks Related to Sphenoid Bone 35

Cephalometric Landmarks (Points) on Sphenoid Bone 35
Dorsum of Sella 36
Floor of Sella 37
Clinoidale 38
Spheno-Occipital Synchondrosis 39
Pterygoid Point 40
Sella 41
Sella Entrance 41
Sphenoethmoidal point 42
Pterygomaxillary Fissure 44

JAYPEE BROTHERS

8. Cephalometric Landmarks Related to Occipital Bone 46
Cephalometric Landmarks (Points) on Occipital Bone 46
Radiographic Anatomy of Occipital Bone 46
Basion 46
Opisthion 48
Bolton's Point 48
Spheno-Occipital Synchondrosis 50

9. Cephalometric Landmarks Related to Zygomatic Bone 52
Radiographic Anatomy of Zygomatic Bone 52
Cephalometric Landmarks (Points) on Zygomatic Bone 52
Orbitale 52
Temporale 54

Section 4: Cephalometric Landmarks Related to Facial Bones and Dentition

10. Cephalometric Landmarks Related to Maxilla 59
Cephalometric Landmarks (Points) on Maxilla 59
Anterior Nasal Spine 59
Point A 61
Prosthion 62
Posterior Nasal Spine 64
Pterygomaxillary Fissure 65
Key Ridge 66
Orbitale 67

11. Cephalometric Landmarks Related to Dentition 70
Incision Superius Incisalis 71
Incision Superius Apicalis 73
Incision Inferius Incisalis 74
Incision Inferius Apicalis 75
Anterior Point of Occlusion 76
Posterior Point of Occlusion 77
Maxillary Central Incisor 79
Maxillary First Molar 79
Mandibular Central Incisor 80
Mandibular First Molar 81
mi 82
ms 83

12. Cephalometric Landmarks Related to Mandible 85
Cephalometric Landmarks (Points) on Mandible 85
Parts of Mandible 85
Nerve Supply to Mandible 85
Articulations 86
Infradentale 86
Point B 87
Pogonion 88
Gnathion 89
dd 91
Menton 92
Gonion 93
Articulare 93
kk 94
Condylion 95

Section 5: Cephalometric Landmarks Related to Cervical Bones

13. Cephalometric Landmarks Related to Hyoid Bone 101
Parts of the Hyoid Bone 101
Radiographic Anatomy of Hyoid Bone 101
Cephalometric Landmarks (Points) on Hyoid Bone 101
Hyoid 101

14. Cephalometric Landmarks Related to Vertebrae 103
Radiographic Anatomy of Cervical Vertebrae 103
Cephalometric Landmarks on Cervical Vertebra 103
Cephalometric Landmarks (Points) Related to Cervical Vertebra 103
cv2ip 104
cv2ap 104
cv2ia 106
cv3sp 106

JAYPEE BROTHERS

cv3ip 107
cv3sa 107
cv3ia 109
cv4sp 109
cv4ip 110
cv4sa 110
cv4ia 112
cv5sp 112
cv5ip 113
cv5sa 113
cv5ia 115
cv6sp 115
cv6ip 116
cv6sa 116
cv6ia 118
Cervical Vertebrae as Indicators of Skeletal Maturity 118

Section 6: Cephalometric Landmarks Related to Pharynx

15. Cephalometric Landmarks Related to Pharynx 123

Nasopharynx 123
Oropharynx 123
Laryngopharynx 123
Cephalometric Landmarks (Points) on Pharynx 123
Anterior Nasal Spine, Posterior Nasal Spine and Pterygomaxillary Fissure 123
Anterior Pharyngeal Wall 123
Posterior Pharyngeal Wall 124
Superior Pharyngeal Wall 124
Tip of the Uvula 124
Point on the Oral Side of the Soft Palate 124
Point on the Pharyngeal Side of the Soft Palate 124
Upper Point of Tongue 124
Significance 124

Section 7: Soft Tissue Cephalometric Landmarks

16. Soft Tissue Cephalometric Landmarks 127

Soft Tissue Cephalometric Landmarks (Points) Related to Forehead 127
Soft Tissue Glabella 127
Soft Tissue Nasion 128
Nasal Crown 129
Pronasale 129
Point "T" 130
Alar Crease Junction 131
Subnasale 131
Soft Tissue Subspinale 133
Labrale Superius 134
Stomion 135
Labrale Inferius 136
Soft Tissue Submentale 136
Soft Tissue Pogonion 138
Soft Tissue Gnathion 139

Section 8: 3D Cephalometric Landmarks

17. 3D Cephalometric Landmarks 143

Vertex 143
Soft Tissue Nasion 143
Pronasale 144
Subnasale 144
Soft Tissue Subspinale 145
Labrale Superius 146
Stomion 146
Labrale Inferius 146
Soft Tissue Submentale 147
Soft Tissue Pogonion 147
Soft Tissue Gnathion 148
Orbitale 148
Zygomatic Prominence 149
Zygion 149
Condylion 149
Gonion 150
Ch 150
Cheilion 151
Alare 151
Exocanthion 151
Sella 152
Sella Entrance 153
Basion 153
Anterior Nasal Spine 154

JAYPEE BROTHERS

Section 9: PA Cephalometric Landmarks

18. PA Cephalometric Landmarks 159

Taking PA Cephalogram 160
Structures Involved in PA Cephalogram 160
Crista Galli 160
Top of Nasal Septum 161
NC 162
Zyg-Zygoma 162
Zygion 163
Zygomatic Arch 163
Zygomatic Suture Point 164
Jugal Process 164
Maxillare 165
Incision Superius Incisalis 165
Incision Superius Apicalis 166
Maxillary Molar 167
Maxillary First Molar 168
Cuspid 169
Incision Inferius Incisalis 169
Incision Inferius Apicalis 170
Incision Inferius Frontale 171
Mandibular First Molar 171
mi 172
Mandibular Molar 173
Menton 173
Articulare 174
Malare 174
Antegonial Tubercles 175
Antegonion 175

Section 10: SV Cephalometric Landmarks

19. SV Cephalometric Landmarks 179

Basion 179
Opisthion 179
Foramina Spinosa Points 180
Foramina Spinosum 180
Odontoid 181
Pterygomaxillary Fissure 182
Middle Cranial Fossa Points 182
Posterior Vomer Point 182
Posterior Cranial Vault Points 183
Angulare Point 184
Maxillary Apical Base Midline 185
Mandibular Dental Midline 185
Mandibular Apical Base Midline 186
First Molar Point 187
Gonion Point 187
Condylion Medialis 188
Condylion Lateralis 188
Condylion Anterioris 189
Condylion Posterioris 190

Section 11: Applications of Cephalometric Landmarks

20. Applications of Cephalometric Landmarks 193

Bjork Cephalometric Analysis 193
Coben Craniofacial and Dentition Cephalometric Analysis 194
Downs Cephalometric Analysis 195
Farkas and Coworkers Soft Tissue Cephalometric Analysis 196
Harvold Cephalometric Analysis 196
Holdaway Cephalometric Analysis 197
Legan and Burstone Soft Tissue Cephalometric Analysis 198
Rickett's Cephalometric Analysis 198
Sassouni Cephalometric Analysis 199
Di Paolo's Quadrilateral Analysis 200
Hasund (Bergen) Cephalometric Analysis 200

JAYPEE BROTHERS

Jarabak Cephalometric Analysis 201
Riedel Cephalometric Analysis 202
Schwartz Cephalometric Analysis 203
Wylie Cephalometric Analysis 203
Steiner's Cephalometric Analysis 204
Tweed's Cephalometric Analysis 205
Wit's Cephalometric Analysis 206
Basis Cephalometric Analysis 207
Cagliari Cephalometric Analysis 207
Chieti Cephalometric Analysis 208
McGann Cephalometric Analysis 209

Index 211

JAYPEE BROTHERS

SECTION 4

Cephalometric Landmarks Related to Facial Bones and Dentition

- Cephalometric Landmarks Related to Maxilla
- Cephalometric Landmarks Related to Dentition
- Cephalometric Landmarks Related to Mandible

JAYPEE BROTHERS

CHAPTER

10 Cephalometric Landmarks Related to Maxilla

The maxilla **(Fig. 10.1)** consists of a large hollow body that houses the maxillary sinus and the four prominent processes.

- The frontal process
- The zygomatic process
- The palatine process
- The alveolar process.

Cephalometric Landmarks (Points) on Maxilla

Cephalometric landmarks seen on the maxilla are as follows **(Table 10.1)**:

Table 10.1: Cephalometric landmarks related to maxilla

Cephalometric landmarks	*Abbreviation*	*Type*	*Origin*
Anterior nasal spine	ANS	Unilateral	Anatomic
Point A	A	Unilateral	Anatomic
Anterior point of maxilla	APMax	Unilateral	Anatomic
Prosthion	Pr	Unilateral	Anatomic
Posterior nasal spine	PNS	Unilateral	Anatomic
Pterygomaxillary fissure	• Ptm • PTM • PTMS	Bilateral	Anatomic
Key ridge	KR	Unilateral	Anatomic
Orbitale	Or	Bilateral	Anatomic

Anterior Nasal Spine

Abbreviation

ANS–Anterior nasal spine is abbreviated using English alphabets and is expressed as capital or upper case A, N and S, written continuously without any space between the alphabets.

Definition

Anterior nasal spine **(Figs 10.2A to D)** is the tip of bony anterior nasal spine in the midline or median plane.

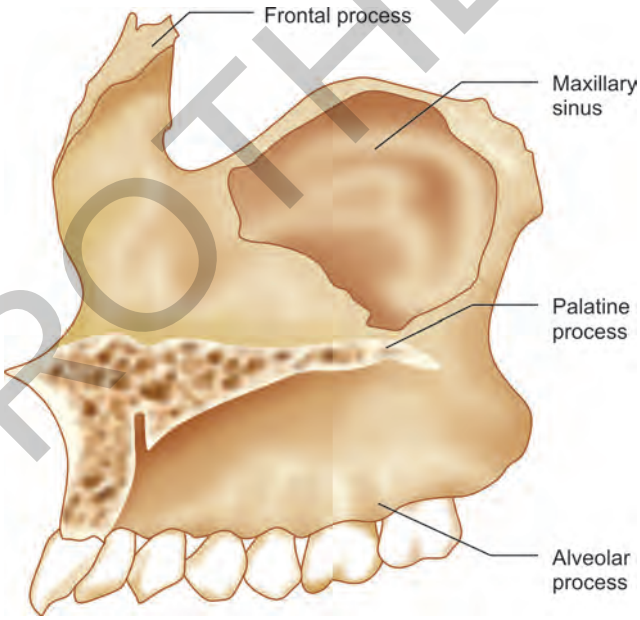

Figure 10.1: Maxillary bone

According to Viken Sassouni

The most anterior point of the nasal floor tip of pre-maxilla on mid-sagittal plane.[1]

According to B Holly Broadbent

Sharp median process formed by the forward prolongation of the anterior aperture of the nose.[2]

According to TM Graber

The tip of the anterior nasal spine as seen on the X-ray film in norma lateralis.[3]

According to Robert E Moyers

The most anterior point on the maxilla at the level of the palate. The ANS is of limited use for analysis in the posterior-

JAYPEE BROTHERS

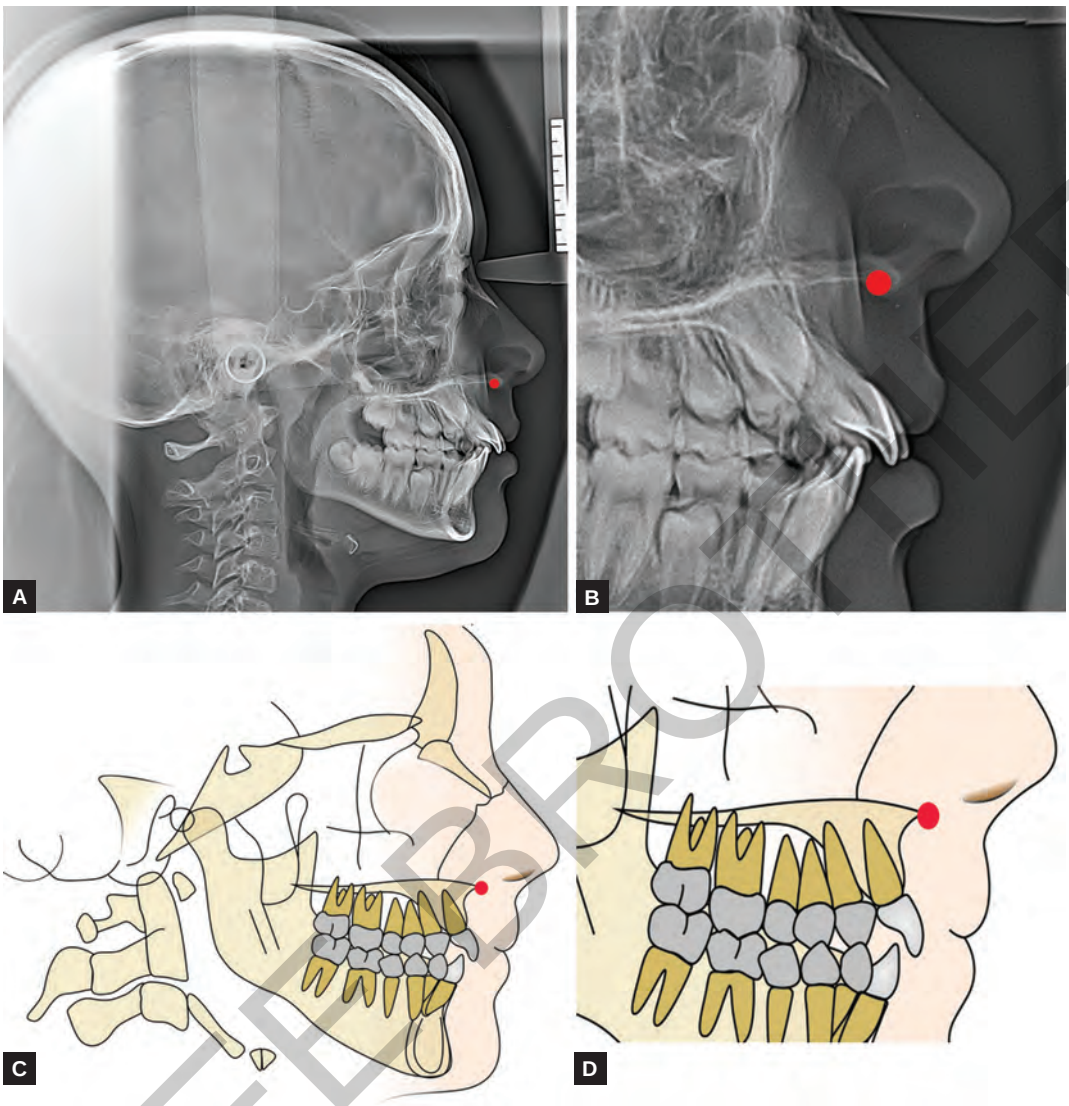

Figures 10.2A to D: (A) Anterior nasal spine on lateral cephalogram; (B) Magnified image showing anterior nasal spine on the lateral cephalogram; (C) Anterior nasal spine on graphic illustration; and (D) Magnified image of Anterior nasal spine on graphic illustration

anterior projection as the actual spine often cannot be seen and its location varies considerably according to radiographic exposure.[4]

Type

Anterior nasal spine is a unilateral, hard tissue cephalometric landmark.

Origin

Anterior nasal spine is an anatomic hard tissue cephalometric landmark.

Tracing of Anterior Nasal Spine on Lateral Cephalogram

There is an individual variation exists in length and width of ANS. In some individuals ANS are long and thin; while in other are short and thick.

Radiographic Appearance

- ANS appears slightly posterior to the anatomic spine.
- *In cases with thin ANS*: In such cases, on the cephalogram, ANS will be unclear because it can superimpose by nasal cartilage.
- *In cases with thick ANS*: In such cases, on the cephalogram, ANS is clear and will be ease in tracing.

JAYPEE BROTHERS

Significance (Ref to Chapter 20)

Anterior nasal spine is used as one of the reference points in the construction of occlusal plane and is used for the assessment of horizontal growth pattern using FH-palatal plane angle (ANS-PNS).

Point A

Abbreviation

Point A: Point A is abbreviated using English alphabets and is expressed as A itself.

Definition

Point A **(Figs 10.3A to D)** is the deepest point on the curved bony outline between the anterior nasal spine (ANS) and prosthion (Pr).

According to Willian B Downs

The deepest midline point on the premaxilla between the anterior nasal spine and prosthion.[5]

According to Robert M Ricketts

Deepest point on the curve of the bone between the anterior nasal spine and dental alveolus. Also termed SS or subspinale (below the spine).[6]

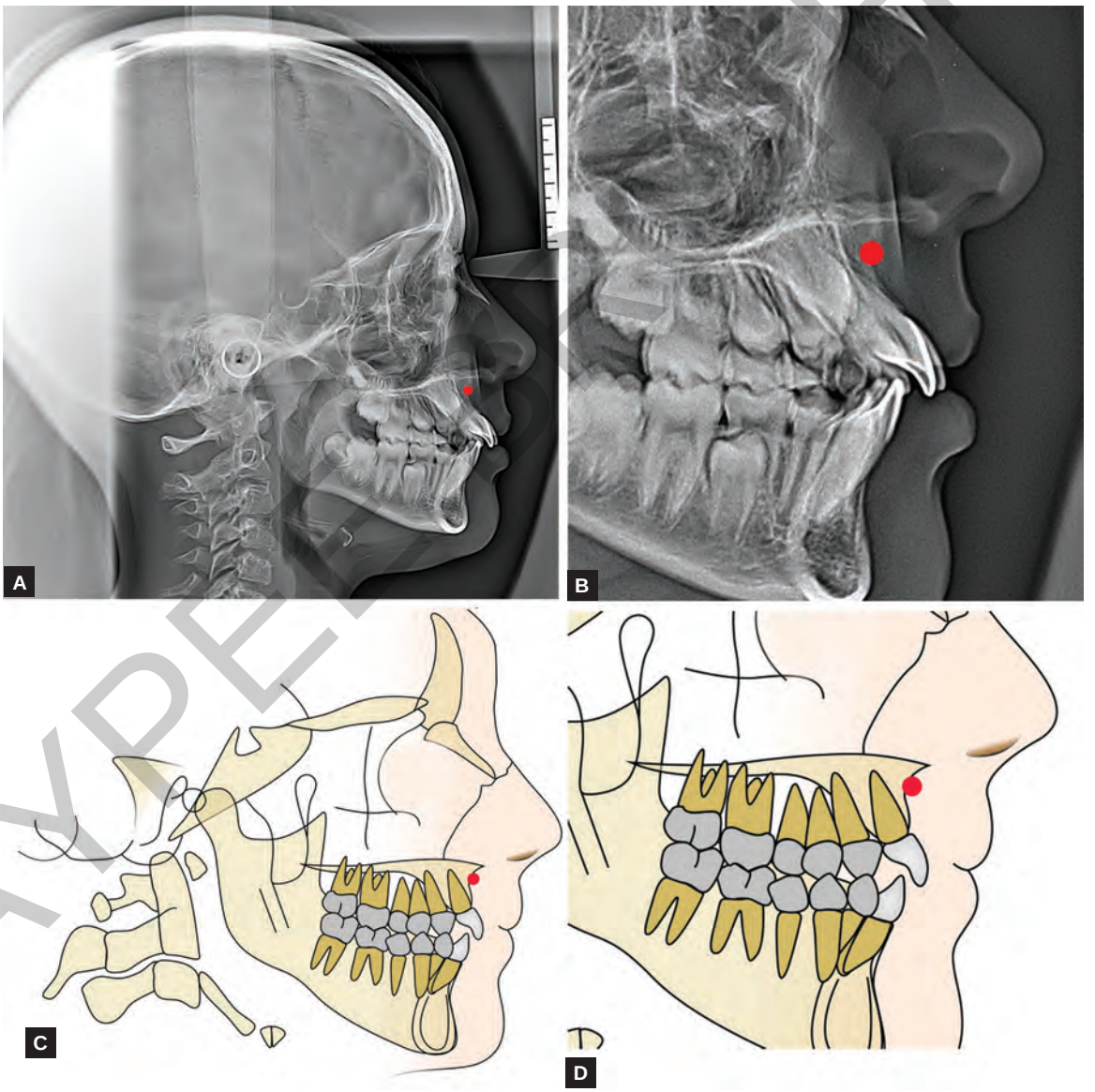

Figures 10.3A to D: (A) Point A on lateral cephalogram; (B) Magnified image showing point A on the lateral cephalogram; (C) Point A on graphic illustration; and (D) Magnified image of point A on graphic illustration

JAYPEE BROTHERS

According to Viken Sassouni

Deepest point on midsagittal plane between ANS and prosthion, mesially around the level of and anterior to the apex of the upper central incisors.[1]

According to TM Graber

The most posterior point on the pre-maxilla above prosthion and immediately lateral to the contour of projection of the anterior nasal spine. It is the junction of the alveolar and basal of the maxilla.[3]

According to Alex Jacobson and W Caufield

Using a line perpendicular to FH locate the most posterior point in the concavity between ANS and maxillary alveolar process.[7]

Or

The most posterior midline point in the concavity between the ANS and prosthion (The most inferior point on the alveolar bone overlying the maxillary central incisor).

According to Robert E Moyers

The most posterior point on the curve between ANS and PR "A" point usually is found approximately 2 mm anterior to the apices of the maxillary central incisor roots. A is not an anatomic point, of course.[4]

According to JR Jarabak

Maxillary denture base, point A is 2 mm labial to the apices of the central incisors.[8]

Type

Point A is a unilateral, hard tissue cephalometric landmark.

Origin

Point A is an anatomic hard tissue cephalometric landmark.

Tracing Procedure for Point A

- First trace the palatal bone, the anterior nasal spine, the marginal bone of the alveolar process and the anterior facial surface of the alveolar process.
- Thereafter, trace the outline of maxillary central incisor which includes tracing of incisal edge, apex of the root outer surface of the crown and root of maxillary central incisor.
- *Note*:The most important factor which helps in location of point A is that it is at almost the same height as the apex of the incisor.
- To establish A point, draw a line between ANS and prosthion. Then draw a line parallel to the ANS–Pr line, tangent to the deepest point between ANS and Pr. This is point A.

Significance (Ref to Chapter 20)

Point A is used as one of the reference points in the construction of angles and planes for the assessment of the following:

- Relationship of maxilla to cranial base is assessed using SNA angle.
- Maxillo-mandibular relationship with anterior cranial base is assessed using ANB angle.
- Inclination upper incisors are assessed using NA-Upper incisor angular and NA-Upper incisor linear.
- Point A is useful indicator of the anteroposterior relationship between the basal bone of the maxilla and the malocclusion.
- In Mc Namara cephalometric analysis, anteroposterior orientation of the maxilla to the cranial base is assessed by the linear distance between nasion perpendicular and point A. An anterior position of point A is a positive value and a posterior position of point A is a negative value.
- Mid facial length is measured from condylion to Point A in McNamara analysis.
- In Mc Namara cephalometric analysis, method of determining of position of maxillary incisor relative to point A. Draw vertical line through the nasion called NP (Nasion perpendicular) and A vertical line constructed through the point A parallel to the Nasion perpendicular line called the parallel to nasion perpendicular through point A (PNP). The anteroposterior distance from maxillary incisor to point A.
- In Mc Namara cephalometric analysis, to determine the anteroposterior position of the mandibular incisors, the distance is measured between the edge of the incisor and a line drawn from point A to Pog. In a well-balanced face, this distance should be 13 mm.

Prosthion

Abbreviation

Pr: Prosthion is abbreviated using English alphabets and is expressed as capital letter or upper case P followed by small letter or lower case r and is written continuously without any space between the alphabets.

Definition

Prosthion **(Figs 10.4A to D)** is the lowermost anterior point of alveolar process of pre-maxilla in the midline between two maxillary central incisors.

JAYPEE BROTHERS

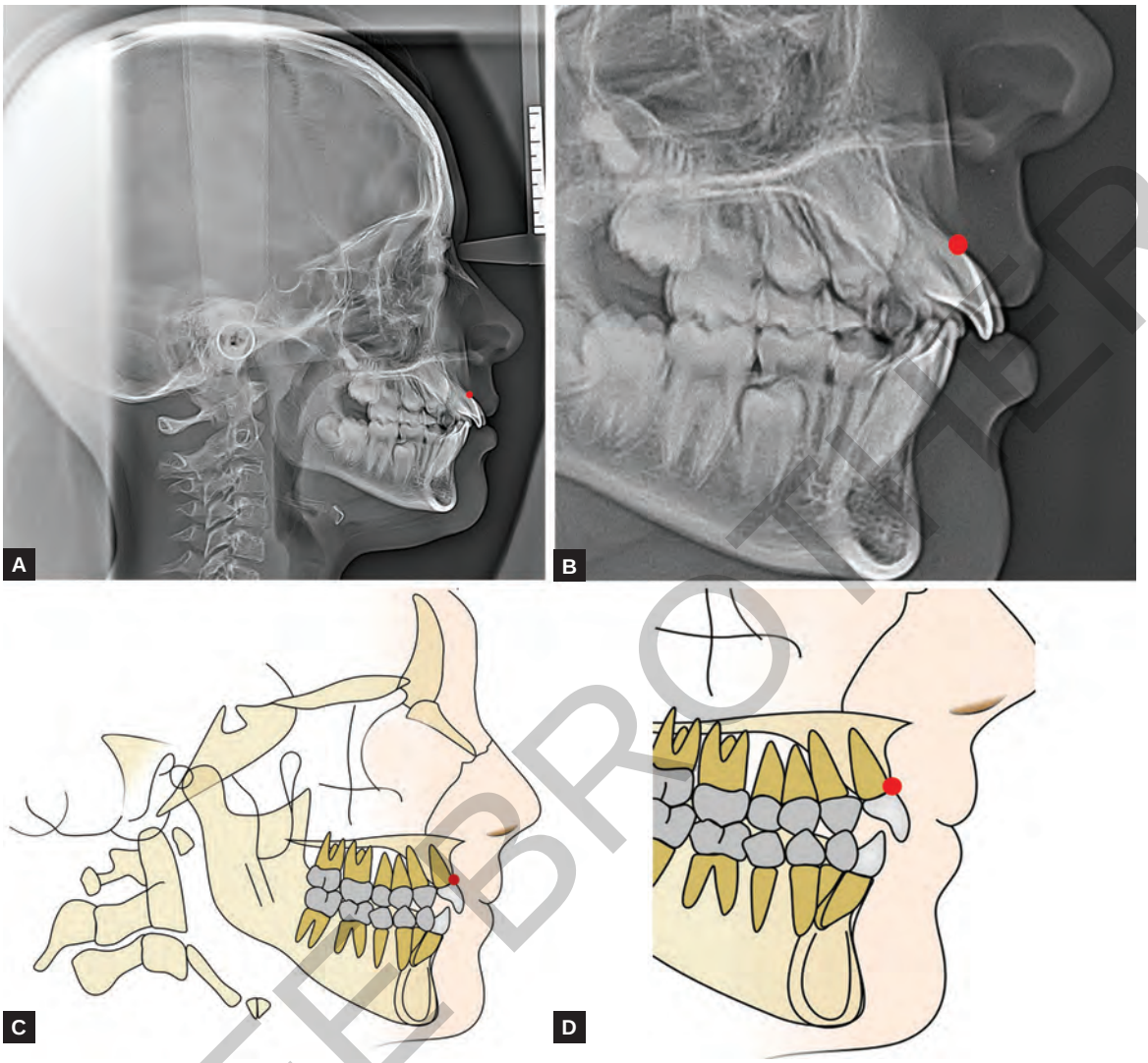

Figures 10.4A to D: (A) Prosthion on lateral cephalogram; (B) Magnified image showing prosthion on the lateral cephalogram; (C) Prosthion on graphic illustration; and (D) Magnified image of prosthion on graphic illustration

According to Arne Bjork

The transition point between the crown of the most prominent medial maxillary incisor and the alveolar projection.[9]

According to TM Graber

The point of the maxillary alveolar process in the midline that projects most anteriorly.[3]

According to Robert E Moyers

The most anterior inferior point on the maxillary alveolar process usually found near the cementoenamel junction of the maxillary central incisor.[4]

Type

Prosthion is a unilateral, hard tissue cephalometric landmark.

Origin

Prosthion is an anatomic hard tissue cephalometric landmark.

Significance (Ref to Chapter 20)

Prosthion is used as one of the reference points in the construction of angles for the assessment of relationship of maxilla skeletal base to cranial base using S-N-Pr angle.

JAYPEE BROTHERS

Posterior Nasal Spine

Abbreviation

PNS: Posterior Nasal Spine is abbreviated using English alphabets and is expressed as capital letter or upper case P, N and S and is written continuously without any space between the alphabets.

Definition

Posterior Nasal Spine **(Figs 10.5A to D)** is the intersection of a continuation of the anterior wall of the pterygopalatine fossa and the floor of the nose.

According to Michael L Riolo

The most posterior point at the sagittal plane on the bony hard palate.[10]

According to TM Graber

The bony posterior projection of the horizontal portion of the palatine bone at the midline.[3]

According to B Holly Broadbent

Process formed by the united projecting medial ends of the posterior borders of the two palatine bones.[2]

According to Viken Sassouni

Most posterior point on the contour of the bony palate.[1]

According to Alex Jacobson and W Caufield

Using a line perpendicular to FH, locate PNS at the most posterior aspect of the palatine bone.[7]

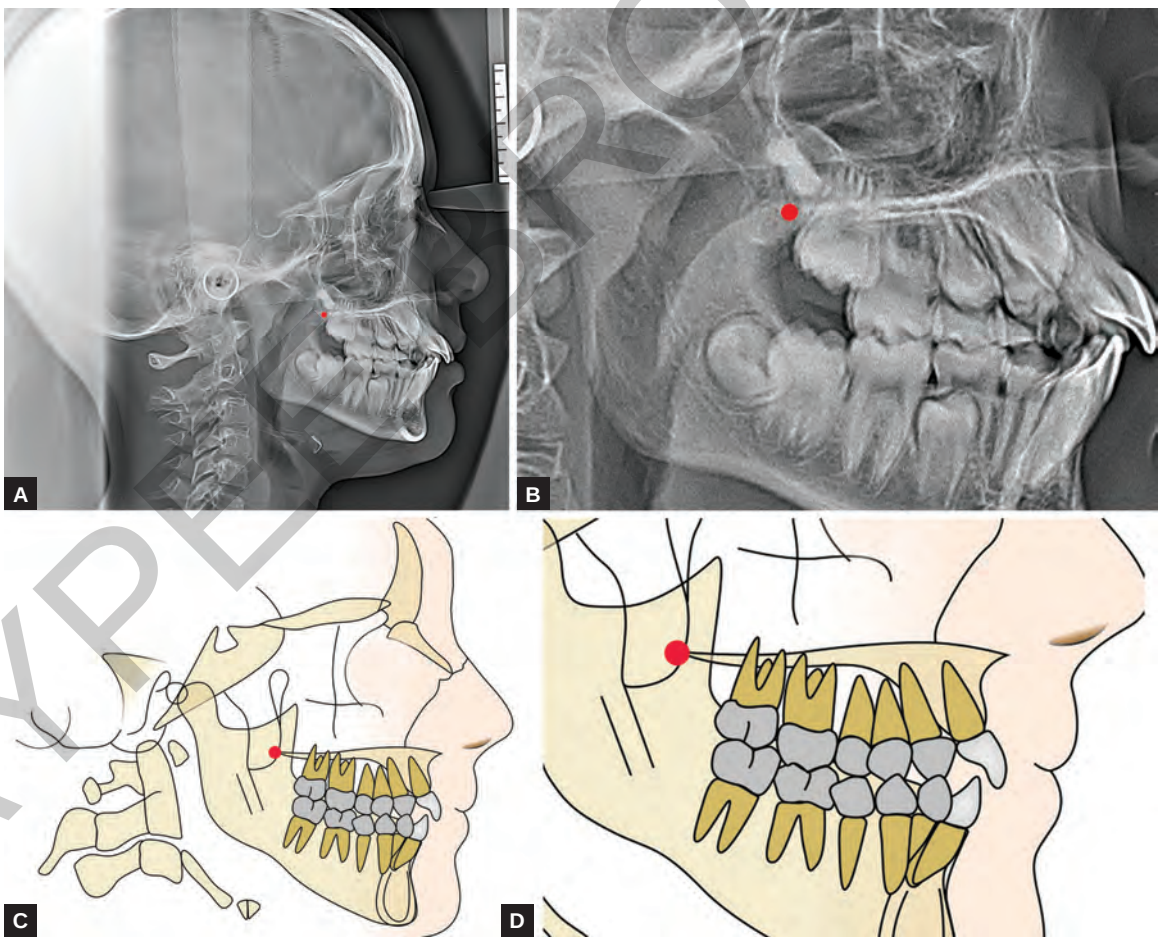

Figures 10.5A to D: (A) Posterior nasal spine on lateral cephalogram; (B) Magnified image showing posterior nasal spine on the lateral cephalogram; (C) Posterior nasal spine on graphic illustration; and (D) Magnified image of posterior nasal spine on graphic illustration

JAYPEE BROTHERS

According to Robert M Ricketts

Midpoint of the base of the palatine bone at the posterior margin of the hard palate.[6]

Type

Posterior nasal spine is a unilateral, hard tissue cephalometric landmark.

Origin

Posterior nasal spine is an anatomic hard tissue cephalometric landmark.

Tracing of Posterior Nasal Spine on the Lateral Cephalogram

- Like ANS, PNS also has variation in length and width.
- PNS is difficult to trace on the cephalogram when there is unerupted teeth, in these cases the PNS can be located between the floor of nasal cavity and the inferior surface of the palatine bone.
- Usually, it is found that PNS is located below the Ptm.

Significance (Ref to Chapter 20)

Posterior nasal spine is used as one of the reference points in the construction of occlusal plane and is used for the assessment of horizontal growth pattern using FH-Palatal plane angle (ANS-PNS).

Pterygomaxillary Fissure

Abbreviation

Ptm: Pterygomaxillary fissure is abbreviated using English alphabets and is expressed as capital or upper case P followed by small or lower case t and m, written continuously without any space between the alphabets.

PTM: According to Robert. M. Moyers, Pterygomaxillary fissure is abbreviated using English alphabets and is expressed as capital or upper case P followed by capital or upper case T and M, written continuously without any space between the alphabets.[4]

PTMS: According to Michael L Riolo, Pterygomaxillary fissure is abbreviated using English alphabets and is expressed as capital or upper case P, T, M, S, written continuously without any space between the alphabets.[9]

Definition

Pterygomaxillary fissure **(Figs 10.6A to D)** is a bilateral tear drop shaped area of radiolucency, the anterior shadow of which represents the posterior surface of the tuberosity of the maxilla; the landmark is taken where the two edges, front and back appear to merge inferiorly.

According to TM Graber

According to TM Graber, the pterygomaxillary fissure is an oval-looped radiolucency resulting from the fissure between the anterior margin of the pterygoid process of the sphenoid bone and the profile outline of the posterior surface of the maxilla.[3]

According to Robert M Moyers

According to Robert M Moyers, the pterygomaxillary fissure is tear drop shaped radiolucency, the anterior shadow of which represents the posterior surface of the tuberosity of the maxilla; the landmark itself is at the most inferior confluences of the curvatures.[4]

According to Clifton T Forsberg

According to Clifton T Forsberg, pterygomaxillary fissure is the most medial and posterior point of each pterygomaxillary fissure. The Ptm line connects right and left Ptm points. The Ptm access is the perpendicular bisector of the Ptm line.[11]

According to Holly Broadbent

Inverted, elongated, tear drop-shaped area formed by the divergence of the maxilla from the pterygoid process of the sphenoid. The posterior nasal spine and staphylion are generally located beneath the lower pointed end of this area.[2]

According to LB Higley

Junction of the Frankfort plane and a line perpendicular to it from the pterygomaxillary fissure.[12]

Type

Pterygomaxillary fissure is bilateral, hard tissue cephalometric landmark.

Origin

Pterygomaxillary fissure is an anatomic hard tissue cephalometric landmark.

Significance (Ref to Chapter 20)

Pterygomaxillary fissure is used as one of the reference points in Cox cephalometric analysis and is used to assess the posterior limit of the maxilla.

JAYPEE BROTHERS

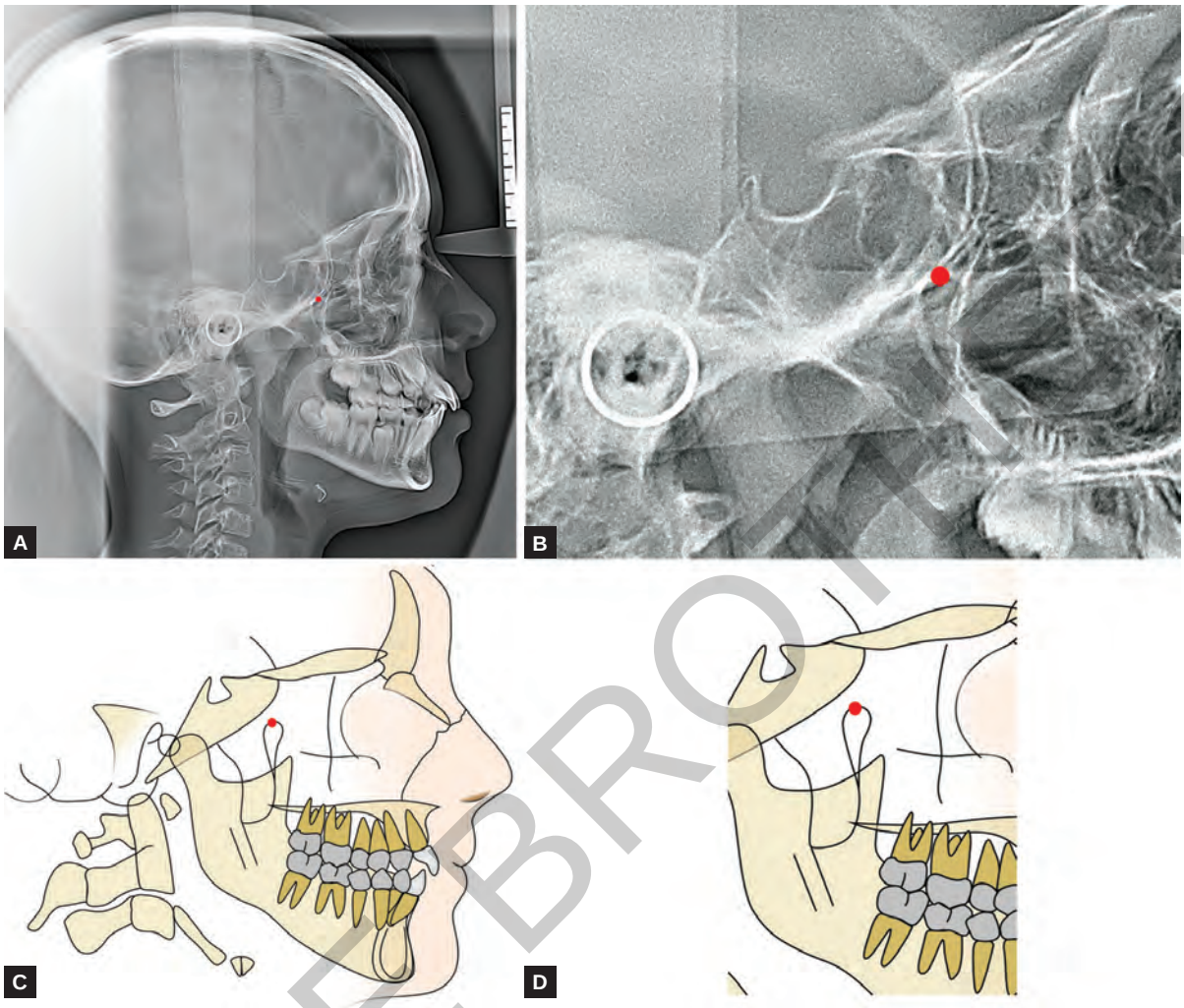

Figures 10.6A to D: (A) Pterygomaxillary fissure on lateral cephalogram; (B) Magnified image showing pterygomaxillary fissure on the lateral cephalogram; (C) Pterygomaxillary fissure on graphic illustration; and (D) Magnified image of pterygomaxillary fissure on graphic illustration

Key Ridge

Abbreviation

KR: Key ridge is abbreviated using English alphabets and is expressed as capital or upper case K, and R, and is written continuously without any space between the alphabets.

Definition

The key ridge **(Figs 10.7A to D)** is the lowermost point on the contour shadow of the anterior wall of the infratemporal fossa.

According to Viken Sassouni

Lowermost point on the contour of the shadow of the anterior wall of the infratemporal fossa.[1]

According to Robert E Moyers

The lowest point on the outline of the zygoma.[4]

According to TM Graber

The most inferior point on the zygomatic ridge.[3]

Type

Key ridge is a bilateral, hard tissue cephalometric landmark.

JAYPEE BROTHERS

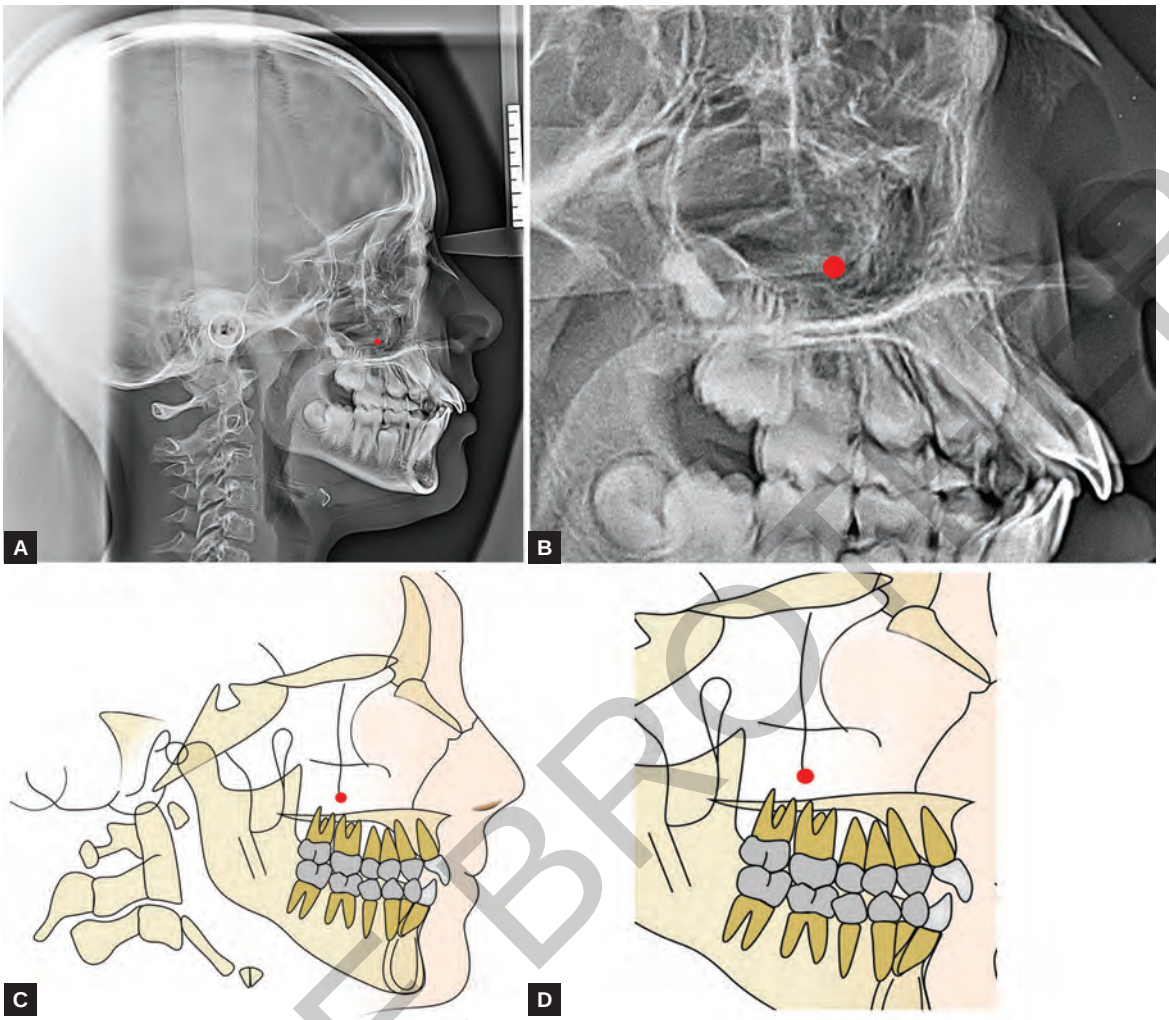

Figures 10.7A to D: (A) Key ridge on lateral cephalogram; (B) Magnified image showing key ridge on the lateral cephalogram; (C) Key ridge on graphic illustration; and (D) Magnified image of key ridge on graphic illustration

Origin

Key ridge is an anatomic hard tissue cephalometric landmark.

Orbitale

Abbreviation

Or: Orbitale is abbreviated using English alphabets and is expressed as capital or upper case O, followed by small or lower case r and both alphabets are written continuously without any space between them.

Definition

According to Arne Bjork

The deepest point on the infraorbital margin.The midpoint, or is used where double projection gives rise to two points, or 1 and or 2.[9]

According to William B Downs

The lowest point on the left infra-orbital margin.[5]

According to TM Graber

The most inferior point on the lower border of the left orbit.[3]

JAYPEE BROTHERS

According to B Holly Broadbent

The left orbital point is used in conjunction with poria to orient the skull on the Frankfort horizontal plane.[2]

Leslie G Farkas

Orbitale is the lowest point on the lower margin of the each orbit. It is identified by palpation and is identical to the bony orbitale.[13]

According to Robert E Moyers

In the lateral cephalogram, the outlines of the orbital rims overlap. Usually, the lowest point on the averaged outline is used for the construction of Frankfort plane.[4]

Type

Orbitale is a bilateral **(Figs 10.8A to D)**, anatomic, hard tissue cephalometric landmark.

Origin

Orbitale is an anatomic hard tissue cephalometric landmark.

Significance (Ref to Chapter 20)

Orbitale is used as one of the reference points in the construction of angles and planes for the assessment of following:

- Growth pattern is assessed using FH plane-Mandibular plane.

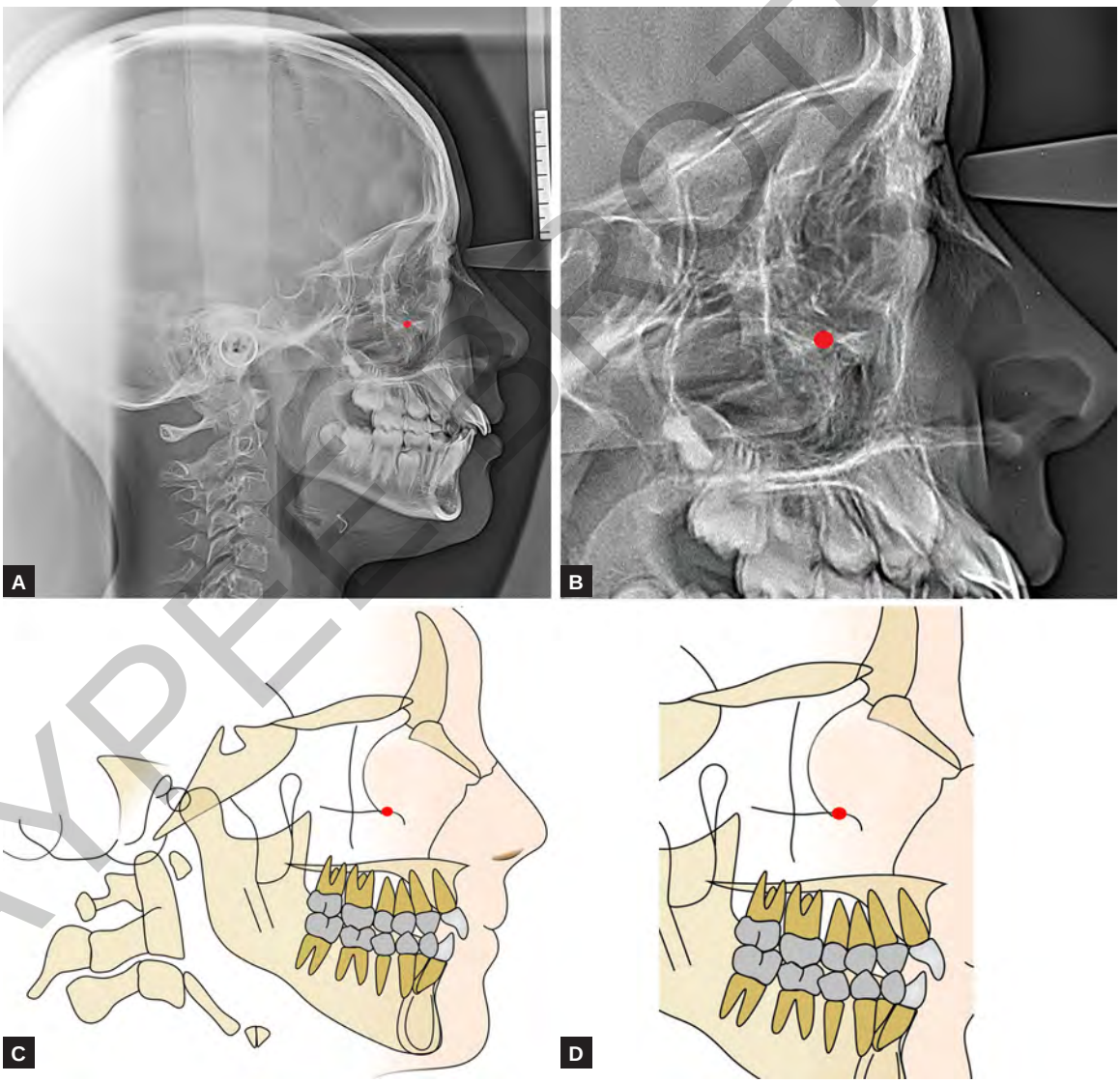

Figures 10.8A to D: (A) Orbitale on lateral cephalogram; (B) Magnified image showing orbitale on the lateral cephalogram; (C) Orbitale on graphic illustration; and (D) Magnified image of orbitale on graphic illustration

JAYPEE BROTHERS

- Upper incisor torque is assessed using FH-long axis of upper incisor.

Tracing of Orbitale on the Lateral Cephalogram

Normally, right and left infra-orbital margins are superimposed on the lateral cephalogram, and then they reveal radio-opaque line on the lateral cephalogram, when patient is positioned accurately on the cephalostat during the radiographic taking procedure.

If the patient is inaccurately positioned then in such cases, the infra-orbital margins appear as two different radio-opaque lines on the lateral cephalogram making difficult to identify the point. In such cases, the orbitale is identified as the mid-point of right and left infra-orbital margins.

References

1. Viken Sassuoni. Orthodontics in dental practice. The CV Mosby company. 1971;330-7.
2. Broadbent BH Sr. Bolton's standards of dentofacial developmental growth. The CV Mosby Company. 1975;133-5.
3. Graber TM. New horizons in case analysis. Clinical cephalometrics. Am J of Ortho. 1952;38:603-24.
4. Moyers RM. Handbook of Orthodontics.Year book medical publishers, Inc. 1988;251-9.
5. Downs WB. Variations in facial relationships. Their significance in treatment and prognosis. Am J of Ortho. 1948;34:812-39.
6. Ricketts RM. Provocations and perceptions in cranio-facial orthopedics. Dental science and facial art. Rocky Mountains, Inc. 1989;797-803.
7. Alex Jacobson, Caufield W. Introduction to radiographic cephalometry. Lea and Febiger. 1985;37-40.
8. Jarabak JR. Technique and treatment with light wire appliance. The CV Mosby company. 1963;132-3.
9. Arne Bjork. The face in profiles. Sven. Tandlak Tidskr. 1947;40:32-3.
10. Riolo ML. An atlas of craniofacial growth. Cephalometric standards from the university school growth study, the university of Michigan.Center for human growth and development. The University of Michigan. 1974;12-21.
11. Forsberg CT. Diagnosis and treatment planning of skeletal asymmetry with submental. Vertical radiograph. Am J of Ortho. 1984;85:224-37.
12. Higley LB. Cephalometric standards for children 4-8 years of age.Am J of Ortho. 1954;40:51-9.
13. Farkas LG. Anthropometry of the head and face in medicine. Elsevier north Holland, Inc. 1981;9-14.

JAYPEE BROTHERS

An Atlas on
CEPHALOMETRIC LANDMARKS

SALIENT FEATURES

- *An Atlas on Cephalometric Landmarks* acts as a basic step towards learning cephalometrics by explaining the anatomy, tracing and significance of all the cephalometric landmarks.
- All classifications of cephalometric landmarks given in the literature are listed. A new working classification given that includes all the cephalometric landmarks, makes recalling easier.
- All cephalometric landmarks on the lateral cephalogram, PA cephalogram and S-V projection covered.
- 3-D cephalometric landmarks explained with high quality photographs from "Anatomage".
- Serves to enrich the postgraduate orthodontic students, orthodontic practitioners and researchers.



Basavaraj Subhashchandra Phulari has formerly been faculty in the Department of Orthodontics and Dentofacial Orthopedics at Mauras College of Dentistry, Hospital and Oral Research Institute, Republic of Mauritius. He is the author of well-accepted textbook *Orthodontics: Principles and Practice with free Booklet of over 2300 MCQs in Orthodontics*. He has also authored three reference books titled: A Clinical Guide to Classifying Malocclusions: Discussion of Various Classification Systems of Malocclusions; Orthodontic Study Models: Fabrication; Types and their Applications in Orthodontics; History of Orthodontics: A glance at an Exciting Path, the Oldest Specialty of Dentistry has treaded so far. He is currently editing another reference book titled: A Practical of Basic Preclinical Wire Bending in Orthodontics. He is a dedicated teacher and also has few scientific publications in national and international journals to his credit.

Shelving
Recommendation
DENTISTRY

ISBN 978-93-5090-324-7

9 789350 903247

Available at all medical book stores
or buy directly from Jaypee Brothers through online shopping
at www.jaypeebrothers.com

JAYPEE BROTHERS
Medical Publishers (P) Ltd.
www.jaypeebrothers.com