Essentials of Orthodontics

Aravind Sivaraj

Foreword
A Venkatesan









JAYPEE

Contents

1. Introduction 1

Introduction to Orthodontics 1

• *Definitions 1* • *Orthodontist 2*

History of Orthodontics 4

• *Orthodontics in India 5* • *Evolution of Orthodontic Appliances 5*

2. Growth and Development 9

General Principles and Concepts 9

• *Definitions 9* • *Factors Affecting Physical Growth 10* • *Concepts of Growth 11* • *Types of Growth Data 17* • *Methods of Gathering Growth Data 18* • *Methods of Studying Growth 19* • *Mechanism of Bone Growth 20* • *Osteogenesis (Mechanism of Bone Formation) 20* • *Theories of Growth 23*

Prenatal Growth and Development 28

• *Period of Ovum 28* • *Period of Embryo 28* • *Prenatal Development of Maxilla 32* • *Development of Palate 32* • *Development of Maxillary Sinus 33* • *Development of Tongue 33* • *Prenatal Development of Mandible 34* • *Meckel's Cartilage 34* • *Endochondral Bone Formation 35* • *Prenatal Growth of Temporomandibular joint 35*

Postnatal Growth and Development 35

• *Neonatal Skeleton 36* • *Postnatal Growth of the Cranial Vault 36* • *Postnatal Growth of the Cranial Base 36* • *Postnatal Growth of Maxilla 38* • *Postnatal Growth of Mandible 40* • *Mandibular Rotation 42* • *Postnatal Growth of TMJ 43 Summary of Facial Growth Changes 44*

Development of Dentition and Occlusion 44

• Bud Stage 45 • Cap Stage 45 • Bell Stage 45 • Periods of Occlusal Development 46 • Predental Period 46 • Deciduous Dentition Period 48 • Mixed Dentition Period 50 • Permanent Dentition Period 53

Functional Development 57

• Normal Milestones of Development 58 • Puberty and Adolescence 59 • Mastication 59 • Deglutition 60 • Respiration 62 • Speech 64 • Trajectories of Force 65 • Wolff's Law of Transformation of Bone 66

Psychological Development 66

• Psychology (Study of Psyche) 67 • Theories of Psychological Development 67 • Behavior in Orthodontics 72 • Behavior Development 73 • Behavior Management 73 • Basic Approaches to Child Management in Orthodontics 77 • Ephebodontics 77

Clinical Importance of Growth and Development in Orthodontics 78

• Infancy and Early Childhood 78 • Juvenile Period 79 • Adolescent Growth 79 • Clinical Implications of Regional Development 79

3. OCCLUSION AND MALOCCLUSION 83

Occlusion 83

• Terminology 83 • Types of Cusps 84 • Arrangement of Teeth in Humans 84 • Imaginary Occlusal Planes and Curves 84 • Centric Relation and Centric Occlusion 85 • Centric Contacts 85 • Eccentric Occlusion 86 • Disclusion 86 • Angle's Concept of Normal Occlusion 87 • Begg's Concept of Normal Occlusion (Attritional Occlusion) 88 • Roth's Concept of Functional Occlusion 88 • Andrews Six Keys to Normal Occlusion 89

Classification of Malocclusion 90

• Malocclusion 90 • Classification 90 • Types of Malocclusion 91 • Systems of Classification 93

Epidemiology of Malocclusion 101

Applications of Epidemiological-Principles 101 • Study Designs 102 • Bias in Research 104 • Statistics Measurement of Data 106 • Hypothesis Testing 106

Indices of Malocclusion 109

• Index 109

Anthropology 117

• Anthropology and Orthodontics 120 • Early Primates 121

4. ETIOLOGY 127

Etiology of Malocclusion 127

• Classification of Etiologic Factors in Malocclusion 127 • Etiology for Specific Types of Malocclusion 133

Habits 135

• *Definition 135* • *Classification of Habits 135* • *Thumb Sucking and Finger Sucking 137* • *Tongue Thrusting Habit 142* • *Mouth-breathing 147* • *Lip Biting and Lip Sucking 151* • *Bruxism 151* • *Finger Nail Biting 153* • *Tongue Sucking 154* • *Pillowing Habits 154*

Nutrition in Orthodontics 154

• *Effect of Nutritional Status on Tooth Movement and Tissue Response to Appliances 154* • *Dietary Counseling for Plaque Control and General Health in the Orthodontic Patient 156* • *Nutritional Considerations in the Orthognathic Surgical Patient 156* • *Nutritional Factors in the Etiology of Craniofacial Anomalies 157*

Genetics in Orthodontics 158

• *History 159* • *Molecular Basis of Inheritance 159* • *Genetics in Orthodontic Perspective 161*

5. ORTHODONTIC DIAGNOSIS 166

Orthodontic Diagnosis 166

• *Esthetics in Orthodontics 166* • *Golden Section 167*

Diagnostic Aids in Orthodontics 171

• *Essential Diagnostic Aids 171* • *Supplemental Diagnostic Aids 172* • *Case History 172* • *Clinical and General Examinations 173* • *Functional Examination 180* • *Orthodontic Study Models 185* • *Total Dentition Space Analysis 193* • *Inference to Deficits and Decisions 195* • *Radiographs Used In Orthodontic Diagnosis 196 Cephalometrics 198* • *Facial Photographs 218*

Computers in Orthodontics 236

• *Characteristics of a Computer 237* • *Uses of Computer in Orthodontics 238*

Sterilization in Orthodontics 243

• *Sterilization 243*

6. ORTHODONTIC TREATMENT PLANNING 246

General Factors in Orthodontic Treatment Planning 246

• *Setting-up Goals 246* • *Enlisting the Treatment Objectives 246* • *Age Factor in Orthodontics 249* • *Treatment and Age 250* • *Tooth Movement and Age 251* • *Young Versus Adult Patients 251* • *Phases of Orthodontic Treatment 252* • *Limitations in Orthodontics 253*

Methods of Gaining Space 253

• *Proximal stripping (Reproximization, Slenderization, Disking and Proximal Slicing) 254* • *Expansion 255* • *Types of Appliances Used 257* • *Slow Expansion 260*

• *Extractions in Orthodontics 262* • *Distalization 267* • *Uprighting of Molars 269*
• *Derotation of Posterior Teeth 269* • *Proclination of Anterior Teeth 269*

Treatment Planning in Class I Malocclusion 269

• *Clinical Features of Class I Malocclusion 269* • *Midline Diastema 272* • *Crossbite 275*
• *Impacted Teeth 281*

Treatment Planning in Class II Malocclusion 284

• *Class II Division 1 Malocclusion 285* • *Class II Division 2 Malocclusion 287*

Treatment Planning in Class III Malocclusion 288

• *Clinical Features of Class III Malocclusion 288* • *Skeletal Features of Class III Malocclusion 289*

Drugs Used in Orthodontics 290

• *Prophylactic Antibiotics for Prevention of Infective Endocarditis 290*

7. BIOMECHANICS 298

Mechanics of Tooth Movement 298

• *Newton's Laws of Motion 298* • *Types of Tooth Movements 299* • *Types of Force 301*

Biology of Tooth Movement 302

• *Physiologic Tooth Movement 302* • *Tooth Mobility 305* • *Histology of Tooth Movement 305* • *Optimum Orthodontic Force 306* • *Hyalinization 307* • *Theories of Tooth Movement 308* • *Phases of Tooth Movement 309* • *Biochemical Reaction to Orthodontic Tooth Movement 310* • *Bone Resorption 311* • *Bone Deposition 311*

Anchorage in Orthodontics 314

• *Definition (Graber) 314* • *Classification 314* • *Sources of Anchorage 315*
• *Implants as Anchorage in Orthodontics 320* • *Anchorage Loss 325*

8. PREVENTIVE AND INTERCEPTIVE ORTHODONTICS 326

Preventive Orthodontics 326

• *Definition 326* • *Caries Control 327* • *Oral Habits Check-up and Educating Patients and Parents 328* • *Space Maintainers 328*

Interceptive Orthodontics 333

• *Definition 333* • *Serial Extractions 334* • *Developing Anterior Crossbite Correction 337* • *Preorthodontic Trainers 340* • *Clinical Management 341* • *Muscle Exercises 341*

9. ORTHODONTIC APPLIANCES 344

• *Classification of Orthodontic Appliances 344* • *Ideal Requirements of an Orthodontic Appliance 345*

Removable Appliances 345

• Indications for Removable Appliances 345 • Advantages of Removable Appliances 345 • Disadvantages of Removable Appliances 346 • Components of Removable Appliances 346

Fixed Appliances 364

• Advantages of Fixed Appliances 364 • Disadvantages of Fixed Appliances 365 • Banding 366 • Bonding 367 • Components of Fixed Orthodontic Appliances 368 I. Active Components 369 • II. Passive Components 372 • Fixed Appliance Techniques 375 • Oral Hygiene in Fixed Appliance Treatment 379

10. DENTOFACIAL ORTHOPEDICS 382

Orthopedic Appliances 382

• Basis for Orthopedic Appliances 382 • Biomechanical Consideration 383 • Headgear 384 • Protraction Face Mask Therapy 388 • Factors Governing Variability in Clinical Response 389 • Chin Cup Therapy 390

Functional Appliances 390

• Definition 391 • Classification of Functional Appliances 391 • Advantages of Functional Appliances 393 • Limitations of Functional Appliances 393 • Action of Functional Appliances 394 • Visual Treatment Objective 395 • Vestibular Screen (Oral Screen) 395 • Activator 397 • Management of the Appliance 400 • Wunderer's Modification 401 • The Reduced Activator or Cybernator of Schmuth 402 • Propulsor 402 • Karwetzky Modification 402 • Herren's Modification of the Activator 402 • Function Regulator (Frankel Appliance) 403 • Bionator 407 • Twin Block Appliance 408 • Herbst Appliance 409

11. RETENTION AND RELAPSE 412

Retention 412

• Schools of Retention 412 • Theorems of Retention 412 • Raleigh Williams Six Keys for Retention 414 • Theories of Retention 414 • Methods of Retention: Retainers 415 Relapse 421 • Failures in Orthodontics 423

12. SURGICAL ORTHODONTICS 429

Minor Surgical Procedures 429

• Extractions 429 • Surgical Exposure of Impacted Teeth 430 • Frenectomy 431 • Pericision (Circumferential Supracrestal Fibrotomy or CSF Procedure) 431 • Corticotomy 432 • Orthodontic Implants 432

Orthognathic Surgery 433

• Etiology of Dentofacial Deformities 433 • Orthognathic Surgery 434 • Presurgical Orthodontics 436 • Maxillary 437 • Mandibular Surgeries 440

Distraction Osteogenesis 442

• *Definition 442* • *Historical Perspective 442* • *Indications 443* • *Advantages 443* • *Disadvantages 443* • *Preoperative Clinical Examination 444* • *Growth and Stability after Distraction 446*

13. MULTIDISCIPLINARY ORTHODONTICS 448

Adult Orthodontics 448

• *Reasons for Increase in Adult Patients 448* • *Biomechanical Considerations 450* • *Diagnosis and Adult Orthodontics 451* • *Treatment Aspects in Adult Orthodontics 452*

Orthodontics in Multispecialty Approach 455

• *Multispecialty Orthodontic Treatment 455* • *Orthodontic-periodontic Interrelationship 457*

Orthodontic Management of TMJ and Occlusal Disorders 462

• *Biomechanics 463* • *Temporomandibular Joint Pathology 464* • *Signs and Symptoms of TMJ Disorders 465* • *Orthopedic Dysfunction 466* • *Diagnosis 468 Management 469*

Orthodontic Management of Cleft Lip and Palate 472

• *Incidence 472* • *Embryological Background 473* • *Family Counseling 480*

Orthodontic Management of Craniofacial Syndromes 480

• *Orthodontic Management of Cleidocranial Dysplasia 480* • *Orthodontic Management of Obstructive Sleep Apnea Syndrome 482* • *Orthodontic and Temporomandibular Joint Considerations in Treatment of Patients with Ehlers-Danlos Syndrome 483*

Orthodontic Management of Medically Compromised Patients 484

• *Management of Physically Handicapped Child 484* • *Management of Orthodontic Patients with a History of Rheumatic Fever or Congenital Heart Disease 485* • *Orthodontic Management of Patients with Bleeding Disorders 486* • *Orthodontic Management of Patients with Hematologic Malignancies 487* • *Orthodontic Management of Patients with Endocrine Disorders 488* • *Orthodontic Management of Patients with Diabetes 489* • *Orthodontic Management of Patients with Cystic Fibrosis 491* • *Orthodontic Management of Patients with Juvenile Rheumatoid Arthritis 491* • *Orthodontic Management of Patients with Renal Failure 492*

Forensic Orthodontics 493

• *Forensic Dentistry 493* • *Role of Orthodontist 494* • *Dermatoglyphics 495*

14. COMMUNITY ORTHODONTICS 496

Orthodontic Practice 496

• *Ideal Orthodontic Services 496* • *Typical Orthodontic Practice Organization 496* • *Orthodontic Work Environment 499*

Medicolegal Considerations in Orthodontics 504

• *Legal Precedents 504*

15. MATERIALS USED IN ORTHODONTICS 507

Orthodontic Materials 507

• *Classification of Orthodontic Appliance Materials 507* • *Orthodontic Arch Wire Materials 509* • *Bracket and Attachment Materials 517* • *Bonding Materials 518* • *TEGDMA 520* • *Orthodontic Cements 520* • *Sealants and Adhesion Promoters 524* • *Conditioning and Crystal Growth Systems 525* • *Elastics and Elastomerics 526* • *Magnets in Orthodontics 526* • *Soldering and Welding 528* • *Other Dental Materials 534*

Acrylic Materials 542

• *Ideal Requirements for Dental Resin 542* • *Acrylic Resins 542*

Finishing and Polishing Materials 545

• *Commonly used Abrasives 545*

Implant Materials in Orthodontics 546

• *History 546* • *Metals and Alloys 546* • *Other Metals and Alloys 547* • *Endosteal and Subperiosteal Implants 548*

Orthodontic Instruments 549

• *Adam's Pliers (Universal Pliers) 549* • *Arch-forming Pliers (Arch-contouring Pliers, De la Rossa Pliers) 549* • *Band Burnisher (Beaver-tail Burnisher) 549* • *Band-contouring Pliers 550* • *Band Pusher (Mershon Band Pusher) 550* • *Band-Removing (Debanding) Pliers, Anterior 550* • *Band-Removing (Debanding) Pliers, Posterior 550* • *Band Seater (Band Biter) 551* • *Bird-beak (No. 139) Pliers 551* • *Bracket-positioning Instrument (Bracket-height Gauge, Boone's Gauge) 551* • *Bracket-removing Pliers (Debonding Pliers) 552* • *Conversion Instrument 552 Coon Ligature-tying Pliers 552* • *Distal-end Cutter 552* • *Elastic Separator Pliers (Separator Pliers) 553* • *Facebow-adjusting Pliers 553* • *Hard Wire Cutter 553* • *Hemostat (Mosquito Pliers) 553* • *Howes Utility Pliers 554* • *Ligature Director (Pitchfork Instrument, Tie in Tucker) 554* • *Light-wire Pliers 554* • *Mathieu-style Ligature-tying Pliers 555* • *Parallel-action Pliers with Cutter (Sargent's heavy-duty Pliers) 555* • *Pin and Ligature Wire Cutter 555* • *Serrated Band Plugger (Serrated Amalgam Plugger) 556* • *Steiner Ligature-tying Pliers 556* • *Torquing Key 556* • *Triple-beaked Pliers (Three Prong Pliers, Three Jaw Pliers, Clasp-adjusting Pliers) 556* • *Turret 557* • *Tweed Arch-adjusting (No. 142) Pliers 557* • *Tweed Loop-forming Pliers (Omega Pliers, Optical Pliers) 557* • *Weingart Utility Pliers 558*

Bibliography 559

Index 561

CHAPTER

12 Surgical Orthodontics

JAYPEE BROTHERS

MINOR SURGICAL PROCEDURES

Surgical orthodontics is a term that refers to surgical procedures carried out as an adjunct to or in conjunction with orthodontic treatment. These surgical procedures are usually carried out to eliminate an etiologic factor or to correct severe dentofacial abnormalities that cannot be satisfactorily treated by growth modification procedures or orthodontic camouflage.

Surgical orthodontic procedures are broadly classified as minor surgical procedures and major surgical procedures. While most minor procedures are an integral part of orthodontic therapy, the major procedures are aimed at treatment of severe skeletal malocclusion or dentofacial deformities.

Minor surgical procedures include:

1. Extractions
   i. Therapeutic extractions
   ii. Serial extraction
   iii. Extraction of carious teeth
   iv. Extraction of supernumerary teeth
   v. Extraction of impacted teeth.
2. Surgical exposure of impacted teeth
3. Frenectomy
4. Pericision
5. Transplantation of teeth
6. Corticotomy
7. Implants for orthodontic purpose.

EXTRACTIONS

Extractions are the most commonly undertaken minor surgical procedure in conjunction with orthodontic therapy. Extractions performed as a part of orthodontic therapy include therapeutic extraction, serial extraction and extraction of supernumerary carious or malformed teeth.

Therapeutic Extractions

Therapeutic extractions are undertaken as a part of comprehensive orthodontic treatment mainly to gain space. Prior to therapeutic extraction a thorough diagnostic exercise is essential. Extraction should be as atraumatic as possible. During the extraction care should be taken to preserve the integrity of the alveolus. Any break or loss of either the buccal or the lingual bony plates may prevent ideal positioning of the teeth during orthodontic therapy. Preoperative radiographs

are a valuable aid in planning and execution of extractions.

Serial Extractions

Serial extraction involves removal of some deciduous teeth followed by specific permanent teeth in an orderly sequence to guide the rest of the permanent teeth into a more favorable position. Serial extraction is usually carried out when an arch length deficiency exists which prevents normal alignment of the whole complement of teeth.

Extraction of Supernumerary Impacted and Ankylosed Teeth

The presence of supernumerary, impacted and ankylosed teeth are important local causes of malocclusion. The most commonly seen supernumerary teeth are the mesiodens. Supernumerary teeth can also occur in the incisor, premolar and molar region. Impactions in the maxilla generally occur in the canine region.

Prior to the removal of these teeth their exact location and their relationship is ascertained by radiographs. During the extraction procedure, care should be taken not to damage the adjacent teeth or roots. The tooth is approached by a buccal or palatal flap depending upon its location. After careful elevation of the flap, adequate amount of bone is removed using rotary cutting instruments. The impacted or supernumerary tooth is removed and the extraction socket inspected for any pathological tissue. The flap is repositioned and sutures placed for a week.

SURGICAL EXPOSURE OF IMPACTED TEETH

The presence of impacted teeth in the dental arch can cause minor dental irregularities due to deflection of adjacent teeth. Impaction of teeth usually occurs as a result of arch length discrepancy or presence of mucosal and bony barriers that prevent their eruption. The most commonly impacted tooth is the maxillary permanent canine. In many cases it is possible for the orthodontist to guide the impacted canine into its normal location in the dental arch after adequate surgical exposure. The following steps are undertaken in the management of impacted tooth:

Location of the Tooth

The exact location of the impacted tooth is determined using the Clark's tube shift technique or the right angle technique. Most impacted teeth present a bulge corresponding to their location which should be examined clinically by inspection and palpation.

Evaluation of Favorability

In many cases the orientation of the impacted teeth may be such that surgical orthodontic guidance of the tooth into the arch may not be possible. The favorability should be examined prior to undertaking of the procedure. It is considered favorable whenever the apex of the canine is close to its normal position.

Evaluation of Space Adequacy

When the impacted tooth is guided into the dental arch, adequate space should be present for its normal alignment. In many cases involving the impaction of permanent canines the deciduous canines are over retained. These teeth may have to be extracted to accommodate the permanent canines. In certain patients, the space intended for the permanent canine may be lost by migration of the adjacent teeth. In such cases space for the permanent canine is created by consolidating the rest of the teeth and possibly extracting a premolar.

JAYPEE BROTHERS

Surgical Excision and Bone Removal

The crown of the impacted tooth is exposed by excision of the overlying soft tissue and removal of bony covering. The bone should be removed up to the maximum height of contour.

Fixing Orthodontic Attachments

In most cases of favorably impacted canines, once the soft tissue and bony tissues are removed, the canine erupts on its own. In some cases, orthodontic guidance for eruption of the teeth into the arch may be required.

Attachments are placed on the impacted tooth to guide the erupting tooth into the arch. Some of the attachments that can be placed on the impacted crowns are:

i. Metal crown with a hook.
ii. Celluloid crown with an attachment bonded to it.
iii. Bondable orthodontic brackets or buttons.

A ligature wire is wound around the attachment and the other end tied to a removable or fixed orthodontic appliance. The wire is gradually tightened at regular intervals to guide the erupting tooth.

FRENECTOMY

Many cases of midline diastema are believed to be caused and maintained by abnormalities of the maxillary labial frenum. The presence of a thick, fleshy and fibrous frenum prevents the two maxillary central incisors from approximating each other. In these patients the frenal tissue may crossover and get attached in the intermaxillary suture area on the palatal aspect.

Frenectomy is a surgical procedure performed to excise the frenum and remove the deeply embedded fibrous tissue. Controversy exists regarding the timing of the surgical procedure. According to some, frenectomy should be performed prior to orthodontic closure of the midline diastema. According to another school of thought, frenectomy should be performed after space closure as it reduces the risk of scar tissue formation that can prevent closure of the midline space.

Regardless of the timing when the procedure is performed the following points should be remembered:

i. Frenum should not merely be clipped; it should be totally excised to the bony level.
ii. Any palatally attached fibrous tissue should be removed.
iii. Fibrous tissue attached to the intermaxillary suture area should be removed.
iv. The mucosa of the lip is undermined to prevent reattachment of the fibrous tissue.

PERICISION (CIRCUMFERENTIAL SUPRACRESTAL FIBROTOMY OR CSF PROCEDURE)

Pericision or circumferential supracrestal fibrotomy, as it is often called is a minor surgical procedure that is undertaken to counter the relapse tendency of the stretched gingival fibers. The transseptal and alveolar crestal groups of gingival fibers remain stretched and do not readily readopt to the new tooth position following correction of rotations hence causing relapse.

Pericision involves surgical sectioning of these fibers by passing a sharp narrow scalpel through the gingival sulcus around the tooth to a depth of 2 mm apical to the alveolar crest. Pericision is generally undertaken as an adjunctive retention procedure after correction of rotations.

JAYPEE BROTHERS

CORTICOTOMY

Corticotomy is a surgical procedure usually undertaken in patients having dental proclination with spacing. This technique involves the sectioning of the dentoalveolar region into multiple small units to hasten orthodontic tooth movement. Labial flaps are raised and interdental bony cuts are made parallel to the long axes of the teeth. These cuts may be joined together by a horizontal bony cut above the apices of the roots. Care should be taken not to totally separate the individual units. Following the surgery orthodontic tooth movement is initiated using fixed appliance.

ORTHODONTIC IMPLANTS

Implants made of titanium have been widely used by several orthodontists as they offer 'Absolute anchorage.'

Classification of Implants

Implants can be broadly classified under the following headings:

Based on the Location

1. *Subperiosteal implants:* Implant body lies over the bony ridge. The subperiosteal design currently in use for orthodontic purpose is the 'Onplant.'
2. *Transosseous implants:* The implant body penetrates the mandible completely, this type is not used in orthodontics.
3. *Endosseous implants:* These are partially submerged and anchored within the bone. These have been the most popular and widely used.

Based on the Configuration Design

1. *Root form implants:* These are the screw type endosseous implants and the name has been derived due to their cylindrical structure.
2. *Blade or plate implants:* These have blade or plate shape.

Based on the Composition of Implant

1. Stainless steel
2. Cobalt-Chromium-Molybdenum (Cr-Co-Mo)
3. Titanium
4. Ceramic implants
5. Miscellaneous such as vitreous carbon and composites.

Based on the Surface Structure

1. *Threaded or nonthreaded:* The root form implants are generally threaded as this provides for a greater surface area and stability of the implants.
2. *Porous or nonporous:* The screw type implants, whereas the plate or blade implants (nonthreaded) have vents in the implant body to aid in growth of bone and thus a better interlocking between the metal structure and the surrounding bone.

Application of Implants in Orthodontics

Implants are used mainly as anchorage sources in orthodontics,

1. As source of anchorage alone (indirect anchorage).
   a. Orthopedic anchorage
      i. Maxillary expansion
      ii. Headgear like effects.
   b. Dental anchorage
      i. Space closure
      ii. Intrusion of anterior teeth or posterior teeth
      iii. Distalization of molars.
2. In conjunction with prosthetic rehabilitation (direct anchorage).

JAYPEE BROTHERS

Recent advances include modified implant designs which are specifically meant for orthodontic usage like:

1. Screw design
   i. Mini-implant
   ii. Impacted titanium post
   iii. Skeletal anchorage system
   iv. The microimplant
   v. The Aarhus implant
   vi. The orthosystem implant systems
   vii. Newer systems (Spider screw, OMAS system, Leone implant, Imtec screws, etc.).
2. Implant disks:
   i. Onplants
3. Plate designs:
   i. Skeletal anchorage system (SAS)
   ii. Graz implant supported system
   iii. Zygoma anchorage system.

Method of Placement

The implant is placed by a surgeon through a specialized procedure known as tunneling. After making an incision in the posterior region of the palate, a subperiosteal tunnel flap is created extending till the desired location, using an elevator. The implant is placed and is not disturbed for a period of 3 to 4 days allow biohealing.

Implants for the purpose of conserving anchorage are welcome additions to the armamentarium of a clinician. They help the orthodontist to overcome the challenge of unwanted reciprocal tooth movement. The presently available implant systems are bound to change and evolve into more patient-friendly and operator-convenient desigs. Usage of implants to achieve orthopedic changes in growing children has also been documented. Long-term clinical trials are awaited to establish clinical guidelines in using implants for both orthodontic and orthopedic anchorage.

ORTHOGNATHIC SURGERY

Orthognathic surgeries are surgical procedures carried out along with orthodontic treatment which provide an opportunity for the orthodontist and the oral surgeon to treat in collaboration, severe dentofacial malformations that cannot be satisfactorily treated by orthodontic treatment alone. The major surgical procedures are mainly aimed at treating dentofacial deformities.

ETIOLOGY OF DENTOFACIAL DEFORMITIES

Dentofacial deformities can be congenital, developmental or acquired in nature and can affect the maxilla, the mandible or both in combination.

The classification of etiologic factors in dentofacial deformities are:

Specific Causes

A. Prenatal causes:
   1. Fetal alcohol syndrome
   2. Retinoic and thalidomide therapy
   3. Hemifacial microsomy
   4. Goldenhar's syndrome
   5. Mandibulofacial dysostosis
   6. Facial clefting syndrome
   7. Achondroplasia
   8. Craniosynostosis syndrome
   9. Pierre Robin syndrome.

B. Postnatal causes:
   1. Injury to nasal septum
   2. Injury to condyle
   3. Injury to ramus
   4. Injury to alveolar bone and teeth
   5. Missing muscles
   6. Condylar hyperplasia.

JAYPEE BROTHERS

Hereditary

1. Mandibular prognathism
2. Interracial mixing.

Environmental

1. Effect of posture
2. Respiratory influence
3. Effect of biting force.

ORTHOGNATHIC SURGERY

Orthognathic surgeries are major surgical procedures carried out along with orthodontic therapy to correct dentofacial deformities or severe orofacial disproportions involving the maxilla, the mandible or both in combination. Orthognathic surgery basically involves planned fracturing of the facial skeletal parts and repositioning them as desired. They should be performed as a team with the oral surgeon and the orthodontist being important members of the team.

Orthognathic surgeries can be performed in the maxilla as well as the mandible or in combination to correct jaw discrepancies in all the three planes of space.

The various orthognathic procedures include:

I. Sagittal procedures:
   Maxillary Prognathism
   1. Subapical osteotomy
   2. LeFort I osteotomy
   3. Anterior maxillary osteotomy (AMO).

   Maxillary Retrognathism
   1. LeFort I osteotomy
   2. LeFort II and III osteotomy.

   Mandibular Prognathism
   1. Bilateral sagittal split osteotomy (BSSO) (Figs 12.1A and B).
   2. Extraoral vertical osteotomy
   3. Ramus vertical osteotomy
   4. Reduction genioplasty.

   Mandibular Retrognathism
   1. Bilateral sagittal split osteotomy
   2. Intraoral vertical osteotomy
   3. Augmentation genioplasty.

II. Transverse procedures:
   1. Midpalatal osteotomy
   2. Surgically assisted rapid palatal expansion.

III. Vertical procedures:
   1. Sagittal split osteotomy
   2. LeFort I
   3. Subapical osteotomy
   4. Combination of sagittal split and LeFort I osteotomy
   5. Genioplasty.

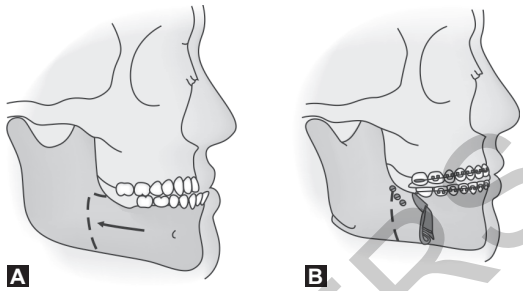

Figures 12.1A and B: BSSO advancement

The planning and execution of orthognathic surgery are done in a methodical manner. The following are steps involved in orthognathic surgery.

Diagnosis (Preoperative Evaluation)

Preoperative diagnosis is very important for the success of orthognathic surgery. The diagnosis is aimed at determining the nature, severity and the possible etiology of the dentofacial deformity.

General medical evaluation: The patient's general medical history should be recorded

JAYPEE BROTHERS

to rule out medical disorders. The patient's overall dental health should be evaluated. Pulpoperiodontal problems should be relived prior to the surgical intervention.

Sociopsychological evaluation: The patient is assessed to determine whether they are aware of the existing dentofacial deformity and what they expect out of the surgical therapy. This helps in determining the patient's motivation. The patient's social status should also be evaluated.

Envelope of Discrepancy (Figs 12.2A and B)

A diagram devised by WR Proffit and JL Ackerman to illustrate graphically the amount of change that can be produced by orthodontic tooth movement alone (inner envelope), orthodontic tooth movement combined with growth modification (middle envelope) and orthognathic surgery (outer envelope) in the sagittal and vertical planes of space, based on the authors' clinical judgment.

Cephalometric evaluation: Cephalometric evaluation is an important tool in determining the nature and severity of the skeletal problems. The commonly used cephalometric analyses are the Burstone's Cephalometrics for Orthognathic Surgery (COGS) analysis and Quadrilateral analysis. Frontal cephalometric evaluation helps in determining the facial asymmetry.

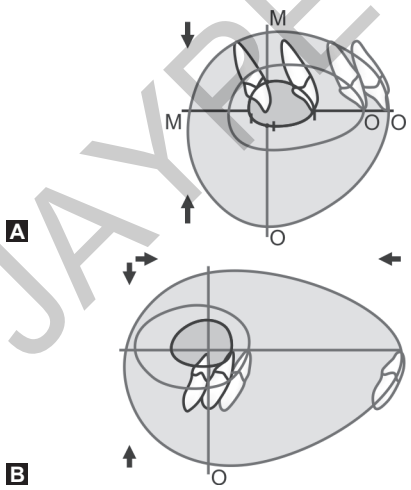

Figures 12.2A and B: Envelope of discrepancy

Radiographic examination: Prior to the surgical intervention the following radiographs are mandatory.

1. *Intraoral periapical radiographs:* These radiographs help in determining the condition of the teeth and alveolar bone. Presence of pathology around the tooth can also be determined using these radiographs.
2. *Panoramic radiographs:* Panoramic radiographs offer a wide view of the entire dentofacial region including the temporomandibular joint. These radiographs are useful in evaluation of bony pathologies, evaluation of the temporomandibular joints and the maxillary sinuses.
3. *Digital cephalometric radiographs:* Lateral and Frontal (in transverse problems) are essential for proper diagnosis and treatment planning. Cephalometric prediction tracings are highly useful in treatment planning.
   Softwares like Dolphin imaging can predict the surgical outcome of the patients.
4. *Submentovertex view:* A radiograph routinely used is the submentovertex view to determine the buccolingual thickness of the mandible as well as degree of deformity of the face.
5. *CT scan and MRI scans:* CT and MRI scans may be useful in cases where three dimensional assessment are required.

Study model evaluation: Study models are helpful in the evaluation of occlusion from all directions. They are used to assess interarch

JAYPEE BROTHERS

and intra-arch discrepancies. Study models are also used in mock surgery and Splint preparation.

Photographic evaluation: Extraoral photographs are particularly used to evaluate the facial changes that may occur after orthognathic surgery may be visualized by photographic mock surgery.

TMJ evaluation: The temporomandibular joint is evaluated by inspection, palpation, auscultation and by radiographic examination to evaluate joint movements and any pathology.

PRESURGICAL ORTHODONTICS

The objective of presurgical orthodontics is to prepare the patient for the intended orthognathic surgery and not to make the occlusal relationship as ideal as possible.

The following procedures are undertaken as a part of presurgical orthodontics:

i. Alignment of the arch.
ii. Space closure, unless it is to be utilized during surgery.
iii. Coordination of the arches.
iv. Intrusion of teeth.

Most severe skeletal jaw discrepancies are partly compensated by change in axial inclination of the anterior teeth. For example, mandibular retrognathism is associated with proclined lower anteriors to partially offset the skeletal discrepancy. Class III patients with prognathic mandible usually exhibit lingually tipped lower incisors to compensate for the skeletal relation. Presurgical orthodontics should correct these positions of compensation to position the teeth correctly over their supporting bone. This procedure is called decompensation.

Since most patients require postsurgical orthodontic treatment, it is unnecessary to carry out extensive presurgical tooth movement that can be accomplished more easily and quickly during or after the surgery. Presurgical orthodontic preparation should never extend more than one year (Fig. 12.3).

Mock Surgery

Soon after the completion of presurgical orthodontic treatment a mock surgery is performed on the upper and lower models mounted on a semiadjustable or fully adjustable articulator. The models are cut and repositioned in the desirable position. The segments are secured in their new position using sticky wax. The mock surgery they help in evaluation and possible modification of the surgical treatment plan. It also helps in the preparation of an occlusal splint to be used during surgery.

Orthognathic Surgery and Stabilization

The next step involves the surgical fracturing and repositioning of the bony segments. The teeth of the upper and lower arches are wired in occlusion to splints. The orthodontic arch wire and brackets can be used for the intermaxillary fixation. Intermaxillary fixation usually spans for 6 to 8 weeks following which the splint is removed.

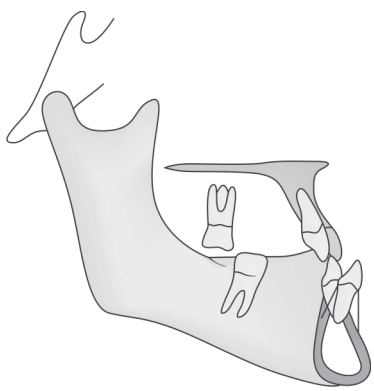

Figure 12.3: Decompensation

JAYPEE BROTHERS

MAXILLARY

Surgeries

Anterior Maxillary Segmental (Subapical) Osteotomy

Osteotomy of the anterior maxillary segment, usually from canine-to-canine, with displacement in a posterior, inferior, superior or rotational manner. Most commonly a combination of posterior and inferior repositioning of the anterior segment is performed, into the space created by simultaneous extraction of the maxillary first premolars. Anterior repositioning of the segment is almost impossible because of difficulties in stabilization and fixation, even with bone grafting and because the soft tissue pedicles often are insufficient to cover the surgical defects. The most popular techniques for this type of osteotomy are the Wassmund and Wunderer techniques (Fig. 12.4).

Wassmund Technique

An approach to anterior maxillary segmental osteotomy described by M Wassmund (1927), which relies on maintaining both the labial and palatal pedicles for vascular supply to the anterior maxillary segment. The osteotomies are carried out through mucosal tunnels created on the vestibular side by vertical incisions at the midline and at the level of the first premolar and through palatal tunnels created by connecting the extraction sockets of the first premolars to a midpalatal incision.

Wunderer Technique

An alternative approach to anterior maxillary segmental osteotomy described by S Wunderer (1963). The technique relies on the vestibular pedicle for vascular supply to the anterior maxillary segment, together with some blood supply from the incisive canal. Bilateral vertical incisions are performed on the vestibular side at the level of the first premolars. These are connected by a transpalatal horizontal incision, allowing reflection of the palatal flap posteriorly.

Complete Maxillary Osteotomy

Maxillary osteotomies traditionally are described in comparison with the common fracture patterns of the midfacial skeleton, named after the work of R LeFort (1900). The LeFort I, II and III fractures indicate the general levels at which the maxilla may be sectioned selectively from the rest of the skull, although the osteotomies are tailored to the individual patients and may deviate from the known fracture patterns (Fig. 12.5).

LeFort I Osteotomy

The most frequently performed of all midfacial osteotomies. It sections the midface through the walls of the maxillary sinuses, the lateral nasal walls and the nasal septum, at a level just superior to the apices of the maxillary teeth. Starting at the inferiorlateral margin of the pyriform aperture of the nose, the osteotomy line traverses the lateral walls of the maxillary sinus approximately 3 to 4 mm above the apices of the canine, premolars and molars. It passes across the canine fossa to the base of the zygomatic buttress and curves around and above the maxillary tuberosity to the lowest part of the pterygomaxillary fissure, where it crosses the posterior wall of the sinus at the same level. It then turns anteriorly through the lateral wall of the nose below the inferior turbinate to join the point of origin. The cut is made bilaterally. Following this, the pterygomaxillary plates are separated from the posterior aspects of the maxillary tuberosities, and the nasal septum is detached

JAYPEE BROTHERS

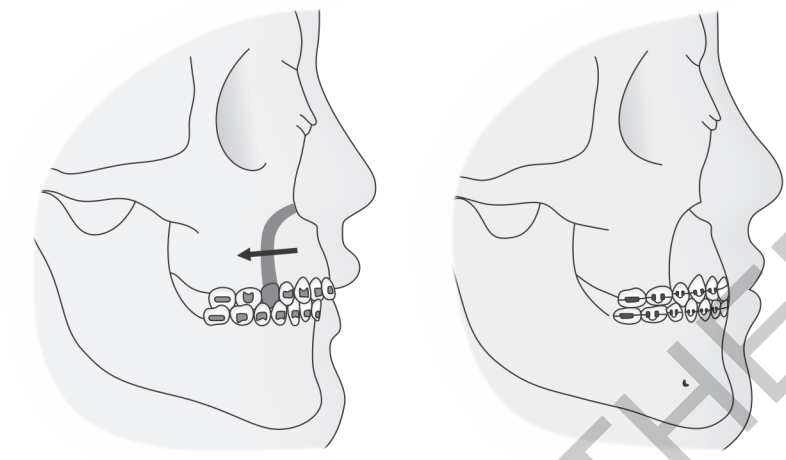

Anterior maxillary segmental osteotomy

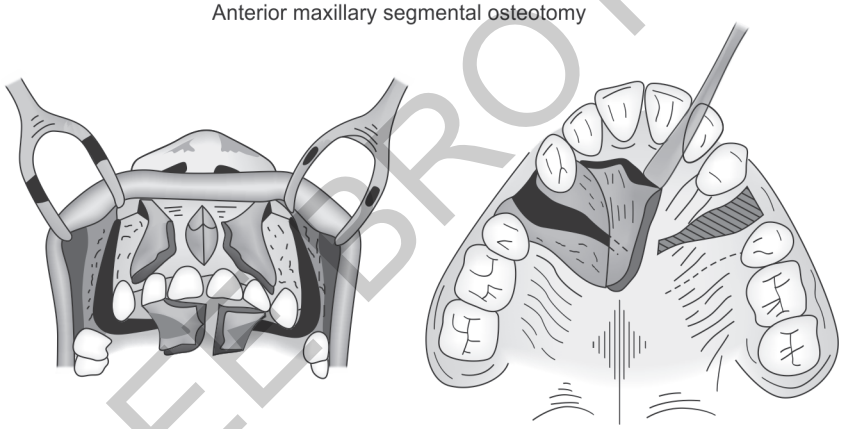

Wassmund technique

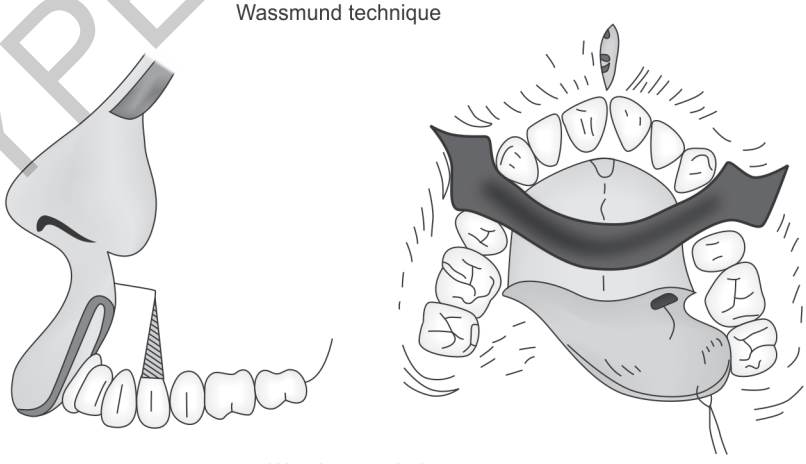

Wunderer technique

Figure 12.4: Maxillary surgeries

JAYPEE BROTHERS

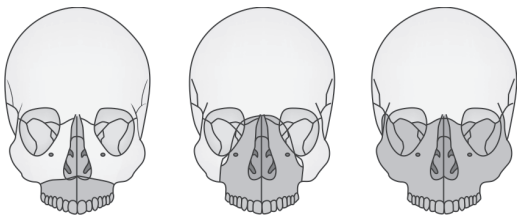

Figure 12.5: LeFort osteotomy

from the superior aspect of the hard palate by dividing it along its length with a chisel, so that the maxillary segment is freed. The LeFort I osteotomy offers a great number of options as the freed maxilla can be reoriented in all spatial planes. Further segmentation of the maxilla can be performed to correct transverse, anteroposterior and vertical discrepancies between the maxilla and the mandible.

LeFort II Osteotomy

A pyramid-shaped osteotomy that is identical to the Le Fort I procedure from the pterygoid column to the zygomatic buttress. From that point, instead of continuing anteriorly to the pyriform aperture of the nose, the cut is directed superiorly, towards the orbit. The cut is kept anteromedial to the infraorbital foramen and crosses the inferior orbital margin at a point halfway between the lacrimal duct medially and the infraorbital canal laterally. It then is continued posteriorly along the floor of the orbit and at right angles to the orbital rim until past the lacrimal groove and its contained lacrimal sac. The cut then is turned medially and anteriorly across the apex of the lacrimal groove and emerges medially to the orbit, just below the midpoint of the medial canthal attachment. The frontal process of the maxilla then is crossed and the cut becomes continuous with the osteotomy of the other side across the nasal bones. The nasal septum is divided at a higher level than during the LeFort I osteotomy, passing from the nasal bones anteriorly in a downward and backward direction to the posterior part of the septum just above the posterior nasal spine. The lateral nasal walls are fractured during mobilization of the maxilla at levels corresponding to the septal cut.

LeFort III Osteotomy

The basic LeFort III osteotomy, as originally described by P Tessier (1971), was designed to achieve anteroposterior movement of the whole facial mass, establishing normal dental occlusion and increasing orbital capacity, enlarging both the height and the depth of the orbits. The aim is to separate the facial mass from the cranial base along the interfrontofacial and the interpterygomaxillary planes. To do this, the osteotomy traverses, on each side, the medial orbital wall, the orbital floor and the lateral orbital wall to reach the region of the frontozygomatic suture. The frontal process of the zygomatic bone then is split sagittally (effectively splitting the lateral wall of the orbit) and the cut is continued inferiorly to complete division of the zygoma. The two sides are connected centrally through the frontonasal area, as in the LeFort II osteotomy. Pterygomaxillary and septal separation then are completed as in the LeFort II operation and the central facial block is mobilized. Many variants of LeFort III procedures exist that can be applied in the treatment of a variety of craniofacial problems and can be combined with surgery of the cranial vault.

Küfner Osteotomy

A modification of the LeFort II osteotomy originally described by J Küfner (1971). It is intended for patients with good nasal bridge and projection, but exhibiting retrusion of the infraorbital region and maxillary dentoalveolar

JAYPEE BROTHERS

area, with zygomatic flatness. The difference is that the osteotomy does not involve the nasal bridge, but is extended laterally to include the infraorbital rim and zygomatic process.

Multiple-piece Maxillary Osteotomy (Fig. 12.6)

When a severe transverse discrepancy between the maxillary and mandibular arches exists, a two- or a three- and sometimes even a four-piece maxillary procedure is performed, following a LeFort I osteotomy, to reposition each segment separately to an ideal relationship with the mandibular arch. Due to the increased risks entailed in the segmental procedures, most clinicians prefer to limit the number of segments into which they divide the maxilla.

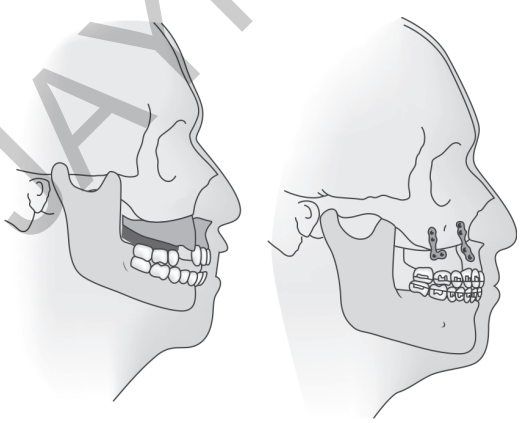

Figure 12.6: Multiple-piece maxillary osteotomy

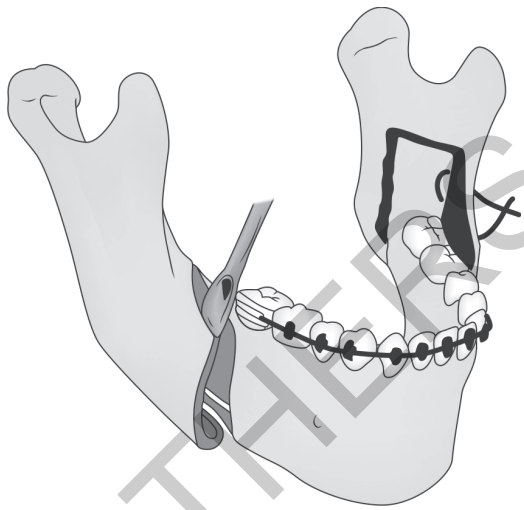

Figure 12.7: Bilateral sagittal split osteotomy

MANDIBULAR SURGERIES

Bilateral Sagittal Split Osteotomy (BSSO) (Figs 12.1, 12.7 and 12.8)

A mandibular orthognathic surgical procedure first reported in the English literature by R Trauner and HL Obwegeser (1957) and subsequently modified by others. In this procedure the rami of the mandible are split parallel with the sagittal plane to allow repositioning of the mandibular body into a more favorable relationship with the maxilla and the face. The procedure currently is routinely performed through an intraoral approach and can be used for advancement, setback and rotation of the distal (mandibular) segment.

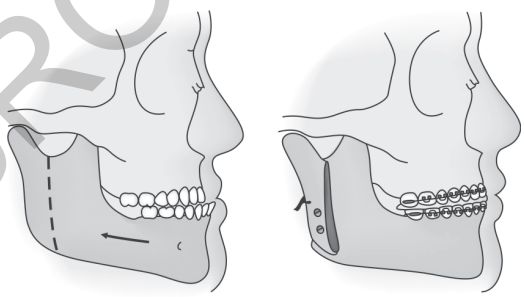

Figure 12.8: Bsso setback

When the distal segment is advanced, a gap is created in the buccal plate. When it is set back, a section of the buccal plate is removed to allow good approximation of the buccal cortex of the proximal segment against the lingual cortex of the distal segment on each side. The osteotomy design spares the mandibular nerve

JAYPEE BROTHERS

Essentials of Orthodontics

Salient Features

- Organized chapters for better understanding of the subject
- Review of topics for general practitioners and as a quick reference guide for the postgraduates in Orthodontics
- Edited with all latest contents in the subject
- Includes figures and flowcharts for understanding the concepts clearly
- Contains new topics like Anthropology, Forensic Orthodontics, Multispecialty Orthodontics, Community Orthodontics, etc.
- Provides exhaustive coverage of text, including the latest advancements
- Includes a chapter on Materials and Instruments in Orthodontics with all the latest materials, instruments, and techniques
- Contains terminologies and definitions for easy understanding
- Provides simple clinical tips and tricks for better judgment.



Aravind Sivaraj graduated from Tamil Nadu Government Dental College and Hospital, Chennai, Tamil Nadu, India, in 1997. He completed postgraduation in Orthodontics and Dentofacial Orthopedics, from the same institution, in 2001. He was the State topper in Tamil Nadu MDS entrance examinations in 1998. He is currently working as the Professor and Head, Department of Orthodontics and Postgraduate guide, Chhattisgarh Dental College and Research Institute, Rajnandgaon, Chhattisgarh, India. His current interests in Orthodontics include Computerized Cephalometrics, Orthodontic Biomechanics ,and Lingual Orthodontics. He has vast clinical and postgraduate teaching and research experience.

Dr Sivaraj has presented many clinical and research papers in national and international conferences and has published various articles in national and international journals. He has been examiner at various universities.

Shelving Recommendation
DENTISTRY

ISBN 978-93-5090-329-2

Available at all medical book stores
or buy directly from Jaypee Brothers through online shopping
at www.jaypeebrothers.com

JAYPEE BROTHERS
Medical Publishers (P) Ltd.
www.jaypeebrothers.com