others.com, for detailed information of orthopedic books, visit our website www.jaypeebrothers.com, for detailed information of orthopedic b

SECOND EDITION

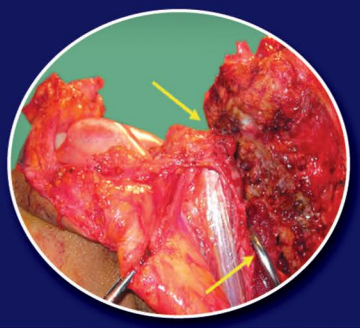

Essentials of
ORTHOPEDICS







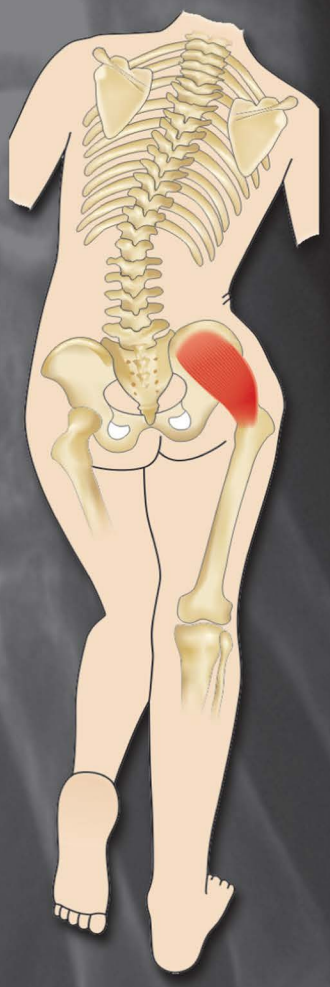

RM SHENOY

Foreword
M Shantharam Shetty

JAYPEE

Contents

CHAPTER 1: Introduction to Fractures and Dislocations 1

- **Fractures 1**
  Definition **1;** *Types of Fracture* **1;** *Deforming Forces* **4;** *Specific Types of Fracture* **4;**
  Signs and Symptoms of a Fracture **5;** *Healing of a Fracture* **5;**
  Factors Influencing Healing (Predisposing Factors for Delayed Union and Nonunion) **6;**
  Management of a Fracture **6;** *Basic Methods of Treating a Fracture* **7;** *Complications* **7;**
  Treatment of Delayed and Nonunions **9;** *Recent Concept of Fracture Healing* **14**
- **Dislocations 15**
  Definition of Dislocation and Subluxation **15;** *Types of Dislocation* **15;** *Traumatic Dislocation* **15;**
  Pathological Dislocation **17;** *Paralytic Dislocation* **17**

CHAPTER 2: Fractures in the Upper Limb 18

- **Fractures Around the Wrist 18**
  Bennett's Fracture **18;** *Rolando's Fracture* **19;** *Scaphoid Fracture* **20;** *Colles' Fracture* **25;**
  Smith's Fracture **29;** *Barton's Fracture* **30;** *Essex-Lopresti Fracture* **31;** *Chauffeur's Fracture* **32**
- **Fractures in the Forearm 33**
  Fracture of the Radius and the Ulna **33;** *Monteggia Fracture* **34;** *Galeazzi Fracture* **36**
- **Fractures Around the Elbow 37**
  Radial Head Fracture **38;** *Olecranon Fracture* **39;** *Capitulum and Trochlea Fractures* **40;**
  Medial and Lateral Epicondyle Fractures **40;** *Medial and Lateral Condyle Fractures* **41;**
  Supracondylar Fracture of the Humerus **42;** *Intercondylar Fracture* **50**
- **Fractures in the Arm and Around the Shoulder 51**
  Fracture Shaft of the Humerus **51;** *Fractures of the Proximal Humerus* **53;** *Fracture of the Clavicle* **54;**
  Fractures of the Scapula **56**

CHAPTER 3: Ligament Injuries and Fractures in the Lower Limb 60

- **Fractures of the Foot 60**
  Chopart's Injury **61;** *Lisfranc's Injury* **61;** *Fracture of the Fifth Metatarsal Bone* **63;** *Jones' Fracture* **63;**
  Pseudo-Jones' Fracture **64;** *Fracture of the Talus* **64;** *Calcaneus Fracture* **67**

- **Injuries Around the Ankle 71**
  Ligament Injuries **71;** *Bony Injuries of the Ankle (Pott's Fracture)* **71;**
  The Surgical Sequence of Reconstruction Followed in Vertical Compression Injury **77**
- **Tibial Diaphyseal Fractures 77**
- **Injuries Around the Knee Joint 79**
  Ligament Injuries **79;** *Meniscal Injuries* **82;** *Fracture of the Patella* **85;**
  Fractures of the Tibial Condyle (Tibial Plateau) **88;** *Fractures of the Femoral Condyles* **89**
- **Fracture of the Shaft of the Femur 91**
  Complications **92**
- **Fractures Around the Hip 92**
  Fracture of the Neck of the Femur **92;** *Intertrochanteric Fracture* **99;** *Subtrochanteric Fracture* **102**

CHAPTER 4: Dislocations 107

- **Dislocation of the Acromioclavicular Joint 107**
  Mechanism of Injury **107;** *Classification* **107;** *Clinical Features* **108;** *Diagnosis* **108;**
  Management **108**
- **Dislocation of the Shoulder 109**
  Types **109;** *Anterior Dislocation of the Shoulder* **109;** *Recurrent Anterior Dislocation* **110;**
  Posterior Dislocation of the Shoulder **111;** *Recurrent Posterior Dislocation* **112**
- **Dislocation of the Elbow 112**
  Types **112;** *Mechanism of Injury* **112;** *Diagnosis* **112;** *Management* **113**
- **Dislocation of the Hip Joint 114**
  Types **114;** *Mechanism of Injury* **114;** *Classification of Posterior Dislocation* **116;**
  Diagnosis **116;** *Management* **116;** *Complications* **118**
- **Dislocation of the Knee 118**
  Diagnosis **119;** *Treatment* **119**

CHAPTER 5: Fractures of the Pelvis 120

- **Formation of Pelvis 120**
  Mechanisms of Injury **121;** *Classifications* **122;** *Clinical Signs of Importance* **123;**
  Investigations **124;** *Principles of Management* **124;** *Complications of Fracture Pelvis* **125**
- **Malgaigne Fracture 125**

CHAPTER 6: Spinal Injuries 127

Structure of the Spinal Column **127;** *Structures that Impart Stability to the Spinal Column* **127;**
Functions of the Spinal Column **128;**

- **Spinal Injury 128**
  Denis' Three Column Concept **129;** *Mechanisms of Spinal Injuries* **129;**
  Specific Types of Spinal Column Injury **131;** *Spinal Cord Injury* **133;** *Management of Spinal Injuries* **134;**
  Management of Established Paralysis (Quadriplegia and Paraplegia) **136;** *Signs of Grave Prognosis* **137;**
  Perianal Anesthesia **137;** *Bulbocavernous Reflex* **137;** *Anal Wink* **137;** *Rehabilitation* **138;**
  A Ray of Hope for Paraplegics and Quadriplegics **138**

CHAPTER 7: Peripheral Nerve and Brachial Plexus Injuries 140

- **Peripheral Nerve Injury 140**
- **Structure of a Peripheral Nerve 140**
- **Response of a Neuron to Injury 140**
- **Classification of Nerve Injury 142**
  Based on Seddon's Classification (1943) **142;** *Based on Sunderland Classification (1951)* **142**
- **Diagnosis 142**
  Autonomic and Sensory Changes **142;** *Motor Changes* **142;** *Special Tests* **144;**
  Sensory Zones of a Peripheral Nerve **144;** *Diagnostic Tests* **144**
- **Management 145**
  Neuropraxia and Axonotmesis **145;** *Neurotmesis* **145;**
  Reconstructive Procedures in Cases of Absent Recovery **147;** *Management* **152;**
  Pathomechanics of Various Deformities and Signs **152**
- **Brachial Plexus 159**
- **Formation of Brachial Plexus 159**
- **Injuries of Brachial Plexus 160**
  Upper Plexus Injury—Erb's Paralysis **161;** *Lower Plexus Injury—Klumpke's Paralysis* **161;**
  Whole Plexus Injury **161;** *Management* **162**

CHAPTER 8: Bone and Joint Infections 165

- **Introduction 165**
  Osteomyelitis **165**
- **Nonspecific Infection 166**
  Acute Hematogenous Osteomyelitis **166;** *Chronic Osteomyelitis* **169;** *Subacute Osteomyelitis* **171;**
  Brodie's Abscess **171;** *Sclerosing Osteomyelitis of Garre* **172;** *Acute Suppurative Arthritis* **172;**
  Tom Smith's Arthritis of Infancy **173**
- **Specific Infections 174**
  Tuberculosis of Bones and Joints **174;** *Tuberculosis of the Spine* **175;** *Types of Kyphus/Gibbus* **176;**
  Cold Abscess **176;** *Pott's Paraplegia* **179;** *Tuberculosis of the Hip* **181;** *Tuberculosis of the Knee* **184;**
  Tuberculosis of the Ankle and Foot **186;** *Tuberculosis of the Shoulder and Elbow* **186;**
  Tuberculosis of the Wrist **186;** *Spina Ventosa (Tuberculous Dactylitis)* **187;**
  Mycotic Infections of the Bone **187;** *Maduromycosis* **187;** *Syphilitic Infection of the Bone* **188;**
  Parasitic Infestation of the Bone **188;** *Hydatid Cysts in the Bone* **188**

CHAPTER 9: Bone Tumors 190

- **Evaluation of a Bone Tumor 190**
  Clinical Evaluation **190;** *Radiological Evaluation* **192;** *Role of Angiography* **192;** *Bone Biopsy* **193;**
  Laboratory Investigations **194;** *Management* **194**
- **Common Benign Bone Tumors 195**
  Osteoid Osteoma **195;** *Benign Osteoblastoma* **195;** *Osteochondroma* **196;** *Chondroblastoma* **197;**
  Chondromyxoid Fibroma **198;** *Enchondroma* **198;** *Aneurysmal Bone Cyst (ABC)* **199;**
  Unicameral Bone Cyst (UBC) **200**

- **Common Malignant Bone Tumors 201**
  Giant Cell Tumor (GCT) **201;** *Osteosarcoma* **203;** *Chondrosarcoma* **206;** *Ewing's Tumor* **206;** *Myeloma* **207**
- **Metastatic Bone Disease 209**

CHAPTER 10: Slipped Capital Femoral Epiphysis, Perthes' Disease and Other Osteochondritis 211

- **Slipped Capital Femoral Epiphysis (SCFE) 211**
  Predisposing Factors **211;** *Pathology of the Slip* **212;** *Clinical Features* **212;** *Investigations* **213;** *Radiological Classification of the Slip* **213;** *Treatment* **213**
- **Legg-Calve-Perthes' Disease 216**
  Predisposing Factors **216;** *Pathology* **217;** *Radiological Features* **217;** *Clinical Features* **218;** *Head at Risk Signs* **219;** *Investigations* **220;** *Treatment* **220;** *Prognostic Factors* **222**
- **Idiopathic Avascular Necrosis/Osteochondritis 223**
  Kienbock's Disease **223;** *Kohler's Disease* **224**

CHAPTER 11: Intervertebral Disc Prolapse 227

- **Introduction 227**
  Pathomechanics of Intervertebral Disc Prolapse **227**
- **Diagnosis 228**
  Investigations **231;** *Treatment* **233**

CHAPTER 12: Nutritional, Endocrine, Degenerative and Autoimmune Disorders 235

- **Rickets and Osteomalacia 235**
  Rickets **236;** *Pathology* **237;** *Clinical Features* **237;** *Investigations* **238;** *Treatment* **239**
- **Osteoporosis 241**
  Types **241;** *Risk Factors* **241;** *Pathology* **241;** *Clinical Features* **241;** *Investigations* **241;** *Treatment* **242**
- **Osteoarthritis 242**
  Types **242;** *Etiology and Pathogenesis* **243;** *Pathology* **243;** *Clinical Features* **243;** *Diagnosis* **243;** *Management* **244**
- **Rheumatoid Arthritis 245**
  Definition **245;** *Etiology* **245;** *Joints, Organs and Tissues Involved* **245;** *Pathology* **245;** *Clinical Features* **245;** *Investigations* **245;** *Treatment* **246**
- **Hyperparathyroidism 247**
  Classification **247;** *Pathology* **247;** *Laboratory Investigations* **248;** *Treatment* **248**

CHAPTER 13: Congenital and Developmental Anomalies 250

- **Congenital Talipes Equinovarus 250**
  Etiology and Pathogenesis **250**; *Deformities in Clubfoot* **250**; *Diagnosis* **251**; *Treatment* **252**
- **Congenital Vertical Talus 256**
  Synonyms **256**; *Definition* **256**; *Etiology* **256**; *Pathological Anatomy* **256**; *Diagnosis* **256**; *Differential Diagnosis* **256**
- **Developmental Dysplasia of the Hip (DDH) 258**
  Predisposing Factors **259**; *Clinical Features* **259**; *Investigations* **262**; *Treatment* **263**
- **Skeletal Dysplasia and Other Conditions 264**
  Skeletal Dysplasias **264**
- **Important Skeletal Dysplasias 265**
  Spondyloepiphyseal Dysplasia **265**; *Multiple Epiphyseal Dysplasia* **265**; *Achondroplasia* **265**; *Hypochondroplasia* **266**; *Osteopetrosis* **266**; *Paget's Disease* **267**; *Fibrous Dysplasia* **268**; *Osteogenesis Imperfecta* **269**

CHAPTER 14: Miscellaneous Conditions 272

- **Mallet Finger 272**
  Etiology **272**; *Clinical Features* **272**; *Treatment* **272**
- **Boutonniere Deformity 272**
  Etiology **272**; *Clinical Features* **273**; *Treatment* **273**
- **Trigger Finger/Thumb 273**
  Etiology **273**; *Clinical Features* **274**; *Treatment* **274**
- **de Quervain's Disease 274**
  Clinical Features **274**; *Treatment* **274**
- **Dupuytren's Contracture 274**
  Etiology **275**; *Clinical Features* **275**; *Treatment* **275**
- **Carpal Tunnel Syndrome 275**
  Etiology **275**; *Clinical Features* **275**; *Treatment* **275**
- **Tennis Elbow 276**
  Pathology **276**; *Clinical Features* **276**; *Test* **277**; *Treatment* **277**
- **Golfer's Elbow 277**
  Test **277**; *Treatment* **277**
- **Supraspinatus Tendinitis 278**
  Treatment **278**; *Calcific Tendinitis* **278**; *Clinical Features* **278**; *Treatment* **278**
- **Subacromial Bursitis 278**
  Etiology **278**; *Clinical Features* **279**; *Treatment* **279**
- **Painful Arc Syndome 279**
  Etiology **279**; *Clinical Features* **279**; *Treatment* **279**

- **Periarthritis Shoulder 279**
  Clinical Features **279;** *Treatment* **280**
- **Calcaneal Spur 280**
  Etiology **280;** *Clinical Features* **280;** *Treatment* **280**
- **Ganglion 280**
  Treatment **281**
- **Baker's Cyst 281**
  Treatment **281**
- **Neuropathic Joint 282**
  Etiology **282;** *Pathology* **282;** *Clinical Features* **282;** *Diagnosis* **282;** *Treatment* **283**
- **Congenital Torticollis or Wry Neck 283**
  Natural Course of the Fibromatosis **283;** *Clinical Features* **283;** *Diagnosis* **283;** *Treatment* **283;** *Prognosis* **283**
- **Idiopathic Avascular Necrosis of the Head of the Femur 283**
  Other Names **283;** *Clinical Features* **283;** *Staging: Ficat and Arlet (1980)* **284;** *Radiological Features of AVN* **284;** *Treatment* **284**
- **Spondylolisthesis 284**
  Types: Based on Wiltse Classification **284;** *Etiopathogenesis* **284;** *Clinical Features* **285;** *Diagnosis* **285;** *Treatment* **285**
- **Bursa and Bursitis 286**
- **Myositis Ossificans 286**
  Predisposing Factor **287;** *Pathophysiology* **287;** *Treatment* **287**

CHAPTER 15: Fractures in Children 288

- **Types of Injuries 288**
  Physeal Injuries **288;** *Thurston Holland Sign (Shiny Corner Sign)* **289;** *Plastic Deformation* **291;** *Buckle Fractures* **291;** *Greenstick Fractures* **292**
- **Common Fractures in the Lower Limb: Diagnosis and Management 292**
  Fracture of Shaft of Femur in Children **292;** *Fracture of Neck of Femur in Children* **293**

CHAPTER 16: Poliomyelitis 295

- **General Information 295**
- **Epidemiology 295**
- **Pathogenesis 295**
  Stages of Poliomyelitis **296;** *Differential Diagnosis* **296;** *Laboratory Diagnosis of Poliomyelitis* **296;** *Treatment of Poliomyelitis* **296**
- **Immunization and its Current Status 297**

- **Skeletal Deformities in Poliomyelitis 297**
  Pathogenesis of Deformities **297;** *Preoperative Considerations* **298;** *Design of Surgical Procedures* **298**
- **Deformities Around the Hip 298**
  Role of Iliotibial Band in Contractures **299;** *Paralytic Dislocation of the Hip* **299;**
  Surgical Procedures for Release of Contractures **299;**
  Surgical Procedures for Paralytic Dislocation of the Hip **299**
- **Deformities of Foot and Ankle 300**
  Tendon Transfers and Corrective Procedures for Muscle Insufficiency **300;**
  Bony Procedures for Deformity Correction **301;** *Triple Arthrodesis* **301;**
  Other Bony Procedures **301;** *Claw Toes* **302;** *Correction of Claw Toes* **302**

CHAPTER 17: Cerebral Palsy 303

- **Etiology 303**
  Prenatal Causes **303;** *Natal Causes* **303;** *Postnatal Causes* **303**
- **Terminologies Used in the Assessment of Limb Involvement 303**
  Monoplegia **303;** *Hemiplegia* **304;** *Paraplegia* **304;** *Triplegia* **304;** *Quadriplegia* **304;**
  Whole Body Involvement **304**
- **Clinical Evaluation of a Child with Cerebral Palsy 304**
  Signs of Prognosis **304**
- **Treatment 305**
  Role of Surgery **306;** *Procedures* **306**

CHAPTER 18: Gait 307

- **Definition 307**
- **Phases 307**
- **Gait Cycle 307**
  Common Terminologies Used in the Analysis of Gait **307**
- **Abnormal Gaits 308**
  Due to Muscle Weakness, e.g. Poliomyelitis **308;**
  Due to Changes in the Bones and Joints **308;**
  Due to Abnormalities in the Nervous System **309**
- **Trendelenburg Gait 309**
  Pathomechanics of Trendelenburg Gait **310**

CHAPTER 19: Amputations 311

- **Definition 311**
- **Indications 311**

- **Types of Amputations 311**
  General Amputations **311;** *Specific Amputations* **311**
- **An Ideal Stump of Amputation 313**
  Recommended Ideal Length of the Stump **313**

CHAPTER 20: Arthroscopy and Total Joint Arthroplasty 315

- **Arthroscopy 315**
  Evolution of Arthroscopes **315;** *Components of an Arthroscope* **315;** *Technique* **315;**
  Advantages of Arthroscopic Procedures **316;** *Limitations of the Arthroscopic Procedures* **316;**
  Complications **316;** *Common Arthroscopic Procedures* **316**
- **Total Joint Replacement (Arthroplasty) 316**
  Evolution **317;** *Complications* **317;**
  Postoperative Rehabilitation after Joint Replacement Surgery **317**

CHAPTER 21: Implants and Instruments 318

- **Introduction 318**
  Materials Used for Orthopedic Implants **318;** *Desirable Properties of an Implant* **318;**
  Types of Implants **318;** *Types of Prosthesis* **319;** *Implant Selection* **319;** *Implant Insertion* **320;**
  Asepsis in the Operating Room **320**
- **Surface Implants 320**
  Screws **320;** *Plates* **321**
- **Intramedullary Implants 323**
  Rigid Nails **323;** *Hollow Nails* **324;** *Elastic Nails* **324**
- **Biodegradable Implants 325**
  Dynamic Hip Screw and a Barrel Plate **325;** *Jewett Nail* **325;**
  Cannulated Cancellous Hip Screw **325**
- **General Instruments Used in Orthopedics 326**
  Mallet **326;** *Chisel* **327;** *Osteotome* **327;** *Bone Gouge* **327;** *William Arbuthnot Lane* **328;**
  William Ferguson **328**
- **Designs of Limb Lengthening Apparatus 328**
  Ilizarov Fixator **328;** *Orthofix Type* **328;** *Wagner Type* **328**

Index *331*

3 Ligament Injuries and Fractures in the Lower Limb

Introduction, general information, mechanism of injury, diagnosis, treatment and complications are dealt with as follows:

- *Fractures of the foot*
- *Injuries around the ankle*
- *Injuries around the knee joint*
- *Fracture of the shaft of the femur*
- *Fractures around the hip*

FRACTURES OF THE FOOT

Introduction

The foot has a very important role in locomotion. It is subjected to constant stress of weight bearing. Loss or impairment of anatomy of the foot following injury may thus lead to serious disability and malfunction. Hence, a subspecialty of ***Foot and ankle surgery*** has evolved and meticulous foot and ankle surgery is being performed these days.

The foot is generally divided into (Fig. 3.1):

A. Hindfoot consisting of calcaneus and talus.
B. Midfoot consisting of navicular, cuboid and the three cuneiforms.
C. Forefoot consisting of metatarsals and phalanges.

Hindfoot

The articulation between the talus and the calcaneus is known as subtalar joint. Inversion and eversion movements take place at this joint.

The talus articulates with the ankle mortise formed by the lower end of tibia and fibula. This forms the ankle joint. Dorsiflexion and plantar flexion movements take place at the ankle joint.

Midfoot

The tarsal bones of the midfoot have multiple articulations. Movements at these articulations occur in a very unique manner, as a unit. When inversion/eversion takes place at the subtalar joint, the tarsal bones lock themselves and move together only to get unlocked when a movement occurs in the opposite direction (eversion/inversion).

It is this, effective, constant and multidirectional adjustment of the tarsus, helps the foot to adapt

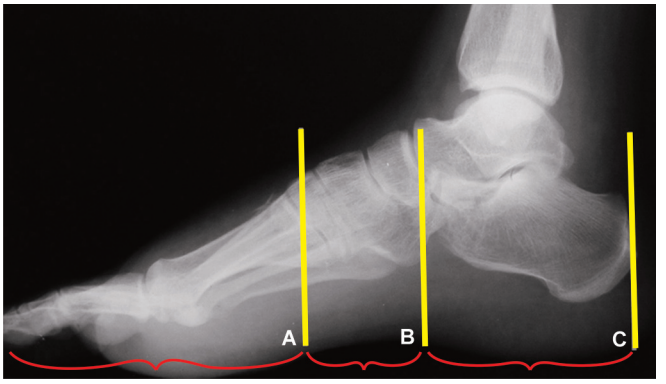

Figure 3.1

Lateral radiograph of a normal foot showing: The forefoot (A); The midfoot (B); The hindfoot (C).

JAYPEE BROTHERS

itself to any terrain which results in a smooth propulsion. Thus, loss or impairment of this mechanism following injury to the tarsal bones/ articulation, results in severe disability.

The articulation between the hindfoot and the midfoot is known as midtarsal joint formed by talonavicular and calcaneocuboid joints. It is also known as ***Chopart's joint*** named after ***Francois Chopart*** (1743–1795) who performed amputations at this level—***Chopart's amputation.*** The procedure removes almost all the insertions of tendons around the ankle and renders the ankle joint unstable.

The articulation between the midfoot and forefoot is known as ***Lisfranc's joint*** named after ***Jacques Lisfranc*** a French surgeon in Napoleon's army. An amputation at this level is known as ***Lisfranc's amputation*** as he performed amputations at this level for frostbite and gangrene, on soldiers at the Russian front.

Forefoot

The articulations between the metatarsals and phalanges are more firm and regular and do not allow multidirectional adjustments. These joints are more involved in transmission of body weight during push off phase of gait cycle. Hence, any disturbance in anatomy following injury will affect the push off phase of gait cycle (See chapter on gait).

The important injuries occurring in the foot are:

1. Chopart's injury
2. Lisfranc's injury
3. Jones' fracture
4. Pseudo-Jones' fracture
5. Talus fracture
6. Calcaneus fracture

Chopart's Injury

Definition

It is a fracture dislocation involving the talonavicular and the calcaneocuboid joint (Midfoot).

Mechanisms of Injury

Common mechanism (80%): Is a severe twisting injury on a plantar flexed and inverted foot causing medial and upward displacement of distal fragments.

Rare mechanism: Is an 'Eversion injury' which causes lateral displacement of distal fragments.

In both the mechanisms, the talus always remains in the ankle mortise.

Fractures associated with Chopart's injury

1. Calcaneus fractures
2. Talus fractures
3. Navicular fractures

Management

Prompt and early accurate reduction along with stabilization is the treatment of choice. Hence, nonoperative methods have a limited role to play. They are useful only in minor grades of injury.

Prognosis

Poor prognosis is seen in those cases which are associated with severe soft tissue injury, fracture of other bones of the foot, persistent malalignment after treatment and in those which present late.

Lisfranc's Injury

Definition

This is a fracture or a dislocation or a fracture dislocation occurring at the junction between the tarsal bones of the midfoot and the metatarsal bones of the forefoot named after ***Jacques Lisfranc*** a French surgeon in Napoleon's army.

Note: *Lisfranc described this injury in soldiers who fell down from their horses with their foot caught in the stirrup (a fall without foot getting released from the stirrup).*

Mechanism of Injury

Mechanism involves severe plantar flexion of the foot, e.g. stepping into a small hole, sports-related injuries, motor vehicle accidents, falling from a height etc.

Lisfranc ligament diagonally connects the 1st (medial) cuneiform with the base of the 2nd metatarsal. If it remains intact at the time of injury, it exerts a traction force on the bone which depending on the direction of pull, causes, either an avulsion of the lateral border of the 1st (medial) cuneiform or an avulsion of the base or medial border of the 2nd metatarsal. If it tears, these fractures do not occur.

JAYPEE BROTHERS

Types

Two basic types are described.

Homolateral (Fig. 3.2A)

- All the metatarsals are displaced to the same side.
- Usually 2nd to 5th metatarsals are involved which displace laterally as a unit.
- May involve all 5 metatarsals.
- More common than divergent.

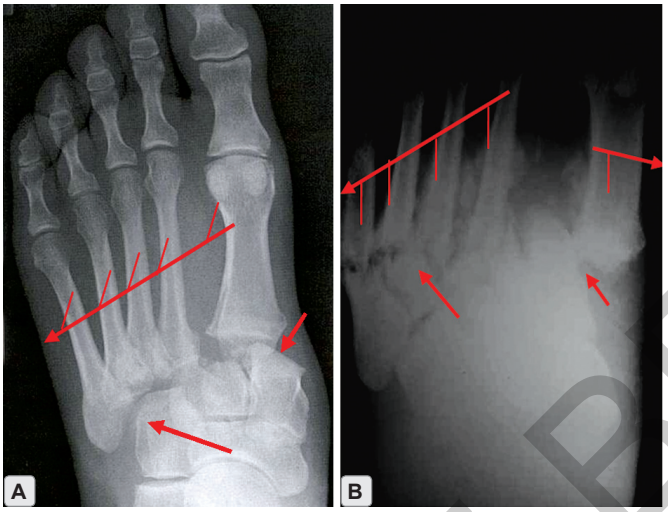

Figures 3.2A and B

Radiographs of the foot showing (A) Homolateral and (B) Divergent types of Lisfranc's injury. Note the direction of displacements of the 1st metatarsal and the 2nd, 3rd, 4th and 5th metatarsals.

Divergent (Fig. 3.2B)

- Usually involves medial displacement of the 1st metatarsal and lateral displacement of 2nd-5th metatarsals.
- Occasionally medial displacement of only the 1st metatarsal may be seen.
- May be associated with a fracture of the 1st cuneiform.
- Usually more severe than homolateral.

Note: *Rarely, isolated injury involving one or two metatarsals which get displaced from others, is seen.*

Fractures associated with Lisfranc dislocations

- Base of 2nd metatarsal fracture.
- Cuneiform fracture.
- Fractures of shafts of metatarsals.
- Dislocations of the 1st (medial) and 2nd (middle) intercuneiform joint and cuneonavicular joint.
- Fractures of the navicular bone.

Imaging (Figs 3.2C to E)

Conventional radiographs are usually sufficient to demonstrate the injury. Normal alignment of the cuneiforms and the bases of the metatarsals are as follows:

- Lateral border of 1st metatarsal is aligned with lateral border of 1st (medial) cuneiform in anteroposterior (AP) view.
- Medial border of 2nd metatarsal is aligned with medial border of 2nd (intermediate or middle) cuneiform in AP view.

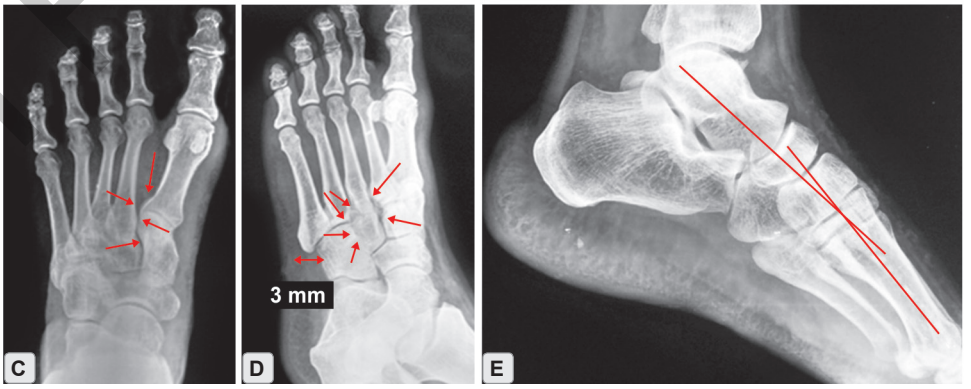

Figures 3.2C to E

Radiograph of a normal foot showing (C) AP view of the foot. (D) Oblique view of the foot. (E) Lateral view of the foot (Refer text for details).

JAYPEE BROTHERS

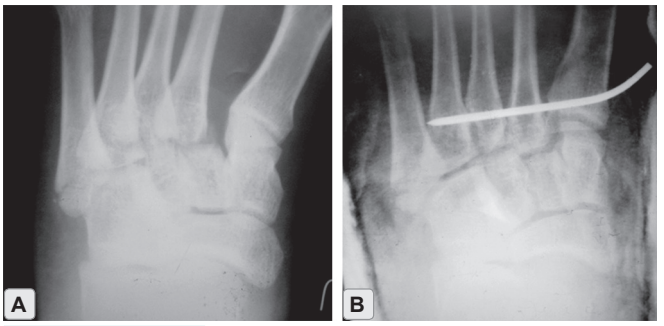

Figures 3.3A and B

Successful reduction and stabilization of a Lisfranc's injury—Homolateral type by (B) closed reduction and pinning. In this, the findings are fracture base of 2nd metatarsal, fracture base of 5th metatarsal—both are avulsion fractures and dislocation of 2nd to 5th metatarsals which are displaced laterally.

- Medial and lateral borders of the 3rd (lateral) cuneiform is aligned with medial and lateral borders of 3rd metatarsal in oblique view.
- Medial border of 4th metatarsal is aligned with medial border of cuboid in oblique view.
- Lateral margin of the 5th metatarsal may project lateral to cuboid by as much as 3 mm in oblique view.
- In lateral view, a line drawn along the long axis of talus intersects a line drawn along the long axis of the 1st metatarsal.

Any loss of this pattern of alignment is an indicator of this injury.

Management

Restoration of anatomical alignment at the earliest is the key for successful result. Hence, closed methods of reduction/fixation and immobilization have a role to play only in less severe forms of injury. Severe forms are always treated by open reduction and internal fixation (Figs 3.3A and B).

Complications

a. Compartment syndrome involving the foot compartment (immediate).
b. Deformities of the foot due to persistent malalignment resulting in chronic pain (early) and degenerative arthritis involving tarsal joints (late).

Prognosis

Severe soft tissue injury, persistent malalignment, associated fractures and late presentation results in poor prognosis.

Note: *Instability on weight bearing can occur with ligament injuries alone, without a fracture or a dislocation.*

Revision Questions

Q. What is Chopart's and Lisfranc's joint? Why it is named so?
Q. What is Chopart's and Lisfranc's amputation?
Q. What is Chopart's and Lisfranc's injury?
Q. What is the mechanism of Chopart's and Lisfranc's injury?
Q. What is Lisfranc's ligament? What are the types of Lisfranc's injury?
Q. What are the fractures associated with Chopart's and Lisfranc's injury?
Q. How do you manage Lisfranc's and Chopart's injury?
Q. What are the complications of Chopart's and Lisfranc's injury?
Q. What is the prognosis of Chopart's and Lisfranc's injury?

Fracture of the Fifth Metatarsal Bone

Fracture involving proximal part of the fifth metatarsal is the most common injury among metatarsal fractures. The distal and the mid shaft fractures of the 5th metatarsal are not common.

Types:
A. Jones' fracture.
B. Pseudo-Jones' fracture (Tennis fracture).

Jones' Fracture

This injury was first described in 1902 by Sir Robert Jones in an article titled "Fractures of the Base of the Fifth Metatarsal Bone by Indirect Violence." He himself is said to have suffered from this injury (fracture) after dancing.

Definition

It is a transverse fracture occurring at base of the fifth metatarsal 1.5–3.0 cm distal to the tuberosity, either at the metaphyseo-diaphyseal or proximal diaphyseal region (Fig. 3.4).

JAYPEE BROTHERS



Figure 3.4
Radiograph of a Jones' fracture.



Figure 3.5
Pseudo-Jones' fracture.

Diagnosis

1. Pain in the region of the fifth metatarsal after an indirect violence.
2. Difficulty in walking.
3. X-ray confirming the diagnosis.

Treatment

Always treated by a non-weight bearing cast for the fear of becoming displaced and causing nonunion at a later period. Nonunion may need bone grafting.

In athletes and in displaced fractures, surgical stabilization is considered.

Pseudo-Jones' Fracture

Definition

It is an avulsion fracture occurring at the base of the fifth metatarsal as a result of the pull of peroneus brevis tendon (Fig. 3.5).

Treatment

Heals well with a compression bandage or a walking cast in about 3 weeks without complications.

Note: *Mechanism of injury—is almost similar both for Jones' and Pseudo-Jones' fractures. It is a lateral ankle strain with sudden inversion of the foot which causes these fractures. Depending on the area that is subjected to maximum stress, fractures occur in different regions of the fifth metatarsal i.e. from the base to the diaphysis.*

Fracture of the Talus

General Information
Talus also known as 'Astragalus', is a unique bone which has no muscle or tendon attachments and held in place mainly by bony and ligamentous support. Superiorly, it articulates with the inferior articular surface of the tibia; inferiorly with the superior articular surface of the calcaneus; medially with the medial malleolus; laterally with the lateral malleolus and anteriorly with the navicular.

Hence, it plays an important role in the function of the ankle and the foot by being responsible for 90% of the movement occurring at the ankle and the foot.

History

Sir Astley Cooper (1832) gave a first hand account of a case of dislocated talus which he treated. (Mr Downes 20th July 1820, who fell down from his horse……)

Anderson (1919) gave the name **'Aviator's Astragalus'** because he found these injuries occurring in Aviators when they crashed with their machines. The foot resting on the rudder bar took the impact of extreme dorsiflexion thereby causing injuries of the talus. Namely, fractures, dislocations and fracture-dislocations.

JAYPEE BROTHERS

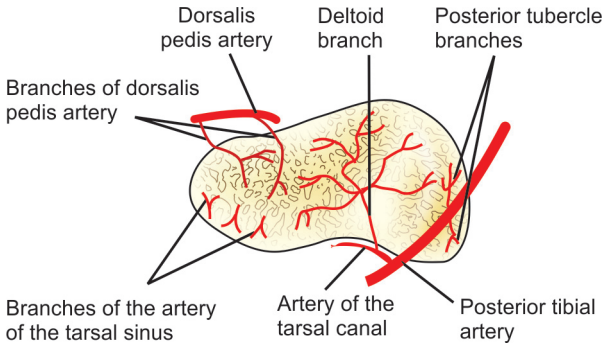

Figure 3.6

Blood supply to the talus. Note that the important supply is through the artery of the tarsal canal which anastomoses with the artery of the sinus tarsi.

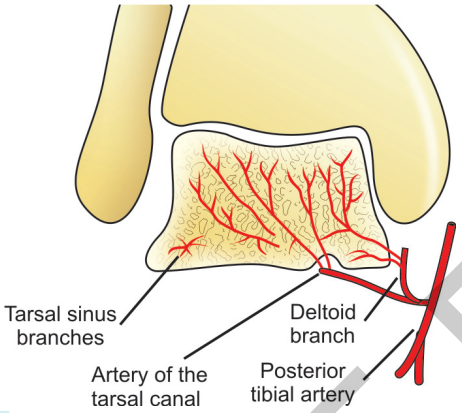

Figure 3.7

Blood supply of the talus in coronal plane.

Blood Supply (Figs 3.6 and 3.7)

GL Mulfinger and J Trueta have described in detail the blood supply of the talus (J Bone Joint Surgery 1970;52B.).

The blood supply to the talus is derived from three main arteries of the leg i.e. the anterior tibial, the posterior tibial and the peroneal artery through a *periosteal network* and through *two discrete vessels* as follows.

1. Posterior tibial artery—through calcaneal branches
2. Anterior tibial artery—through anterolateral/anteromedial malleolar branches or through medial tarsal artery
3. Peroneal artery—through perforating branches
4. Artery of the tarsal canal, a branch of posterior tibial artery
5. Artery of the sinus tarsi, a branch of dorsalis pedis artery

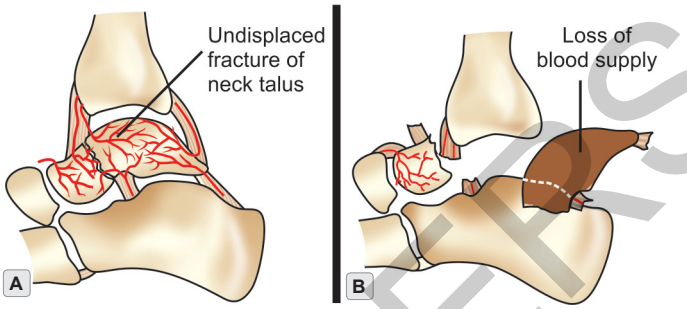

Figures 3.8A and B

(A) Fracture of the neck of the talus alone does not disturb the blood supply without displacement of the body; (B) When the body is displaced the blood supply is lost.

Note:

Two plexus are formed by anastomosis.

i. In the region of the posterior tubercle.

ii. In the region of the sinus tarsi.

The calcaneal branches of posterior tibial artery form a plexus in the region of posterior tubercle while the anterolateral malleolar branches of anterior tibial artery along with branches from dorsalis pedis artery form a plexus in the region of sinus tarsi. Thus, 'vascular slings' are formed all around the talus due to anastomosis.

An undisplaced fracture of the neck disturbs the blood supply the least. Hence, the incidence of AVN is low (Intact 'vascular slings').

A displaced fracture neck of the talus, disturbs the blood supply to the body and causes avascular necrosis. Similarly, a fracture of the body of the talus impairs the blood supply to the body and causes avascular necrosis (Damage to 'vascular slings') (Figs 3.8A and B).

Mechanism of Injury

Talar neck fractures: Extreme dorsiflexion of the ankle or direct axial loading causes rupture of the posterior capsule and impaction of the talar neck against the distal tibia resulting in a vertical fracture of the neck. Subsequently, one of two things can happen. Either the foot subluxates forwards with body of the talus adopting a position of equinus because of the recoil or if the dorsiflexion continues the body of the talus dislocates and is pushed backwards out of the ankle mortise. In the second scenario, the body of the talus goes on to lie between the medial malleolus and Achilles tendon with the fracture surface facing upwards and laterally (Ankle mortise has been described under ankle injuries).

JAYPEE BROTHERS

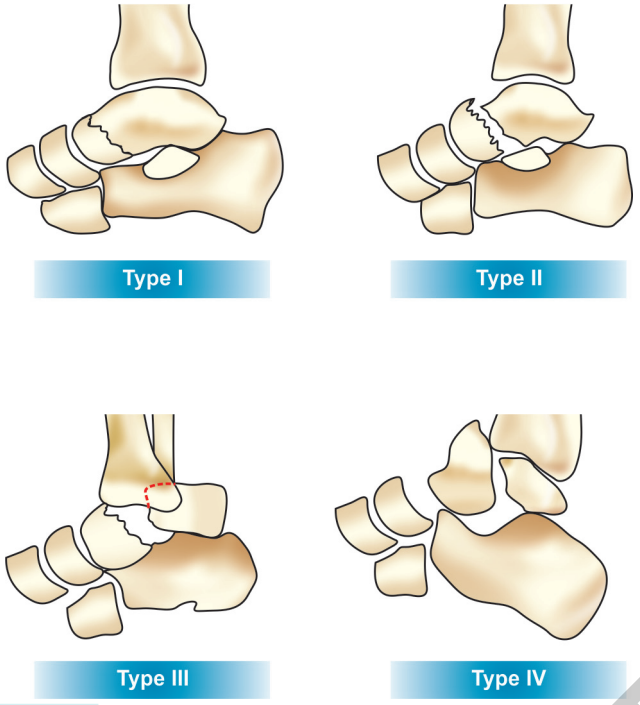

Figure 3.9

Different types of fracture of talus based on Hawkins' classification modified by Canale and Kelly.



Figure 3.10

Radiographs of different fractures based on Hawkins' classification and modification by Canale and Kelly. *Type I*: Undisplaced fracture. *Type II*: Displaced fracture with subtalar subluxation/dislocation. *Type III*: Displaced fracture with both subtalar and ankle subluxation/dislocation. *Type IV*: Displaced fracture with subtalar, ankle and talonavicular dislocation.

Classification of the Fractures/Dislocations and Fracture—Dislocations of the Talus

Following injuries are seen in the talus:

A. Talar neck fracture
B. Talar body fracture
C. Talar head fracture (rare)
D. Subtalar dislocation
E. Total talar dislocation

Classification of talar neck fracture

Based on Hawkins' classification (1970) it is classified as follows (Figs 3.9 and 3.10):

I. Undisplaced vertical fracture.
II. Displaced fracture with subtalar joint subluxation/dislocation.
III. Displaced fracture with both subtalar and ankle dislocation.

Canale and Kelly, proposed a IV Group.

IV. Displaced fracture with subtalar, ankle and talonavicular dislocation.

Classification of talar body fractures

Based on Sneppen classification (1977) they are classified as follows:

I. Osteochondral dome fractures
II. Coronal, sagittal, horizontal shear fractures
III. Posterior process fractures
IV. Lateral process fractures (Snowboarder's fracture)
V. Crush fractures

Talar head fractures are rare and generally associated with talonavicular dislocation/subluxation.

Complications

a. Osteochondral fracture may cause loose body inside the joint which results in persistent pain and limitation of movement.
b. Nonunion in fracture neck of the talus.
c. Avascular necrosis of the body of the talus.
d. Degenerative arthritis of the ankle.

JAYPEE BROTHERS

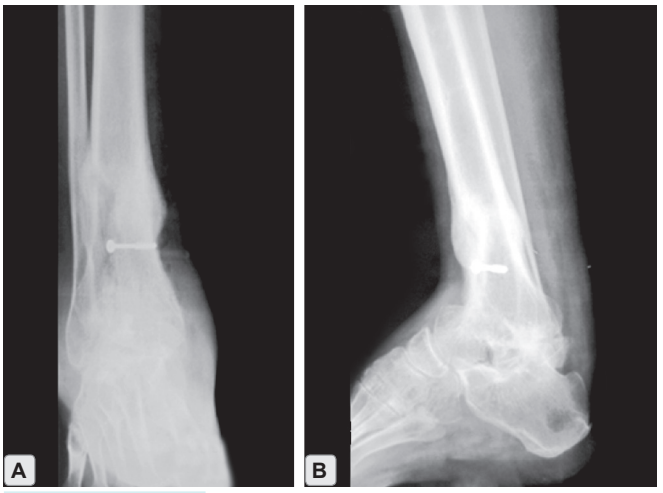

Figure 3.11A and B

AP and lateral view of ankle arthrodesis done for an old fracture talus with nonunion and AVN of the body. Note that the calcaneus is not plantigrade. The ankle is in 5 degrees of dorsiflexion. This will result in calcaneocavus deformity of the foot over a period of time when the patient starts weight-bearing.

Hawkins' sign:
This is a sign seen at the end of 6-8 weeks which indicates presence of good vascularity. This can be clearly visualized in a mortise view as a subchondral radiolucent band in the dome of the talus.

Treatment

A. *Nonoperative:* Fractures which are undisplaced/ displaced less than 1 mm are immobilized in plaster cast.

B. *Operative:*
Internal fixation: Displaced fractures such as Types II, III and IV neck fractures; coronal, sagittal and horizontal shear fractures of the body are openly reduced and internally fixed.
Arthroscopy: Arthroscopic procedures are done for removal of loose body, management of osteochondral lesions and in early degenerative arthritis of ankle.
Arthrodesis: Indicated in secondary complication of nonunion, avascular necrosis and degenerative arthritis (Figs 3.11A and B).
Total joint arthroplasty: Indicated in secondary degenerative arthritis (without AVN).
Talectomy or Astragalectomy: Rarely done as it renders the ankle highly unstable.

Essay Questions

Q. Describe the blood supply of talus. Discuss the mechanism of injury, diagnosis and management of fracture neck of talus and its complications.
Q. Classify fractures of the talus. Discuss the management of the fractures of the talus. Enumerate their complications.

Calcaneus Fracture

Also known as " Lover's fracture"and "Don Juan fracture".

Functional Importance of the Calcaneus

a. Acts as a lever arm for gastrosoleus complex.
b. Transmits the body weight.
c. Supports and maintains the lateral column of the foot.

Hence, when its anatomy is not restored after a fracture the above functions get impaired and the gait is affected.

Surgical Anatomy

The calcaneus has two articular surfaces.

i. Anterior
ii. Superior.

The anterior articular surface is saddle shaped and articulates with the cuboid bone.

The superior articular surface has three articular facets.

1. The concave anterior facet.
2. The concave middle facet.
3. The convex posterior facet.

The anterior facet articulates with the anterior talar facet and is supported by the beak of the calcaneus. The middle facet lies over sustentaculum tali. Between the middle and the posterior facet is the calcaneal groove/ sulcus.

Those fractures which involve the articular surfaces produce complex articular surface irregularities. Hence they need to be managed accurately in order to reduce the functional disability after recovery.

JAYPEE BROTHERS

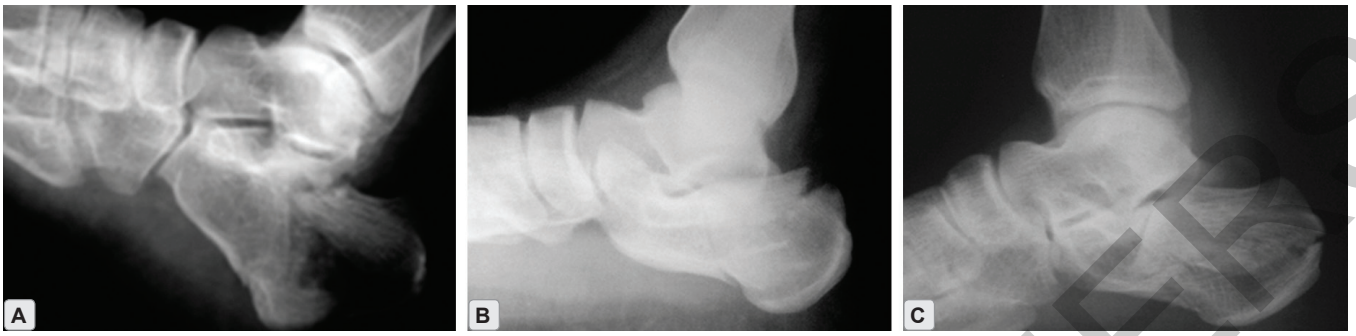

Figures 3.12A to C

Different types of calcaneal fractures based on Essex-Lopresti classification: (A) Extra-articular type; (B) Tongue, type; (C) Joint depression type.

Mechanisms of Injury

a. *Axial loading and shear:* Occurs when a person falls from a height and lands on the heel. The talus is driven down onto the calcaneus causing an articular surface fracture thereby disturbing the subtalar joint anatomy.
b. *Direct impact by blunt force:* Results in extra-articular fractures of the plantar tuberosity and the body.
c. *Twisting injuries:* Results in avulsion fractures of the calcaneus because of the pull of tendons and ligaments. For example, posterior tuberosity fracture due to the pull of tendo-Achilles.

Note: *When a person presents with calcaneus fracture, there is always a need to examine the pelvis, spine and the other limb, especially when there is a history of fall from a height or a high velocity injury. This is to rule out more serious injuries such as fracture of the pelvis and the spine. Also, it is very important to note whether there is developing compartmental syndrome involving the central compartment of the foot.*

Classifications of Fracture Calcaneum

Essex-Lopresti classification (Figs 3.12 and 3.13):

a. Extra-articular
b. Intra-articular
   – Tongue type
   – Joint depression type

When there is an impact of axial loading, the calcaneum is subjected to two deforming forces which are transmitted through the talus.

a. Shearing force
b. Compression force

The pathomechanics following such an impact is explained below.

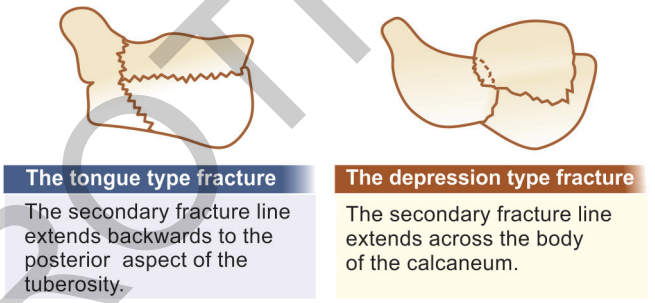

Figure 3.13

Diagrammatic representation of Essex-Lopresti classification of fracture involving the joint.

Pathomechanics of intra-articular fracture: When the calcaneus is subjected to axial loading the sharp edge of the lateral process of talus is driven into the 'crucial angle of Gissane' of the calcaneus (see Fig. 3.16B). Because of this, a shear fracture of the body develops with the fracture line extending from the lateral cortex to sustentaculum tali medially. This passes through the medial 1/3 or 1/2 of the posterior facet of the calcaneum.

If the force continues, a compression stress generated causes a secondary fracture. This fracture may be a tongue type or joint depression type.

Sander's classification: Developed in 1992, based on coronal and axial CT scans of the calcaneus. This classification is useful for deciding the treatment as well as reporting the results. This system defines four types of fractures (Fig. 3.14):

Type 1—Undisplaced fractures
Type 2—2 part split fractures
Type 3—Depressed fractures and/or 3 part split fractures
Type 4—4 part/comminuted fractures

JAYPEE BROTHERS

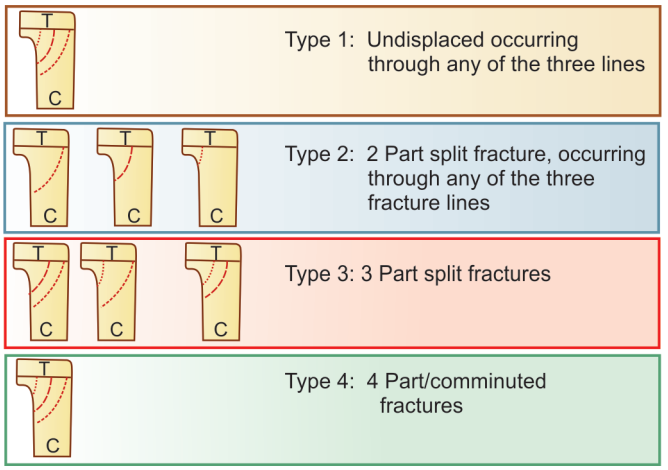

Figure 3.14

Diagrammatic representation of calcaneal fractures in coronal plane based on Sander's classification. *T—talus; C—calcaneus

Accordingly, patients with type 1 injuries do well with nonoperative treatment; patients with type 2 and 3 injuries may be treated effectively with open reduction and internal fixation; type 4 injuries defy operative reduction.

Rowe classification: Based on this classification the fracture is classified into five types as follows (Fig. 3.15).

Type 1a—Tuberosity fracture medial or lateral

Type 1b—Fracture of the sustentaculum tali

Type 1c— Fracture of the anterior process of the calcaneus

Type 2a—Avulsion fractures involving posterior calcaneus (Beak fractures)

Type 2b—Avulsion fracture involving the insertion of the tendo-Achilles

Type 3—Oblique fracture of the body not involving the subtalar joint

Type 4—Body fracture involving the subtalar joint

Type 5—Body fracture with subtalar joint depression and comminution

Radiology in Fracture Calcaneum

Following views are necessary for a detailed evaluation:

- Lateral view—for assessment of 'Bohler's tuber angle' and 'crucial angle of Gissane' (Figs 3.16A and B).
- Axial view (Harris view)—for assessment of subtalar joint involvement.
- Anteroposterior view—for assessment of calcaneo-cuboid joint and avulsion fractures at the anterior and lateral part of the calcaneus.

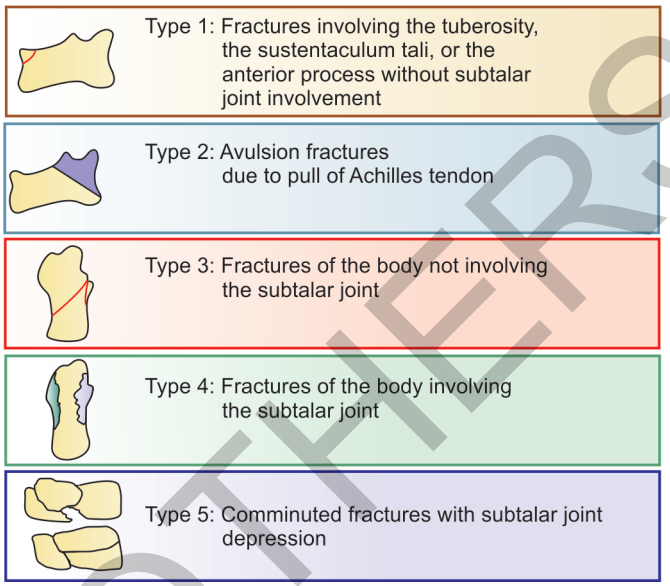

Figure 3.15

Diagrammatic representation of calcaneal fractures based on Rowe classification.

- Oblique view (Anthonsen view and Borden view)—for assessment of articular extension of fractures.
- CT scan in complex and comminuted fractures for detailed and 3D evaluation.

Treatment

Aim of treatment of fracture calcaneum is to maintain the 'crucial angle of Gissane' and 'Bohler's joint tuber angle' and maintain the anatomy of calcaneocuboid articulation (when indicated).

Undisplaced fractures as well as fractures which do not involve the articular surface (extra-articular fractures) are treated nonoperatively by application of well padded bandages, plasters slabs, casts and splints depending on severity of injury and immobilized for a period of 2–6 weeks. This is followed by gradual mobilization.

Displaced fractures as well as fractures which involve the articular surface and subtalar joint (intra-articular fractures) are treated by closed/open anatomical reduction and internal fixation using K-wires, cancellous screws or special plates, e.g. H-plates.

Avulsion fractures are treated by closed/open reduction and internal fixation (Figs 3.17A and B).

JAYPEE BROTHERS

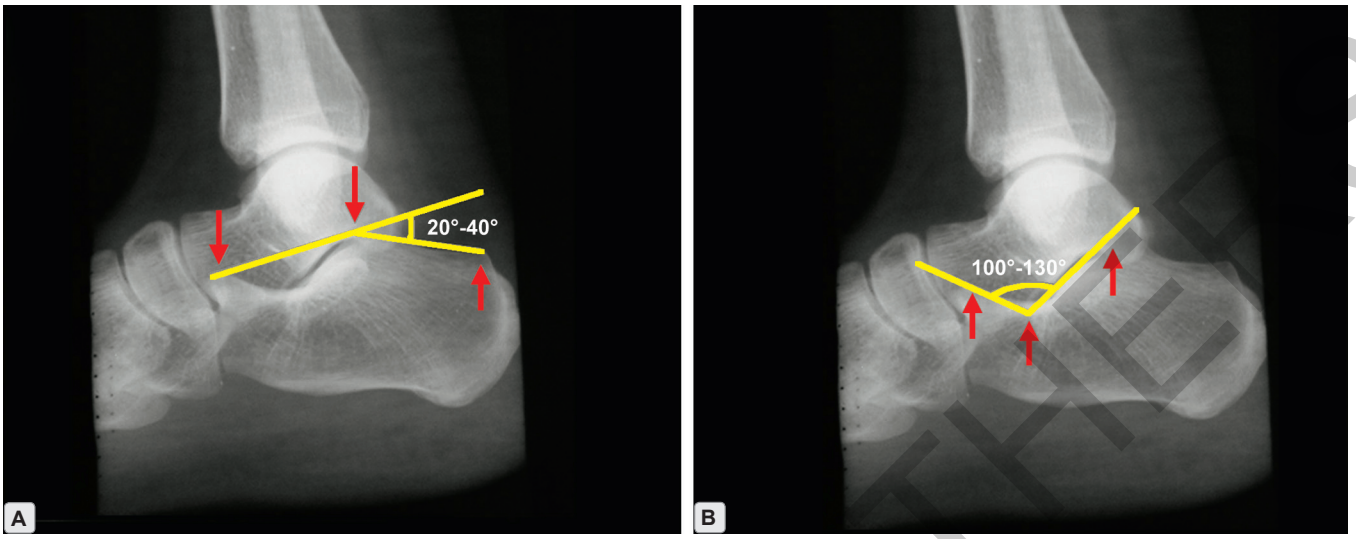

Figures 3.16A and B

(A) Normal 'Bohler's joint tuber angle' is 20–40°. It is an angle formed by two intersecting lines drawn between the superior margin of the posterior facet to the superior margin of the anterior process, extended proximally and another line drawn from the same point on the superior margin of the posterior facet to the superior margin of the tuberosity. The angle decreases or at times reverses in a posterior facet collapse; (B) Normal 'crucial angle of Gissane' is 100–130°. It is formed by the lines drawn between the lateral margin of the posterior facet and the anterior process. It increases in posterior facet depression.

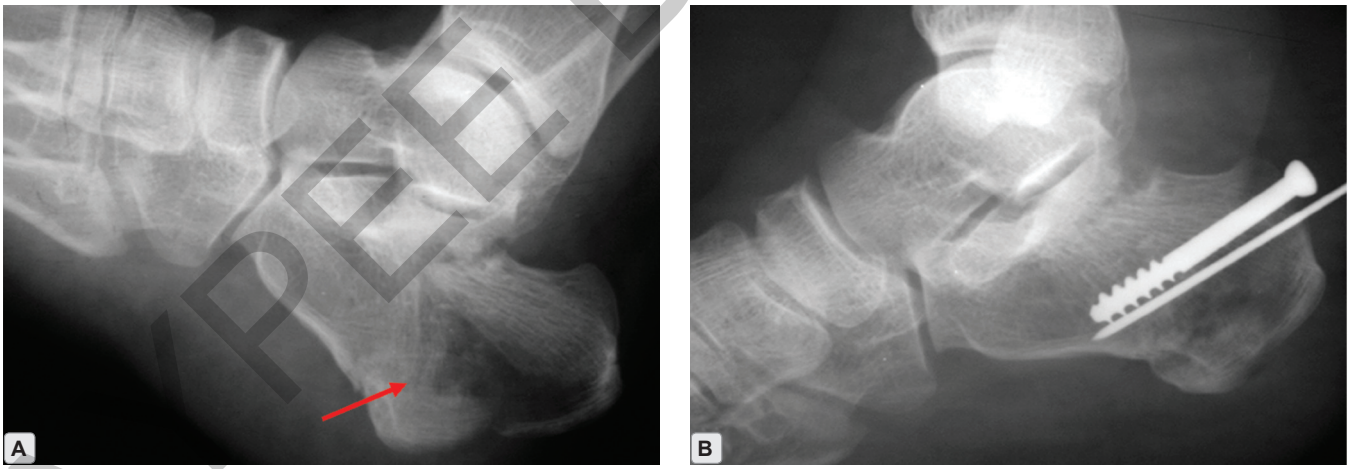

Figures 3.17A and B

Radiographs of an extra-articular fracture of the calcaneum fixed by closed reduction and internal fixation. The technique of fixation was as follows. A pin was driven through the fractured bone. With the pin as the lever the fracture was manipulated and reduced with the foot in plantar flexion. Then the pin was driven further through the fracture site and the fracture was firmly transfixed. Next the cancellous screw was passed to achieve firm fixation. The transfixing wire may be kept *in situ* or may be removed.

JAYPEE BROTHERS

Severely comminuted and complex fractures are generally treated by arthrodesis of the subtalar joint (Arthrodesis is a secondary procedure. Rarely it is done as a primary procedure).

Revision Questions

Q. Discuss briefly the surgical anatomy and the functions of the calcaneum.
Q. What is the mechanism of injury in fracture calcaneum?
Q. Classify fracture calcaneum.
Q. Draw the 'Bohler's joint tuber angle' and 'crucial angle of Gissane' and discuss their clinical importance.
Q. How will you proceed with the investigations in a case of fracture calcaneum?

Essay Question

Q. Classify fracture calcaneum. Discuss the mechanism of injury, diagnosis and management of fracture calcaneum. Briefly discuss the prognosis.

INJURIES AROUND THE ANKLE

Injuries around the ankle fall into two groups:

A. Ligament injuries
B. Bony injuries

Ligament Injuries

The common ligaments injured are the lateral ligament, the medial or the deltoid ligament and the syndesmotic ligament (the ligament binding the lower tibia and the fibula, i.e. inferior tibiofibular syndesmosis). These injuries are classified into three grades.

- Grade 1—Stretching of the ligaments
- Grade 2—Partial tear of the ligaments
- Grade 3—Complete tear of the ligaments

Management

Complete and severe tears require surgical repair. Less severe, strains and sprains heal well with adequate immobilization. Physiotherapy and gradual mobilization is always essential for a good recovery.

Bony Injuries of the Ankle (Pott's Fracture)

Pott's Fracture

All bony injuries of the ankle are grouped under one eponym, i.e. '**Pott's fracture**' because, it was Sir Percivall Pott (1714–1788) who first made an attempt to describe the various injury patterns occurring at the ankle.

It was also thought that Sir Percivall Pott had this fracture, after he fell off his horse in the year 1756. But, the fact was that Sir Percivall Pott actually had a compound fracture of the femur.

Hence, the term is considered to be misnomer. Sir Percivall Pott, neither described these injuries completely nor suffered this fracture.

Definition

Pott's fracture is defined as a uni, bi or trimalleolar fracture with or without subluxation or dislocation of the ankle joint.

Points to Remember

Ankle joint is a beautiful **hinge joint** which allows only the **movement of *dorsiflexion and plantar flexion.*** This movement takes place in a mortise known as ankle mortise formed by medial, lateral and posterior malleolus (posterior 1/3rd of the inferior articular surface of the lower tibia is known as posterior malleolus). The ligaments that support the mortise are the deltoid ligament medially, the lateral ligament laterally and the syndesmotic ligament superiorly.

Any other movement occurring in the ankle joint other than dorsiflexion and plantar flexion, is abnormal and tends to injure the supporting bony and ligamentous structures, leading to deformation of the joint. Failure patterns thus seen are several, because the ankle joint is amenable for a variety of abnormal stresses. These failure patterns are similar and are reproducible by a specific type of stress. This has been accurately described by Lauge-Hansen in this 'Genetic Classification' which he derived after experiments on cadavers. He used a wrench and subjected the cadaveric ankle to a variety of stresses and documented the results. It is worth noting that a particular type of stress produced a particular failure pattern and these patterns of failure were reproducible.

Lauge-Hansen' Genetic Classification

In this classification, the position of the foot at the time of impact as well as the direction of deforming force is

JAYPEE BROTHERS

or detailed information of orthopedic books, visit our website www.jaypeebrothers.com, for detailed information of orthopedic books, visit our

Essentials of ORTHOPEDICS

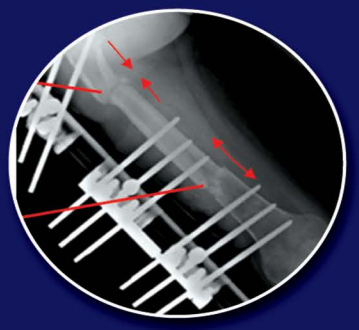

SALIENT FEATURES

- Overview of orthopedics with special emphasis on high-yield topics for both undergraduates and postgraduates
- Precise and updated information with recent advances
- Lucid presentation with numerous illustrations to enhance easy reading and retention
- Extensive X-ray images accompanying description of entities
- Meticulously revised second edition with additional contents.



RM Shenoy D Orth MS Orth is a renowned Orthopedic Surgeon who has to his credit 32 years of service in the specialty. Currently, he is a Professor and Unit Head, Department of Orthopedics at Yenepoya Medical College (a constituent of Yenepoya University), Mangalore, Karnataka, India. Previously, he served as the Head of the Department of Orthopedics at Srinivas Institute of Medical Sciences and Research, Mangalore (2010–2012) and as a Professor at Kasturba Medical College (Manipal University), Mangalore (1982–2010). He has undergone several specialty trainings in Orthopedics in India, USA and France before choosing a career path that included dedicating a considerable amount of time for teaching activities. He is recognized as a teacher par excellence and has taught a large number of undergraduates and postgraduates. He is well known for his clinical acumen, analytical and meticulous approach as well as clarity of expression. He has participated in several seminars and Continuing Medical Educations (CMEs) as faculty and also has delivered guest lectures at multiple state and national conferences. This book summates his vast experience and exemplifies his love for teaching and imparting knowledge.

Shelving Recommendation
ORTHOPEDICS

ISBN 978-93-5090-373-5
9 789350 903735

Available at all medical book stores
or buy directly from Jaypee Brothers through online shopping
at www.jaypeebrothers.com

JAYPEE BROTHERS
Medical Publishers (P) Ltd.
www.jaypeebrothers.com